

ANALOGIES AND DIFFERENCES OF THE SECOND
AND EIGHTH NERVES AND END-ORGANS: GEN-
ERALIZING, PRELIMINARY, ANATOMIC CON-
SIDERATIONS, ESPECIALLY WITH REFERENCE
TO CHOKED DISC, GLAUCOMA, AND CHOKED
LABYRINTH

CLIFFORD B. WALKER, M.D.

Los Angeles

At or shortly after the time when the ophthalmologist and the otologist began to devote their entire attention to the intensive study of their own subject at the expense of the other specialty, the neurologic surgeon came into the field, and there occurred a thinly overlapping group of facts interesting to all three, yet perhaps of necessity more frequently explored by the neuro-surgeon than by either of the other two. Gradually each became quite conscious of his tiny gaps of knowledge in the specialties of the others in relation to his own. These gaps may occur in a very irregular and quite surprising manner; for instance, I have heard a prominent otologist express astonishment at the fact that the nerve fibers grow up the optic stalk from the retina, or the ophthalmologist will be surprised when he learns that the aqueous is directly analogous to the endolymph of the ear both in formation, entrance and egress; or again, a neurologist may express interest that both the eye and the ear have at least one raphé and one macula.*

I had not progressed far in accumulating analogies or near analogies, which I hoped might be of useful interest to

* Doubtless conscious of some such situation, Dr. Isaac Jones suggested, in a symposium on the eighth nerve before the Los Angeles Study and Research Club, delving into the physical analogies and differences of the second and eighth nerves, although later on the possibilities of the so-called choked labyrinth brought the subject more to the foreground.

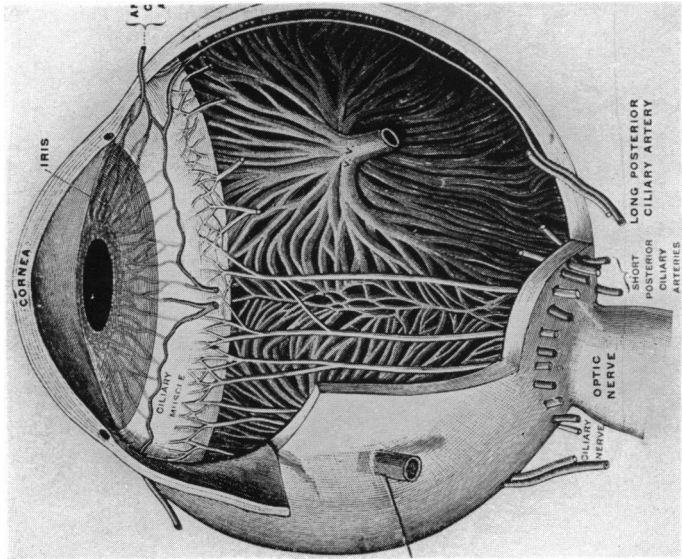


Fig. 1 A

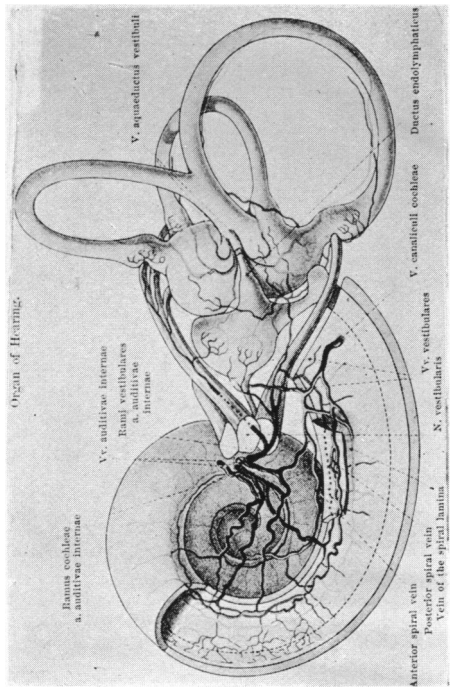


Fig. 1 B

Figs. 1 A and 1 B.—For rapid comparison of blood supply as regards size and number of vessels. The eye seems to have about 25 arteries as large as the single auditory artery (Festut and Spaltenholz).

all three specialists and perhaps to others, when I came across a fact which was most stimulating. This fact was that Dr. Herman Knapp, one of the fathers of ophthalmology in this country, to whom we all owe so much, not only for his contributions to science, but also for his foundations and endowments of various sorts, including the offering of a medal for research work, had written the first and only paper in the English language bearing on this subject. There was also the feeling and hope that in some small way the discharge of a well-recognized obligation might also be effected by accumulating a more readily accessible comparative grouping of facts in this field. Herman Knapp's⁵⁴ communication, which appeared in the last conjoined publication of the Archives for Ophthalmology and Otology, consisted of a consideration of the diseases that affect both the eye and the ear, translated and amplified from the work of Moos,⁶⁵ but none of the other ramifications of possible analogies or differences was touched upon—in fact, many were not known at that time.

While one naturally considers this subject first from the anatomic standpoint, still the knowledge we possess at the present time permits the grouping of facts which largely follow at least six general divisions, namely, embryologic and developmental, anatomic, physical, clinico-pathologic, toxemias and poisons, and hydrostatics.*

The ear, being purely an organ for receiving tactile or pressure sensations, is much less vascular than the eye, apparently in the ratio of approximately 25 to 1, when it is considered that the auditory artery is about the same size as a single long ciliary artery, whereas the eye has 25 arteries of similar caliber (fig. 1). Evidently the eye is a chemical laboratory requiring a large blood supply, and while it

* This paper will be devoted largely to anatomic considerations, since upward of 200 points and 66 illustrations have been accumulated and distributed under the various captions, and will, *in case it seems desirable*, be brought into print if time and space permit.

normally handles only about one octave of vibration frequency (wave length about 380 to 760 mm.) as compared with the 10 octaves of frequency (about 20 to 20,000) handled by the ear, still it must control the chemical reactions of photopic, scotopic, and color vision, together with their heat transformations, as well as provide for action currents, equilibrium sensations, glycolysis, vitaminosis, and pupillomotor activation. Whereas some pigment is found in the internal ear, the amount is practically nil as compared with the pigment and visual purple of the eye, and is apparently without function. Even if the middle ear received just as much blood as the labyrinth, the eye would be at least 10 times more vascular than the ear, and its sensitivity is almost in the same proportion.*

Incidentally there seems to be accumulated about 10 times as much knowledge concerning the eye and its functions as that concerning the ear. The methods of accurate examination of the eye and its functions seem to exceed those of the ear in a similar ratio, and certainly the eye is 10 times more accessible for study, not only on account of its transparency, but also because of its motility and relatively soft encapsulation. In the literature the otologists apparently refer to analogies found in the eye with respect to the ear correspondingly more frequently than the ophthalmologist refers to the ear.

The acoustic canal measures about 17 mm. on its longest side, but it is often only one-half as long on its shortest side, averaging about 10 mm. in length, and terminating in an ampullating expansion decidedly larger than the width of its entrance diameter, which is 5 mm. The ampullae accommodate the expansion of the cochlear and vestibular ganglions, together with branches of the audi-

* Knudsen estimates that the eye is between six and seven times as sensitive as the ear in percentage difference detection, while Ferree and Rand³¹ accept a 2 to 1 ratio as regards acuity in the most sensitive parts.

tory nerve, facial nerve, and pars intermedialis (Wrisberg). Several anastomoses occur between the superior branch of the auditory nerve, the pars intermedialis, and the facial nerve, exhibiting, at the beginning, the great anastomotic tendency of the auditory nerve. However, notwithstanding all these nerves the acoustic canal, as compared with the optic canal, is only loosely filled. Each of these nerves is accompanied by a small artery, and the auditory artery is also accompanied by one auditory vein and fine lymphatics, but in no instance are any of these vessels embedded within the nerves, as in the case of the ophthalmic vein and artery. The auditory nerve divides into five vestibular branches, in addition to the main cochlear branch, which enter the labyrinth through separate openings. It is interesting to note that in some of the vertebrates the optic nerve likewise divides into several distinct branches, with separate points of entry into the globe.²⁹ The auditory artery is a branch of the basilar artery, close to the circle of Willis; in the same way the ophthalmic artery originates from the internal carotid, also situated close to the circle of Willis. The dura, arachnoid, and pia extend along the auditory nerves as far as their entrance into the labyrinth, after the manner in which the sheath of Schwalbe follows the optic nerve, and in both cases these arachnoidal extensions contain cell rests capable of producing meningiomas.

The optic foramen, which in cross-section is 4.5 by 6.5 mm., carries only the ophthalmic artery and fine lymphatics in addition to the optic nerve and is more snugly filled by its contents than the auditory canal, yet it permits a free flow of subarachnoid cerebrospinal fluid and also within the sheath of Schwalbe to the plane of the lamina cribrosa. The lymph from both the labyrinth and the optic nerve returns largely to the subarachnoid spaces.

Both optic and auditory bony canals may be enlarged, a condition shown by the *x*-ray by the presence of a new growth,

but, according to Adson,* in his experience such enlargement of the optic canal is rare.

The venous drainage of the labyrinth is effected by way of three different channels: (1) The auditory vein through the auditory canal to the superior petrosal sinus; (2) the vestibular vein to the inferior petrosal sinus or lateral sinus through the aquaeductus vestibuli, close to but in a separate canal from the ductus endolymphaticus; and (3) the cochlear vein, running to the inferior petrosal sinus in the canalis cotunnii, paralleling the ductus cochlearis as it travels in the aqueduct of the cochlea. None of these veins has an arachnoidal investment, and although they may be exposed to lateral pressure from the subarachnoidal space, yet they are more or less protected by the dural investment. In no instance, therefore, are they surrounded by strangulating pressure, as in the case of the central vein of the optic nerve. However, those veins entering the reversible current of the petrosals, like the veins from the eye, have two possible exits. The auditory vein and the vein of the cochlear canal have an adequate anastomotic connection within the labyrinth, and also one branch is received from the utricle and saccule, whereas the remaining venous return from the ampullae and the semicircular canals is quite distinct, as it returns in the vena aquaeductus vestibuli, somewhat parallel with the ductus endolymphaticus. According to Politzer,⁷¹ the vessels of the labyrinth near those of the middle ear anastomose through minute perforations of the thin intervening wall.

Within the eye the ophthalmic vein has practically no anastomotic connection, while the venae vorticosae anastomose freely among themselves and to some extent with

* Dr. Alfred W. Adson and Dr. Walter I. Lillie were courteous and kind enough to review and criticize my first outline of this subject, and gave this additional point, for which I wish to express thanks. For other points as they appear in this or subsequent papers I acknowledge my deep obligation to Dr. Harvey Cushing, Dr. Chas. H. Frazier, Dr. Walter E. Dandy, Dr. Dana W. Drury, Dr. Lewis H. Weed, and Dr. Stacy R. Guild.

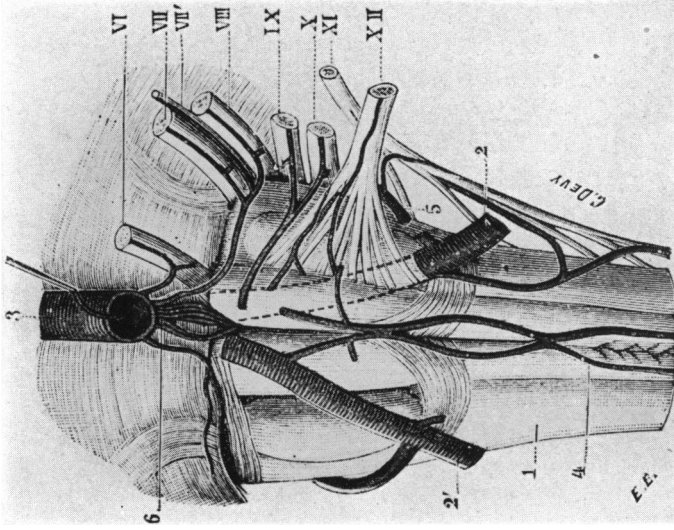


Fig. 2 A

Fig. 2 A.—Showing origin of auditory nerve and its course without penetrating the auditory nerve. 1, Bulbus, front view. 2, Vertebral artery. 3, Basilar trunk. VI, Oculomotorius external. VII, Facial. VIII, Trigeminal. VIII, Auditory. IX, Glossopharyngeus. X, Pneumogastricus. XI, Spinal. XII, Hypoglossus.

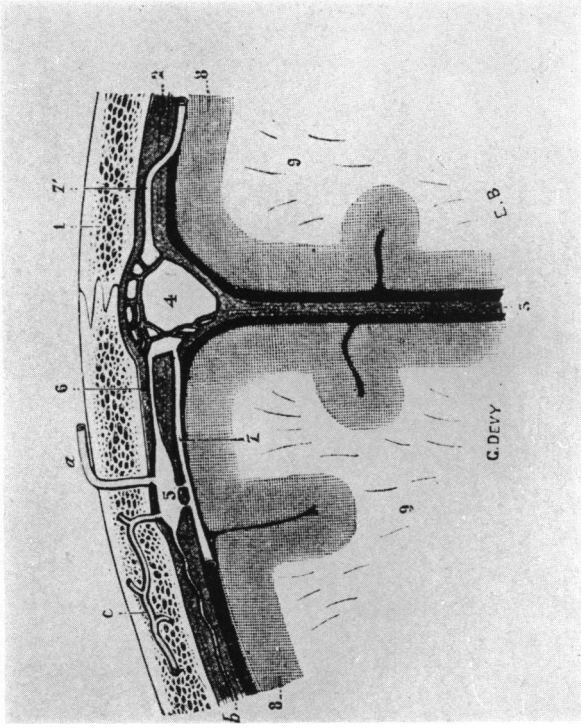
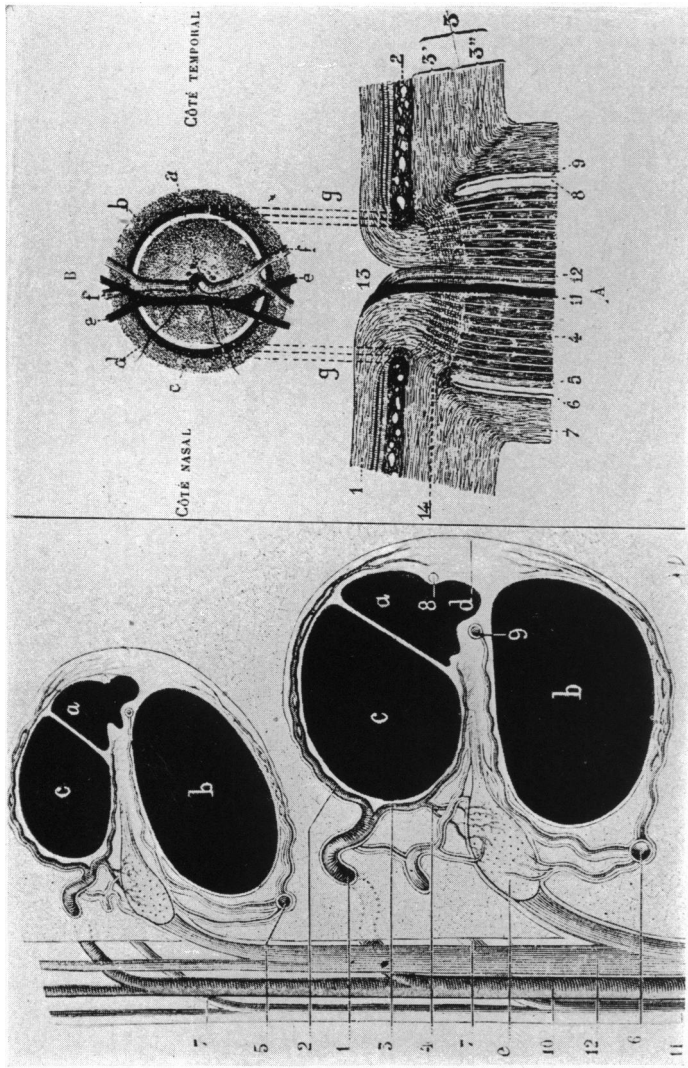


Fig. 2 B

Fig. 2 B.—General method of return of veins from cranial bones through and in the dura to a sinus; 1, Diploë. 2, Dura mater. 3, Falx cerebri. 4, Longitudinal superior sinus. 5, A receiving intradural lake (sanguineous); (6) One emissary vein; (7) meningeal vein; (c) diploic vein; (d) canal which anastomoses with cerebral veins (Testut).



B

A

Fig. 3.—To show difference in hydrostatic principle present at entrance of nerve.

A, Arteries and veins remain distinct throughout. 1, Spiral artery. 2, Its anterior branches. 3, Middle branches. 4, Posterior branches. 5, Superior spiral vein. 6, Inferior spiral vein. 7, Vein of the lamina spiralis. 8, Prominent vessel. 9, Spiral vessel. 10, Internal auditory artery. 11, Internal auditory vein. 12, Cochlear nerve. a, Scala media or endolymph canal; b, Scala tympani; c, Scala vestibuli, perilymph canals (Testut).

B, Artery and vein enclosed completely in a potential mechanical press. 1, Scleral portion of the optic nerve. 2, Retina. 3, Choroid. 3', Lamina interna, forming lamina cribrosa. 3'', Laminae externae which continue with the dural sheath of the optic nerve. 4, Optic nerve. 5, Sheath of pia. 6, Sheath of arachnoid. 7, Sheath of dura. 8, Subarachnoid space. 9, Subdural space. 11, Central artery of retina. 12, Central vein. 13, Physiologic excavation of papilla. 14, Lamina cribrosa. B, Papilla of the optic nerve; a, Physiologic excavation; b, grayish points represent lamina cribrosa; c, scleral ring; d, choroid ring; e, artery; f, vein (Testut).

the anterior ciliary and conjunctival veins. Outside of the eye the blood may return either to the cavernous sinus or to the facial plexus of veins, because of the free communication between the two. It can seek the line of least resistance, and is, therefore, not affected by intracranial pressure even to the extent that the returns from the labyrinth may be. Thus it seems possible to set up an analogy between the ophthalmic vein and the venae aquaeductus vestibuli as regards their independence and drainage into a channel having a double exit, but they differ in that the ophthalmic vein is encircled by nerve, pia, and arachnoid, whereas the venae which drain semicirculars may only receive lateral pressure from the arachnoid as it travels either within or on the inner surface of the dura.

As regards the presence of anastomosis both within and without their drainage territory, the venous returns of the choroid are like those of the cochlea; and in respect to the double exit from the limiting walls of this territory, and as regards their final external drainage in either one of two large channels, they also resemble those of the cochlea. Nevertheless, they are unlike these in that the venae vestibuli, on leaving the labyrinth, are in no wise subjected to intracranial pressure, whereas the auditory and the cochlear vein may receive quite severe lateral pressure from the arachnoid, although not in the same class with the encapsulation of the ophthalmic vein. This may be helpful in considering the fact that when intracranial pressure is present, hemorrhage, diapedesis, and the like are often found in the cochlea and retina and never in the choroid. Valves are absent throughout the venous system of both the eye and the ear.

Nerves. If the arrangement of the optic nerve fibers—by which they entered the eyeball in separate bundles—as first described in certain vertebrates by Johannes Deyl,²⁹ had persisted, the optic nerve might be more like the audi-

tory nerve than it is at present. Now we find these fibers are most unlike in the matter of anastomosis and bundle arrangement. The anastomotic tendency is greatest in the cochlear division (fig. 5A), beginning almost as the fibers leave the percipient elements; it is marked in the ganglionic region, and is also noticeable in the auditory canal. Not only this anastomosis, but interweaving of the fibers takes place, so that cross-sections, in order to trace bundle or quadrant defects, are not so valuable in the auditory nerve as in the optic nerve and therefore are not so often displayed. Considering the orderly manner in which the optic nerve is arranged, one wonders how the auditory nerve maintains any system in sound reports. Certainly such meshing could never be tolerated in the telephone switchboard.

Normally, the glia extends farther toward the percipient elements in the auditory than in the optic nerve—the auditory nerve averages 18 mm. in length and the glia extends to within 6 mm. of the macula. These measurements are from 2 to 4 mm. shorter in women than in men. The extension is farther out the vestibular portion of the auditory nerve. The glia extends only to the disc in the optic nerve.

The fibers of both nerves are medullated. This medullation, in the case of the optic nerve, is lost at the lamina cribrosa, but in the auditory nerve it persists through the bony cribriform, corresponding to the membranous macula, and stops at the habenula perforata in the cochlea and at the basement membrane of the macula of the vestibular portion. Although these labyrinthine entrances seem better fortified by both bony and fibrous gateways, where the lamina cribrosa is only fibrous, nevertheless the arachnoid follows along the nerve loosely enough so that cerebral pressure may be delivered nearer to the nerve endings in the labyrinth than in the bulbus. The myelin sheath of the auditory nerve is segmented and grows each way from the bipolar ganglion cells, as do the nerve fibers, whereas the myelin sheath of the optic

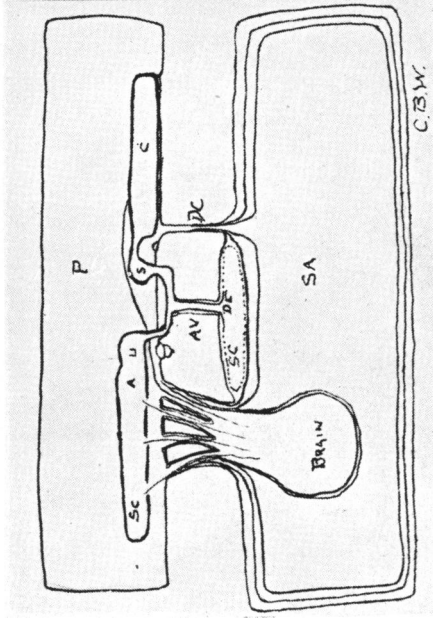


Fig. 4 A

Fig. 4 A.—Diagram to emphasize hydrostatics of cerebrospinal fluid, perilymph, and endolymph. *sc*, Subarachnoid cerebrospinal fluid space surrounded by subarachnoid *sd*, dura and connected with *p*, Perilymph space by *dc*, cochlear duct. Endolymphatic space, *e*, Sinus; *cd*, Cochlear canal; *a*, ampulla; *u*, utricle; *ae*, ductus endolymphaticus leading to *sc*; *s*, saccus endolymphaticus; *av*, aquaeductus vestibularis; *u*, sacculus; *c*, cochlear canal (C. B. Walker).

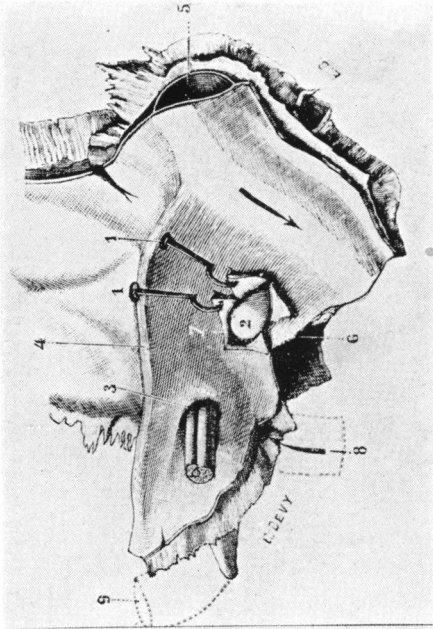


Fig. 4 B

Fig. 4 B.—Posterosuperior part of petrosal to show endolymphatic sac. 1, Dura mater. 2, Saccus endolymphaticus. 3, Internal auditory canal with three nerves. 4, Sinus petrosus superior. 5, Lateral sinus. 6, Posterior part of petrosal. 7, Aquaeductus vestibuli. 8, Aquaeductus cochleae. 9, Carotid interna (Testut).

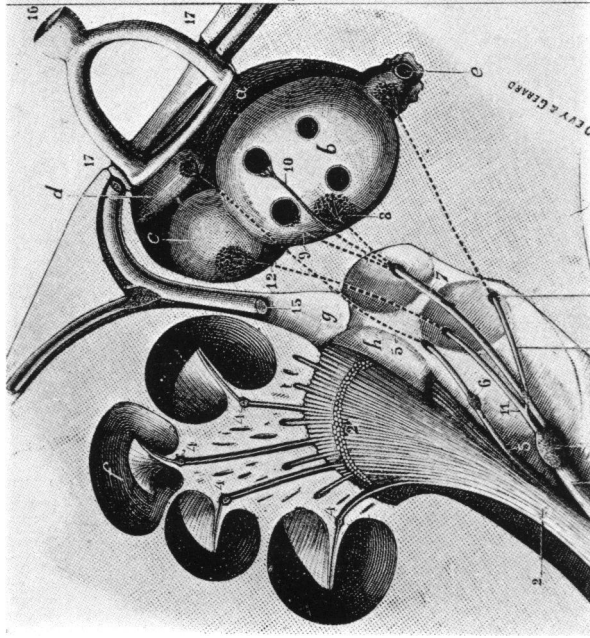


Fig. 5 A

Fig. 5 A.—Sketch showing the distribution of auditory nerves. a, Vestibule, with b, Utricle. c, Saccula. d, Beginning part of cochlear canal. e, Ampulla of posterior semicircular canal. f, Cochlea. g, Aquaeductus fallopi. h, Bottom of internal auditory tube with four small fossae. i, Cochlear branch, with j, Vestibular branch. k, Vestibular ganglion. l, Small branch from the vestibular part of the cochlear canal. m, Superior ampullar nerve. n, Superior vestibular nerve. o, Utricular nerve. p, Superior ampullar nerve. q, External ampullar nerve. r, Inferior vestibular nerve. s, Saccular nerve. t, Facial nerve. u, Stapes on the fenestra ovalis. v, Tympanum (Testut).

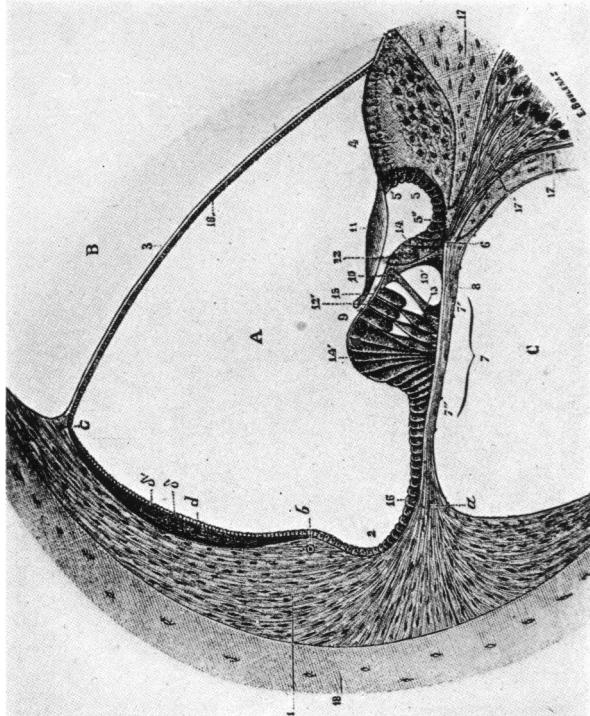


Fig. 5 B

Fig. 5 B.—Transversal section of cochlear canal with special showing of the epithelial cells of Corti's organ. A, Scala media. B, Scala vestibularis. C, Scala tympanica. 1, Spiral ligament, with a, Insertion of the basillary membrane; b, cup of spiral ligament with section of vas prominens; c, crest of insertion of Reissner's membrane. d, Stria vasculosa with two layers—epithelial and conjunctival. 2, External spiral ridge. 3, Reissner's membrane. 4, Furrowed bandelette. 5, Internal spiral ridge, with 5', Vestibular part, and 5'', Tympanic part. 6, Foramen for the nerves. 7, Basillar membrane, with 7', Smooth zone, and 7'', Striated zone. 8, Spiral vessel. 9, Corti's organ, with 10, One of its pillars, and 10', Tunnel. 11, Membrana tectoria. 12, Internal ciliated cells. 12' External ciliated cells. 13, Deiters' cells. 14, Internal Claudius cells. 14', External Claudius cells. 15, Reticular membrane. 16, Epithellum of cochlear canal. 17, Lamina spiralis ossea, with the efferent canal of Rosenthal overtopped by efferent branches of Corti's ganglion. 18, Circumferential lamina (Testut).

nerve is unsegmented and grows down from the brain after the nerve fiber has grown up from the unipolar retinal ganglion cells.

The analogy of the saccus endolymphaticus to Schlemm's canal (fig. 7). When it was noted, by comparing measurements, that the circumference of the saccus endolymphaticus—the average diameter of which is 12 mm.—was practically equal to that of Schlemm's canal—also 12 mm. in diameter—and that both drained more or less peripherally through numerous special exit devices⁴³ into venous channels,^{45,79} it became interesting to study the limits to which the analogy could be carried.

The anterior chamber of the eye and the endolymph canals of the labyrinth may be regarded as closed cavities draining through such peripheries as have just been described, and obtaining their supply of fluid to a large extent from a vascular area, which may be considered the ciliary body in the eye and the stria vascularis in the cochlear canal (scala media) of the membranous labyrinth. If the length of this stria is taken as about 30 mm., it is seen to be almost as long as the circumferential measurements of the ciliary processes, without accounting for the folds of these processes. Although the volume of the two chambers may be very similar, yet it seems quite certain that the rate of flow is greater in the anterior chamber of the eye—1 c.mm. per min. This is reasonable in view of the greater vascularization and productive area of the ciliary body. Further, the portals of exit are less extensive for the saccus, as they are more toward the neck of the pars intermedia of the sac, at least, according to Guild,⁴⁶ in the case of the guinea-pig. Not only does the drainage area in the saccus appear to be less extensive, but a membrane of columnar epithelium without a basement layer, having the drainage ability of arachnoid villi, is interposed before the endolymph reaches the surrounding copious venous system, whereas in Schlemm's canal the connection

is quite direct, by capillary anastomosis, with the ciliary venous system, although membranes still more definitely of the character of arachnoid villi are found in the pectinate ligament, called pectinate villi by Weed and Wegefarth.^{98,101} Thus the circulation of the aqueous in the eye, of endolymph in the ear, and of the subarachnoid ventricular fluid in the brain all seem to be subject to an analogous mechanism of nature. In this respect they fit well into the general system of control of fluids in the body cavities, as taught by Weed, although published only in part as yet.*

Some difference seems to be present, due to the fact that the anterior chamber is lined with endothelium while the membranous labyrinth is lined with epithelium, yet Guild shows endothelial cells in the avascular villi found in the saccus. Perhaps these cells are derived from the venous sinus lining, into which they drain. Clearly, the analogy is sufficient to allow one to speculate on the possibilities of trephining the saccus in case its drainage mechanism should become blocked and thereby produce a hypertension analogous to that of glaucoma within the membranous labyrinth. As a matter of fact, the saccus has been surgically drained (Portmann⁷⁵) several times in an effort to control persistent tinnitus, which it was believed might be due to hypertonus in the endolymphatic chambers. The great handicap of the otologist thus far has been his inability actually to measure the pressure and rate of flow in the aural chambers in the way that the ophthalmologist does so easily in the chambers of the eye. But it seems certain, since the way has been pointed in Guild's work, that data on these points should soon appear.

Further, it may be analogized that both the eye and the ear have to a certain extent a pumping mechanism. Thus if the scleral spur, being frequently pulled upon by the longitudinal fibers of the ciliary muscle, provides a flow outward

* Personal communication.

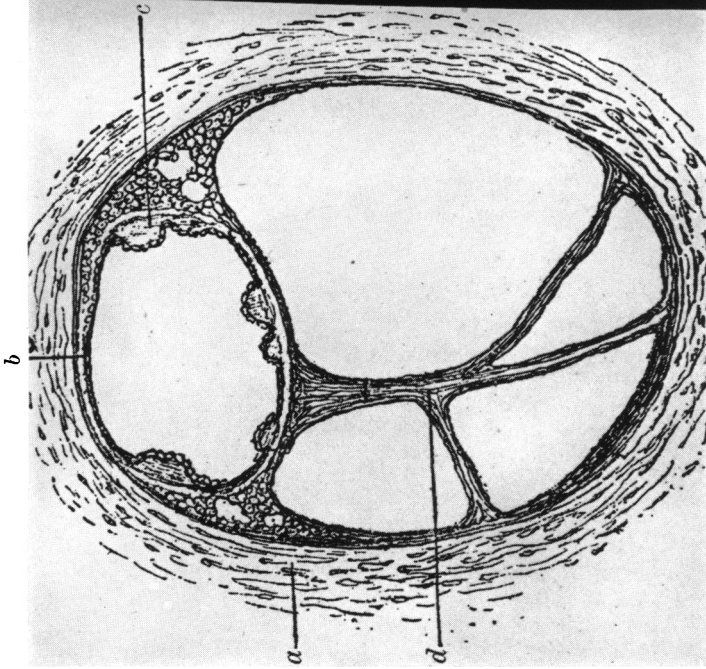


Fig. 6 A

Fig. 6 A.—Section of the osseous and membranous semicircular canals. *a*, Osseous semicircular canal; *b*, place of attachment of the membranous semicircular canal; *c*, globular elevations on the inner surface of the membranous semicircular canal; *d*, vascular connective-tissue bands (Poltzer).

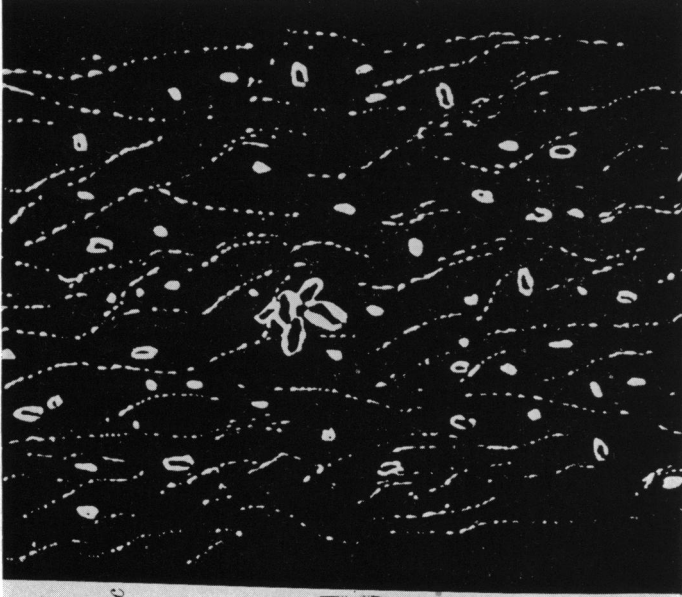
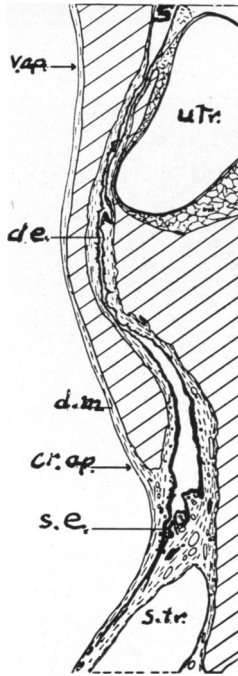


Fig. 6 B

Fig. 6 B.—Structure of the substance analogous to vitreous in which the otolith crystals are embedded. Under dark-ground illumination (Tenaglia).



• Fig. 7 B

Fig. 7 B.—Section of the lumen of the ductus endolymphaticus (Guinea-pig). *cr. ap.*, *v. ap.*. The arrows indicate, respectively, the cranial (or external) and the vestibular (or internal) apertures of the osseous aquaeductus vestibuli, bone being shown by oblique hatching, as in the other figures. *d.e.*, Ductus endolymphaticus; *d.m.*, dura mater; *s.*, sacculus; *s.e.*, sacculus endolymphaticus; *s.tr.*, transverse dural venous sinus; *utr.*, utriculus (Guild).

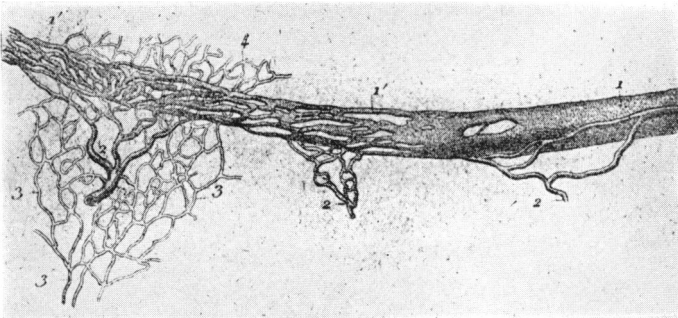


Fig. 7 A

Fig. 7 A.—Schlemm's canal (Leber). 1, 1', Canal with anastomoses and plexuses. 2, 2, 2, Veins of the ciliary muscles emptying into the canal and on the other side anastomosing, with 3, The episcleral venous network. 4, Venous network on the brim of the cornea, which continues in front of Schlemm's canal, with episcleral net.

from Schlemm's canal and the pectinate villi, then it might appear that the pulsation of the cerebral tissues against the saccus with each heart beat could perform a similar function for the endolymph system. The long capillary tube—6 mm. by .025 mm. in diameter—of the ductus endolymphaticus plus the pars intermedialis of the saccus is analogous in function to the tortuous canals of the pectinate ligament and Schlemm's canal. At least it would have to have a capacity roughly of only 1/25 that of the anterior chamber—which is 1 c.mm. per min.*—to be analogous on a basis of the larger blood supply to the eye.

The drainage mechanism of the anterior chamber, however, seems much more free than that of the saccus, which apparently has more of the characteristics of a semipermeable membrane. In the dog, Weed and Wegefarth have described mechanisms in the drainage apparatus of the anterior chamber (fig. 8A) which have the characteristics of the arachnoid villi, yet much more definitely than in the monkey. In the same way that closure of Schlemm's canal or the drainage angle of the eye can produce hypertony in the eye, so closure or obstruction of the ductus or the saccus endolymphaticus can produce signs of pressure in the endolymphatic chambers of the ear, as indicated by dilatation of the canals. This has been noted by Guild⁴⁶ in the guinea-pig, and by Fraser³⁵ in a man, aged twenty-three years, with congenital lues and deafness. Incidentally, it may be observed also that the work of Rüdinger, cited in many textbooks as having demonstrated the presence of fine channels leading from the periphery of the distal portion of the saccus into the dural lymph channels, has not been confirmed by Guild,⁴⁵ by Sterzi,⁹² or by Siebenmann.⁸⁵

The ductus endolymphaticus (fig. 4) receives a right-angle—rather than a “Y”—connection from the utricle as it proceeds to the saccule. The saccule is connected with

* Friedenwald, Jonas S. Tr. Am. Ophth. Soc., 1931, xxix, p. 153.

the cochlear canal (scala media) by another narrow canal, the "ductus reuniens," and on this account, since the narrow— $1/8$ mm.—arm of the right-angle branch going to the utricle is very short—1 mm.—it might be expected that pressure changes between the saccus and the utricle and the semicircular canals would be less prompt than between the saccus and the cochlea. However, this may not account entirely for the fact that hemorrhage is more common in the cochlea not only during the unrelieved pressure of brain tumor, but also immediately after decompression operations. Probably the reason for this is that the vessels are more fully protected by trabecular fibrous tissue in the semicircular posterior canal of the labyrinth.

The ductus cochlearis is a direct by-pass, 9 mm. long and 0.25 mm. in diameter, connecting the chamber of the scala tympani—and, therefore, the entire perilymph chamber surrounding the endolymph canal—with the subarachnoid space (fig. 4). In this respect there is only the faintest analogy in the eye. That is to say, the connection of the subchoroid space of the eye with the subarachnoid chamber of the sheath of Schwalbe is of such microscopic dimensions that it has been a matter of argument. Certainly from a pressure standpoint the percipient elements of the eye are protected from cerebral pressure by this route better than in the case of the ear, where the subarachnoid fluid and pressure can be effective almost if not quite to the terminal elements. Because of this condition the necessity for the fluid counterpressure obtainable from a by-pass possibly accounts for the ductus cochlearis, in much the same way that the Eustachian tube equalizes the air pressure on the membrana tympani. However, there is this difference: the counterpressure in the labyrinth must be accomplished partly through the intermediation of the flexible Reissner's membrane in balance with the saccus endolymphaticus, its drainage exits, and fluid additions from the stria vascularis.

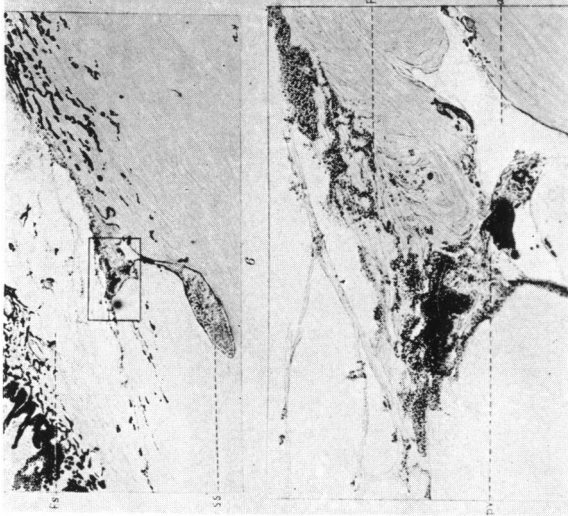


Fig. 8 A

Fig. 8 A.—Upper part: Posterior chamber injection. Filtration limited to one point along scleral surface. Direct communication between large sinus and branch of anterior ciliary plexus (Schlemm's canal). *f. s.*, Fontana space. *s. s.*, Scleral sinus. Lower part: High power at point of drainage to show continuity of column of pigment-granules between angle and plexus. The specimen was counterstained with eosin alone, but even here the protrusion of the pectinate tissue into the sinus can readily be seen. *p. l.*, Pectinate ligament; *a. p.*, Anterior ciliary plexus. *p. v.*, Pectinate villus (Wegearth).

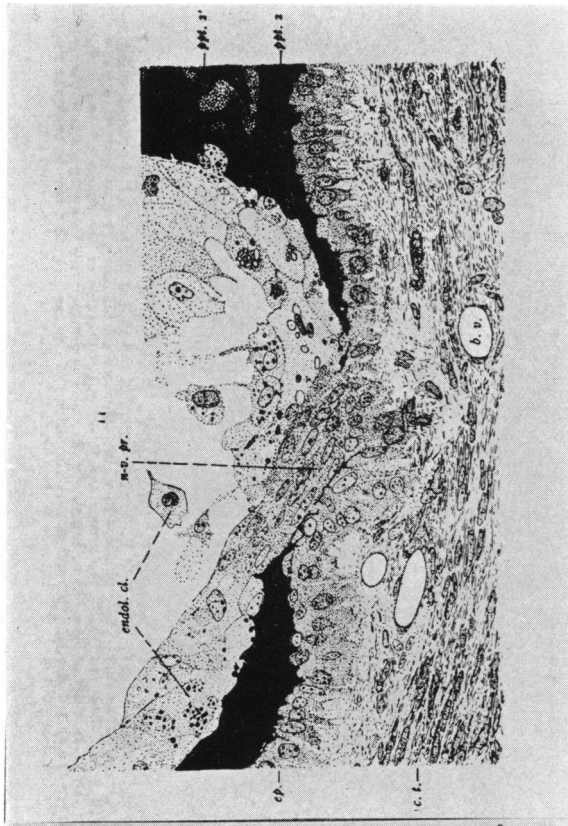


Fig. 8 B

Fig. 8 B.—A non-vascularized epithelial process (*n-v. pr.*) cut through its long axis, as well as typical wall and contents of the columnar epithelial region of the sacculus. *n-v. pr.*, Non-vascularized epithelial process. *endol. cl.*, Cells and debris in the lumen of sacculus endotheliateus. *ep.*, Epithelium. *c. l.*, Connective tissue. *b. v.*, Blood-vessel (Guld).

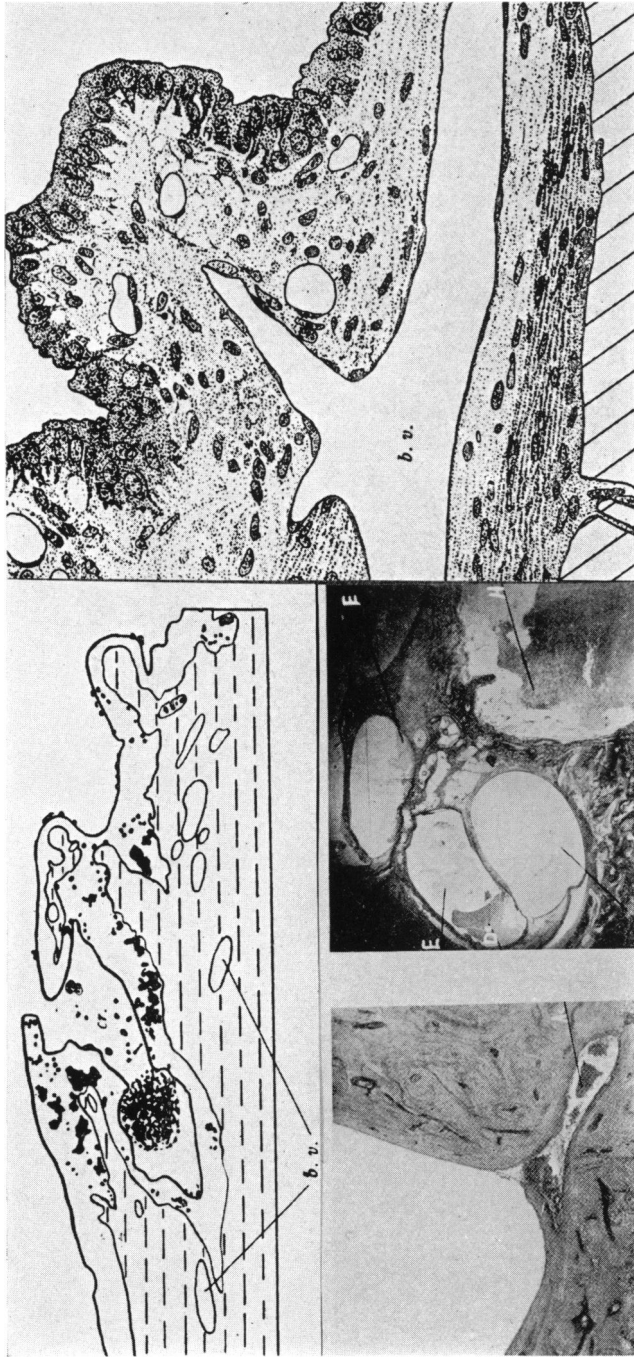


Fig. 9.—A. Outline sketch of part of wall of pars intermedia of the saccus endolymphaticus—after a 1 per cent. solution of equal parts of potassium ferrocyanid and iron-ammonium citrate had been injected into the ductus cochlearis; fixation by 10 per cent. formalin plus 1 per cent. HCl. In order to permit the Prussian-blue precipitate to be demonstrated in the sketch without the use of a colored-illustration, the epithelium and connective tissue have been shown in outline only. *ep.*; Epithelium, in outline. *c.l.*, Connective tissue, shown with horizontal hatching. *b.v.*, Two of several small blood-vessels in sketch. *cr.*, A crypt of the saccus. All solid black dots and masses represent the ferric ferrocyanid present (Guild).

B. Typical region of the wall of the part of the saccus endolymphaticus in which columnar epithelium is present (pars intermedia of the saccus endolymphaticus proprius of the suggested terminology). *b.v.*, Longitudinally cut blood-vessel; this vein empties into the transverse sinus. The lumina of this and the other blood-vessels are empty because of the vascular injection of the fixation fluid (Guild).
 C. Tumor of the upper region of the parietal lobe. Not operated upon.
 A.c. Choked labyrinth. Blood and exudate in the cochlear aqueduct, upon.
 D. Tumor of the middle fossa. Not operated upon. Choked labyrinth. Hemorrhage in the internal auditory meatus, H—; exudate in the scalae, E, E, E, and in the cochlear canal (Alexander).

Therefore the total result may be an increase of pressure, both inside and outside the membranous labyrinth, practically equal to that of the intracranial pressure. As far as the increase of pressure alone is concerned, we have an analogy with glaucoma more than with ocular choked disc, since the latter does not increase the pressure within the eyeball, although, as Parker⁶⁸ has shown, the low-pressure eye is affected first by intracranial pressure.

Nevertheless hemorrhages, exudates, and venous congestion occur in the cochlea³ as in choked disc, under the same condition of increased intracranial pressure; therefore the increased labyrinthine pressure is still unable to balance the thin-walled venous congestion produced by lateral—not choking—pressure on the auditory vein. On the other hand, although, on that account, there are increased pressure and nerve atrophy in the ear, yet there is not the cupped-disc effect in the ear, because there is no flexible lamina cribrosa, but rather a multitude of rigid bony sieves; *e. g.*, zonula perforata, etc. This does not permit the stretching of the nerve fibers and the strangulation of nutrition, as are found in glaucoma simplex. Furthermore, the function of the labyrinth must be impaired less than that of the eye under increased pressure. According to Crowe and Dandy, who state, in a personal communication, after examining the records of 500 brain tumor cases, that no disturbance of hearing occurred no matter how high the intracranial pressure, unless the auditory pathways themselves were encroached upon. The extremely large tumors which occur in the chiasmal and in the frontal region offer the clearest demonstration of this phenomenon.

CONCLUSIONS

Altogether it seems as if the labyrinthine condition in cerebral pressure does resemble the conditions of both glaucoma and choked disc to a certain extent, but not enough to take

the name of either without giving a wrong impression. It really justifies a new name, just as glaucoma and choked disc did in the first place. For the present, a descriptive term, such as "hydro-congestive labyrinth" or "otic hydro-congestion," would be more definite than "choked labyrinth," the "hydro" element indicating the increase of fluid pressure, as in intracranial pressure, while the term "congestive" indicates that part of the congestive phenomena of choked disc that may be present. Then again "endolymph-hydrops," or simply "otic hydrops," would be a better term to use than "glaucoma of the ear" in describing the condition of insufficient drainage from the aural endolymphatic system.

Symptomatically, there is a certain similarity in the early stages of congestive hydro-labyrinth, glaucoma simplex, and choked disc, provided one deprives the ophthalmologist of his tonometer, perimeter, and ophthalmoscope.* Then, just as the otologist may detect no defect in hearing or equilibrium by ordinary tests, so may the simple central visual test fail to show appreciable loss of vision in choked disc or simple glaucoma for many months—perhaps, in some cases, for years.

It seems certain, at least, that the pressure in the otic perilymph must increase as the subarachnoid pressure increases (fig. 4A) if the cochlear duct is patent, since the supply of cerebrospinal fluid is so great that no otic drainage would be sufficient to carry off the large amount necessary to keep the labyrinthine pressure normal. This increased pressure in the perilymph canals would tend to depress Reissner's membrane (fig. 5B)—even rupture it—unless the pressure in the endolymph canal was also increased. Pressure in the endolymph canal could be raised by pressure of the brain

* Thereby reducing the state of the ophthalmologist to that of the otologist, who is fully conscious of these deficiencies and is turning for study to animals having a somewhat transparent, almost skin-deep, large labyrinth, not bony encased, as, *e. g.*, the hammer-headed shark.¹⁰⁸

against the saccus endolymphaticus, thereby sufficiently reducing its drainage until the difference in the pressure could be borne by Reissner's membrane. In the absence of definite experimental knowledge of the pressures in these canals it would seem that the frequent finding of hemorrhage in the cochlea after cranial decompression is significant. This can be explained by the sudden release of these hydrostatic pressures through both the ductus endolymphaticus and the ductus cochlearis, leaving the congested surface capillaries of the membranous cochlea insufficiently supported. Vibration due to operation on the skull and blood-pressure elevated by an anesthetic would aid also in starting such bleeding. A similar condition occurs in the operations for the relief of high tension in the eyes, perhaps to a less extent because of the greater use of vasoconstricting drugs. Thus the hydro-congestive labyrinth of cerebral hypertension has some, but not all, of the features of both choked disc and glaucoma.

Glaucoma of the type due to insufficient drainage into the canal of Schlemm has a more direct analogue in the "otic hydrops" of the endolymph chambers due to insufficient saccus drainage. To what extent this condition in the ear may account for such a syndrome as Ménière's disease is uncertain, but it is not difficult to conceive that it may occur almost as frequently as the analogous condition in the eye, and it probably accounts for more distorted hearing and imperfect equilibrium than we are now able clearly to differentiate.

I am particularly indebted to Dr. Harvey Cushing for stimulating interest, suggestion, and criticism. Likewise, it is a pleasure to acknowledge the helpful suggestions of Dr. Isaac Jones, Dr. Charles H. Frazier, Dr. Alfred W. Adson, Dr. Walter I. Lillie, Dr. Dana W. Drury, Dr. Lewis H. Weed, Dr. Stacy R. Guild, Dr. Samuel Crowe, and Dr. Walter E. Dandy. I wish also to express my appreciation of the erudite

cooperation of Dr. Slava Pavich in translating many difficult passages in numerous languages, also for bibliographic search and assembly, as well as for careful survey of the manuscript.

REFERENCES

1. Adler: Arch. Ophth., 1927, lvi, p. 593.
2. Alexander: Monatschr. f. Ohrenh., 1927, lxi, p. 446.
3. Idem: Surg. Gynec. Obst., 1928, xlvi, p. 361.
4. Idem: Handbuch d. Hals-, Nasen- u. Ohrenh., Herausg. v. A. Denker and O. Kahler, Julius Springer, Berlin; J. F. Bergmann, München, 1926.
5. Idem: Monatschr. f. Ohrenh., 1918, lii, p. 161.
6. Idem: Ztschr. f. Psychol. u. Physiol. d. Sinnesorg., 1905, xxxviii, p. 24.
7. Idem: Arch. Neerl. d. Physiol., 1922, vii, p. 552.
8. Alexander and Marbourgh: Handbuch d. Neurologie d. Ohres, Urban and Schwarzenburg, Berlin, 1928.
9. Alt: Monatschr. f. Ohrenh., 1898, xxxii, p. 97.
10. Beaver: Lehigh Valley M. Magazine, 1893, v, p. 134.
11. Benesi: Monatschr. f. Ohrenh., 1920, liv, p. 961.
12. Benjamins: (Groningen) Internat. Zentralbl. f. Ohrenh., July, 1930.
13. Boettcher: Kritische Bemerkungen und neue Beiträge zur Literatur des Gehörlabyrinthes, 88pp., 2 pl. 8 (Dorpat), W. Glasers Verlag, 1872.
14. Brunner: Monatschr. f. Ohrenh., 1927.
15. Bruns: Die Geschwulste des Nervensystems, Berlin, 1908.
16. Camis and Creed: The Physiology of the Vestibular Apparatus, Clarendon Press, Oxford, 1930.
17. Cannieu: Compt. rend. T., cxix, No. 2.
18. Cunningham: Text-Book of Anatomy, Macmillan Co., New York, 1902.
19. Cushing: Bull. Johns Hopkins Hosp., Sept., 1901, p. 290.
20. Idem: Am. J. M. Sc., cxv, p. 1017.
21. Idem: J. M. Research, 1914, xxvi, p. 1.
22. de Juan: Acta oto-laryng., xiv, pt. 1-2.
23. De Kleyn and Versteegh: J. Laryng. & Otol., 1927, xlii, p. 649.
24. Denker and Kahler: Handbuch d. Hals-, Nasen- u. Ohrenh., Julius Springer, Berlin, 1927.
25. Deyl, Jan: Diseases of the Optic Nerve, Norris and Oliver, 1898, iii, p. 579.
26. Idem: Now. lek. Poznan., 1904, xvi, p. 194.
27. Deyl, Johannes: Anat. Anz., 1895, xi, p. 687; čas. lék česk., 1896, 35: 81, 1892.
28. Idem: Rozpr. čezke acad. čis. Frantiska Josefa, 1897, vii, No. 14, p. 1.
29. Idem: Anat. Anz., 1895, xi, p. 8.
30. Drury: Laryngoscope, 1925, xxxv, p. 1.
31. Ferree and Rand: Arch. Ophth., 1931, v, p. 225.
32. Fischer: Monatschr. f. Ohrenh., 1925, lix, p. 877.
33. Flechsig: Die Leitungsbahnen im Gehirn und Rückenmark des Menschen auf Grund entwicklungsgeschichtlicher Untersuchungen, W. Engelmann, Leipzig, 1876, xvi, p. 382.
34. Fraser: Arch. Otolaryng., 1931, xiii, p. 2.
35. Idem: Laryngoscope, 1923, xxxiii, p. 721.
36. Gerstmann: Wien. klin. Wchnschr., 1927, p. 1133.
37. Gildemister: Ztschr. f. Hals-, Nasen- u. Ohrenh., 1930, xxvii, p. 290.
38. Gladkov: Z. usn. Bol., 1929, vi, p. 636.
39. Grahe: Centralbl. f. Hals-, Nasen- u. Ohrenh., 1924, v, p. 289.
40. Grashey: Festschrift, 1892, iv, p. 1.

41. Gray: *Labyrinth of Animals*, J. and A. Churchill, London, 1907, i, p. 27.
42. Idem: *Anatomy of the Human Body*, Lea & Febiger, Philadelphia, 1924, Ed. 21.
43. Guild: *Anat. Record*, 1924, xxvii, p. 205.
44. Idem: *J. Lab. & Clin. Med.*, 1919, iv, p. 153.
45. Idem: *Am. J. Anat.*, 1927, xxxix, p. 57.
46. Idem: *Am. J. Anat.*, 1927, xxxix, p. 1.
47. Habermann: *Ztschr. f. Ohrenh.*, 1917, lxxv, p. 19.
48. Hamburger: *Am. J. Ophth.*, 1930, xiii, p. 831.
49. Henks and Lubarsch: *Handbuch d. spec. Path. Anat. u. Hist.*, Wittmaack, xii.
50. Hoff: *Ztschr. f. Neurol.*, 1929, cxxi, p. 751.
51. Horsley: *Tr. Roy. Soc. London*, 1890.
52. Karlefors: *Acta oto-laryng.*, 1924, iv, Suppl.
53. Katz: *Verhandl. d. X. Internat. Congress, Berlin*, 1900.
54. Knapp, Herman: *Arch. Ophth. & Otolaryng.*, 1878, iii, p. 173.
55. Kobrak: *Arch. f. Ohrenh.*, 1930, cv, p. 132.
56. Kolmer: *Handbuch d. mikroskopischen Anatomie d. Menschen*, Wilhelm v. Mollendorff, 1928, iii, pt. 1.
57. Kompanejetz: *Monatschr. f. Ohrenh.*, 1930, lxiv, p. 193.
58. Kravkov: *Graefe's Arch. f. Ophth.*, 1930, cxxiv, p. 335.
59. Lasareff: *Bull. de l'acad. sc. de Rusoie*, 1918, p. 1297.
60. Lewis: *Tr. Sect. Ophth.*, A.M.A., June, 1931.
61. Maxwell: *Labyrinth and Equilibrium*, Philadelphia and London, 1923.
62. Meltzer: *Gradenigo's Syndrome*.
63. M'Nally: *Lectures on Physiology of Ear*, 1930, xxxix, p. 248.
64. Mendoza: *Rev. españ. y Americana de laryngol.*, June, 1930, p. 251.
65. Moos: *Berl. klin. Wchnschr.*, 1884, xxi, p. 713.
66. Idem: *Verhandl. d. Internat. Med. Congress, Berlin*, 1891.
67. Morris: *Human Anatomy*, P. Blakiston's Son & Co., Philadelphia, 1893.
68. Parker: *J. A. M. A.*, 1916, lxvii, p. 1053.
69. Idem: *Arch. Neurol. & Psychiat.*, 1925, xiv, p. 31.
70. Piersol: *Anatomy*, J. B. Lippincott Co., Philadelphia, 1930, Ed. 9.
71. Politzer: *Diseases of the Ear*, Lea Brothers, Philadelphia, 1922, Ed. 4.
72. Idem: *Arch. f. Ohrenh.*, 1874, xi.
73. Idem: *Arch. f. Ohrenh.*, 1905, lxv, p. 161.
74. Porter: *Ann. Oto-Laryng.*, 1930, xxxix, p. 193.
75. Portmann: *Proc. Roy. Soc. Med.*, 1927, xx, p. 1862.
76. Pritchard: *Quart. J. Med. Sc.*, 1876.
77. Riley: *Arch. Ophth.*, 1930, iv, p. 640; p. 885.
78. Rüdinger: *Über die Verbreitung des Sympathicus in der Animal. Rohre des Rückenmarkes*, J. J. Lentner, München, 1863.
79. Idem: *Über die Abflusskanäle d. Endolympe d. inneren Ohres*, F. Staub. München, 1888; *Army Med. Library*, reprint from, *Sitz. d. math.-phys. Cl. d. k. bayer. Akad. d. Wiss.*, 1887.
80. Idem: *Beiträge zur Anatomie d. Gehörorganes der venosen Blutbahnen der Schadelhöhle sowie der überzähligen Finger*, München, 1876.
81. Idem: *Cursus der topographischen Anatomie*, J. F. Lehmann, München, 1899, Ed. 4.
82. Rumjanzewa: *Ztschr. f. Augenh.*, 1930, lxxii, p. 391.
83. Ryder: *Development of the Eye*, Norris and Oliver, 1897, i, p. 1.
84. Sherrington: *Tr. Roy. Soc. London*, 1898, p. 190.
85. Siebenmann: *Passow's Beitr. z. Anat.*, u. s. w. d. Ohres.
86. Idem: *Ztschr. f. Ohrenh.*, 1899, xxix.
87. Idem: *Ztschr. f. Ohrenh.*, 1896, xxix, p. 28.
88. Somberg: *Am. J. Ophth.*, 1927, x, p. 837.

320 *Analogies and Differences of Second and Eighth Nerves*

89. Sorsby: *Brit. J. Opth.*, 1931, xv, p. 1.
90. Spalteholtz: *Hand-Atlas of Human Anatomy*, J. B. Lippincott Co., 1900.
91. Stenvers: *Psychiat. u. Neurol.*, 1924, vi, p. 227.
92. Sterzi: *Morph. Jahrb.*, 1909, xxxix, p. 446.
93. Testut: *Traité d'Anatomie Humaine*, Octave Doin et Fils, Paris, 1911, Ed. 6.
94. Tolt: *Atlas of Human Anatomy*, Macmillan Co., New York, 1928, Ed. 2.
95. Urbantschitsch: *Pflüger's Arch. f. d. ges. Physiol.*, 1880, xlii, p. 155.
96. Veronese: *Riv. Veneta di sc. med. Venezia*, 1888, ix, p. 322.
97. Von Stein: (a) *Die Lehre von Funktion d. Labyrinthes*, Jena, 1847. (b) *Der Schwindel*, Universitätsklinik Moskau, 1910. (c) *Auge u. Ohr von Martin Bartels in Kurzes Handbuch d. Ophthalmologie*, Schieck and Bruckner, 1931, iii, p. 725.
98. Weed: *J. M. Research*, 1914, xxvi, p. 21.
99. Idem: *J. M. Research*, 1914, xxvi, p. 51.
100. Idem: *J. M. Research*, 1914, xxvi, p. 93.
101. Wegfarth: *J. M. Research*, 1914, xxvi, p. 119.
102. Idem: *J. M. Research*, 1914, xxvi, p. 149.
103. Wegfarth and Weed: *J. M. Research*, 1914, xxvi, p. 167.
104. Werner: *Ann. Otol., Rhin. & Laryng.*, 1930, xxxix, p. 104.
105. Idem: *Ztschr. f. Hals-, Nasen- u. Ohrenh.*, 1930, xxvi, p. 445.
106. Wilkinson: *J. Laryng. & Otol.*, 1930, xlv, p. 833.
107. Wilmer: *Wash. M. Ann.*, 1912, xi, p. 253.
108. Wittmaack: *Klin. Beitr. z. Ohrenh.*, (Festschrift f. Urbantschitsch), 1919.
109. Wodak: *Monatschr. f. Ohrenh.*, 1922, lvi, p. 826.
110. Würdemann: *Am. J. Opth.*, 1927, x, p. 831.
111. Zange: *Anatomie und Physiologie der mittelohrentspringenden Labyrinthentzündungen*, J. F. Bergmann, Wiesbaden, 1919, p. 187.