

The Effect of *Pneumostrongylus tenuis* (Nematoda: Metastrongyloidea) on Kids

R. C. Anderson and Uta R. Strelive*

SUMMARY

Kids, 6-28 weeks of age, infected with 200-1000 infective larvae of meningeal worm (*Pneumostrongylus tenuis*) of white-tailed deer (*Odocoileus virginianus*), developed colitis and peritonitis. *Bacteroides* sp., *Bacillus* sp., *Escherichia coli*, *Proteus* sp. and *Enterococcus* sp. were found in the peritoneal cavity. Most kids were moribund or dead 4-11 days after infection and frequently the colon had ruptured. Only two kids (of 11) in which the disease was allowed to run its course survived colitis and peritonitis but these two animals developed severe neurologic signs 18 and 38 days after infection. Numerous developing worms and various traumatic and other lesions were found in the central nervous system of kids which developed neurologic signs.

RÉSUMÉ

On a pu produire de la colite et de la péritonite chez des chevreux en les infestant, à l'âge de 6 à 28 semaines, avec 200 à 1000 larves de *Pneumostrongylus tenuis* d'*Odocoileus virginianus* (chevreuil à queue blanche). On a réussi à isoler de la cavité péritonéale des Bactéroïdes, *Bacillus*, *Escherichia coli*, *Proteus* et *Enterococcus*. La plupart des chevreux étaient morts ou mourants entre 4 et 11 jours après l'infection et leur colon s'était rupturé. Sur onze chevreux, deux seulement survécurent à la colite et à la péritonite. Ces deux animaux manifestèrent cependant de graves symptômes neurologiques de 18 à 38 jours après l'infection. On observa de nombreuses formes évolutives de vers et plusieurs lésions traumatiques et autres dans le système nerveux central des chevreux qui avaient souffert de symptômes neurologiques.

INTRODUCTION

Pneumostrongylus tenuis, the meningeal worm of the white-tailed deer (*Odocoileus virginianus*) of eastern North America, has been transmitted experimentally to moose, wapiti, mule deer, caribou, sheep and guinea pigs in all of which it can cause neurologic diseases; the worms migrate to the central nervous system and lacerate the neural parenchyma of these hosts (1, 3, 4, 5, 7, 15). During August, 1967, larvae of *P. tenuis* were given orally to a kid which subsequently developed signs of illness and died on the fifth day apparently of peritonitis. Subsequent studies, outlined herein, indicate that *P. tenuis*, when given to kids in doses of 200 larvae or more, caused a fatal necrotizing colitis and peritonitis. Also, kids surviving the intestinal phase of the infection succumbed to neurologic disease.

MATERIALS AND METHODS

Infective larvae of *P. tenuis* were removed by artificial pepsin digestion from the terrestrial snails *Triodopsis albolabris* and *Mesodon thyroidus* exposed to first-stage larvae from faeces of a white-tailed deer fawn. Larvae were concentrated in a few ml of water and given orally to kids. The kid used in experiment I was about four months of age. Kids used in experiments II-IV were about six weeks, three and a half months, and seven months of age respectively. Kids used in experiment IV were treated with 2-(4'-thiazoly) — benzimidazole¹ and 1-(4-amino-2-n-propyl-5-pyrimidinyl-methyl)-2-picolinium chloride hydrochloride² for one week prior to infection. Kids were not necessarily related,

*Department of Zoology, University of Guelph, Guelph, Ontario, Canada.

¹Thiabendazole, Merck, Sharp and Dohme, Montreal.
²Amprolium, Merck, Sharp and Dohme, Montreal.

having been purchased from several farmers near Guelph. Methods used to study the central nervous system were as previously described (2).

RESULTS

EXPERIMENT I

As a preliminary test, 500 larvae were given to a male kid during August, 1967. Three days after infection the kid appeared depressed. Its abdomen was swollen and apparently tender. It refused food. Signs remained the same until the time of death five days after infection. An extensive peritonitis found at necropsy was considered the immediate cause of death. Worms and lesions were not found in the central nervous system. Infiltrations of neutrophils and lymphocytes into the leptomeninges and in tissue about dorsal nerve roots (C7, T2, T6, T7, T13, L3-6, S2-4) suggested worms were in the vicinity.

EXPERIMENT II

Six kids were given 200-500 larvae and two were kept as controls (Table I).

Clinical signs — Infected kids became listless 3-6 days after infection and were reluctant to feed. Breathing was frequently laboured and irregular. A day or two after the onset of signs the abdomen became

swollen and the animals moved reluctantly with short, unsteady steps. Three kids (Nos. 1-3, Table I) were moribund 1-6 days after the appearance of signs. Three kids (Nos. 4-6, Table I) were found dead 1-5 days after the onset of signs. There was no relationship between the number of larvae given (200-500) and the onset of abnormal signs, or the time at which the kids were found moribund or dead. Control kids displayed no abnormal clinical signs during an observation period of two weeks after the commencement of the experiment.

Necropsy findings (Table I) — There was in all kids a diffuse, fibrinous peritonitis with much pink fluid in the peritoneal cavity. Mesenteric lymph nodes were enlarged, often 3-4 times, and oedematous. Dark red areas of various sizes were noted on the omentum. Small bright red areas were observed on the mucosa of the abomasum near the pylorus. The small intestine appeared swollen and flaccid. Usually an area about 6-8 cm long on one loop of the colon was darker in colour and had a circumscribed necrotic area in its centre. This necrotic area usually had a perforation with ragged edges and about 2-3 cm in diameter. Copious amounts of gut contents had been released through this perforation into the peritoneal cavity. The mucosa of the colon was dark red in colour and covered by a diphtheritic membrane in localized areas. Dark red areas were noted on the caecal mucosa.

TABLE I Experiment II. The Results of Infecting Kids with *Pneumostrongylus tenuis*

Kid No.	Sex	No. Larvae	First* Signs	Necropsy*	Condition Prior to Necropsy	Necropsy Findings
1	M	500	3	9	Moribund	Peritonitis and Rupture of Colon
2	F	400	3	4	Moribund	Peritonitis and Colitis
3	M	300	6	11	Moribund	Peritonitis and Rupture of Colon
4	M	200	6	7	Dead	Peritonitis and Rupture of Colon
5	F	200	3	8	Dead	Peritonitis and Rupture of Colon
6	M	200	3	4	Dead	Peritonitis and Colitis
7	M	0	none	14	Normal	Normal
8	F	0	none	14	Normal	Normal

*days after infection

Bacteriological findings — The colon of kid 2 had not ruptured. *Escherichia coli* was isolated from the spleen and peritoneal fluid of this kid. *Bacillus* sp. was cultured from fluid in the peritoneal cavity.

Histological findings — The most marked changes were in the spiral colon, mesentery, omentum, and intestinal serosa. There was coagulative necrosis of the wall of the colon which was infiltrated by inflammatory cells, mainly neutrophils. The mucosa of the colon was autolysed and covered in localized areas by a diphtheritic membrane. A marked fibrinopurulent peritonitis extended along the serosa of the small intestine and also involved the peritoneum; eosinophils were fairly numerous. Mesenteric lymph nodes were hyperplastic and oedematous. The muscle layers of the small intestine were sometimes invaded by inflammatory cells and the lamina propria was oedematous although the mucosa appeared normal. There were no significant changes in the liver, kidney, and spleen, and larvae were not found in sections.

EXPERIMENT III

Each of four kids (two males and two females) was infected with 600 larvae. A kid was killed for necropsy each day for four days (kids 1-4). Four kids (three males and one female) were kept as controls but only two were killed (days 1 and 2) for necropsy (kids 5-6).

Clinical signs — Kids 3 and 4 became depressed the third day following infection. The abdomen was swollen at this time. The animals seemed reluctant to stand and when they moved it was with short, uncertain steps. Both kids refused food. Rectal temperatures of kids 3 and 4 were 104.7 and 104.8°F respectively; rectal temperatures of two control kids were 103.4 and 104.3°F. Kids 7 and 8, which were not killed during the course of the experiment, did not show signs of illness during the experimental period or while under observation for several weeks after the experiment.

Necropsy findings — A few pinkish areas were found on the mucosa of the abomasum of kid 1. The mucosa of the first four cm of the duodenum of kid 2 was slightly red and there were a few tiny red spots on the mucosa of the abomasum. An early diffuse fibrino-haemorrhagic peritonitis covered the intestine of kid 3. Mesenteric lymph

nodes were 2-3 times normal size and oedematous; nodes near the ileo-caecal valve were reddish. The ileum was oedematous with subserosal petechial and ecchymotic haemorrhages prominent over an area 10 cm in length about 40 cm from the ileo-caecal valve. The mucosa of the ileum was dark red in several localized areas 1-5 cm in length. Subserosal petechiae were present on the caecum. Part of the mucosa of the caecum near the ileo-caecal valve was dark red. The peritoneal cavity of kid 4 contained a large amount of straw-coloured fluid and fibrin. Mesenteric lymph nodes were oedematous and swollen 3-4 times their normal size. A dark red area, about 3 cm in length, was seen in the duodenum about 30 cm distal to the pylorus. The intestinal mucosa was congested. A dark red area, about 5 cm in length, was seen in the ileum about 40 cm from the ileo-caecal valve. The spiral colon was dilated, flaccid, and greenish in colour (Fig. 1). The mucosa of the colon was dark red and covered by a membrane in certain localized areas.

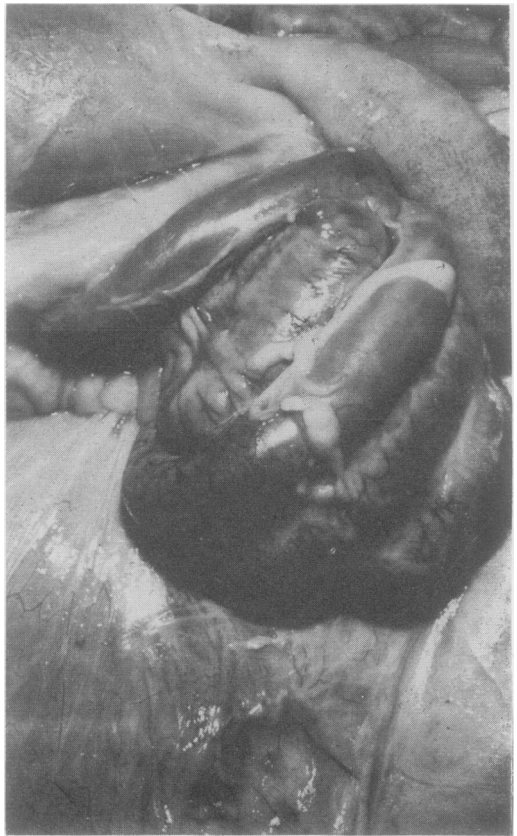

Fig. 1. Colitis in kid infected four days previously with 600 larvae of *P. tenuis*.

Control kids 5 and 6 appeared normal.

Bacteriological findings — Attempts to culture bacteria from swabs taken from the peritoneal cavity were unsuccessful.

Histological findings — A few tiny infiltrations of neutrophils and haemorrhages were observed in the lamina propria and muscularis mucosa of the abomasum of kid 1. Small infiltrations of neutrophils and lymphocytes were found in the submucosa and muscularis externa of the abomasum of kid 2. The epithelium was absent and there was infiltration of neutrophils, lymphocytes, and eosinophils in the lamina propria of the duodenum. The mucosa of the ileum of kid 3 was autolysed. The mucosa of the caecum was autolysed and haemorrhagic, and dense collections of neutrophils and eosinophils were present in the lamina propria; there was sloughing of the epithelium. Evidence of colitis and peritonitis (Fig. 2) in kid 4 was similar to that described in experiment II.

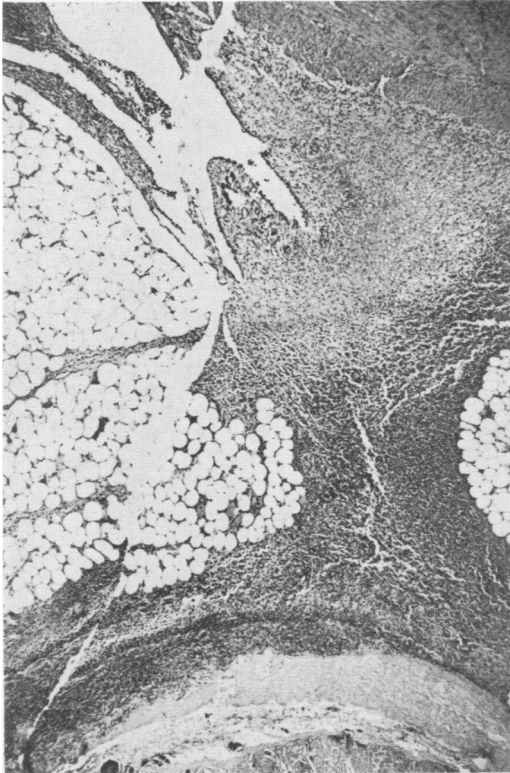


Fig. 2. Necrosis of the mucosa of the colon and peritonitis (with infiltrations extending in mesentery to intestine and within the external muscle layers of the colon), in kid infected four days previously with 600 larvae of *P. tenuis*.

EXPERIMENT IV

Four male kids were infected as follows: No. 1 — 1000 larvae; No. 2 — 800 larvae; No. 3 — 1000 larvae; No. 4 — 50 larvae. Two male kids were kept as controls. Kids 1 and 2 were killed and examined on the fourth day following infection.

Clinical signs — Signs of colitis and peritonitis in kids 1-3 within the first four days were similar to those noted at similar times in earlier experiments. Kid 3 appeared markedly depressed from the 4th to the 10th day after infection but on the 11th day it commenced to feed again. However, neurologic signs became apparent at this time. Evidence of lameness of the left front leg was observed and the head was held at a slight angle. The kid tended to crouch on the hindquarters. From the 12th to the 14th day following infection, the left hind and right front legs dragged. The animal had difficulty rising because of weakness of the limbs. By the 15th day the kid could not rise unassisted and from this day until the 18th day, when it was killed, it lay in left lateral recumbancy; the kid was hungry and would eat when fed by hand. Faeces were normal and there was no evidence of an elevated temperature.

Kid 4 did not display signs of colitis or peritonitis during the course of the experiment. However, 38 days after infection with only 50 larvae, it had trouble rising. Signs of locomotor difficulty persisted until the 41st day when the kid could not rise or stand unassisted. The left front leg was held in an abnormally flexed position and the hindquarters were weak. The fetlocks of the hind limbs knuckled. The kid displayed central nervous system abnormalities but was obviously hungry, eating well, and in good flesh. Breathing was rapid. The kid died the 42nd day after infection.

Necropsy findings — Findings in kids 1-2 were similar to those reported in experiment II; the colon had not ruptured. Adhesions were observed near the ileo-caecal junction in kid 3. Nothing abnormal was found in the viscera and central nervous system of kid 4. Control kids appeared normal.

Bacteriological findings — Peritoneal fluid and fibrin from kid 1 contained *Bacteroides* sp.; *Escherichia coli* was found in the peritoneal fluid and on the serosa of the colon. Peritoneal fluid of kid 2 contained

E. coli, *Proteus* sp., and *Enterococci* sp. Bacteria were not recovered from the heart blood, spleen, and liver of the above animals. Bacteria were not recovered from the peritoneal cavity of two control kids killed at the same times as kids 1-2.

Histological findings — Findings in the alimentary canal of kids 1 and 2 were similar to those reported in experiment II. Histological study of the central nervous system of kids 3 and 4 revealed the following:

Kid 3 — Worms were found in dorsal horns of grey matter in all regions of the spinal cord i.e. C1, C5, C6 (both horns), C7 (both horns), C8, T2, T4, T5, T10, T13 (both horns), L2 (both horns), L5 (both horns), L6. Worms were also in ventral horns at L1, L2, and S3, between dorsal and ventral horns at S4 and S5, and in the ventral funiculus at T2. There were delicate cavities surrounded by compressed tissue in dorsal horns at T2, T3, T9, L3 and undoubtedly these were caused by worms lying in tissue immediately prior to fixation. Infiltrations and perithelial proliferations were rare in various regions of the spinal cord which, under lower magnifications, appeared normal. More careful study revealed small areas of torn grey matter in dorsal horns, especially near worms. These disrupted areas tended to pull apart during the preparation of sections. Conspicuous focal haemorrhages were in dorsal horns at T2 and T10, in ventral horns at T2, and in grey matter between horns at T2. Less obvious haemorrhages were common in tissue near worms. Neuronal degeneration was observed at S4. There were no worms present and few changes in white matter. However, small areas of disrupted tissue with histiocytes and swollen axis cylinders were found in the dorsal funiculus at C6, the ventral funiculus at C8, T5, T7, T9, T11, and T13, and the lateral funiculus at T7.

Two worms were found in the brain stem near the roots of hypoglossal nerves. Trauma was slight and there was only slight cuffing with lymphocytes near the worms. A worm was found in the pons. Two worms were found in grey matter of the medulla oblongata. There was cuffing with lymphocytes and a few eosinophils near one worm and slight perithelial proliferations near the other. Minute haemorrhages were found also in the grey matter. There was a streak of degenerating tissue with histiocytes in the cerebellum.

Kid 4 (Table II). — Lesions were rare

in ventral horns and absent in the ventral funiculus. In the lateral funiculus lesions were most numerous in the dorsal region especially near dorsal horns. Worms, gliosis, histiocytes, and infiltrations of lymphocytes and eosinophils were common in dorsal horns and were associated frequently with torn tissue and microcavitations. Cells displaying chromatolysis and nuclear eccentricity were common in dorsal horns especially in the thoracic, lumbar and sacral regions. Infiltrations, gliosis, and histiocytes were relatively uncommon in funiculi suggesting that most damage there was relatively recent. Lesions in white matter consisted mainly of swollen axis cylinders, round cavities of various sizes, and focal haemorrhages. Infiltrations with many lymphocytes and eosinophils were common in the leptomeninges and often extended well into the dorsal sulcus and ventral fissure. Similar infiltrations were found in the dura matter. An interesting observation was the frequency of light to heavy infiltrations around dorsal nerve roots. The ependymal canal, invaded by worms and damaged in the sacral region, contained numerous histiocytes.

Few lesions were found in sections of the brain. Small perivascular cuffs of lymphocytes and eosinophils were in the medulla oblongata. One small area of focal malacia with numerous histiocytes, slight leptomeningitis, a few swollen axis cylinders, and degenerating neurons (chromatolysis) were in a lateral sector of the medulla oblongata. In the brain stem near the pons there was neuronal degeneration, cuffing with eosinophils, and a single haemorrhage with many histiocytes. A small area of gliosis was seen in the cerebellum. Lesions were not found in the cerebrum except for focal collections of eosinophils in the leptomeninges.

DISCUSSION

It is not yet possible to account for the occurrence of colitis and peritonitis in kids infected with meningeal worm although they are presumably associated in some way with the penetration of the larvae. Fourie (8) reported that larval *Oesophagostomum columbianum* in lambs may enter deep tissues of the bowel and facilitate bacterial invasion. Also, larvae may enter the peritoneal cavity and provoke a fatal peritonitis. According to Gordon (9)

TABLE II The Positions of Worms and Major Lesions in the Spinal Cord of a Kid Infected 42 Days Previously with 50 Larvae of *Pneumostrongylus tenuis*

	Dorsal horns	Ventral horns	Dorsal funiculus	Lateral funiculus	Lepto-meninges	Dura mater	Dorsal nerve roots	Ependymal canal
Worms	C1, L6		C2, C7, L6	C8, T2, T4	C7, C8, T11 T13, S2	T2, T11, S1	C7	T12
Microcavitations	C1, C3, T4, T5, T6, T10, S3	C2, S1	S3					
Swollen axis cylinders			C1, C2, C4, C5, C7, C8, T5, T10, T11, L4, L5, S1	C2, C4, C5, C8, T1, T2, T4, T5, T6, T11, T13, L1, S3				
Haemorrhages	C4, T12, L4, L6		T5, L5, L6	C2, C7, T6, T11, S3	C7, T13			
Histiocytes	C1, C2, C5, T5, T6, L1, L4, L5, S3	C2, S1	T10, T11	T12, T13				S3, S4
Gliosis	C1, C2, C3, C5, C7, T5, T6, T10 T11, L4, L5, S3							
Infiltrations	C1, C2, C3, C4, C7, T12, L2, L6 S4	C1, C2, C4, C5, L4, L11	C1, C2, C4, C5, L4, L11	C4, T2, T4 T6, T8	C4, C6, C8, T5, T6, T7, T10, T12 T13, L1, L2 L3, L4, L5, S1, S2, S3, S4, F. T.	C4, C6, T12, L1 L4, S2, S3, S4, F. T.	C2, C3, C7, C8 T1, T2, T4, T7 T9, T11, T12, T13, L1, L4, L5, S3, S4	
Neuron degeneration	T1, T2, T6, T9, T12, T13, L1, L2, L6, S2, S3	C1, T12, S3						

Abbreviations: C = cervical; T = thoracic; L = lumbar; S = sacral; F. T. = filum terminale. Sections were cut from blocks of tissue at each pair of spinal nerve roots usually including dorsal root ganglia.

nodules with *O. columbianum* often burst onto the peritoneal surface of the bowel resulting in peritonitis and adhesions; 200-300 worms may produce severe disease. *O. radiatum* can cause acute clinical signs in cattle as a result of massive invasion of the gut by infective larvae (12). Immature *Chabertia ovina* in sheep and goats have been associated with colon congestion (14) and the adults with haemorrhagic colitis (10). Kotlán (11) reported that massive doses of larvae of *Oesophagostomum dentatum* resulted in a necrotizing enteritis in piglets attributed to activation of facultative pathogens of the intestinal flora. Nickels and Haupt (13) reported similar results in piglets infected with massive doses of *O. quadrispinulatum*; worms apparently activated an acute or chronic salmonellosis.

The number of larvae required to produce a necrotizing colitis and peritonitis has not been sufficiently explored. One kid given only 50 larvae did not develop signs of colitis and peritonitis but 200 larvae produced the same clinical pattern as 600 larvae. Unfortunately, various kids used in the experiments were not the same age and most were probably unrelated. Nevertheless, the similarity in the results was striking. One kid which survived an oral dose of 1000 larvae was older than kids used in earlier experiments; however, clinical signs and adhesions near the ileo-caecal valve suggested that a localized peritonitis had developed.

The production of neurologic disease in two kids which survived the gut phase of the infection indicates that larvae, once they have entered the peritoneal cavity, behave as in deer in that they migrate to the spinal cord and enter the dorsal horns of grey matter (6). Data in Table II illustrate the importance of the dorsal horns of grey matter in infections in kids and suggest that kids are highly susceptible to neural invasion by *P. tenuis* (one kid received only 50 larvae and yet cross-sections of worms were found in 18 places in the spinal cord). Significantly some worms had completed their development in the neural parenchyma and reached the subarachnoid and subdural spaces. There is no evidence that *P. tenuis* will develop to this extent in sheep which seem rather resistant (5). The number, type, and position of lesions observed in the central nervous system are similar to those found in infected cervids other than white-tailed deer.

ACKNOWLEDGMENTS

We are most grateful for the technical and editorial advice of Dr. A. A. van Dreumel, Dr. T. Wilson, Dr. P. Stockdale, Prof. T. J. Hulland and Prof. R. Thomson of the Department of Pathology, Dr. Joan Budd and Prof. L. H. A. Karstad of the Department of Avian Pathology, Wildlife Diseases, and Virology, and Dr. R. A. Wiloughby of the Department of Clinical Studies, of the Ontario Veterinary College. Prof. M. A. Soltys of the Department of Veterinary Microbiology of O. V. C. kindly carried out the bacteriological examinations. This work was supported by an operating grant from the National Research Council and by a grant from the Canadian National Sportsman's Show.

REFERENCES

- ANDERSON, R. C. Neurologic disease in moose infected experimentally with *Pneumostrongylus tenuis* from white-tailed deer. *Pathologia vet.* 1: 289-322, 1964.
- ANDERSON, R. C. The development of *Pneumostrongylus tenuis* in the central nervous system of white-tailed deer. *Pathologia vet.* 2: 360-376, 1965.
- ANDERSON, R. C., M. W. LANKESTER and U. R. STRELIVE. Further experimental studies of *Pneumostrongylus tenuis* in cervids. *Can. J. Zool.* 44: 851-861, 1966.
- ANDERSON, R. C. and U. R. STRELIVE. The transmission of *Pneumostrongylus tenuis* to guinea pigs. *Can. J. Zool.* 44: 533-540, 1966.
- ANDERSON, R. C. and U. R. STRELIVE. Experimental cerebrospinal nematodiasis (*Pneumostrongylus tenuis*) in sheep. *Can. J. Zool.* 44: 889-894, 1966.
- ANDERSON, R. C. and U. R. STRELIVE. The penetration of *Pneumostrongylus tenuis* into the tissues of white-tailed deer. *Can. J. Zool.* 45: 285-289, 1967.
- ANDERSON, R. C. and U. R. STRELIVE. The experimental transmission of *Pneumostrongylus tenuis* to caribou (*Rangifer tarandus terraenovae*). *Can. J. Zool.* 46: 503-510, 1968.
- FOURIE, P. J. J. A contribution to the study of the pathology of oesophagostomiasis in sheep. *Onderstepoort J. vet. Sc. animal Indust.* 7: 277-347, 1936.
- GORDON, H. McL. Some aspects of parasitic gastroenteritis of sheep. *Aust. vet. J.* 26: 14-28, 46-52, 65-72, 93-98, 1950.
- GORDON, H. McL. and N. P. H. GRAHAM. A few cases of infestation with *Chabertia ovina*. *Aust. vet. J.* 9: 198-199, 1933.
- KOTLÁN, A. Über die Rolle von Darmnematoden beim Zustandekommen bakterieller Infektionen nebst Bemerkungen über die Pathogenität von *Oesophagostomum dentatum*. *Wien. tierärztl. Mschr.* 43: 658-664, 1956.
- MAYHEW, R. L. Studies on bovine gastrointestinal parasites. X. The effects of nodular worm (*Oesophagostomum radiatum*) on calves during the prepatent period. *Am. J. vet. Res.* 9: 30-34, 1948.
- NICKEL, E. A. and W. HAUPT. Verlauf und Auswirkungen experimenteller Knöthenwurminvasionen bei Schweinen. *Berl. Münch. tierärztl. Wschr.* 77: 193-197, 1964.
- ROSS, I. C. and G. KAUZAL. Preliminary note on the pathogenic importance of *Chabertia ovina* (Fabricius, 1788). *Aust. vet. J.* 9: 215-218, 1933.
- SPRATT, D. M. and R. C. ANDERSON. The guinea pig as an experimental host of the meningeal worm (*Pneumostrongylus tenuis* Dougherty). *J. Helminth.* 42: 139-156, 1968.