
NOTES

Pox in South American Sea Lions (*Otaria byronia*)

T. M. Wilson and I. Poglayen-Neuwall*

RÉSUMÉ

Deux otaries, *Otaria byronia*, importées de l'Amérique du Sud, présentaient plusieurs nodules cutanés à leur arrivée aux États-Unis. L'examen histologique de ces nodules a révélé que le derme était infiltré par une masse de cellules épithéliales en prolifération. De grosses inclusions acidophiles intracytoplasmiques étaient visibles dans les cellules de cette masse. L'examen de ces inclusions, à l'aide d'un microscope électronique, a démontré le virion du virus de la variole, à la forme caractéristique d'haltère. On a observé une ressemblance entre la condition présente et une maladie cutanée de l'homme due à un virus variolique, l'acné varioliforme.

An epizootic of a proliferative skin disease in captive California sea lions, *Zalophus californianus*, which included the electromicroscopic demonstration of dumbbell-shaped poxvirus virions in the lesions was reported in 1969 (7). Morphological studies of this seal poxvirus, employing negative stained preparations, revealed mulberry

forms (M) and capsular forms (C). The orderly pattern of the surface filaments and the size and shape of the M form revealed a similarity to Orf virus (Contagious Pustular Dermatitis) and Bovine Papular Stomatitis virus (8). In December 1969, an international mail survey was made of aquariums and veterinarians working with pinnipeds, requesting skin specimens and information concerning the incidence of seal pox in free living and captive pinnipeds. Data (9) from this survey has revealed that pox occurs in captive California sea lions, free living California sea lions, free living Harbor seals and South American sea lions. The present paper is an account of the clinical and pathological features of seal pox in two South American sea lions investigated during the course of this survey.

Two South American sea lions, one male and one female each weighing about 35 pounds and approximately six months of age were obtained from South American rookeries through a dealer in the Netherlands. Both seals exhibited skin nodules upon arrival in the Netherlands from Peru, South America. The animals, which had been in captivity in the Netherlands for about four weeks prior to shipment to the United States, arrived in poor condition and immediate examination revealed numerous nonulcerated cutaneous nodules. The nodules were firm, partially covered with hair, less than five mm in diameter and

*Department of Pathology, Ontario Veterinary College, University of Guelph, Guelph, Ontario, Canada (Wilson) and Louisville Zoological Garden, Louisville, Kentucky, U.S.A. (Poglayen-Neuwall).

This work was supported by the Medical Research Council of Canada, Grant No. MA 3998.

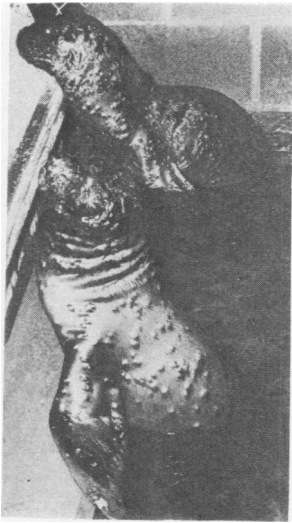

Fig. 1. Two juvenile South American sea lions exhibiting multiple cutaneous nodules.

irregularly distributed over the entire body surface. Within the next ten to 14 days similar nodular lesions rapidly erupted over the entire body surface, including the flippers, and consisted of solitary umbilicated and nonumbilicated lesions approximately one to two cm in diameter. Occasionally lesions were confluent. At the height of the clinical disease, the body of each animal was covered by several hundred nodules (Fig. 1, 2). Dehiscence of most nodules followed this clinical peak which resulted in a generalized pustulosis. These skin lesions healed during the next one to two weeks and were represented by areas of alopecia and shortened hair. Both animals died after a one month illness characterized by multiple skin nodules, anorexia, listlessness and light grey feces. During the course of their illness, treatment included topical ointments and parenteral antibiotics. Roccal¹ at a rate of nine ppm and granulated salt in the quantity of 100 lbs per 340 gallons of water were added to the seal tank water in an unsuccessful attempt to control the skin lesions.

Necropsy examination of both sea lions revealed enteritis to be the cause of death. The majority of skin nodules had regressed at the time the animals died; however, some skin nodules were present. *Salmonella saint-paul* was cultured from the intestine of the male sea lion while *Staphylococcus* sp. and *Streptococcus* sp. were isolated from the skin lesions of this same sea lion.

¹Roccal, National Laboratory, Montvale, N.J.

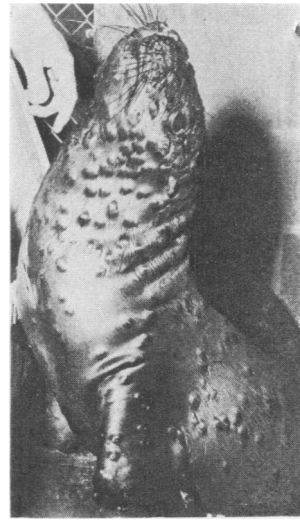


Fig. 2. Photograph of a male South American sea lion illustrating closer view of multiple skin nodules.

Histological examination of formalin fixed hematoxylin and eosin stained slides of skin nodules revealed the dermis to be infiltrated by a downward proliferative mass of epithelial cells. This dermal epithelial mass, which was well demarcated from the surrounding dermis, had a depression in the center with cords of epithelial cells radiating peripherally (Fig. 3). This central depression was in part due to tissue loss during processing. The layer of cells which formed these epithelial cords were morphologically similar to the germinal and spinosum layers of the normal epidermis.

Some basal cells which may have been infected were large and contained large nuclei and large, distinct basophilic nucleoli. Occasionally small eosinophilic and basophilic intracytoplasmic inclusion bodies were observed in basal cells and cells

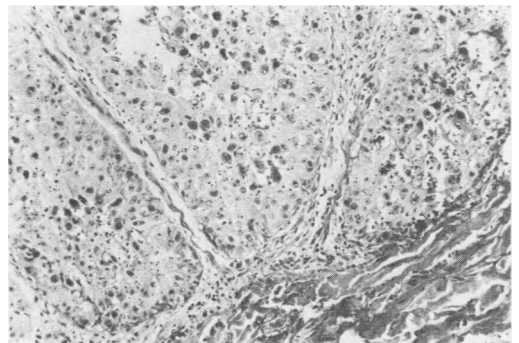


Fig. 3. Several well demarcated epithelial cords radiating from the penetrating dermal mass. H.E. X60.

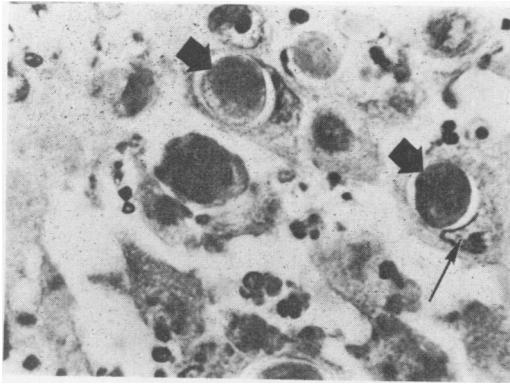


Fig. 4. Large intracytoplasmic inclusions (large arrows) in epithelial cells of the cords. Note displaced nucleus (small arrow). H. E. X360.

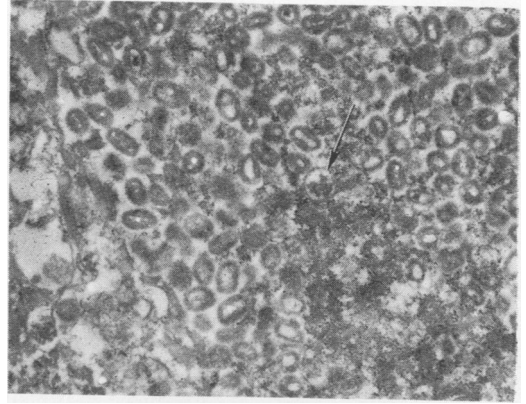


Fig. 5. Masses of mature pox virions. Note immature spherical viral form (arrow). X19,400.

immediately adjacent to the basal cell layer. Cells located in the spinosum layer of these cords contained large vesicular nuclei and distinct basophilic nucleoli. Many of these cells contained small and large eosinophilic intracytoplasmic inclusions. Most epithelial cells located superficially in these cords contained large eosinophilic and basophilic intracytoplasmic inclusions which markedly displaced the nucleus peripherally. Detritus, which included inclusion bodies and a slight mixed inflammatory cell reaction, was present along the surface of these epithelial cords. There was no significant dermal reaction to the downward growth of epithelial cells other than compression of the subcutis.

The intracytoplasmic inclusion bodies observed were usually eosinophilic although both large and small basophilic inclusions were occasionally observed. Some inclusion bodies appeared to maintain intimate contact with the surrounding cytoplasm; however, the majority were located in a distinct cytoplasmic cavity (Fig. 4). A refractile wall or envelope appeared to be present surrounding many of the larger intracytoplasmic inclusions. These homogeneous intracytoplasmic inclusions, generally one to a cell, were circular or oval, and ranged from approximately 10 to 26 microns in diameter and often appeared hyalinized.

A skin nodule fixed in formalin and embedded in paraffin was prepared for electronmicroscopic examination, with a slight modification, according to the technique of Morecki and Becker (3). Twenty micron thick sections, as suggested in that procedure, were cut but proved too thin and fragile for proper epoxy resin embedding.

After localization of the lesion in the paraffin block a small 2 x 2 mm cube was excised and prepared for embedding. This small cube was rinsed in xylene to remove the paraffin then dehydrated, embedded in epon, sectioned, stained with lead hydroxide and examined with a Philips electron microscope model 200.

Due to the method of tissue fixation and preparation prior to electron microscope examination no attempt was made to undertake an ultrastructure study of the skin but rather an attempt was made to confirm the morphology of the large intracytoplasmic inclusion bodies. Under the electron microscope these inclusion bodies were composed of masses of densely packed mature poxvirus virions with the occasional immature spherical viral form distributed throughout the inclusions. Loose and dense aggregates of an electron dense fine granular material were interspersed throughout the inclusion. The mature pox virion appeared rectangular. Its fine structure consisted of a dumbbell-shaped central core surrounded by a membrane and compressed between two lateral bodies; the outer portion of the virion consisted of a complex envelope (Fig. 5). Measurements of apparently undistorted mature virions indicated an approximate length of 250 mu and a width of 200 mu.

Poxviruses have been reported in vertebrate (6) and invertebrate hosts (1, 5) and depending on the strain and virulence of the poxvirus, variable gross and histological lesions may develop. Information (9) presently compiled from a field and aquarium survey for seal pox indicates that the cutaneous nodules associated with seal pox invariably consist of hypertrophied and

hyperplastic epithelial cells. These cells are generally confined to the stratum spinosum and granulosum and their apparent direction of proliferation is toward the skin surface. Hyperkeratosis and parakeratosis are evident in variable degrees.

The eosinophilic intracytoplasmic inclusion bodies associated with seal pox are variable in size and shape. One or several inclusions may be present in a single cell and the size of the inclusions varied from two to 10 microns in diameter. A consistent feature of these inclusions is their irregular shape. The mature poxvirus virions examined in all cases of seal pox consistently appeared elongated and cylindrical with the typical poxvirus morphology.

This case report of seal pox differs markedly from all other cases of seal pox examined. While the usual cutaneous lesions of seal pox appear to proliferate outward, the lesion in this report is a distinctive downward proliferative mass. The intracytoplasmic inclusion bodies in this case report are very large, distinctly oval or circular and occur one to a cell while the inclusions in other cases of seal pox are much smaller, very irregular in shape and may occur several to a cell. The virion in this case report appears rectangular while the virions observed in all other cases of seal pox appear cylindrical and elongated (7, 9).

An apparent similarity between this case report of seal pox and *Molluscum Contagiosum* of humans is evident. *Molluscum Contagiosum* is a contagious skin disease of humans of worldwide distribution caused by a poxvirus and characterized by single or multiple umbilicated cutaneous nodules which may occur anywhere on the body (4). The skin lesions, approximately two to five mm in diameter, are most common in children and have a variable clinical course ranging from weeks to months. The histological lesions are most characteristic and consist of downward proliferating epithelial lobules that are well demarcated from the dermis (2). Epithelial cells located in these lobules contain the characteristic Henderson-Patterson intracytoplasmic inclusion bodies which are usually eosinophilic, very large, ranging from nine to 37 microns and located in a distinct cytoplasmic cavity (10). Electronmicroscopic studies (4) have demonstrated the characteristic brick shaped poxvirus virion in these inclusions and have shown the mature virion to be rectangular in shape and between 288 x 230 mu. According to Wilner (6) the

poxvirus of *Molluscum Contagiosum* is presently ungrouped in the poxvirus subgroups.

The similarities in this case of seal pox in South American sea lions and *Molluscum Contagiosum* are the multiple umbilicated cutaneous lesions, the downward proliferating mass of epithelial cords, the large distinct eosinophilic and basophilic intracytoplasmic inclusion bodies and the rectangular shape of the mature poxvirus virion. It is presently not possible to draw confident conclusions concerning the morphology and size of the mature virion in this case due to treatment prior to electronmicroscopic examination. More extensive studies, employing properly preserved tissue, must be carried out on this poxvirus disease of South American sea lions before conclusive information can be obtained.

ACKNOWLEDGMENTS

Assistance in obtaining specimens and advice in preparation of this case report were generously given by Dr. H. J. Olander, Department of Pathology, School of Veterinary Science and Medicine, Purdue University, Lafayette, Indiana and Dr. A. D. Boothe, National Animal Disease Laboratory, Ames, Iowa.

REFERENCES

1. GRANADOS, R. R. and D. W. ROBERTS. Electron microscopy of a poxlike virus infecting an invertebrate host. *Virology* 40: 230-243. 1970.
2. MONTGOMERY, H. *Dermatopathology*. Volume 1. New York: Harper and Row Publishers. 1967.
3. MORECKI, R. and N. H. BECKER. Human herpesvirus infection. *Archs Path.* 86: 292-296. 1968.
4. POSTLETHWAITE, R. *Molluscum contagiosum*. *Archs envir. Hlth* 21: 432-452. 1970.
5. WEISER, J. A pox-like virus in the midge, *Campochironomus tentans*. *Acta virol.* 13: 549-553. 1969.
6. WILNER, B. I. *A Classification of the Major Groups of Human and Other Animal Viruses*. Minneapolis, Minn.: Burgess Publishing. 1969.
7. WILSON, T. M., N. F. CHEVILLE and L. KARSTAD. Seal pox. *Bull. Wildl. Dis. Ass.* 5: 412-418. 1969.
8. WILSON, T. M. and P. R. SWEENEY. Morphological studies of seal poxvirus. *J. Wildl. Dis.* 6: 94-97. 1970.
9. WILSON, T. M. Unpublished data. 1970.
10. VAN ROOYEN, C. E. The micromanipulation and microdissection of the molluscum contagiosum inclusion body. *J. Path. Bact.* 46: 425-436. 1938.