

A Case of Viral Neonatal Calf Diarrhea in a Quebec Dairy Herd

M. Morin, P. Lamothe, A. Gagnon and R. Malo*

ABSTRACT

This report is concerned with a consistent problem of neonatal calf diarrhea (NCD) in a dairy herd in which, for nearly two years, the morbidity had approached 100% and the mortality had varied from 20% to 45%. Generally, diarrhea appeared at three days of age. By the fluorescent antibody tissue section technique the two Nebraska NCD viruses (reo-like and corona-like) were detected in the cytoplasm of many absorptive cells of the small intestine from a calf submitted for necropsy. Reo-like virus antigen was not detected in the absorptive and crypt cells of the colon but coronavirus-like antigen was. An adenovirus was also isolated from the small intestine of this calf. The disease was reproduced experimentally in a two day old colostrum deprived calf with a bacteria free intestinal homogenate obtained from the naturally infected calf. Both Nebraska NCD viruses were demonstrated in this experimental animal. However, the adenovirus was not re-isolated. Histological lesions observed in the small and large intestines of the naturally and experimentally infected calves were similar and because of their good correlation with the immunofluorescent findings, a combination of the two Nebraska NCD viruses was thought to be a major cause of the neonatal calf diarrhea problem afflicting this dairy herd.

RÉSUMÉ

Ce travail visait à étudier un problème de diarrhée néo-natale qui persistait, depuis environ deux ans, dans un troupeau de bovins laitiers et qui se traduisait par une morbidité de presque 100%, ainsi que par une mortalité d'environ 20 à 45%. La diarrhée débutait généralement chez les veaux âgés de trois jours. L'immunofluorescence permit de déceler la présence des deux virus de la diarrhée néo-natale isolés au Nebraska (les virus reo et corona), dans le cytoplasme de plusieurs cellules absorbantes de l'intestin grêle d'un veau référé pour nécropsie. On ne décéla pas la présence du virus reo dans les cellules absorbantes du côlon, mais on y retrouva le virus corona. On isola aussi un adénovirus de l'intestin grêle de ce veau. On reproduisit la maladie chez un veau âgé de deux jours qui n'avait pas ingéré de colostrum; à cette fin, on utilisa une émulsion exempte de bactéries de l'intestin du veau ayant souffert de l'infection naturelle. On démontra la présence des deux virus du Nebraska chez ce veau expérimental, mais non celle de l'adénovirus. Les lésions histologiques de l'intestin grêle et du côlon du veau expérimental et de celui qui avait souffert de l'infection naturelle s'avèrent semblables. A cause de leur corrélation avec les résultats de l'immunofluorescence, on en vint à la conclusion que l'association des deux virus du Nebraska constituait la principale cause du problème de diarrhée néo-natale qui sévissait dans ce troupeau.

INTRODUCTION

Neonatal calf diarrhea (NCD) has been extensively investigated since it is known to be a major health problem in young calves (11, 14). For several years *Escherichia coli* was considered to be the main cause of NCD (7). Other agents including

*Département de Pathologie et Microbiologie (Morin) et de Médecine (Lamothe), École de Médecine vétérinaire, Université de Montréal, C.P. 5000, Saint-Hyacinthe, Québec J2S 7C6, Institut de Microbiologie et d'Hygiène de Montréal, C.P. 100, Laval-des-Rapides, Québec H7N 4Z3 (Gagnon) et Laboratoire de Pathologie Animale, Ministère de l'Agriculture du Québec, C.P. 5000, Saint-Hyacinthe, Québec J2S 7C6 (Malo).

Submitted September 17, 1973.

chlamydia (13, 15) and viruses such as bovine viral diarrhoea virus (1), infectious bovine rhinotracheitis virus (12), adenoviruses (3, 4), parvoviruses (16) and enteroviruses (16) were also suggested as possible causes of the disease. Recently two viruses were isolated from cases of NCD on Nebraska ranches (6, 7, 8, 10). The first one was a reo-like virus which induced diarrhoea generally within the first 96 hours of life (5, 7, 10). Incubation period was very short (13 or 14 hours) and the diarrhoea was characterized by yellow and liquid feces. In uncomplicated cases or when gnotobiotic calves were infected with the virus recovery usually occurred within 24 hours after the onset of diarrhoea (7). The second virus isolated was a coronavirus-like agent which was reported to infect calves between five days and six weeks of age (7, 8, 9, 10). Gnotobiotic calves infected experimentally with this virus suffered a diarrhoea, which persisted for several days, and finally died (7).

The purpose of this report is to describe clinical observations, gross and microscopic lesions, virological and immunofluorescence observations on a case of neonatal calf diarrhoea in a dairy herd where a combination of the two Nebraska viruses was thought to be a major cause of the problem and to describe the experimental reproduction of the disease.

MATERIALS AND METHODS

ANIMALS

Two years ago a Holstein breeder experienced problems with calf diarrhoea but strict observation of a herd health program and antibiotic therapy satisfactorily improved the condition. Six months later the farmer complained that calves, born and raised on pasture, presented acute enteric problems during their first week of life. Morbidity reached almost 100% and mortality 45%, although preventive and therapeutic treatments were undertaken. Several survivors manifested rough coat, chronic enteritis and slow growth. Since that time this diarrhoea has been a consistent problem in the calves born in this herd with a morbidity rate nearing 100% and a mortality rate varying from 20 to 40%. Generally

diarrhoea appeared at three days of age. The first sign was a small thread of blood on the surface of nearly normal feces. This was followed by a watery yellowish diarrhoea which severely dehydrated the calf within 24 hours. Antidiarrhoeic therapy prevented the appearance of diarrhoea within the first week of life in some calves but most of them suffered from diarrhoea at the second week of age. Mortality at this age was low but calves remained thin with rough coat and chronic enteritis for a prolonged period. Necropsies had been performed on some of these calves and a nonhemolytic *E. coli* strain resistant to all common antibacterial agents except the nitrofurans and chlorexidine had been isolated from their small intestines.

In the present study a four day old calf from this dairy herd was presented alive for necropsy, 24 hours after the beginning of profuse, watery and yellow diarrhoea. A two day old colostrum deprived calf was used in an attempt to reproduce the disease with a bacteria free intestinal homogenate obtained from the naturally infected calf and was necropsied 24 hours after the onset of diarrhoea.

NECROPSY

Calves were electrocuted and exsanguinated. The abdominal cavity was opened immediately and specimens were collected from the upper, middle, lower jejunum and colon. They were fixed in 10% neutral buffered formalin and processed for paraffin tissue sections according to conventional methods. Sections 6.0 μ thick were stained with hematoxylin, phloxin and safran (HPS) (2). Intestinal specimens obtained immediately adjacent to those saved for histopathology were frozen rapidly at -40°C for immunofluorescence studies. Specimens from the upper, middle and lower jejunum were submitted for aerobic (blood, MacConkey's, SS agar plates and selenite broth) and anaerobic cultures. Gram stained direct smears of mucosal scrapings from these specimens were used to evaluate their bacterial population.

FLUORESCENT ANTIBODY TECHNIQUE

The fluorescent antibody tissue section technique (FAT) was used to search for the reo-like virus and the coronavirus-like agent. The two conjugates specific for these

viruses were obtained commercially¹. Pieces of jejunum and colon were embedded with OCT embedding medium² on the cryostat specimen holder and the gut samples were oriented to obtain longitudinal sections of the villi. Sections were cut 8.0 μ in a cryostat at -30°C . The slides obtained were allowed to dry for ten to 15 minutes at 37°C and were fixed in acetone at room temperature for 15 minutes. After fixation they were dried for five minutes at 37°C , flooded with conjugate and incubated in a moist chamber at room temperature for 30 minutes. These slides were subsequently washed through three changes (two minutes each) of a carbonate-bicarbonate buffered saline solution pH 9.0 (17). The slides were allowed to dry and a coverslip was mounted on the sections with buffered glycerin (one part of glycerin to nine parts of carbonate-bicarbonate buffered saline, pH 9.0). Specificity of the fluorescence produced by the conjugates was tested in the following manner: frozen sections from the small intestine and colon of newborn calves without signs of enteric disorders, when stained with the fluorescent antibody preparations, failed to show fluorescence similar to that seen in the naturally and experimentally infected calves of the study reported herein. Intestinal sections from the infected calves were stained with anti-transmissible gastroenteritis conjugate. Fluorescence similar to that produced by the conjugates specific for the Nebraska NCD viruses was not observed. Fecal smears were made from diarrheic feces obtained from another calf in the herd within five hours after the beginning of diarrhea. These smears were used for detection of reo-like virus by immunofluorescence and the staining procedure was the same as that described for the intestinal sections.

EXPERIMENTAL REPRODUCTION OF THE DISEASE

A 20% intestinal homogenate in phosphate buffered saline (PBS) was prepared from jejunal segments and their content obtained from the naturally infected calf submitted for necropsy. This homogenate was centrifuged at 10,000 RPM for 30 minutes. The supernatant fluid obtained

was passed through a 0.45 μ grid membrane³ and tested for the absence of bacteria. Calf testis cell cultures were used to search for IBR, BVD viruses and adenoviruses. Ten ml of this supernatant fluid were given orally to a two day old colostrum deprived calf.

RESULTS

CLINICAL SIGNS EXHIBITED BY THE EXPERIMENTALLY INFECTED CALF

At 30 hours postinoculation small threads of blood were seen on the surface of normal feces from the experimentally infected calf and six hours later diarrhea occurred. Dehydration was very severe 24 hours after the onset of diarrhea. Rectal temperature reached 103.8.

³Nalgene Filter Unit. Nalge Sybron Corporation, Rochester, N.Y. 14602.

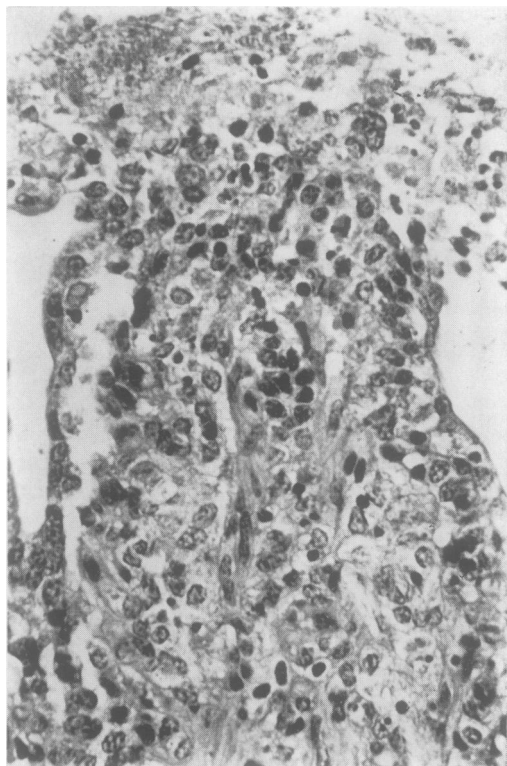


Fig. 1. Section from the middle jejunum of the naturally infected calf. Epithelial cells covering the upper part of this villus are undergoing degeneration and desquamation. HPS X240.

¹Reovirus Conjugate and Coronavirus Conjugate. Norden Laboratories, Lincoln, Nebr. 68501.

²Tissue-Tek, Ames Co., Elkhart, Indiana.

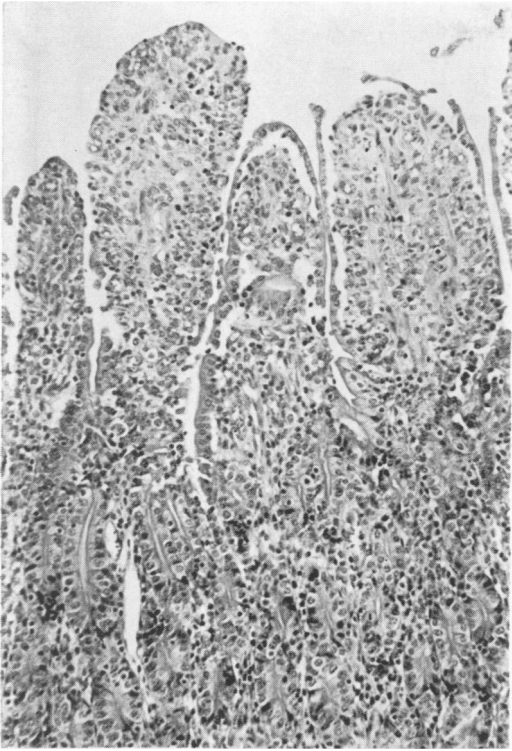


Fig. 2. Section from the upper jejunum of the naturally infected calf. Notice villi more or less denuded and more blunt than normal. One villus is completely covered by cuboidal epithelial cells. HPS X100.

GROSS LESIONS

The naturally infected calf presented for necropsy was very dehydrated. The small intestine, cecum, colon and rectum were distended by a watery, yellow content. Milk curd was also present. In the lower jejunum and ileum there was a large amount of mucosal debris free in the intestinal content and there were whitish membranes attached to several areas of the intestinal mucosa in these regions. Gross lesions were not seen in other organs.

Macroscopic lesions similar to those described above were observed in the experimentally infected calf. However, the amount of mucosal debris in the lower jejunum and ileum was smaller and whitish membranes were not observed.

HISTOPATHOLOGICAL AND IMMUNO-FLUORESCENCE STUDIES

In the upper and middle jejunum of the naturally infected calf several villi were

more blunt than normal and covered by vacuolated low columnar epithelial cells. In several areas of the same segments the columnar absorptive cells were undergoing desquamation (Fig. 1) and the upper half or the tip of several villi was completely denuded (Fig. 2). Several other villi were also blunt and the epithelial cells covering them were cuboidal in shape and had a poorly developed brush border (Figs. 2 and 3). Several of these villi were moderately shorter than normal and in both denuded and non denuded villi there was an increase in the number of reticulum cells in their lamina propria. In the lower jejunum and ileum there were large numbers of desquamated cells in the lumen. Intestinal villi were very atrophic and lined by cuboidal or squamous epithelial cells (Fig. 4). In some areas of the colon, absorptive cells were undergoing degeneration and desquamation, whereas in other areas these cells were cuboidal in shape rather than columnar.

By the FAT reo-like virus antigen (Fig.

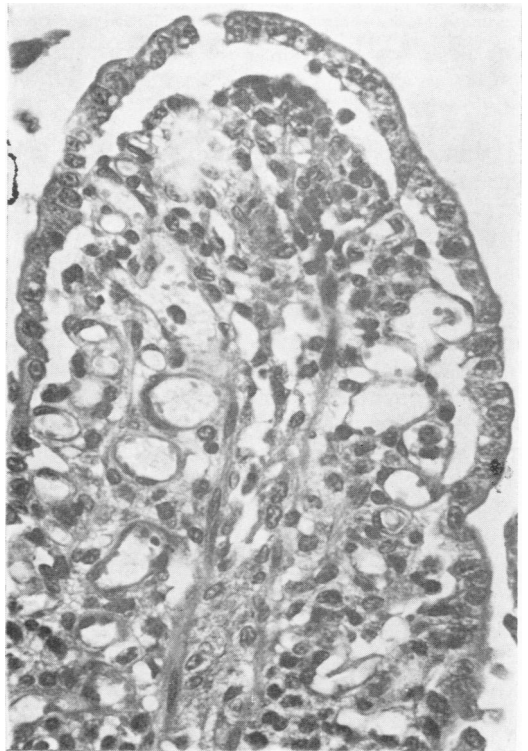


Fig. 3. Section from the middle jejunum of the naturally infected calf. This villus is more blunt than normal and covered by cuboidal epithelial cells. HPS X240.

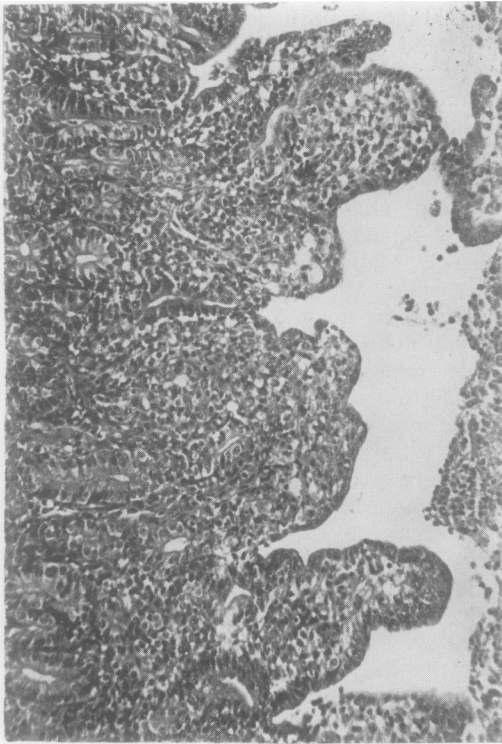


Fig. 4. Section from the lower jejunum of the naturally infected calf. There is a severe villous atrophy and replacement of the columnar absorptive cells by squamous or cuboidal epithelial cells. Notice the large number of desquamated cells in the intestinal lumen. HPS X100.

5) and coronavirus-like antigen (Fig. 6) were detected in the cytoplasm of many absorptive cells in all segments of the small intestine examined but were not detected in the epithelial cells lining the crypts of Lieberkühn. Reo-like virus antigen was not detected in the colon samples examined, whereas the coronavirus-like antigen was demonstrated in the cytoplasm of absorptive and crypt cells in several areas of the same specimens (Fig. 7). Reo-like virus was demonstrated by immunofluorescence in the cytoplasm of numerous intestinal epithelial cells in smears from the fecal sample collected from another calf in the herd five hours after the onset of diarrhea. The coronavirus was not demonstrated with this method.

Histopathological and immunofluorescence observations on the experimentally infected calf necropsied 24 hours after the beginning of diarrhea were similar to those made on the naturally infected calf. However, severe lesions of villous atrophy like those observed in the lower small intestine

of the naturally infected calf were not observed.

BACTERIOLOGICAL STUDIES

Gram stained direct smears from the upper, middle and lower jejunum of the naturally and experimentally infected calves revealed a very poor bacterial flora. A small number of nonhemolytic *E. coli* was isolated from the jejunum of both calves. Anaerobic cultures gave negative results.

TISSUE CULTURE STUDIES FOR DETECTION OF IBR, BVD VIRUSES AND ADENOVIRUSES

An adenovirus was isolated from the intestinal homogenate obtained from the naturally infected calf. However, this virus was not reisolated from the intestinal tract of the experimentally infected calf.

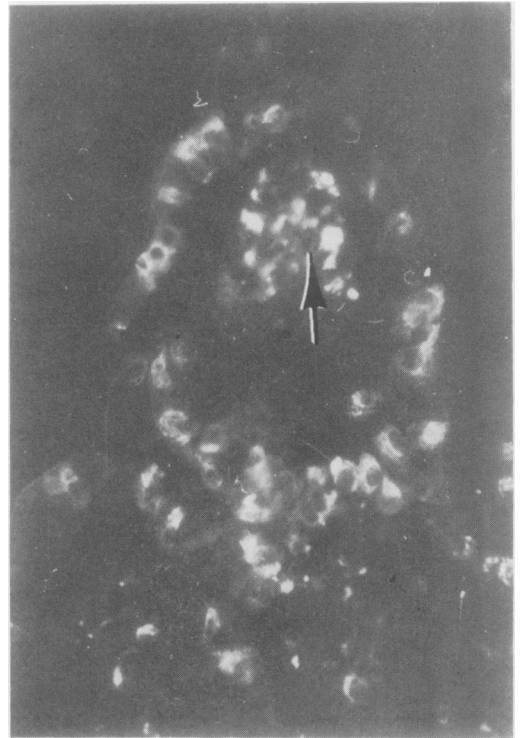


Fig. 5. Fluorescent antibody stained section from the middle jejunum of the naturally infected calf. Notice the number of absorptive cells with reo-like virus antigen in their cytoplasm. Eosinophils present in the lamina propria produce a bright nonspecific fluorescence (arrow). X150.

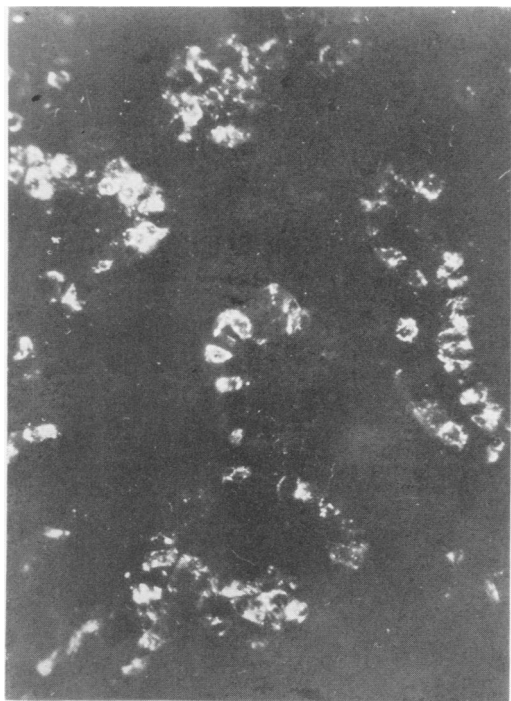


Fig. 6. Fluorescent antibody stained section from the middle jejunum of the naturally infected calf. Notice the large numbers of absorptive cells on the villi with coronavirus-like antigen in their cytoplasm. X150.

DISCUSSION

In the NCD problem reported in this paper the two Nebraska NCD viruses and an adenovirus were demonstrated. The disease was reproduced experimentally in a colostrum deprived calf fed with a bacteria free filtrate from the small intestine of the naturally infected calf. Both Nebraska NCD viruses and lesions similar to those observed in the naturally infected calf were demonstrated in this experimental animal. However, the adenovirus was not reisolated.

It has been reported that the reo-like virus and the coronavirus-like agent infect the columnar absorptive cells of the small intestine and cause their degeneration and desquamation (5, 7, 9, 10). The coronavirus-like agent also infects the absorptive and crypt cells of the colon (7, 9, 10). The infected cells are replaced by cuboidal epithelial cells which are just derived from the crypts of Lieberkühn. Lesions caused by the coronavirus-like agent were reported to be more severe and persistent than those caused by the reovirus (7). Because of the

presence of a severe infection by the two viruses in the NCD problem reported herein, as demonstrated by the FAT, large numbers of columnar absorptive cells in the small and large intestine were undergoing degeneration and desquamation, several villi were denuded, while several others were covered by cuboidal cells with a poorly developed brush border. These extensive damages to the digestive absorptive surface of the small intestine and the absorptive surface of the colon were responsible for the severe diarrhea and dehydration suffered by calves in this herd.

While it is felt that the Nebraska NCD viruses were the major etiological agents in this case, the possible participation of other infectious agents has not been ruled out. The significance of the adenovirus isolated from the intestinal tract of the naturally infected calf is not known. Adenovirus infection in calves is usually a respiratory disease which can be accompanied by diarrhea (3, 4). Calves in the herd under study

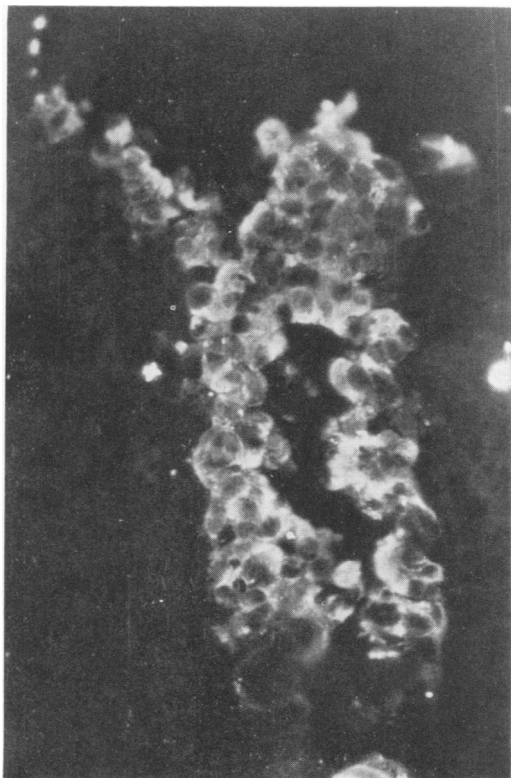


Fig. 7. Fluorescent antibody stained section from the colon of the naturally infected calf. Notice the large numbers of absorptive and crypt cells with coronavirus-like antigen in their cytoplasm. X200.

didn't have any respiratory problems and it is well known that adenovirus infection is rarely observed in calves less than one week old (3). Some strains of this virus have been isolated from apparently healthy animals (3, 4). Parvoviruses have been isolated from fecal samples of calves affected with an enteric disease (16). This virus was not searched for in the present case. It is well established that chlamydial agents infect the intestinal tract of clinically normal cattle (13). In some experimentally infected young calves diarrhea has occurred (15). BVD virus was not isolated with the cell culture system used. However, the possible presence of a noncytopathic strain of the virus has not been ruled out.

This case report emphasizes how complex the etiology of NCD can be. In order to demonstrate the presence or absence of the Nebraska viruses in a case of NCD the fluorescent antibody technique would seem to be the best method when specific conjugates can be obtained. Histological lesions in the mucosa of the small intestine and colon could be of some help to suggest the presence of one or both Nebraska viruses. However, this has to be confirmed by the FAT, as mentioned earlier or by electron microscopy examinations (10). It is important to remember that microscopic lesions similar to those described in this paper could be induced by other injuries to the absorptive surface of the small and large intestine.

ACKNOWLEDGMENTS

The authors wish to thank le Ministère de l'Agriculture et de la Colonisation de la

Province de Québec for its financial assistance in this study.

REFERENCES

1. LAMBERT, G. and A. L. FERNELIUS. Bovine viral diarrhea virus and *Escherichia coli* in neonatal calf enteritis. *Can. J. comp. Med.* 32: 410-446. 1968.
2. LANGERON, M. Précis de microscopie. p. 638. Paris: Masson et Cie. 1943.
3. MATTSON, D. E. Naturally occurring infection of calves with a bovine adenovirus. *Am J. vet. Res.* 34: 623-629. 1973.
4. MATTSON, D. E. Adenovirus infection in cattle. *J. Am. vet. med. Ass.* 163: 894-896. 1973.
5. MEBUS, C. A., E. L. STAIR, N. R. UNDERDAHL and M. J. TWIEHAUS. Pathology of neonatal calf diarrhea induced by a reo-like virus. *Vet. Path.* 8: 490-505. 1971.
6. MEBUS, C. A., M. KONO, N. R. UNDERDAHL and M. J. TWIEHAUS. Cell culture propagation of neonatal calf diarrhea (Scours) virus. *Can. vet. J.* 12: 69-72. 1971.
7. MEBUS, C. A. Concepts of viral calf diarrhea. *Norden News.* 47, no 4: 5-7. 1972.
8. MEBUS, C. A., E. L. STAIR, M. R. RHODES and M. J. TWIEHAUS. Neonatal calf diarrhea: propagation, attenuation and characteristics of coronavirus-like agent. *Am. J. vet. Res.* 34: 145-150. 1973.
9. MEBUS, C. A., E. L. STAIR, M. B. RHODES and M. J. TWIEHAUS. Pathology of neonatal calf diarrhea induced by a coronavirus-like agent. *Vet. Path.* 10: 45-64. 1973.
10. NORDEN LABORATORIES, Lincoln, Nebraska. Laboratory Methods for detecting calf diarrhea viruses. 1973.
11. OXENDER, W. D., L. E. NEWMAN and D. A. MORROW. Factors influencing dairy calf mortality in Michigan. *J. Am. vet. med. Ass.* 162: 458-460. 1973.
12. RADOSTITS, O. M. Clinical management of neonatal diarrhea in calves with special references to pathogenesis and diagnosis. *J. Am. vet. med. Ass.* 147: 1367-1376. 1965.
13. SMITH, P. C., R. C. CUTLIP and L. A. PAGE. Pathogenicity of a strain of *Chlamydia psittaci* of bovine intestinal origin for neonatal calves. *Am. J. vet. Res.* 34: 615-618. 1973.
14. SPEICHER, J. A. and R. E. HEPP. Factors associated with calf mortality in Michigan dairy herds. *J. Am. vet. med. Ass.* 162: 463-466. 1973.
15. STORZ, J., A. K. EUGSTER, K. P. ALTERA and H. J. OLANDER. Behavior of different bovine chlamydial agents in newborn calves. *J. comp. Path.* 81: 299-307. 1971.
16. STORZ, J. and R. C. BATES. Parvovirus infections in calves. *J. Am. vet. med. Ass.* 163: 881-886. 1973.
17. U.S.D.A. DIAGNOSTIC SERVICES. National Animal Disease Laboratory, Ames, Iowa. Suggested components and procedures for utilizing the tissue culture fluorescent antibody technique (FA) in the diagnosis of hog cholera. 1965.