

# Porcine *Hemophilus parahemolyticus* Pneumonia in Saskatchewan

## II. Bacteriological and Experimental Studies

B. Schiefer and J. Greenfield\*

### ABSTRACT

The incidence of porcine pleuropneumonia caused by *Hemophilus parahemolyticus* has shown a marked increase in recent years in some countries. Isolation of a strain distinct from European serotypes was made from a natural outbreak of the disease in pigs in Saskatchewan. Experimentally infected pigs did not develop clinical signs but pathologic-anatomic studies of lungs revealed the presence of necrotizing fibrinous pneumonia with intense proliferation of mesenchymal tissue elements. Similar extensive fibroblastic activity had been found to be a typical feature in the natural infection. It is speculated that the Saskatchewan strain may have invasive patterns different from European serotypes.

### RÉSUMÉ

Les cas de pleuro-pneumonie porcine attribuables à *Hemophilus parahemolyticus* ont accusé une forte augmentation au cours des dernières années, dans certains pays. On a isolé une souche différente des sérotypes européens, lors de l'éruption de la maladie chez des porcs, en Saskatchewan. L'infection expérimentale de porcs ne provoqua pas l'apparition de signes cliniques; l'anatomie-pathologique de leurs poumons révéla cependant la présence d'une pneumonie fibrineuse et nécro-

sante qui s'accompagnait d'une prolifération intense d'éléments tissulaires mésenchymateux. Une activité fibroblastique intense similaire s'avéra typique de l'infection naturelle. Les auteurs présumant que la souche de la Saskatchewan posséderait un pouvoir d'invasion différent de celui des sérotypes européens.

### INTRODUCTION

Porcine pleuropneumonia attributed to *Hemophilus parahemolyticus* (or a synonym) has been described in Argentina, Canada, Denmark, Switzerland, the United Kingdom and the United States (2, 3, 4, 6, 8, 11, 13, 14) and the incidence has shown a very marked increase in recent years (10). Several workers have reproduced the disease in swine with apparent ease (2, 3, 4, 9, 11, 14).

This paper reports the characteristics of an *H. parahemolyticus* strain isolated from pigs with pleuropneumonia in Saskatchewan, Canada, and it describes an attempt to reproduce the disease in healthy pigs.

### MATERIALS AND METHODS

#### BACTERIOLOGY

Porcine lung tissue or pleural fluid was wiped over the entire surface of paired 5% sheep blood agar plates (BA) and the surface allowed to dry. Onto one of the two like plates a cross-streak of *Staphylococcus aureus* (SA) was applied. The SA produces

\*Department of Veterinary Pathology (Schiefer) and Veterinary Microbiology (Greenfield), Western College of Veterinary Medicine, University of Saskatchewan, Saskatoon, Saskatchewan S7N 0W0.

Present address of Dr. Greenfield: British Columbia Department of Agriculture, Veterinary Laboratory, P.O. Box 100, Abbotsford, B.C., Canada.

Submitted May 11, 1973.

excess amounts of diphosphopyridine-nucleotide (DPN, V factor) which diffuses into the agar adjacent to the streak. Plates were placed in an atmosphere of approximately 10% carbon dioxide (CO<sub>2</sub>). In addition, like plates were placed in an anaerobic jar in which an atmosphere of hydrogen and CO<sub>2</sub> was introduced using a Gaspak<sup>1</sup>. All cultures were incubated at 35°C.

Suspect *Hemophilus* colonies were subcultured on BA and trypticase soy agar (TSA) on which were placed small paper discs impregnated with V factor (5 µgm per ml) or culture was made on TSA into which V factor (4 µgm per ml) was incorporated (TSA-V). Isolates were inoculated into broth media recommended by Nielsen (9) into which was added V factor (4 µgm per ml).

The drug sensitivity of the isolates was tested by the *in vitro* disc method.

#### EXPERIMENTAL STUDIES

Seven three month old cross bred pigs were purchased. These had been raised under conventional conditions and except the serum samples inactivated at 50°C for for an occasional occurrence of atrophic rhinitis, the parent herd had been free from apparent respiratory disease for several years.

Blood was collected from each pig and

half an hour prior to being tested for *H. parahemolyticus* antibodies. A sterile 0.6 cm paper disc was dipped into a serum sample and placed on a TSA-V plate which was seeded with *H. parahemolyticus*. The plate was incubated at 35°C in 10% CO<sub>2</sub> for 24 hours and then observed for evidence of *Hemophilus*-inhibiting activity.

Each of four pigs was infected intranasally with 5 ml of a 24 hour broth culture containing approximately 10<sup>8</sup> *H. parahemolyticus* cells per ml. The bacterial population was estimated by inoculating TSA-V with separate calibrated drops (0.025 ml) from serial dilutions of the inoculation culture and after incubation the surface colonies were counted. One pig received 5 ml of sterile TSB only and it was housed with the infected pigs. In addition, one other pig was inoculated intranasally with 5 ml of culture which had been exposed to sonic dismembration for two minutes with an ultrasonic probe<sup>2</sup> and this animal was housed with a pig which was not treated.

All the pigs were permitted access *ad libitum* to water and to unmedicated pelleted commercial starter ration.

The animals were observed several times daily and carefully examined once each day at which time their temperatures were recorded. The pigs were euthanized at the termination of the study and a complete necropsy was performed.

<sup>1</sup>Gaspak, BioQuest, Cockeysville, Maryland.

<sup>2</sup>Biosonik, Bronwill Scientific, Rochester, New York.

TABLE I. Summary of Observations on Pigs Inoculated Intranasally with *Hemophilus parahemolyticus* (strain K17)

Identification	Inoculation	Euthanized (days post infection)	Typical Pathological Findings		Isolation of <i>H.</i> <i>parahemolyticus</i> from pulmo- nary Lesions
			Gross	Histological	
A. Infected group					
#502	<i>H. parahemolyticus</i>	9	+	+	+
#493	<i>H. parahemolyticus</i>	9	+	+	0
#497	<i>H. parahemolyticus</i>	9	+	+	0
#505	<i>H. parahemolyticus</i>	9	0	0	0
#519	Sterile culture medium (contact animal)	9	0	0	0
B. Sonification					
#513	<i>H. parahemolyticus</i> subjected to sonification <sup>a</sup>	12	+	+	+
C. Non-infected					
#491	None	12	0	0	0

<sup>a</sup>Ultrasonic dismembration procedure was not sufficient to sterilize the culture

## HISTOPATHOLOGY

Samples for histopathological studies were fixed in 10% neutral buffered formalin, embedded in paraffin, sectioned at 6  $\mu$ m and stained with hematoxylin and eosin (H & E) and Verhoeff-van Gieson.

## RESULTS

The bacteriological and pathological findings are summarized in Table I.

### CLINICAL OBSERVATIONS

One pig infected with *H. parahemolyticus* showed a mild increase in temperature and respiratory rate on the fourth day post-infection. No other animal showed any signs of respiratory disease.

### BACTERIOLOGY

After 24 hours incubation the culture plates which had been inoculated with lung or lymph node tissue from the infected group of pigs revealed scant growths of coli-forms, staphylococci and non-hemolytic streptococci in most cases. Typically altered lung tissue from one of the five infected pigs which was cultured on BA and TSA plates with a SA cross streak produced a heavy growth of small hemolytic colonies which grew close to the SA. This growth pattern resembled that of a V factor dependent *Hemophilus* sp. After 24 to 48 hours incubation the *Hemophilus*-like colonies were about 1 mm in diameter close to the SA, pin-point in size 1 cm from the SA, and none was visible 1.5 cm or more from the streak. Similar colonies were isolated from lung lesions from the pig inoculated with a sonicated *H. parahemolyticus* culture but none was isolated from the untreated negative control animal.

Culture of necrotic pulmonary tissue from a second pig in the infected group yielded a very heavy growth of diverse aerobic and anaerobic bacteria (*Escherichia coli*, staphylococci, streptococci, *Bacteroides melaninogenicus* etc) and although tiny satellite *Hemophilus*-like colonies were observed a pure isolate was not obtained.

The *Hemophilus* colonies were translucent and each was surrounded by a clear band of hemolysis. The colonies were mucilaginous and they adhered tenaciously to

the agar medium. Subcultures made before 48 hours grew well on TSA-V or in TSB-V. In broth cultures the bacteria were non-motile and adhered to the walls of the tubes.

Stained colony smears showed very small Ggam negative coccobacilli which occurred in clumps or in short chains.

The biochemical activities of the isolates were as follows: V factor dependent, clear hemolysis on 5% sheep blood agar, strong urease positive, oxydase positive, slight catalase production, nitrate reduced to nitrite, no indol produced, citrate not utilized, methyl red and Voges-Proskauer tests negative. The following carbohydrates were fermented: dextrose (no gas), fructose, lactose (two days), maltose, mannitol, sorbitol (slight), sucrose, trehalose (slight), xylose. The following carbohydrates were not fermented: adonitol, arabinose, dulcitol, inositol, salicin. Several separate iso-

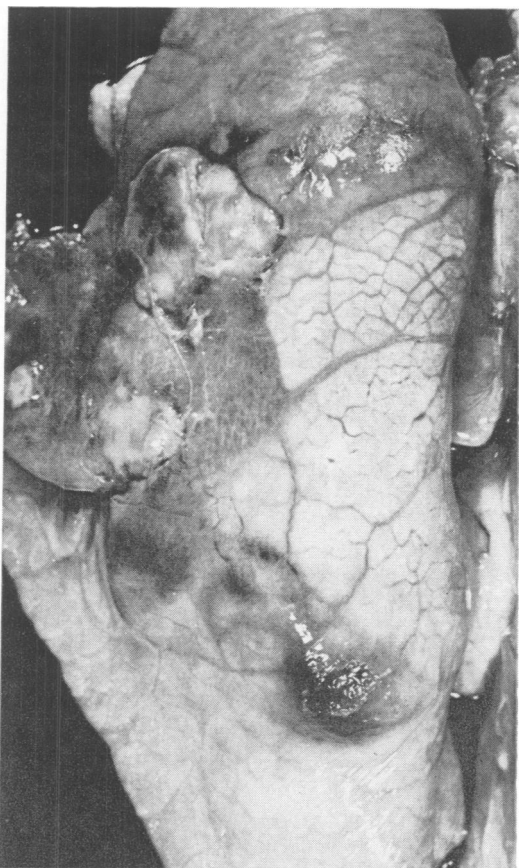


Fig. 1. Areas of consolidation, covered with a thin layer of fibrin, in apical, cardiac and diaphragmatic lobes of a pig, experimentally infected with *Haemophilus parahemolyticus*. Euthanasia nine days p.i.

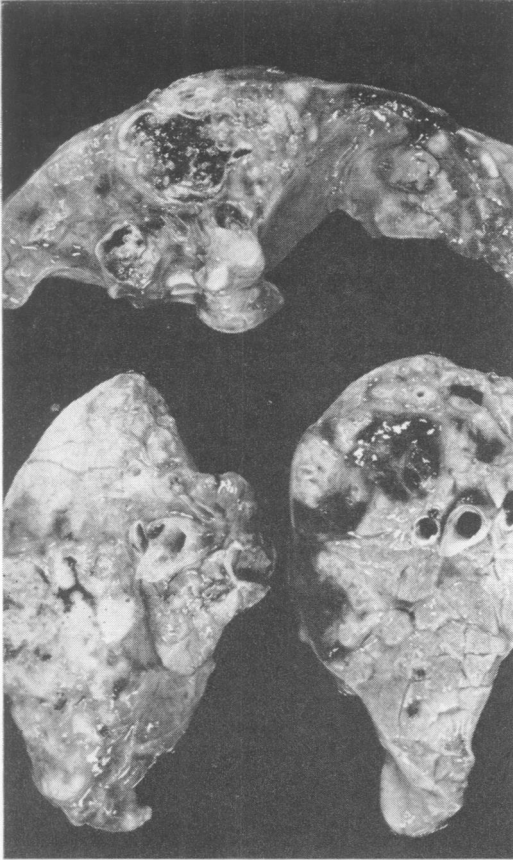

Fig. 2. Cross sections through affected lobes, showing the necrotizing, hemorrhagic character of the lesions.

lates were serotyped (5) and identified as *H. parahemolyticus* strain K17.

When tested by the *in vitro* disc method, the isolates were sensitive to the following antibacterials: ampicillin, chloramphenicol, chlorhexidine, cloxicillin, dihydrostreptomycin, erythromycin, furacin, kanamycin, lincomycin, neomycin, nifuraldezone, penicillin, polymixin B, sulfachloropyridazine, a sulfadiazine-sulfamerazine-sulfamethazine combination, tetracycline, and tylosin.

#### PATHOLOGIC-ANATOMIC FINDINGS

Three of the four pigs infected with *H. parahemolyticus* and the pig which received a sonicated culture showed typical foci of necrotizing fibrinous pleuropneumonia, although only circumscribed areas of the lungs were involved (Fig. 1). Cross sections revealed the hemorrhagic and necrotizing character of the lesion (Fig. 2). The regional lymph nodes were enlarged,

firm and edematous. The pig which received a sonicated *H. parahemolyticus* culture had one large abscess-like lesion in the left diaphragmatic lobe. No other lesions were found. None was found in the untreated pig housed with the infected group.

#### HISTOPATHOLOGICAL FINDINGS

The four pigs with gross lesions showed qualitatively similar lesions. The most outstanding feature was the occurrence of irregularly shaped necrotic areas (Fig. 3) resembling those observed in lungs of naturally infected pigs (13). The reactive cell type was mainly lymphocytic in character (Fig. 4) and such cells were most numerous in the dense darkly stained bands although some macrophages and polymorphonuclear leucocytes were observed. Surrounding the necrotic areas an intense pro-

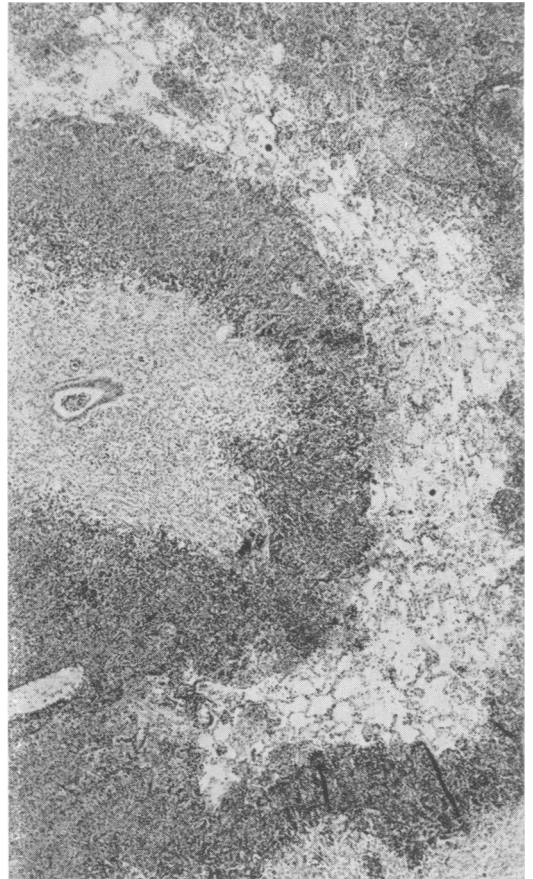


Fig. 3. Irregular shaped areas of necrosis, nine days after experimental infection with *Hemophilus parahemolyticus*. H & E. X40.

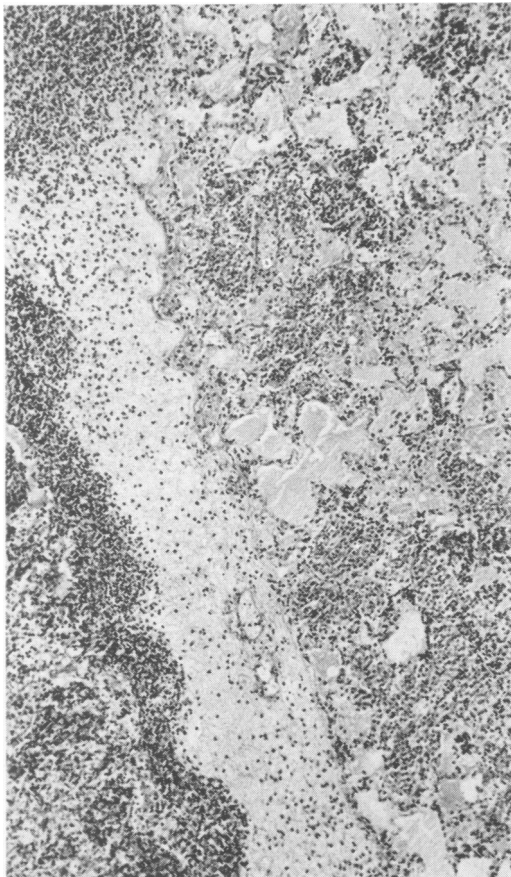


Fig. 4. Collections of lymphocytes and macrophages around necrotic tissue. H & E. X80.

liferation of fibroblasts and the formation of neocapillaries had occurred. Organization of fibrinous exudate took place in the interstitial spaces and on the pleural surface.

A cursory examination gave the impression of a rather advanced chronic lesion (Fig. 5). However, the lesions observed were not more than nine or 12 days old. This fact was substantiated by the results of examination using polarized light. This procedure revealed that the connective tissue was not birefringent, suggesting that the tissue was less than three weeks old (5).

The pulmonary parenchyma at the periphery of the necrotic and reactive foci contained proteinaceous fluid in the alveoli and an increased number of cells in the interstitial tissue. This interstitial reaction became less obvious distant from the seat of infection and was not observed in unaffected lobes.

Activation of peribronchial lymph folli-

cles was not seen but there was a marked activity of the lymph follicles in the bronchial and mediastinal lymph nodes. Cells containing pale nuclei were located in the center of the follicles and mitotic figures were numerous. The central afferent lymph vessels and sinuses were filled with macrophages, whereas the efferent lymph vessels were engorged with polymorphonuclear leucocytes. Occasional microthrombi were seen in venules in the periphery of the lymph node.

## DISCUSSION

The nutrient requirements and biochemical characteristics of the *Hemophilus* iso-

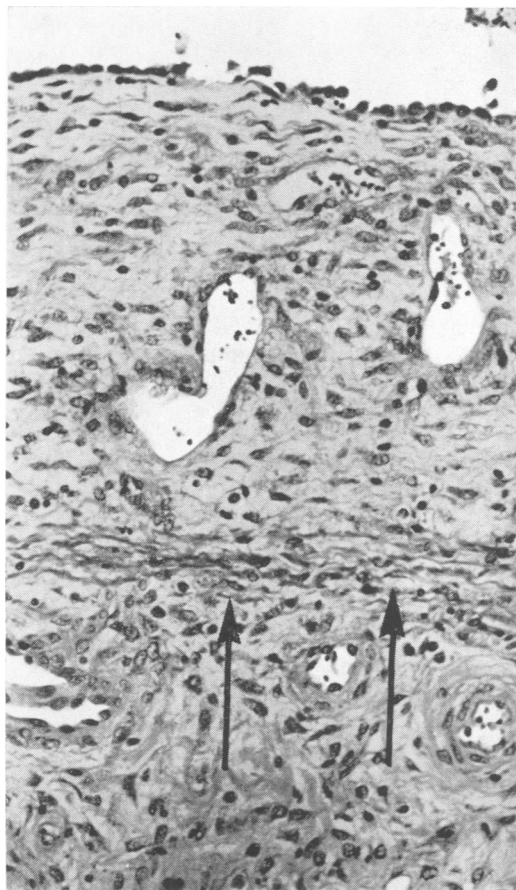


Fig. 5. Organization of pleuritic exudate, nine days after experimental infection with *H. parahemolyticus*. Note the position of the pleural basal membrane (arrows) and the thickness of newly formed tissue, rich in capillaries. H & E. X160.

late conformed with those described for *H. parahemolyticus* (6, 9). Tests showed that the culture required V factor but it was not X factor (hemin) dependent. Antibiograms revealed that the bacteria were sensitive to a broad spectrum of antibacterial drugs.

The four pigs which were infected experimentally with the isolate and which were necropsied after nine days showed pathological and histopathological features consistent with *H. parahemolyticus* infection. Stained lung sections revealed a marked degree of organization of fibrinous exudate and the proliferative reaction of mesenchymal tissue around necrotic areas showed a remarkable degree of intensity. This extensive fibroblastic activity was regarded to be a constant and typical feature of *H. parahemolyticus* pneumonia and such a reaction is observed only rarely in pneumonic processes of other etiology.

Culture procedures yielded the pathogen from only one of the four infected pigs. An additional pig was inoculated with a culture which had been subjected to sonic dismembration but this culture produced typical lung lesions from which *H. parahemolyticus* was isolated in pure culture. It was concluded that the sonic intensity or period of exposure was not sufficient to destroy all viable cells.

The results of experimental infection were not so definite as those obtained by other workers (2, 3, 4, 9, 11, 14). No remarkable clinical signs of illness were apparent during the periods of observation (nine or 12 days) and it is possible that certain factors were absent which predispose swine to the clinical disease. Upon receipt, the experimental pigs were apparently healthy and during the study they were not unduly stressed. There was no evidence of concomitant bacterial or viral infections which some workers believe must be present to initiate the disease (12) and which were present in the naturally occurring disease as described by us (13).

Intranasal infection only was used and other routes which have proven effective in transmitting the disease (intratracheal, intravenous, intraperitoneal, subcutaneous, conjunctival) were not attempted. The distinct K17 strain of *H. parahemolyticus* isolated from naturally infected pigs in Saskatchewan has not been associated previously with contagious porcine pleuropneumonia or similar diseases and it may have invasive patterns different from described types.

Strain K17 is a serotype antigenically distinct from European types 1, 2 and 3. This "American" strain was first isolated from a lamb with arthritis (1) and later it was shown experimentally to produce a septicemic disease in swine (11). Olander (11) showed that some virulent isolates from natural infections in swine were closely related antigenically to strain K17 but these cultures were not serotyped.

## ACKNOWLEDGMENTS

For identification of cultures, the authors thank Dr. J. Nicolet, University of Bern, Switzerland and Dr. R. Nielsen, Statens Veterinære Serumlaboratorium, Copenhagen, Denmark. We are indebted to Dr. H. J. Olander for the loan of his Ph.D. thesis, and to Dr. J. L. Agar for his help in preparations for the experiment.

## REFERENCES

1. BIBERSTEIN, E. L. and H. S. CAMERON. The family Brucellaceae in veterinary research. *A. Rev. Microbiol.* 15: 93-118, 1961.
2. HANI, H., H. KÖNIG, J. NICOLET and E. SCHOOL. Zur Haemophilus-Pleuropneumonie beim Schwein. V. Pathomorphologie. Schweizer Arch. Tierheilk. 115: 191-203, 1973.
3. HANI, H., H. KÖNIG, J. NICOLET and E. SCHOOL. Zur Haemophilus-Pleuropneumonie beim Schwein. VI. Pathogenese. Schweizer Arch. Tierheilk. 115: 205-212, 1973.
4. LITTLE, T. W. A. and J. D. J. HARDING. The comparative pathogenicity of two porcine Haemophilus species. *Vet. Rec.* 88: 510-545, 1971.
5. MESSOW, C. Regeneration und Entzündung vom Standpunkt der vergleichenden Pathologie. Schaper, Hannover, 1960.
6. NICOLET, J. Sur l'hémophilose du porc. I. Identification d'un agent fréquent: *Haemophilus parahaemolyticus*. *Path. Microbiol.* 31: 215-225, 1968.
7. NICOLET, J. Sur l'hémophilose du porc. III. Différenciation sérologique de *Haemophilus parahaemolyticus*. *Zentbl. Bakt. ParasitKde I Abt. Orig.* 216: 487-495, 1971.
8. NIELSEN, R. Pleuropneumoni hos svin, fremkald af *Haemophilus parahaemolyticus*. I. Kliniske, patologisk-anatomiske og epidemiologiske undersøgelser. *Nord. VetMed.* 22: 240-245, 1970.
9. NIELSEN, R. Pleuropneumoni hos svin, fremkald af *Haemophilus parahaemolyticus*. II. Undersøgelser over den isolerede bacteries identitet af patogenitet. *Nord. VetMed.* 22: 246-255, 1970.
10. NIELSEN, R. Pleuropneumoni — sakaldt (ondartet lungesyge) hos svin. *Medlemsbl. danske Dyrlaegeforen.* 55: 719-723, 1972.
11. OLANDER, H. J. A septicemic disease of swine and its causative agent, *Haemophilus parahaemolyticus*. Thesis. University of California. Davis, 1963.
12. PATTISON, I. H., D. C. HOWELL and J. ELLIOT. A Haemophilus-like organism isolated from pig lung and the associated pneumonic lesions. *J. comp. Path.* 67: 320-329, 1957.
13. SCHIEFER, B., R. E. MOFFATT, J. GREENFIELD, J. L. AGAR and J. A. MAJKA. Porcine Hemophilus parahaemolyticus in Saskatchewan. I. Natural occurrence and findings. *Can. J. comp. Med.* 38: 99-104, 1974.
14. SHOPE, R. E. Porcine contagious pleuropneumonia. I. Experimental transmission, etiology, and pathology. *J. exp. Med.* 119: 357-368, 1964.