

# Dolphin Pox: A Skin Disease of Cetaceans

J. R. Geraci, B. D. Hicks and D. J. St. Aubin\*

## ABSTRACT

Poxvirus has been identified morphologically from skin lesions in captive and free-ranging bottlenosed dolphins, *Tursiops truncatus* and a stranded Atlantic white-sided dolphin, *Lagenorhynchus acutus*. The lesions, commonly referred to as ring or pinhole lesions, appear as solitary or coalesced circular grey blemishes. Advanced ring lesions may take the form of black punctiform stippled patterns known as "tattoo". Histologically, the stratum externum is thickened, and there is ballooning degeneration and eosinophilic intracytoplasmic inclusions in the stratum intermedium. These inclusions contain virus particles which exhibit typical poxvirus morphology. Stress, environmental conditions and general health appear to play a major role in the clinical manifestation of dolphin pox.

## RÉSUMÉ

Une étude morphologique a permis aux auteurs d'identifier un poxvirus, à partir des lésions cutanées de dauphins à gros nez (*Tursiops truncatus*) qui vivaient en captivité ou en liberté, ainsi que de celles d'un dauphin à flanc blanc (*Lagenorhynchus acutus*) de l'Atlantique qui avait échoué sur le rivage. Ces lésions, communément appelées lésions en anneau ou en trou d'épingle, se présentent sous la forme de taches grises et circulaires, solitaires ou fusionnées. Les lésions en anneau avancées peuvent prendre la forme de dessins pointillés noirs qu'on désigne sous le nom de tatouages. Au microscope, la couche externe de la peau lésée présente un épaississement, tandis que les cellules de la couche intermédiaire présentent une dégénérescence hydropique et des inclusions intra-cytoplas-

miques éosinophiliques. Ces inclusions recèlent des particules virales dont la morphologie est identique à celle d'un poxvirus. Le stress, les conditions environnantes et l'état de santé général semblent jouer un rôle important dans les manifestations cliniques de la variole des dauphins.

## INTRODUCTION

Pox diseases occur in a wide variety of terrestrial vertebrate species (1). Their occurrence in marine mammals has been reported in seals and sea lions (14,15). The present study sheds light on some morphological features of a skin disease in dolphins commonly referred to as "targets", "watered-silk" (7), "ring", "pinhole", "circle" and "tattoo" lesions and establishes poxvirus as the etiological agent.

## MATERIALS AND METHODS

Seven bottlenosed dolphins, *Tursiops truncatus*, were selected for this study. One was a free-ranging, postweaned one and one-half to two year old male, discovered moribund in inshore waters off Marathon, Florida. The dolphin died immediately after being found. The carcass was placed on ice and necropsied 15 hours after death. Postmortem findings included chronic pharyngeal lymphadenitis and idiopathic right-sided pulmonary rupture resulting in unilateral hemo- and pneumothorax.

The six other bottlenosed dolphins in the study were maintained at the New England Aquarium (NEA) in an indoor semiclosed system containing filtered recirculating natural sea water at a salinity of 30 g/L, and a water turnover rate of 2 h. A twelve hour day-night photoperiod was achieved using both incan-

\*Wildlife Disease Section, Department of Pathology, Ontario Veterinary College, University of Guelph, Guelph, Ontario N1G 2W1, New England Aquarium, Boston, Massachusetts and Institute for Delphinid Research, Grassy Key, Florida.

Submitted June 14, 1979.

descent and fluorescent lighting. Seasonal variation in water temperature ranged between 13°C and 24°C.

An immature male Atlantic white-sided dolphin, *Lagenorhynchus acutus*, stranded alive near Wellfleet, Massachusetts died after a brief period in captivity at Sealand of Cape Cod. The carcass was stored frozen for four months, prior to necropsy. Postmortem examination revealed a heavy trematode infestation in the hepato-pancreatic duct, erosive osteitis of the palatine bone associated with numerous *Crassicauda*-like nematodes and large numbers of *Stenurus globicephalae* in the auditory canals and cranial sinuses.

Skin samples from the NEA dolphins were removed by surgical biopsy. A 3 x 6 mm wedge of epidermis was removed down to dermal papillae. The freshly excised tissues were placed in a Petri dish containing 2% glutaraldehyde (cacodylate buffered, pH 7.2) and cut into approximately 1 mm cubes. Necropsy specimens were placed in 10% formalin.

Tissue samples for light microscopy were embedded in paraffin, sectioned at 6 µm and stained with hematoxylin and eosin (H&E) and Masson's trichrome. Epon

embedded biopsy material was sectioned at 1 µm and stained with 1% toluidine blue in a 1% sodium borate solution at 90°C.

Specimens for electron microscopy were obtained from either glutaraldehyde-fixed biopsies or formalin-fixed tissues from dolphin carcasses. Following initial fixation in either formalin or glutaraldehyde, the tissues were washed in 0.1 mol/L cacodylate buffer, postfixed in 1% osmium tetroxide in 0.1 mol/L cacodylate buffer for four hours at 4°C, dehydrated in acetone and embedded in epon.

Epon embedded tissues were sectioned with glass knives in a Reichert OmU<sub>2</sub> ultramicrotome. Thin sections were stained with uranyl acetate and lead citrate and examined in either an Hitachi HS-9 electron microscope with an accelerating voltage of 70 KV or a Phillips

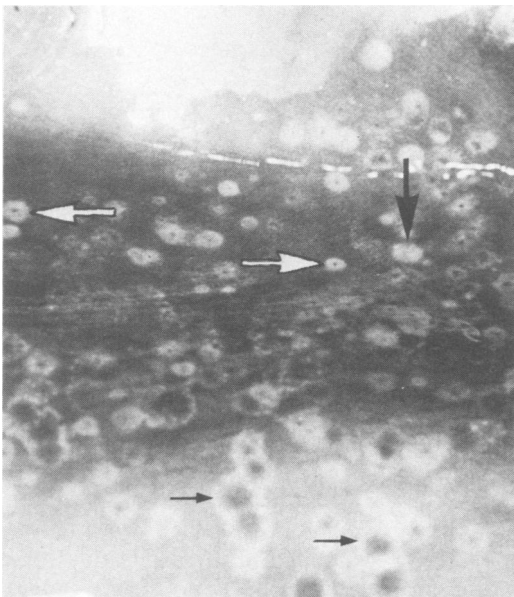


Fig. 1. Ring lesions on the dorsolateral surface of a subadult male bottlenosed dolphin, *Tursiops truncatus*. The lesions range from 0.5 to 3 cm in diameter. Early lesions are generally pale and may have a dark border (• ▲); those with grey centers are regarded as intermediate stages (↑) and lesions with black punctiform centers are more advanced (⬇).

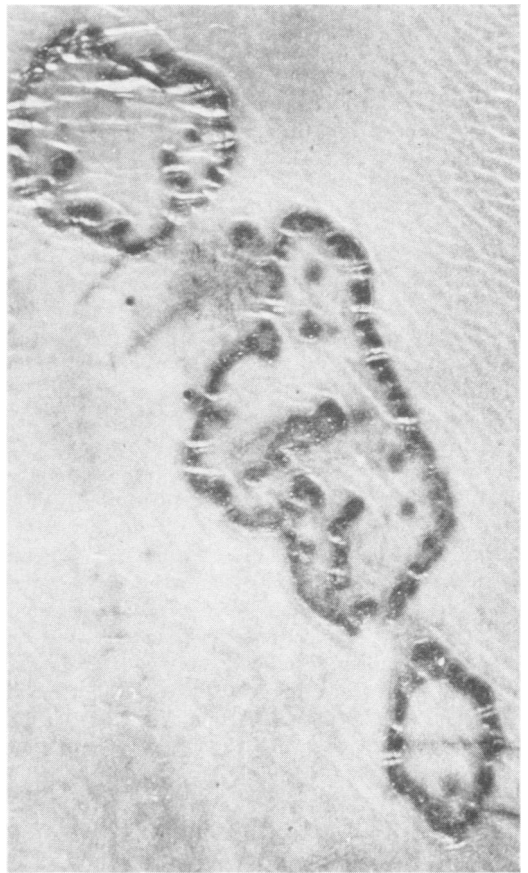

Fig. 2. Tattoo lesions on the ventrolateral surface of an Atlantic white-sided dolphin, *Lagenorhynchus acutus*. The depressed black punctiform areas consist of desquamated cells, cellular debris and bacteria.

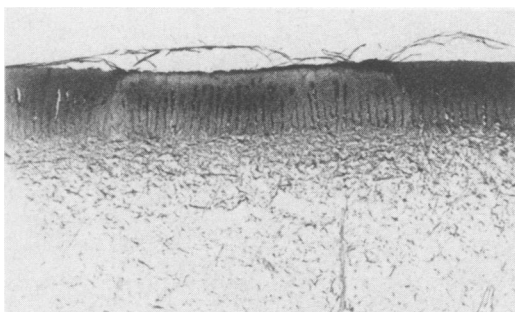


Fig. 3. Section through an early ring lesion showing a well defined pale zone of epidermis. Epithelium sloughing shown in the photograph is a normal feature of cetacean epidermis. Masson's trichrome. X5.

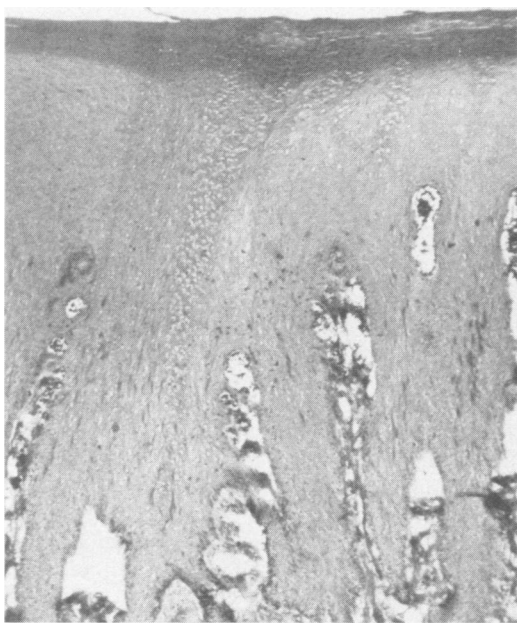

Fig. 4. Section through the edge of the ring lesion shown in Fig. 3. A transitional zone of compacted stratum intermedium cells separates normal tissue (left) from the pale vacuolated area on the right. Note the downward thickening of the stratum externum over the lesion. H&E. X100.

200 electron microscope with an accelerating voltage of 60 KV.

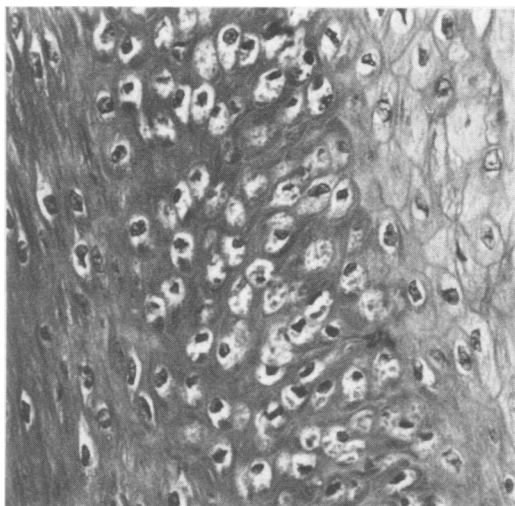
## RESULTS

A brief description of dolphin skin will aid in an understanding of our

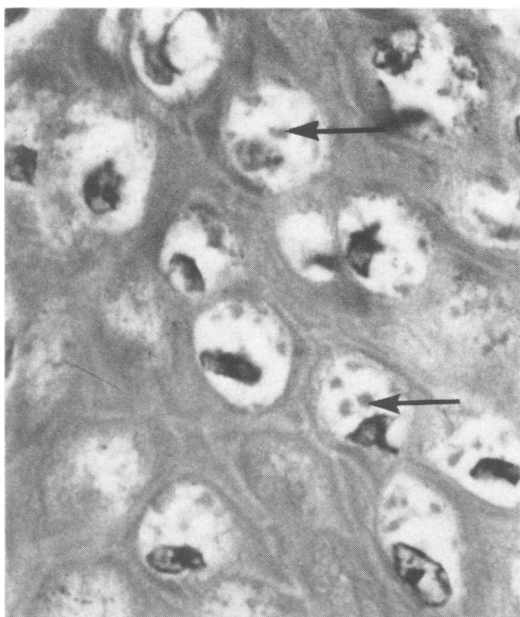
findings. Dolphin epidermis has a smooth rubbery texture and is free of hair and glands. Histologically, the stratum germinativum has a single basal layer of tall columnar cells interspersed with melanocytes arranged along the sides of prominent dermal papillae. Overlying the stratum germinativum is the stratum spinosum, which consists of one to two layers of spherical to ovoid cells 10-12  $\mu\text{m}$  in diameter, often containing 1-2  $\mu\text{m}$  lipid droplets. Above the spinosum, the stratum intermedium comprises the main mass of epidermal tissue. Cells in this region are flattened and elongated. The outermost layer, the stratum externum, is unique in cetaceans. It is not keratinized, but consists of ten to 15 layers of viable flattened cells with elongated nuclei and prominent organelles, including mitochondria. The stratum externum is commonly referred to as the parakeratotic layer (8,9).

"Ring" lesions occur commonly in captive dolphins (Fig. 1). They most often appear on the skin of the dorsal body surface and on the pectoral flippers, dorsal fin and flukes (tail). Typically, each lesion is flat or slightly raised and consists of a solitary 0.5 to 3 cm round or elliptical blemish. These sometimes coalesce. Early lesions are light gray in color and may have a dark gray border. In some cases a reversal of this color pattern is evident. Advanced stages of the lesion generally have depressed black punctiform centers which may form a stippled pattern of varying design, known as tattoos (Fig. 2). On cut section, early lesions are seen as well defined pale zones confined to the epidermis (Fig. 3).

Histological examination of early ring lesions revealed three morphologically distinguishable zones. Cells of the stratum intermedium in the central zone showed marked cytoplasmic vacuolation and a prominent reticular pattern of keratinaceous fibers (Figs. 4 and 5). This central zone was well demarcated from an adjacent transition zone of intermedium cells which contained small, spherical or irregularly shaped, pale eosinophilic intracytoplasmic inclusions (Figs. 6 and 7). The uninfected epidermal tissue adjacent to the lesion was compressed with the longitudinal axis of the cells displaced from its normal orientation to one perpendicular to the skin surface (Fig. 5).

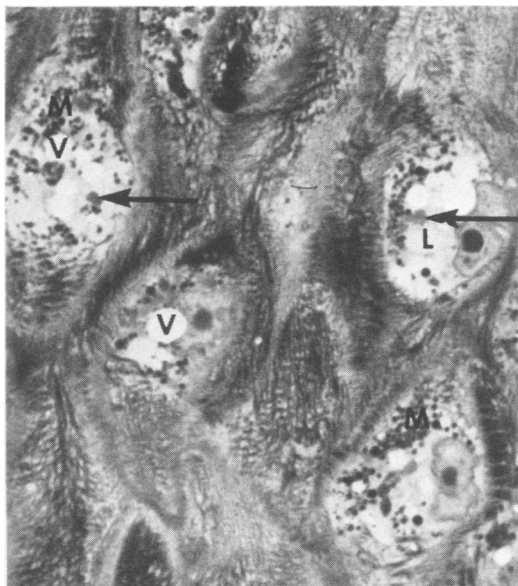


**Fig. 5.** The transitional zone of the ring lesion shown on Fig. 4, detailing the compressed stratum intermedium (left), virus-infected cells (center) and ballooning degeneration of intermedium cells in the core of the lesion (right). H&E. X200.



**Fig. 6.** Eosinophilic intracytoplasmic inclusion bodies (arrows) in infected stratum intermedium cells in the transition zone. H&E. X1575.

The intracytoplasmic inclusions in cells of the transition zone contained aggregations of virions in varying stages of development (Fig. 8). The virions, which measured approximately 200 by 300 nm, contained a dumbbell-shaped core with an outer membrane, an intermediate coat and an outer envelope (Fig. 9). Virus-



**Fig. 7.** Biopsy specimen of ring lesion showing virus aggregations (arrows), cytoplasmic vacuolization (V), lipid droplets (L) and melanin granules (M). Toluidine blue stained 1  $\mu$ m section. X2000.

infected cells showed evidence of central cytoplasmic lysis with margination and disruption of cytoplasmic organelles and clear intracytoplasmic vacuoles. Nuclei were irregularly shaped with clumping, margination and rarefaction of chromatin. Morphologically identical virus particles were evident in lesions from the free-ranging bottlenosed and white-sided dolphins and from five of the six captive bottlenosed dolphins.

The number of cell layers in the stratum externum overlying the lesion was increased up to threefold with marked individual cell compression. This resulted in a downward thickening of the zone with little or no elevation above the level of the adjacent normal tissue (Fig. 4).

In advanced ring lesions, the black punctiform center appeared histologically as a break in the continuity of the stratum externum, extending into the stratum intermedium as a conically shaped pit. The pits contain desquamated cells, cellular debris and bacteria.

## DISCUSSION

Poxvirus diseases in terrestrial verte-

brates are often manifested as vesicular eruptions of the skin, progressing from macules through papular, vesicular and sometimes pustular stages (2). Ring lesions in dolphins depart from this development pattern, seldom progressing beyond the macular stage. This feature may be attributed to the uniqueness of cetacean integument. The epidermal cells have extraordinarily high metabolic activity (3,4,9,13) and a mitotic rate up to 290 times greater than that of human epidermis (10). This level of activity is associated with continuous sloughing of epidermal cells which may keep pace with the rate of hyperplasia, leaving a smooth surface contour and only a downward thickening of the stratum externum in the area of the lesion.

The reason(s) for the variation in color and distribution of ring lesions is not fully understood and is the subject of current investigation. Presently, they are regarded as different stages in the course of the disease.

The condition, observed in captive and free-ranging cetaceans, shows few consistent features. There is no apparent age or sex predilection, the time course, severity and clinical appearance are variable, resolved lesions may or may not leave a permanent faint blemish and the condition can recur on the same animal. The disease occurs frequently in captive dolphins and is endemic in some colonies. In addition to the two species described, we recognize it from descriptions of skin lesions in several other species of toothed whales (7,11,12).

One seemingly consistent feature of this disease, which we have termed "dolphin pox", appears to be its relationship to environmental conditions and to the general health of the animal. A severe case was observed in an adult male bottlenosed dolphin held in an open sea water pen. The appearance and subsequent regression of ring lesions coincided with an episode of bleeding gastric ulcers. In another instance, recurrence of the disease was associated with poor water quality. An adult male bottlenosed dolphin held in artificial sea water at an inland aquarium would develop numerous ring lesions when transported each fall from an open-air pool to a more crowded indoor tank with inadequate water filtration. The lesions persisted throughout the winter period of indoor confinement

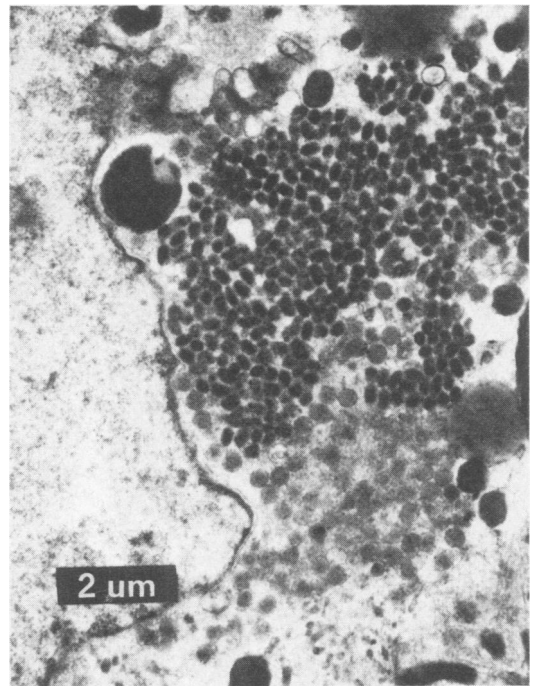


Fig. 8. A large aggregation of immature and mature pox virions in degenerating cytoplasm of a stratum intermedium cell.

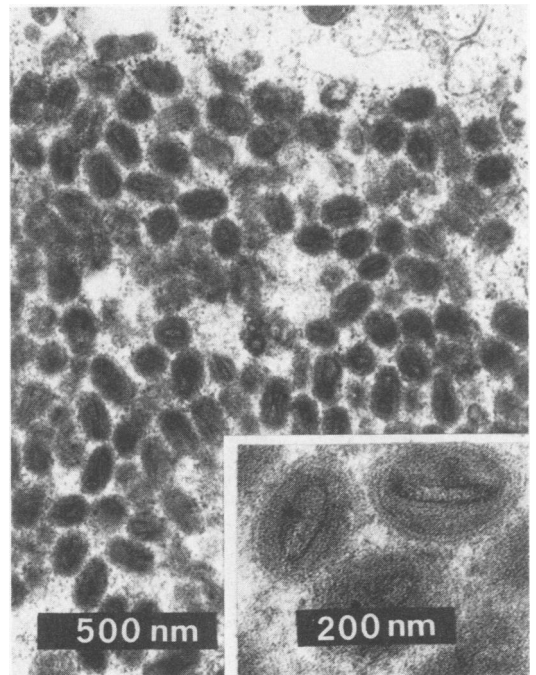


Fig. 9. Aggregation of poxvirus. Insert: Section through virions detailing the core with an outer membrane, an intermediate coat and an outer envelope.

and would regress when the dolphin was transferred to the outdoor facility. Tattoo and ring lesions on the NEA dolphins were first observed after a sudden change in water temperature from 21°C to 3°C and a power failure caused by a severe winter storm.

Other similar cases have been noted, yet the association between stress and dolphin pox is still tentative. These observations suggest however that dolphin pox is more than a skin disease. It may provide a useful visual clue to general health and stress in captive and free-ranging dolphins (5,6).

#### ACKNOWLEDGMENTS

We thank J. H. Prescott, J. Pearson and P. Fiorelli of the New England Aquarium, Boston and J. Rodriguez, A. Rodriguez and the staff of the Institute for Delphinid Research, Grassy Key, Florida for access to dolphins, technical assistance with sample collection and case histories. Drs. J. Johnson and I. K. Barker (Ontario Veterinary College) and Dr. N. Palmer (Ontario Ministry of Agriculture and Food) provided useful comments on the manuscript. Dr. J. Johnson also reviewed histological material. This study was funded jointly by the Natural Sciences and Engineering Research Council of Canada (grant A6130) and the Department of Fisheries and Oceans, Canada (Science Subvention grant FMS-5427).

#### REFERENCES

1. BRUNER, D. W. and J. H. GILLESPIE. Hagan's Infectious Diseases of Domestic Animals. The Animal Poxviruses. 6th Edition. Chapter 39. pp. 918-948. Ithaca, New York: Cornell University Press. 1973.
2. CHEVILLE, N. F. Cytopathology of viral diseases. In Monographs in Virology. Volume 10. J. L. Melnick, Editor. pp. 1-235. Basel: S. Karger. 1975.
3. DARGOLTZ, V. G., E. V. ROMANENKO and V. E. SOKOLOV. Oxygen consumption by skin in dolphins and problem of cutaneous respiration in cetaceans. Zool. Zh. 57: 768-776. 1978.
4. GERACI, J. R. and D. J. ST. AUBIN. Tissue sources and diagnostic value of circulating enzymes in cetaceans. J. Fish Res. Board Can. 36: 158-163. 1979.
5. GERACI, J. R. and D. J. ST. AUBIN. Stress and diseases in the marine environment: insights through strandings. In Biology of Marine Mammals: Insights Through Strandings. J. R. Geraci and D. J. St. Aubin, Editors. pp. 223-238. Springfield, Virginia: Nat. Tech. Inf. Serv. PB-298 890. 1979.
6. GERACI, J. R., S. A. TESTAVERDE, D. J. ST. AUBIN and T. H. LOOP. A mass stranding of the Atlantic white-sided dolphin, *Lagenorhynchus acutus*: a study into pathobiology and life history. Nat. Tech. Inf. Serv. PB-289 361. 1979.
7. GREENWOOD, A. G., R. J. HARRISON and H. W. WHITTING. Functional and pathological aspects of the skin of marine mammals. In Functional Anatomy of Marine Mammals. Volume 2. R. J. Harrison, Editor. pp. 73-110. New York: Academic Press. 1974.
8. HARRISON, R. J. and K. W. THURLEY. Structure of the epidermis in Tursiops, Delphinus, Orcinus, and Phocoena. In Functional Anatomy of Marine Mammals. Volume 2. R. J. Harrison, Editor. pp. 45-71. New York: Academic Press. 1974.
9. LING, J. K. The integument of marine mammals. In Functional Anatomy of Marine Mammals. Volume 2. R. J. Harrison, Editor, pp.1-44. New York: Academic Press. 1974.
10. PALMER, E. and G. WEDDELL. The relationship between structure, innervation and function of the skin of the bottlenosed dolphin (*Tursiops truncatus*). Proc. Zool. Soc. London 143: 553-568. 1964.
11. SERGEANT, D. E. The biology of the pilot or pothead whale *Globicephala melaena* (Traill) in Newfoundland waters. Fish Res. Board Can. Bull. 132: 1-84. 1962.
12. SIMPSON, J. G. and M. B. GARDNER. Comparative microscopic anatomy of selected marine mammals. In Mammals of the Sea: Biology and Medicine. S. H. Ridgway, Editor. pp. 298-418. Springfield, Illinois: C. C. Thomas. 1972.
13. TINYAKOV, G. C., V. P. CHUMAKOV and B. A. SEVASTIANOV. Some patterns of skin microstructure in cetaceans. Zool. Zh. 52: 399-407. 1973.
14. WILSON, T. M., N. F. CHEVILLE and L. KARSTAD. Seal pox. Bull. Wildl. Dis. Ass. 5: 412-418. 1969.
15. WILSON, T. M. and I. POGLAYEN-NEUWALL. Pox in South American sea lions (*Otaria byronia*). Can. J. comp. Med. 35: 174-177. 1971.