

CHOROIDEREMIA

A REPORT OF THREE CASES IN THREE GENERATIONS*

BY

RONALD F. LOWE

Melbourne, Australia

THE appearances of the fundi in choroideremia have fascinated ophthalmologists since the first cases were described by Mauthner (1871). This author differentiated the condition from retinitis pigmentosa. His two cases had night-blindness and constricted visual fields, but in addition there was marked choroidal atrophy giving a brilliant white appearance to the fundi, the retinal vessels were normal, and the optic disks were not atrophic. The disease is rare but since that time many cases have been reported. Considerable confusion exists throughout the literature because white, atrophic fundi may be found in the final stages of other diseases, *e.g.*, retinitis pigmentosa, choroidal sclerosis, and gyrate atrophy.

From the early reports the familial incidence was appreciated. Zorn (1920) found six cases in three generations of a family. Schutzbach (1938) traced thirteen cases in four generations, finding that the changes in the females were less severe than in the males. Goedbloed (1942) showed that males may exhibit typical choroideremia whereas the females of the family present "salt-and-pepper fundi". He concluded that the disease is transmitted by way of the sex chromosomes showing intermediate dominance. This mode of inheritance was confirmed by McCulloch and McCulloch (1948), who succeeded in tracing 86 cases of choroideremia in two families. As a result of these accumulated investigations different manifestations can now be appreciated; the following account, taken from the writings of Bedell (1937), McCulloch and McCulloch (1948), and Fralick (1948), represents the present knowledge of the disease.

Choroideremia, in the male, is a progressive disease and the fundus picture changes from youth to age. Night-blindness in childhood is followed by progressive loss of sight and advancing field defects in youth and adult life, and complete blindness in old age. Choroideremia is not due to congenital absence of the choroid with spared macular areas, but is the result of an inherited form of progressive retinal degeneration resembling retinitis pigmentosa.

* Received for publication June 12, 1950.

The affected female has a characteristic fundus picture but develops no obvious defect in vision. Progression is slow and of a minor degree compared with the male. Typical fundus changes in a female show her to be a transmitter of the disease, whereas any woman who does not present the stigmata of choroideremia in her fundi cannot pass it to her descendants. This form of hereditary transmission is called sex-linked conditional or provisional dominance. The defective gene is located in the X-chromosome. As there is no allelomorph in the male, the disease is not repressed and classical choroideremia occurs. In the female the healthy allelomorph modifies the effect so that although some retinal atrophy occurs the effects are benign.

These facts are of great help to practising ophthalmologists. Any person showing no signs of choroideremia can be safely assured that no descendants will be affected. On the other hand, any person showing even minor manifestations will transmit the disease according to the chances of sex-linked inheritance. An afflicted male may be told that none of his sons nor any of their descendants will suffer from the disease, and that all his daughters will have good sight, although they will have signs of the disease in a mild form. The affected females will transmit the disease to half their sons, who will eventually become blind, and to half their daughters, who will have no significant disability but will pass on the disease to their descendants in similar proportions.

CASE REPORTS

Case 1. F. S., male, aged 20 years (Generation V, 6).—At the age of 4 years he was noticed to have a left convergent strabismus and poor vision in bad light. For as long as he can remember he has had no useful central vision in his left eye. He does not think that the sight in his right eye has changed very much. Sometimes at school he had to sit close to the board but otherwise he experienced no difficulty. He left school at the age of 14 years having reached a class standard that can be considered average for his age. He was not particularly interested in sport—he had difficulty with cricket and baseball because he could not follow the flight of the ball quickly enough, but football gave him no trouble. He followed the occupations of toy-making, metal polishing, and French polishing, none of which he left because of difficulty with vision. To my consternation I found his present occupation to be that of a motor-truck driver amid the very busy traffic of Melbourne. He noticed that at first he had difficulty as he tended to drive too near the centre of the road, but now that he is familiar with his work he has no trouble; he has had no accidents. He experiences no difficulty in parking or in negotiating heavy traffic. He fails on all Ishihara plates, but passed the police lantern test and can name paint-box pigments accurately. He has no trouble during daylight but at dusk his vision becomes poor and in the dark he is quite blind.

Examination.—V.R. 6/60, with—1·75 D. cyl. axis 90°, 6/18.

V.L., only hand movements in the temporal field.

The right pupil reacts briskly to light, the left sluggishly. Media are clear. The ocular fundi show the typical appearances of choroideremia (Fig. 1). The optic disks

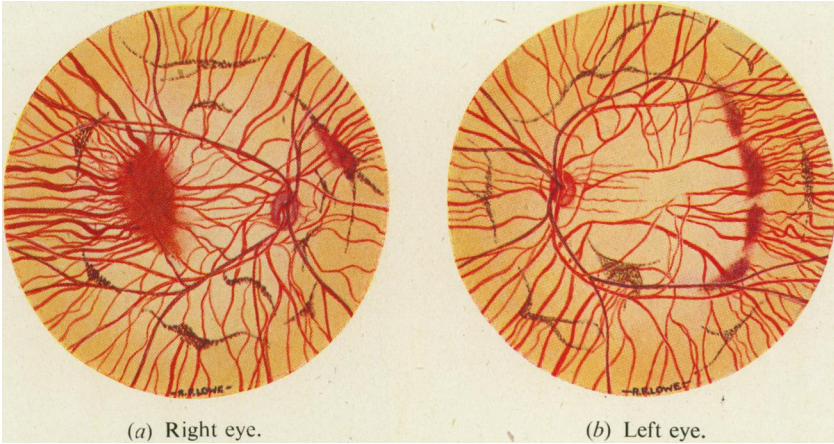


FIG. 1.—Ocular fundi of F. S., aged 20 years (Generation V, 6), illustrating typical appearances seen in affected males.

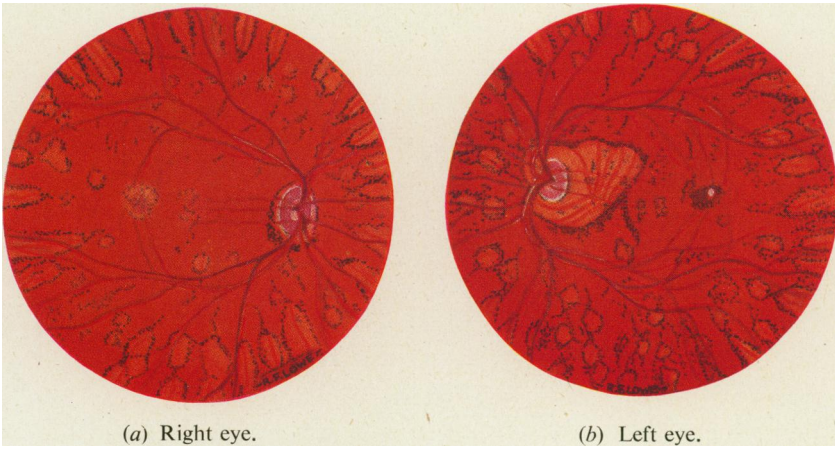


FIG. 4.—Ocular fundi of E. S., aged 55 years (Generation IV, 1), illustrating typical appearances seen in female transmitters.

and retinal vessels appear normal. The red reflex is replaced by a brilliant off-white tinged with yellow-green, but a few islands of red choroid and retina remain. Large choroidal vessels are prominently outlined against the bared sclera and they are closely spaced where they appear to stream to and from the retinal islands. The largest retinal island is at the right macula, but the central area of the left retina is completely bare which accounts for the absence of left central vision. Irregular linear collections of retinal pigment outline roughly concentric circles round the optic disks and maculae, and are sometimes associated with the retinal islands. Although in most places there is no ophthalmoscopic evidence of red choroid and retina in association with the pigment collections, the visual fields show that some functioning retinal cones must be present there.

In testing the visual fields small test objects were barely seen. The Bjerrum's screen showed very small enclosures when the right eye was tested (Fig. 2, overleaf). The one-third-metre perimeter gave very interesting charts. The easiest test object to use was 20/330 white. With it each eye presented concentric zones of vision suggesting a concentration of retinal cones distributed as mentioned above (Fig. 3, overleaf). Fields with 10/330 showed narrow and irregularly-edged bands of vision with sloping edges that were very difficult to record.

Case 2. E. S., female, married, aged 55 years (Generation IV, 1).—Her history gives no eye disability until the onset of presbyopia.

Examination.—V.R., with +0.5D. cyl. axis 180, 6/6.
V.L., with +0.25D. axis cyl. 180°, 6/6.

The fundi show the characteristic changes of the female transmitter of choroideremia (Fig. 4). The optic disks and retinal vessels are normal in appearance. The striking feature is a patchy choroido-retinal thinning especially marked round the equator and periphery but also round the optic disks and near the maculae. The patches are similar in size to the optic disks but some are smaller and others are larger. Each consists of an area paler than normal with large choroidal vessels exposed on account of retinal thinning and depigmentation, and surrounded by a border of coarsely granular, proliferated retinal pigment. Linear or grouped aggregations of retinal pigment also occur separately. The appearances have been described as resembling "pepper and salt" fundi but the term is much too vague. The symmetry of the lesions in each eye and the regularity of the distribution point to a genetic anomaly. The appearances can be recognized as a modified manifestation of the complete lesion seen only in males.

The visual fields to 3/2000 white showed the periphery around the 20° circle with barring of each blind spot, but no other abnormality.

Case 3. F. E. P., male, aged 80 years (Generation III, 1).—At the age of 6 years it was noticed that he could not see at twilight or in a bad light, and was treated for choroiditis. At the age of 21 years he had three periods of "black-outs" lasting several minutes. At the age of 24 years he remembers standing in his garden (in England) and seeing men working on the Blackpool tower two miles away, so that he could not have been myopic at that time. He also remembers that inside the room where he worked his vision was so poor that he could not see tools on the bench. By the age of 27 his sight had become very weak, and at 32 years he was no longer able to drive his horse and cart as he had only side vision. When 37 years of age he became completely blind. He became deaf at the age of 74 but otherwise "has a sound constitution".

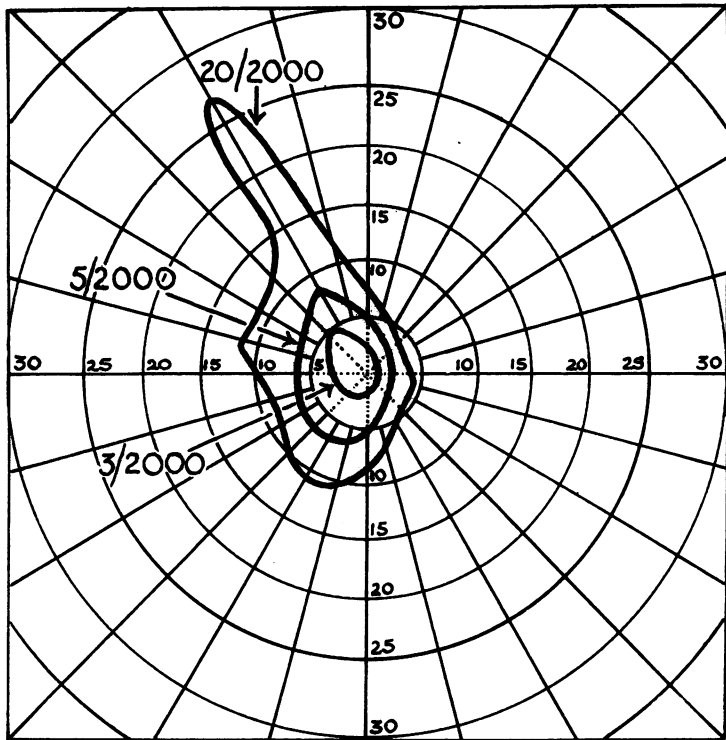


FIG. 2.—Central visual fields of right eye of F. S. (Generation V, 6), tested on 2-metre Bjerrum's screen (September 24, 1949).

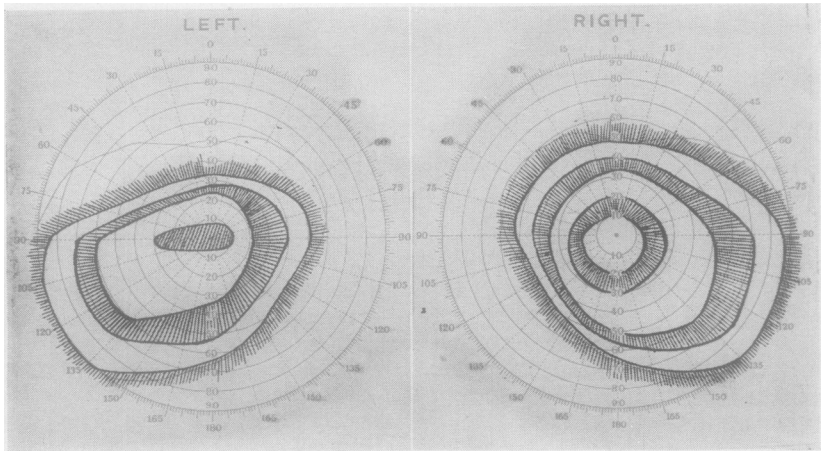


FIG. 3.—Visual fields of F. S., (Generation V, 6), tested on perimeter with 20,330 white test objects (September 24, 1949).

As he was a blind pensioner he was examined in 1934 (aged 64 years) the report being—" optic atrophy, retinal atrophy, and lenticular opacities ". As he still resides in England I was unable to examine him personally, but he was recently examined by Dr. T. S. Blacklidge who reported—" the fundi show extensive atrophy of the choroid and retina with central lens opacities. The appearance is that of choroideremia ".

Mr. F. E. P. has given the following reports of his relatives, the family tree being set out in full in Fig. 5.

His father (Generation II, 1) died in 1878 at the age of 50 years, having had no known abnormality of vision.

His mother, who died in 1907, aged 71 years, had to go to hospital when aged 50 years with a rash on her face and head and lost her sight for a few weeks but the vision recovered. The marriage was not consanguineous.

He had one brother and two sisters (Generation III, 2-4) who all died before reaching the age of two years.

Neither of his grandmothers (Generation I, 2 and 3) had any known abnormality of vision. They died at the ages of 76 and 78 years.

He did not know either of his grandfathers personally although he heard no account of any poor vision. His maternal grandfather, E. H. (Generation I, 4), who died in 1872 at the age of 62 years, had always been employed as an engine-fitter. Apparently his vision was adequate for his tasks because there was no family knowledge of poor sight. He died when F. E. P. was aged 2 years, four years before F. E. P.'s symptoms of night-blindness were noticed.

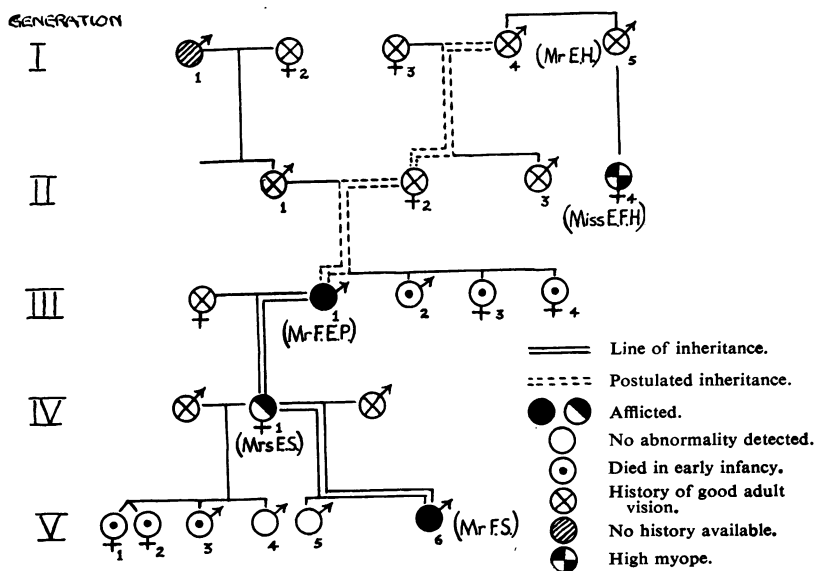


FIG. 5.—Family tree of reported family showing inheritance as a sex-linked conditional dominant.

DISCUSSION

The three cases reported show the characteristic features of choroideremia. Its inheritance as a sex-linked conditional dominant is confirmed. The two males from alternate generations show the disease in its severe form and the female in direct line in the intervening generation shows it in the benign form of the female transmitter.

Mr. F. E. P's maternal grandfather (E. H., Generation I, 4) should have had choroideremia in a severe form but it appears most improbable that he did so. His vision remained good enough for him to continue working as an engine-fitter until over the age of 60 years. Even if his maculae were spared to allow this, he apparently had neither night-blindness nor grossly restricted visual fields. In view of his occupation and the age in which he lived he probably worked most of the time in a dim light. He died when F. E. P. was aged 2 years, and only four years later night-blindness began to trouble F. E. P., who was taken to the Royal Eye Hospital, Manchester. The grandmother lived 10 or 15 years longer, by which time the child's night-blindness must have been severe, yet no knowledge exists of any similar defect in the grandfather. Other family details supplied by F. E. P. show that the various members were well known to each other, so that if E. H. had any visual defect it is inconceivable that the others should not have been aware of it.

E. F. H. (Generation II, 4), an unmarried female cousin of F. E. P's mother was thought to have defective eyes similar to those of F. E. P. She has been examined recently by Mr. H. V. White, ophthalmic surgeon, of Manchester, England, who reported—"Both globes protrude markedly due to high myopia, both lenses are opaque and the fundi are not seen. No perception of light remains in the right eye, the left eye can just perceive light". She wore strong glasses until she became blind at the age of 65 years, her present age being 82 years. She has remained unmarried but it is unlikely that she was a transmitter of choroideremia as her father would then have had it too, and there is no family suggestion of this.

If E. H. (Generation I, 4) did not suffer from choroideremia his X-chromosomes did not initially contain the defective gene. Such a gene must have arisen by mutation either in his sex cells early in his life, or in those of his daughter, F. E. P's mother (Generation II, 2), before the age of 35 years, *i.e.*, between the years 1810 and 1870. The smallness of the family prevents more exact timing. Cases where defective genes have arisen in healthy families are well known and the occurrence of a mutation leading to choroideremia need cause no surprise. Similar mutations must be very rare because choroideremia is a rare disease, and after the mutation has occurred the disease becomes very obvious in the males of subsequent generations.

SUMMARY

Two male cases and one female case of choroideremia in three generations are presented. Inheritance was by way of a gene showing

sex-linked conditional dominance. A mutation resulting in choroid-eremia probably occurred in an X-chromosome between the years 1810 and 1870.

I should like to express my appreciation to the various members of the family who rendered all possible assistance in this investigation, and to Dr. F. Hall, C.B.E., County Medical Officer of Health, Lancashire County Council, for invaluable help in obtaining records and sending copies to me.

REFERENCES

- BEDELL, A. J. (1937). *Arch. Ophthal., Chicago*, **17**, 444.
FRALICK, F. B. (1947-48). *Trans. Amer. Acad. Ophthal. Oto-laryng.*, p. 187.
GOEDBLOED, J. (1942). *Ophthalmologica, Basel*, **104**, 308.
MAUTHNER, L. (1871). *Ber. naturw.-med. Ver. Innsbruck.*, **2**, 191.
McCULLOCH, C., and McCULLOCH, R. J. P. (1947-48). *Trans. Amer. Acad. Ophthal. Oto-laryng.*, p. 160.
SCHUTZBACH, M. (1938). *Graefes Arch. Ophthal.*, **138**, 315.
USHER, C. H. (1935). *Trans. ophthal. Soc. U.K.*, **55**, 164.
ZORN, B. (1920). *Graefes Arch. Ophthal.*, **101**, 1.