

## EOSINOPHILIC GRANULOMA OF THE ORBIT\*

BY

AARON J. BELLER AND WALTER KORNBLUETH

*From the Neurosurgical and Ophthalmological Departments, Rothschild Hadassah University Hospital, Jerusalem, Israel*

REPORTS on intra-orbital tumours and causes of exophthalmos do not mention the disease entity of eosinophilic granuloma first described by Lichtenstein and Jaffe (1940). Pfeiffer (1943), in reviewing 200 successive cases of exophthalmos, enumerated 31 different lesions, among which eosinophilic granuloma of the orbit was not listed. Forest (1949) reported on 222 cases of intra-orbital tumours collected from the registry of the U.S. Army Institute of Pathology, but did not include eosinophilic granuloma. Dandy (1941) did not mention this possibility in his monograph on orbital tumours.

A review of the literature on eosinophilic granuloma of the bone (Dundon and others, 1946; Hansen, 1949; Jaffe and Lichtenstein, 1944) revealed one case in which the lesion was limited to the orbit (Walshard and Zuppinger, 1949). Here the diagnosis of a granuloma, probably due to xanthomatosis, was made in a two-year-old boy, but a re-check confirmed the correct diagnosis of eosinophilic granuloma. This report seems justified by the need to call attention to this lesion in the differential diagnosis of intra-orbital tumours.

### CASE REPORT

**Case 1.** M. S., a 14-year-old boy, came to the Ophthalmological Clinic on January 8, 1950, complaining of pain in the left supra-orbital region, and blurred vision of two weeks' duration in the left eye. Two weeks previously the patient had been hit in the head (left temporal region) by the iron door of a bus while trying to board the moving vehicle. The family history as well as the past history were irrelevant, except for the fact that the boy had spent the last four years in an institution for defective children because he was mentally retarded. In 1944 he had suffered from a chronic otitis media in the left ear.

On inspection the boy was seen to keep his left eye closed. There was no swelling of the lids nor any external sign of contusion. On being told to open and close his left eye he was able to do so quite freely.

---

\* Received for publication October 23, 1950.

There were no abnormal findings in the right eye, visual acuity, corrected with  $-0.75$ , being  $5/6$ .

The palpebral fissure of the left eye was slightly wider than that of the right. Measured with the exophthalmometer of Hertel, the left eye, in comparison with the right, showed a protrusion of 3 mm. Eye movements were limited in all directions, in particular on lateral gaze to the left. The pupils were round and equal in size, the left reacting sluggishly to light, directly and consensually. Corneal sensitivity was intact, the media and the eye ground did not show any pathological changes. Visual acuity amounted to counting fingers excentrically at a distance of 1.5 m. The visual field was difficult to take because of the patient's lack of co-operation, but seemed to indicate an absolute central scotoma.

X ray of the orbits showed some destruction of the left sphenoidal ridge extending into the lateral wall of the orbit. There was no evidence of increased intra-orbital pressure (Fig. 1). Examination of the nasal sinuses and the nasopharynx revealed no abnormality. Pulse rate, temperature, and blood pressure were within normal limits. General physical as well as neurological examinations were negative except for hypoaesthesia in the distribution of the left supra-orbital nerve. A bone survey failed to disclose any other destructive lesion.

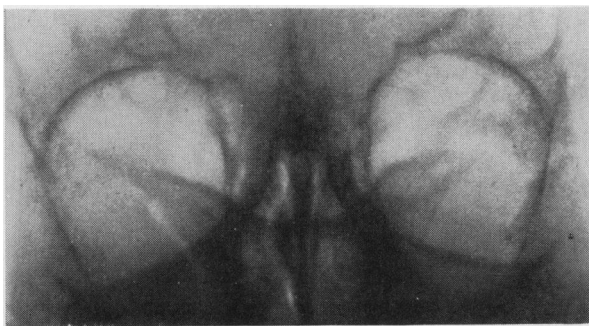


FIG. 1.—Case I. Destruction of left sphenoidal ridge extending into lateral wall of orbit.

*Laboratory Findings.*—Blood count: erythrocytes 4,950,000; haemoglobin 75 per cent. (Sahli); leucocytes 8,000; neutrophils 62 per cent.; monocytes 5 per cent.; eosinophils 4 per cent.; bandform 3 per cent.; lymphocytes 26 per cent.

Sternal puncture no abnormality.

Blood chemistry: sugar 81 mg. per cent.; urea 25 mg. per cent.; total protein 7.8 per cent. (albumin 5.1 per cent., globulin 2.7 per cent.); total cholesterol 186 mg. per cent. (free cholesterol 59 mg. per cent., cholesterinester 127 mg. per cent.); phosphorus 3 mg. per cent.; phosphatase 6.2 Bodansky units; calcium 8.3 mg. per cent.

Blood sedimentation rate one hour (Linzenmeyer).

Urine analysis normal.

Arteriography was performed by injecting the left common carotid artery with 20 ml. 35 per cent. diodrast. There was no aneurysm in the distribution of the internal carotid artery, nor was there any displacement of vessels.

While in hospital the patient complained of severe supra-orbital pain which was relieved temporarily only by an injection of novocain into the supra-orbital nerve at its exit from the supra-orbital notch. Proptosis of the left eyeball increased to 5 mm. and vision decreased to recognizing hand movements close to the eye. This time the left fundus presented slight engorgement of the veins.

Five weeks after the patient was first seen the whole clinical picture dramatically changed within 24 hours. The patient spontaneously reported that pain had completely disappeared and vision improved remarkably overnight. Sudden regression of the proptosis could be confirmed so that the difference between the two eyes was only 1 mm. The movements of the eyeball were altogether free. There were some nystagmoid jerkings on extreme lateral gaze to the left. Visual acuity in the left eye rose to 5/5 and the visual field was full. Ophthalmoscopic examination was negative. X ray of the orbits taken the following day showed marked destruction of the left sphenoidal ridge in its middle portion, extending to the roof and the lateral wall of the orbit. The area of destruction was as if punched out, and there were no signs of reactive bone changes at its margin (Fig. 2).

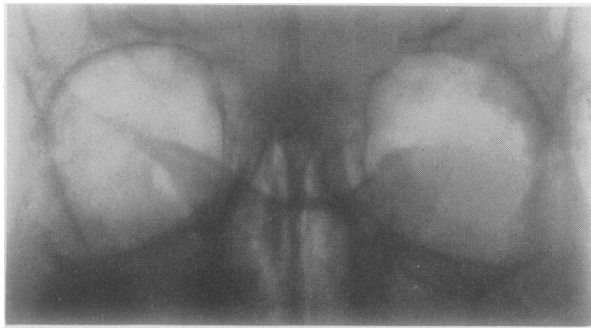


FIG. 2.—Case 1. Punched-out area in sphenoidal ridge, roof, and lateral wall of left orbit (5 weeks after Fig. 1).

*Operation.*—On March 1, the lesion was exposed through a left transfrontal craniotomy. The dura covering the frontal pole was retracted from the orbital roof. At the posterior part of the orbital roof a hole was seen in the bone through which a soft yellowish mass bulged into the cranial cavity. The tumour was removed piecemeal by means of a curette. It was adherent to the bone margin but could easily be freed from the capsule of Tenon. Part of the tumour entered the middle fossa for a distance of 2 cm. at the area where the sphenoidal ridge had been destroyed. The tumour was removed as far as could be seen. The post-operative course was uneventful.

*Microscopic Examination.*—The tissue as a whole was very cellular showing a few areas of haemorrhage and necrosis. There was a moderate amount of collagen connective tissue particularly at the margin of the lesion. Numerous congested capillaries were found adjacent to the areas of haemorrhage. The tissue contained abundant eosinophilic leucocytes (Fig. 3), and a sheet-like accumulation of small and

large histiocytes (Fig. 4). Foci of multi-nuclear giant cells, with a granular cytoplasm, which occasionally revealed some pale vacuoles, were seen in the vicinity of the areas of necrosis and haemorrhage.

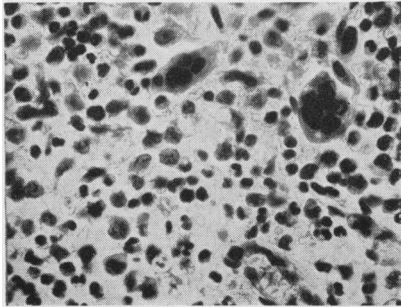


FIG. 3.—Case 1. Eosinophilic leucocytes and multinuclear giant cells. Haematoxylin and eosin (x 405).

After complete healing of the operative wound, the patient received deep X-ray treatment through the left frontal and temporal fields totalling 2150r.

The boy was last seen in July, 1950, four months after the operation. Re-examination of the eyes revealed no abnormality. A repeated X ray of the orbits (Fig. 5) showed some density at the area of previous destruction and the margins of the lesion could hardly be recognized.

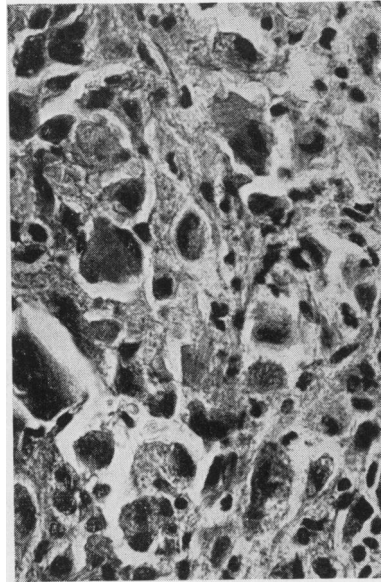


FIG. 4.—Case 1. Numerous histiocytes. Haematoxylin and eosin (x 405).

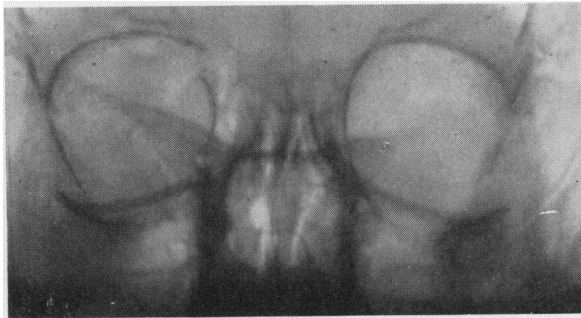

FIG. 5.—Case 1. Density at area of previous destruction (4 months after operation).

**Blood Chemistry.**—Total cholesterol 150 mg. per cent.; phosphorus 2.7 per cent.; phosphatase 7 Bodansky units; calcium 11.6 mg. per cent. There were still 5 per cent. eosinophils in the peripheral blood.

## COMMENT

At the time of the first examination diagnosis of an intra-orbital space-occupying lesion of undefined nature was made. The history of trauma to the left temporal region, followed by the rapid development of the clinical symptoms, suggested among other possibilities retrobulbar haematoma. The roentgenological finding of some destruction of the sphenoidal ridge and of the roof of the orbit rather favoured a neoplastic lesion. Hand-Schüller-Christian's disease was also considered in the differential diagnosis. Final proof of the true nature of the lesion was obtained by histological examination of the tissue removed at the operation.

The sudden improvement—regression of the protrusion of the eyeball, return of full visual acuity and disappearance of the muscular palsies—could be explained by decompression due to the marked destruction of the orbital walls shown in Fig. 2.

Several points in the history and clinical course of the disease might have indicated the probability of eosinophilic granuloma:

- (i) The age group most frequently affected by this lesion includes the first two decades of life.
- (ii) Incidence in males is higher than in females.
- (iii) The significance of trauma in the aetiology of the disease has been stressed by several authors.
- (iv) The rapid development and progress of the clinical picture were characteristic of an eosinophilic granuloma.
- (v) X-ray of the bone as a rule shows a well defined osteolytic process with little evidence of reactive bone formation at the margin of the defect.
- (vi) Most of the reported cases showed an increase of eosinophiles in the peripheral blood.

Though one has to take eosinophilic granuloma into account in the differential diagnosis of an orbital lesion, a malignant tumour of the orbit destroying the bone could not be definitely excluded. One was, therefore, justified in exploring surgically the affected region.

The patient showed no general signs, such as diabetes insipidus, or enlargement of liver and spleen, suggesting the symptom complex of Hand-Schüller-Christian's disease. In this connection it is of interest to note that in a later publication Jaffe and Lichtenstein (1944) assumed eosinophilic granuloma of the bone to be "the mildest clinical expression of the peculiar inflammatory histiocytosis", comprising also Letterer-Siwe's disease and Hand-Schüller-Christian's disease.

## SUMMARY

A case of eosinophilic granuloma of the orbit, causing exophthalmos, palsy of the third, fourth, and sixth nerves, irritation of the first division of the fifth nerve, and loss of vision, is described.

The symptoms and signs characteristic of the lesion are discussed.

Eosinophilic granuloma, though apparently of very rare occurrence in the orbit, should have its place in the differential diagnosis of orbital tumours.

#### ADDENDA

(a) Since this paper was submitted for publication, an additional case of eosinophilic granuloma has been seen.

**Case 2.** A 2½-year-old girl, suffering from a progressive proptosis of the left eye of 8 months' duration, was examined in our out-patient department on June 27, 1950. The only pathological findings were a marked proptosis on the left side and a sluggish reaction to light of the left pupil. X ray revealed a destructive lesion of the roof and lateral wall of the left orbit (Fig. 6). A tentative diagnosis of an epidermoid cyst was made and operation suggested. Professor Hugh Cairns (Oxford) at whose clinic the patient attended, and with whose kind permission this case is appended, removed a tumour which proved on histological examination to be a typical eosinophilic granuloma.

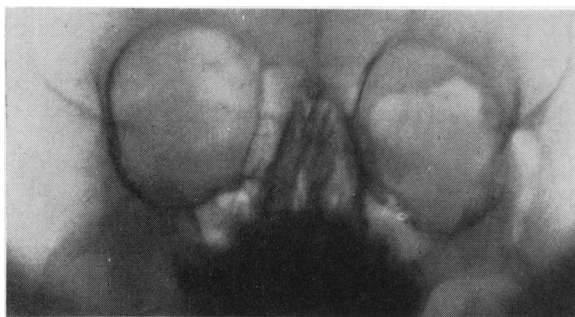

FIG. 6.—Case 2. Marked destruction of left orbit and left temporal bone.

(b) An announcement of yet another case of eosinophilic granuloma of the orbit without any bone changes which is shortly to be published has been made by Babel (1950).

#### REFERENCES

- BABEL, J. (1950). *Ophthalmologica, Basel*, **120**, 63.  
DANDY, W. E. (1941). "Orbital Tumors". Oskar Piest, New York.  
DUNDON, C. C., WILLIAMS, H. A., and LAIPPLY, T. C. (1946). *Radiology*, **47**, 433.  
FORREST, A. W. (1949). *Arch. Ophthal., Chicago*, **41**, 198.  
HANSEN, P. B. (1949). *Acta radiol., Stockh.*, **32**, 89.  
JAFFE, H. L., and LICHTENSTEIN, L. (1944). *Arch. Path. Lab. Med.*, **37**, 99.  
LICHTENSTEIN, L., and JAFFE, H. L. (1940). *Amer. J. Path.*, **16**, 595.  
PFEIFFER, R. L. (1943). *Amer. J. Ophthal.*, **26**, 724, 826, 928.  
WALTHARD, B., and ZUPPINGER, A. (1949). *Schweiz. med. Wschr.*, **79**, 618.