

**ANATOMICAL STUDY OF SCHLEMM'S  
CANAL AND AQUEOUS VEINS BY  
MEANS OF NEOPRENE CASTS\***

**PART I. AQUEOUS VEINS**

BY

**NORMAN ASHTON**

*From the Department of Pathology, Institute of Ophthalmology, London*

THE purpose of this paper is to report a new technique which has been devised to demonstrate the anatomy of Schlemm's canal, its immediately related vessels and the aqueous veins in particular.

It has long been recognized that an exact knowledge of the anatomy of Schlemm's canal, apart from being of academic interest, is pre-requisite to the proper understanding of those physiological and pathological processes which are concerned with the elimination of intra-ocular fluids. Among the many important papers on the subject are those of Hovius (1716), Fontana (1781), Schlemm (1830), Retzius (1834), Rouget (1856), Schwalbe (1870), Leber (1873), Waldeyer (1875), Rochon-Duvigneaud (1892), Troncoso (1905), Henderson (1908), Maggiore (1917), Dvorak-Theobald (1934), Swindle (1937), and Kiss (1943). The work of most of these writers has been so well reviewed by Dvorak-Theobald (1934) that there is no purpose to be served by re-capitulating it here. All their studies were made upon specimens injected with dyes or Indian ink, reconstructed serial sections, or combinations of the two methods. While the use of serial sections is a valuable technique in this type of investigation, it is one which has a number of serious disadvantages. It is exceedingly tedious and time-consuming, thus limiting the number of eyes which can be examined; furthermore, the specimen is distorted in varying degrees in the process of fixation and cutting, and models constructed from such preparations may, therefore, be most misleading.

The present work began with an anatomical study of aqueous veins and, since there are no known histological characteristics by which they may be recognized in a section, it was decided to attempt to prepare Neoprene casts of Schlemm's canal in eyes removed at operation in which aqueous veins had been previously identified and marked with a loop suture. Neoprene latex was first introduced for renal vascular studies by Lieb (1940), and has since been used by

---

\* Received for publication February 12, 1951.

Shonyo and Mann (1944), Duff and More (1944), and Trueta and others (1947), but this is the first occasion upon which its use has been reported in studies of the vessels of the eye. The technique described below has proved successful, and it has not only been possible to demonstrate the origin of aqueous veins in four cases, but the specimens have also shown the anatomy of Schlemm's canal in a most striking way. Much of the work carried out by previous investigators is completely confirmed by the Neoprene casts, but the casts also show that many writers gained a faulty or incomplete conception of the true anatomy of the canal and its branches from serial sections. Our method is not, of course, without its own limitations; for instance, arteries and veins cannot be distinguished as in stained sections, filling defects may be misinterpreted, and the final preparations are extremely delicate and difficult to manipulate. Nevertheless, these disadvantages work in a different direction from the disadvantages of serial sections, and the two methods are thus complementary to each other. This technique promises, therefore, to be of value in a wider field than that for which it was originally designed.

#### TECHNIQUE

##### APPARATUS (Fig. 1).

- (1) Stereoscopic microscope.\* (The stage is removed and replaced by a transparent perspex platform supported from the screw stand, so that the microscope may be moved without disturbing the specimen).
- (2) Direct source of illumination† (either from an electric-light fitting with condensing lenses mounted on universally adjustable arms which can be attached to the microscope, or from a separate high-power low-voltage filament lamp).
- (3) Transparent circular perspex platform with gutters and drainage holes.
- (4) Black perspex tray with rubber drain to sink.
- (5) Adjustable screw stand with ball-jointed arms and clamp.‡
- (6) Fine glass capillary cannulae as shown in Fig. 2 (easily prepared in the laboratory).
- (7) Small Woulff's bottles, connected to cannulae and pump, for irrigation (alternatively the water-irrigating cannula may be connected directly to the water tap).
- (8) Electric pump (Edward's rotary vacuum pump and compressor, Type IV, adjusted to give a pressure of 10 lb.).

**MATERIAL.**—The technique is applicable to unfixed eyes excised at operation or to *post-mortem* material taken within a few hours after death; if *post-mortem* degeneration is present the injection fluid may rupture the vessel walls.

**METHOD.**—The following instructions apply when it is required to demonstrate the anatomy of aqueous veins; when Schlemm's canal alone is to be studied, proceed from Section 5.

\* Cooke Troughton and Simms, Ltd., Stand M6020. † Cooke Troughton and Simms, Ltd., M6443 or M1805. ‡ C. F. Palmer, London.




FIG. 1.—Apparatus used for the injection of Schlemm's canal.

- |                                |                                |
|--------------------------------|--------------------------------|
| A. Stereoscopic microscope (1) | G. Drainage tube to sink (4)   |
| B. Palmer adjustable stand (5) | H. Woulff's bottle (7)         |
| C. Ball-jointed arm (5)        | J. Tubing to pressure pump (8) |
| D. Cannulae. Types A and B (6) | K. Running tap water (7)       |
| E. Perspex platform (3)        | L. Electric light fitting (2)  |
| F. Black Perspex Tray (4)      |                                |

(1) A patient is selected in whom the eye is to be enucleated, preferably for a posterior pathological condition in which the anterior vessels are not congested or otherwise abnormal; *e.g.*, a choroidal melanoma.

(2) An aqueous vein identified by the use of the slit lamp is recorded by a drawing and, if possible, a photograph.

(3) At the operation, immediately before the eye is enucleated, a fine suture of black silk or tantalum wire is passed around the aqueous vein and tied loosely so that the flow of aqueous is not impeded. At this stage it is important to avoid lacerating vessels with the needle; otherwise when the Neoprene is injected it will leak out and obstruct the view of the vessel to be studied.

(4) The eye is now enucleated and as much conjunctiva is removed in the region of the aqueous vein as is compatible with a satisfactory repair of the orbital cavity. The eye is placed at once into heparin water to prevent coagulation of blood within the vessels and to lyse the red cells

(approx. 3,000 units heparin per ml.). The fact that the cornea may be required for graft purposes interferes with the technique only in that the necessary delay allows time for the blood to clot in the vessels. If the cornea must be taken, the method can still be used, but the results are likely to be less satisfactory.

(5) Mark the cornea with a superficial linear incision at 12 o'clock. It is essential that this incision should be accurate so that it may subsequently be possible to orientate the cast.

(6) Cut the eye coronally through the ora serrata. If a histological report is required, the posterior portion should be placed in 10 per cent. formol saline, but on no account must fixative be allowed to come into contact with the anterior portion.




FIG. 2.—Types of cannulae used for Neoprene irrigation (A) and injection (B).

(7) Remove the lens, iris, and ciliary body. Alternatively, if the deep connections of Schlemm's canal are to be studied, the iris and ciliary body should be left *in situ* and the pigment removed with a camel-hair brush under running water. Until the intricacies of

the technique are mastered it is easier in the first instance to carry out the injection with the iris and ciliary body removed as this allows a clear view of the canal.

(8) Cut to the centre of the cornea through the corneo-scleral junction at 12 o'clock, along the incision previously made.

(9) Under the stereoscopic microscope (eyepiece x 7, objective x 1.25, giving a magnification of x 8.75), a fine glass capillary cannula (Fig. 2, Type A), connected to a water-tap and held in the adjustable clamp, is inserted into the open end of Schlemm's canal (Figs 3 and 4). Contrary to what might be supposed, this procedure is a simple one and the open end of the canal can easily be seen in the posterior part of the pigment band of the uveo-scleral meshwork. The canal is irrigated with water in both directions for about 2 hours until all the blood is washed out of the pericorneal vessels.

(10) A bulb capillary glass cannula (Fig. 2, Type B), with the capillary end bent at right angles and pointed sideways towards the operator, is now filled with Neoprene latex coloured red with carmine\*, and is attached to an electric pump.

The cannula, held in the clamp, is now inserted into Schlemm's canal, and the Neoprene is injected for about one minute or until the canal is seen to have filled throughout its extent. This should be carried out

\* It is necessary to colour the Neoprene in order that the degree of filling of the vessels may be seen, but for photographic purposes it is preferable that the final cast should be white; carmine bleaches in the subsequent process of tissue digestion and was selected for this reason.

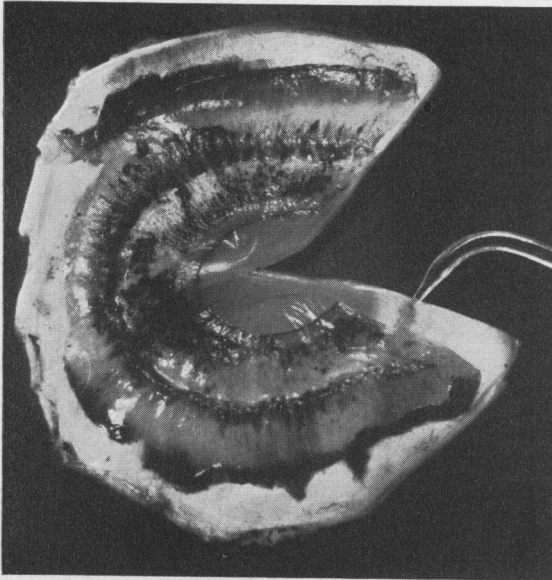


FIG. 3.—Anterior part of the eye cut to the centre of the cornea through the corneo-scleral junction at 12 o'clock. The cannula is inserted into the open end of Schlemm's canal.

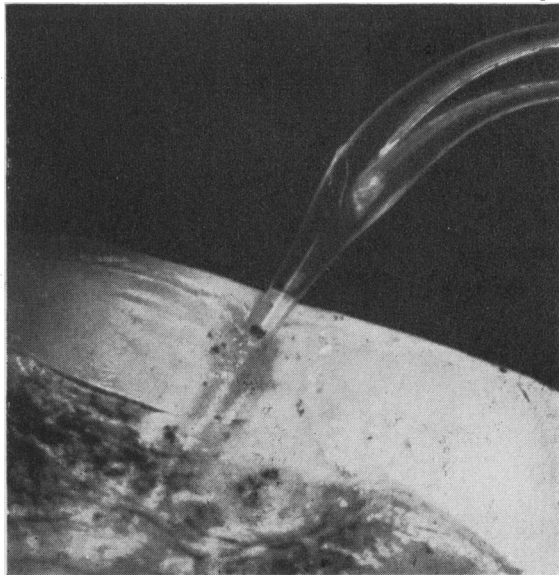


FIG. 4.—High-power view of glass cannula in Schlemm's canal, seen in Fig. 3.

under a stream of water so that any escaping Neoprene is immediately washed away and its adherence to the specimen is thus reduced to a minimum. When injection is complete the episcleral, limbal, and conjunctival vessels may be seen to be fully injected (Fig. 5, overleaf).

*(It was found that the aqueous veins were also filled, Figs 8 and 10).*

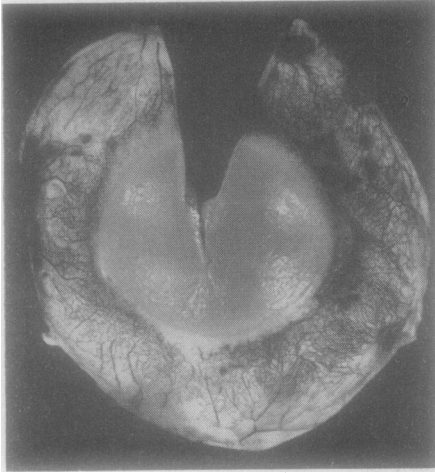

FIG. 5.—Pericorneal vessels after an injection in which black Neoprene was used.

FIG. 6.—Injected specimen placed in dish containing pepsin in N/10 hydrochloric acid and incubated at 37 C. for 48 hours.

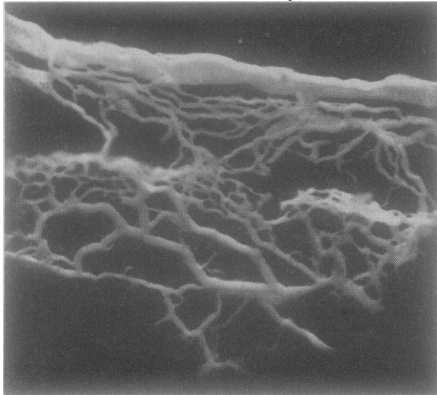
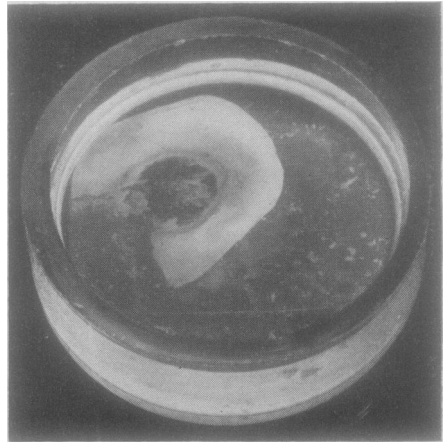


FIG. 7.—Part of a Neoprene cast of Schlemm's canal showing collector channels passing into the deep scleral plexus from which intrascleral branches pass to the episcleral plexus. Mounted in gelatin.  $\times 18$ .

(11) The injected specimen is now placed in a small dish containing pepsin in N/10 hydrochloric acid and incubated at 37° C. for 48 hours (Fig. 6). At the end of this time the specimen will be seen to be softened and partially digested (the cornea will have disappeared) and much can be learnt by examining the specimen at this stage while the cast can still be seen through the translucent tissues in its normal position. Neoprene mixed with Indian ink makes an ideal injection fluid for studies at this stage. The pepsin solution is then carefully replaced by a solution of trypsin in 10 per cent. sodium bicarbonate for a further 48 hours. The scleral tissue disintegrates but does not completely disappear. (The specimen may be corroded in hydrochloric acid but we abandoned this method because it led to distortion and sticking of the cast).

(12) The specimen, still in the trypsin fluid, is now placed under the stereoscopic microscope and the gelatinous, semi-digested tissue may easily be teased gently from the cast. The trypsin solution is now carefully replaced with water: the cast must not be allowed to dry, otherwise the minute twigs adhere together permanently and their spatial arrangement is lost.

At this stage, with fine dissecting instruments, the anatomy can be made out and recorded by drawing or photography. From these records large-scale models may later be constructed with wire and plasticine (Fig. 13, p. 301).

(13) A permanent mount of the cast is prepared as follows:

The specimen is carefully floated into a large petri dish. It is held in the required position beneath iced water and warm, cleared 20 per cent. gelatin is run on to it with a teat pipette; as the gelatin sets the cast is held in position. The water is then poured off and the specimen is exposed to formalin vapour which hardens the gelatin and so prevents its subsequent solution and infection with moulds (Fig. 7).

Finally, the specimen is mounted in more gelatin on a concave slide and the cover-glass is sealed by Rousselet's method (two or three applications of a solution containing two parts of Damar resin in benzol and one part of gold size, followed by one application of pure gold size).

(14) Substances other than Neoprene (such as vinolyte, Marco resin, or perspex) may be used, but the technical difficulties are much greater and we have not so far succeeded in overcoming them.

The above technique was used throughout the investigation reported in this paper. It has recently been found, however, that the following modification gives better results:

After the canal has been irrigated with water (Section 9) 10 per cent. formol saline is pumped in both directions for about 2 minutes. The specimen is then placed in slow running water overnight in order to remove the formalin which would otherwise rapidly coagulate the Neoprene. Next morning the canal is irrigated with water before the Neoprene is injected. This modification ensures that the canal and its connections are fixed in the fully dilated position, and tends to reduce the permeability of the vessel walls; the procedure thus results in a more perfect cast with fewer artefacts.

## THE ANATOMY OF AQUEOUS VEINS

The discovery of aqueous veins independently by Ascher in 1942 and by Goldmann in 1946 has tended to confirm the hitherto controversial belief that there is a continuous drainage of aqueous from the anterior chamber; that the veins contained aqueous humour was made probable by Ascher's studies and was proved by Goldmann's intravenous fluorescein-injection experiments. In the literature on aqueous veins which has accumulated since 1942, the demonstration of the exact anatomy of these vessels has not, curiously enough, been seriously attempted: most workers have been content to assume, from the considerable clinical evidence, that they arise directly or indirectly from the canal of Schlemm. Maggiore (1917) and Theobald (1934) have both stated that there are between twenty and thirty efferent branches of Schlemm's canal (a statement we shall later discuss) lying midway in the thickness of the tissue of the corneo-scleral junction, and "as a rule they are greatly flattened". These venules were said to reach their destination in the intrascleral venous plexus by a course that is sometimes straight but often rather tortuous, occasionally sending a branch to the episcleral vessels at the limbus. Ascher (1942) believes

*that these latter branches are to be considered as the anatomic substrata of at least a great many if not all of the aqueous veins . . . whether histologic differences could be found between vessels recognized intra-vitam to be aqueous veins and ordinary vessels of the peri-corneal region is a question worth investigation.*

Weinstein (1950) is of the opinion that laminated aqueous veins are probably continuations of the thin veins of the ciliary plexus described by Kiss (1943), where the blood and aqueous must have mixed together; he advances arguments for believing that a discharge system other than Schlemm's canal exists. Henderson (1950) maintains that aqueous veins should not be considered as separate entities as their special appearances are simply due to a continuation on the surface of the perivascular spaces which surround all vessels in the sclera, while from the clinical aspect such veins do not account for the disappearance of a hyphaema or hypopyon when there is no tension. Trantas (1950) has failed to confirm Goldmann's fluorescein experiments; he holds that laminary veins are an ordinary phenomenon and that they are in no way related to the elimination of the aqueous fluid. There is, therefore, sufficient speculation and difference of opinion to indicate the need for a purely anatomical study of aqueous veins, and the purpose of this research, which is still in progress, is to answer the question:

*What is the exact origin and course of aqueous veins and in what way do they differ anatomically from the other vessels of the pericorneal region?*



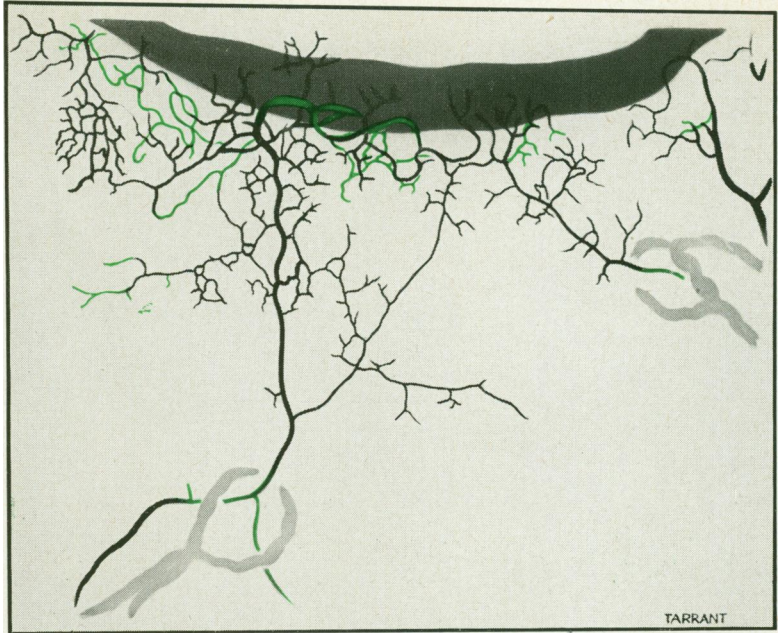


FIG. 9.—Case 1. Drawing from Neoprene cast shown in Fig. 8. The aqueous vein on the left can be seen arising directly from Schlemm's canal by a hook-shaped origin, while the aqueous vein on the right does not arise directly from the canal but is connected to it *via* the deep scleral plexus, shown in green.

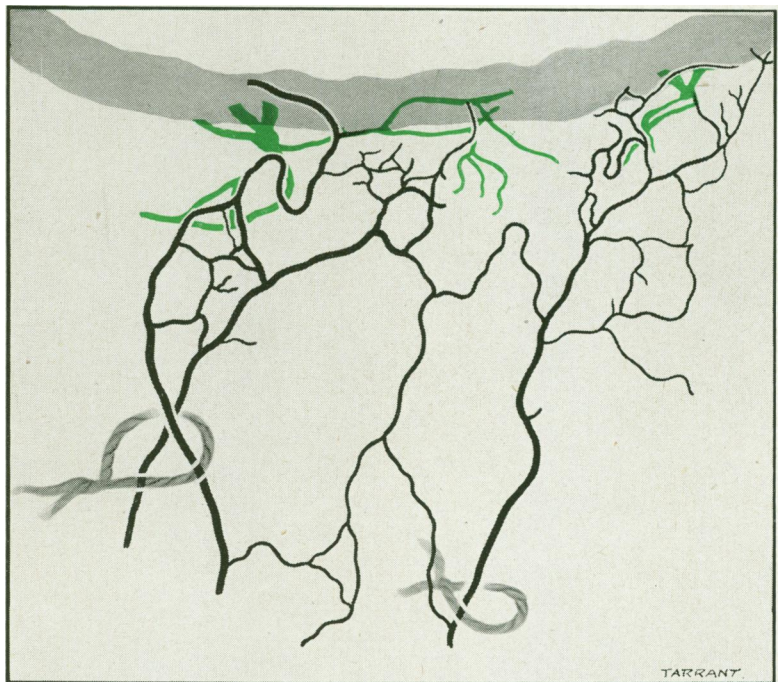


FIG. 12.—Case 2. Drawing from a Neoprene cast shown in Fig. 10. The deep scleral plexus is shown in green. The aqueous vein on the left can be seen to arise directly from Schlemm's canal by a hook-shaped origin, while the aqueous vein on the right does not connect directly with the canal but is connected with a communicating branch between the superficial and deep scleral plexuses.

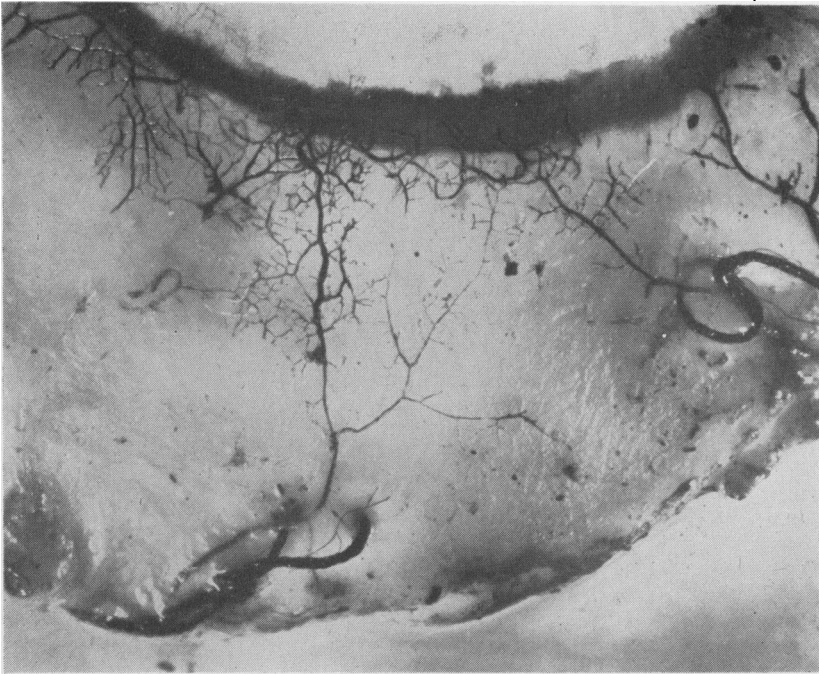


FIG. 8.—Case 1. Low-power view of two aqueous veins after injection of Schlemm's canal with black Neoprene. The two black silk sutures may be seen around the vessels. The photograph was taken before the tissue was removed by corrosion. The details of the origin of the aqueous veins are shown in Fig. 9.

### RESULTS

The recognition of the aqueous veins and their identification with a loop suture was carried out in all cases by Mr. Arthur Lister London, and we gratefully acknowledge his valuable assistance in this important preliminary step.

**Case 1.** Male aged 67 (patient of Mr. A. G. Cross), melanoma of the choroid. Striated aqueous veins were seen situated at 6 and 7 o'clock; a black silk ligature was tied loosely around each vessel. The eye was enucleated and the cornea taken for grafting. The anterior part of the eye was removed and a radial cut to the centre of the cornea was made at 4 o'clock. Neoprene coloured black with Indian ink was then injected into Schlemm's canal, and a photograph was taken (Fig. 8). Both aqueous veins filled with Neoprene.

The specimen was now corroded in hydrochloric acid gas and when the tissue had completely corroded the larger of the two aqueous veins (7 o'clock) was seen to arise directly from Schlemm's canal by a hook-shaped origin as shown in the diagram (Fig. 9). The smaller vein (6 o'clock) did not communicate directly with Schlemm's canal, but connected with a communicating branch between the superficial and deep scleral plexus.

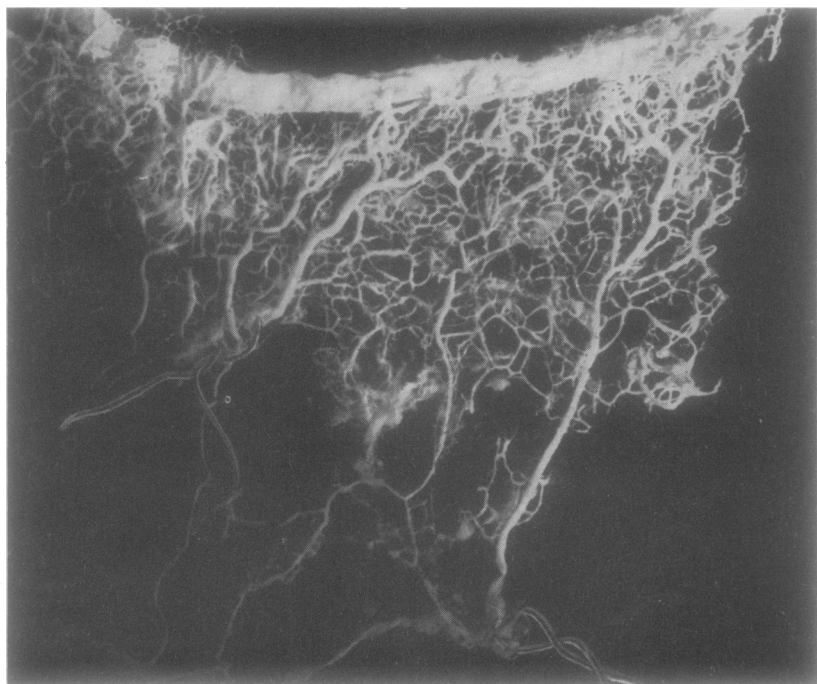


FIG. 10.—Case 2. Neoprene cast of Schlemm's canal showing sector in which two aqueous veins were ligatured with tantalum wire loops still to be seen *in situ*. Details of the origin of the aqueous veins in this case are shown in Figs 11, 12 (see colour plate), and 13.

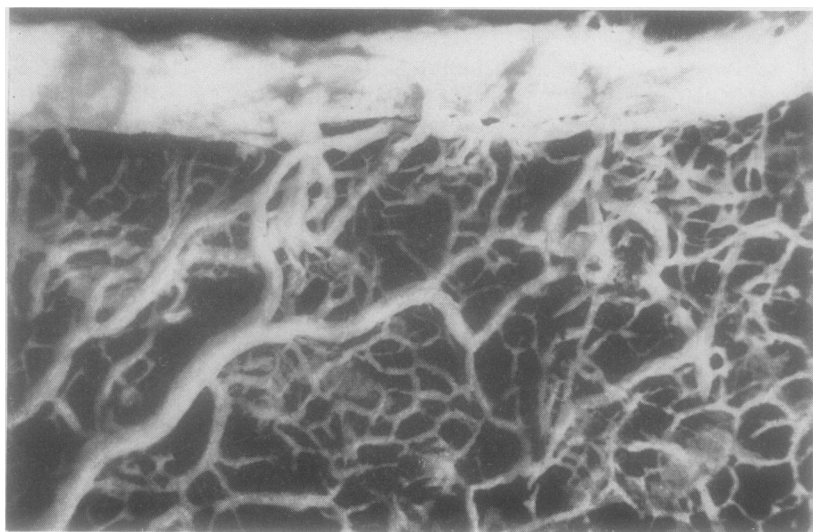


FIG. 11.—Case 2. High-power view of Neoprene cast showing hook-shaped origin of one of the aqueous veins. Note also a cruciate varicose type of collector channel from Schlemm's canal.

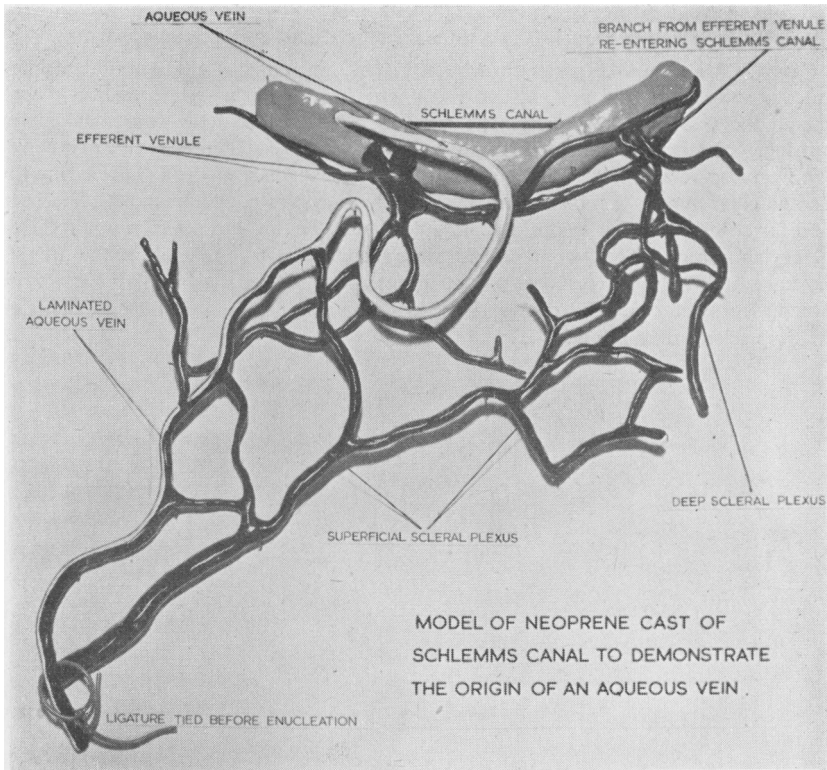


FIG. 13.—Case 2. Plasticine and wire model made from Neoprene cast shown in Figs 10 and 11, demonstrating the hook-shaped origin of an aqueous vein.  $\times 16$  normal size (original model  $\times 100$ ).

**Case 2.** Female aged 38 (patient of Mr. C. Dee Shapland), melanoma of the ciliary body. Striated aqueous veins were seen situated at 7 and 8 o'clock; a tantalum wire ligature was tied loosely around each vessel. The eye was enucleated and the cornea taken for grafting. The anterior part of the eye was removed and a radial cut to the centre of the cornea was made at 12 o'clock. Neoprene coloured red with carmine was injected into Schlemm's canal. Both aqueous veins filled with Neoprene. The specimen was now digested in pepsin followed by trypsin. The aqueous vein situated at 8 o'clock was seen to arise directly from Schlemm's canal by a hook-shaped origin as shown in the photographs, diagram, and model (Figs 10, 11, 12, and 13). The aqueous vein situated at 7 o'clock did not communicate directly with Schlemm's canal but connected with a communicating branch between the superficial and deep scleral plexus (Fig. 12).

**Case 3.** Male aged 61 (patient of Mr. C. Dee Shapland), melanoma of the choroid. A striated aqueous vein was seen at 9 o'clock; a tantalum wire ligature was tied loosely around it. The eye was enucleated and the cornea taken for grafting. The anterior part of the eye was removed and a radial cut was made to the centre at 12 o'clock. Neoprene coloured red with carmine was injected into Schlemm's canal. The aqueous vein filled with Neoprene. The specimen was then digested in pepsin and trypsin.

The aqueous vein did not communicate directly with Schlemm's canal but it connected with a communicating branch between the superficial and deep scleral plexus.

**Case 4. Male aged 42** (patient of Mr. A. Lister), melanoma of the choroid. Striated aqueous veins were seen at 4, 6, and 7 o'clock; a tantalum wire ligature was placed around the vessel at 4 o'clock. The eye was enucleated and the cornea taken for grafting. Neoprene coloured red with carmine was injected into Schlemm's canal. The ligatured vessel filled with Neoprene. The anterior part of the eye, including the iris and ciliary body, was then digested in pepsin and trypsin. Since the eye had been used for corneal grafting a considerable time elapsed before the specimen was received in the laboratory. The Neoprene cast was, therefore, not complete but the area of the aqueous vein was fortunately fully injected. This aqueous vein did not arise directly from the canal but connected with it by way of communicating branches to the deep scleral plexus (Fig. 14).

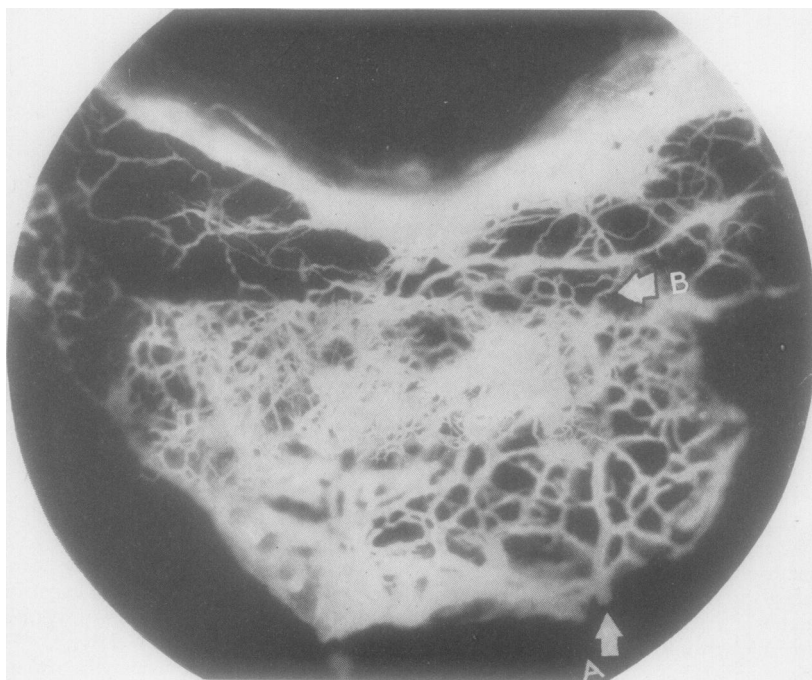


FIG. 14.—Case 4. Neoprene cast showing aqueous vein (A) in the episcleral plexus. It does not communicate directly with Schlemm's canal but is connected with it by a communicating intrascleral branch (B) to the deep scleral plexus. Mounted in gelatin.  $\times 17$ .

#### DISCUSSION

By this technique we have so far studied four cases in which six aqueous veins were ligatured, and our results were as follows:

(1) Two of the aqueous veins were seen to arise *directly from Schlemm's canal* by a hook-shaped type of origin (Cases 1 and 2).



(2) The other four aqueous veins did not arise directly from Schlemm's canal but were *connected to it by an anastomotic branch between the superficial and deep scleral plexus* (Cases 1, 2, 3, and 4).

(3) All the aqueous veins were of the striated or laminated variety.

Our findings thus confirm Ascher's belief that the occasional branches between the superficial and deep scleral plexuses are the anatomic substrata of at least a great many of the aqueous veins. Since all the aqueous veins were of the striated variety this conclusion is not in accord with Weinstein's suggestion that such vessels are direct continuations of the ciliary plexus; it does not, however, disprove his theory of the importance of aqueous drainage from the uvea, for the casts clearly show that vessels from the ciliary plexus do in fact connect either directly with Schlemm's canal or with the deep scleral plexus. Nor can it be said that our limited results dispose of the possibility that certain aqueous veins may not derive their aqueous from Schlemm's canal. Nevertheless, the results indicate that all striated aqueous veins probably arise directly or indirectly from the canal. It is hoped that in the near future it will be possible to obtain a pure aqueous vein for study by this method and it is expected that a similar origin will be found.

## REFERENCES

- ASCHER, K. W. (1942). *Amer. J. Ophthal.*, **25**, 1174.  
 DUFF, G. L., and MORE, R. H. (1944). *J. tech. Methods*, **24**, 1.  
 DVORAK-THEOBALD, G. (1934). *Trans. Amer. ophthal. Soc.*, **32**, 574.  
 FONTANA, F. (1781). "Traité sur le venin de la vipère". Florence.  
 GOLDMANN, H. (1946). *Ophthalmologica, Basel*, **111**, 146.  
 HENDERSON, T. (1908). *Trans. ophthal. Soc. U.K.*, **28**, 167.  
 ——— (1950). Personal communication.  
 HOVIUS, J. (1716). "Tractatus de circulari humorum motu in oculis". Lugduni Batavorum (Louvain).  
 KISS, VON F. (1943). *Ophthalmologica, Basel*, **106**, 225.  
 LEBER, T. (1873). *Graefes Arch. Ophthal.*, **19**, pt. 2, p.91.  
 LIEB, E. (1940). *J. tech. Methods*, **20**, 48.  
 MAGGIORE, L. (1917). *Ann. Ottalm.*, p. 317.  
 ROCHON-DUVIGNEAUD (1892). *Arch. Ophtal., Paris*, **12**, 732.  
 SCHLEMM, F. S. (1830). In J. N. Rust, "Theoretisch praktisches Handbuch der Chirurgie", vol. 3, pp. 403-5. Berlin.  
 SHONYO, E. S., and MANN, F. C. (1944). *Arch. Path.*, **38**, 287.  
 SWINDLE, P. F. (1937). *Arch. Ophthal., Chicago*, **17**, 420.  
 TRANTAS, N. (1951). *XVI Conc. ophthal. Acta, London 1950*.  
 TRONCOSO, M. U. (1909). *Ann. Oculist., Paris*, **142**, 237.  
 TRUETA, I., BARCLAY, A. E., DANIEL, P. M., FRANKLIN, K. J., and PRICHARD, M. M. L. (1947). "Studies of the Renal Circulation". Blackwell, Oxford.  
 WALDEYER, H. (1874). In A. Graefe and T. Saemisch "Handbuch der gesammten Augenheilkunde", vol. 1, p. 248.  
 WEINSTEIN, P. (1950). *British Journal of Ophthalmology*, **34**, 161.

(This study is to be continued in a future issue of this Journal.)