

ACQUIRED HOLE IN THE DISK*

BY

O. GAYER MORGAN

London

HOLES in the disk are usually considered to be of congenital origin, though in the published articles which deal with collected series of cases, it has been suggested that some of those described might have a different aetiology. The following case is of interest because it shows conclusively that a typical hole can be produced by some pathological condition occurring in a perfectly normal eye.

CASE REPORT

An Army officer, 21 years of age, was first seen by me in December, 1929. He had 6/5 vision in each eye, with no appreciable error of refraction, and his media and fundi were found to be perfectly normal.

In March, 1933, he came back complaining that a month previously, with his right eye, people's faces looked as if they had a bulge on the right side. He had seen an Army oculist who reported that at first the disk looked slightly oedematous and the veins engorged, but that this had rapidly subsided. He had had a general examination, including a blood test which was negative, and his teeth, sinuses, etc., had been passed as normal.

Vision in the right eye was 6/6, and there was a relative scotoma for colours—objects looked dull instead of bright, and linear objects had a kink in them. There was no pain on movement, or tenderness on pressure over the the globe.

The right disk is shown in Fig. 1 (overleaf). There seemed to be a hollowing out of the temporal side, with what appeared to be a newly-formed temporal crescent (not present in the other eye), and two faint ridges enclosing an area of slight swelling. Involvement of the macula at the apex of the inner bulge would account for the metamorphopsia. It looked as if there must be something in the temporal edge of the nerve head just outside the globe, causing a retraction of the temporal side of the nerve head, and a bulging forward of the sclerotic and other tissues with some dragging away of these tissues from the nerve head (Fig. 2, overleaf).

The appearance suggested a gumma or tuberculoma, or possibly a vascular tumour or neurofibroma. It was unlikely that a plaque of disseminated sclerosis could produce such an effect. A further full investigation revealed nothing, and he was given no treatment.

One month later the condition was almost unchanged though there seemed to be some faint whitish dots on the raised area. Vision was 6/6. The vitreous was perfectly clear, and there was slight enlargement of the blind spot.

* Received for publication February 20, 1951.

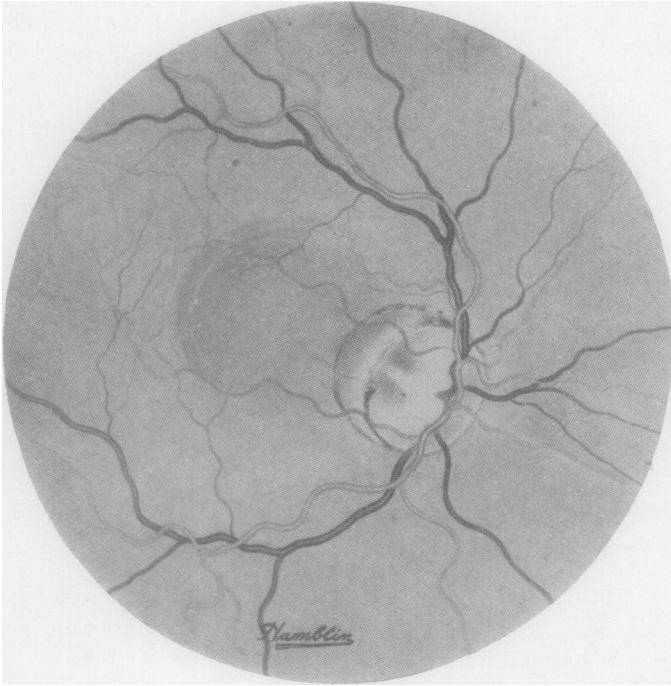


FIG. 1.—Fundus in 1933 showing newly formed temporal crescent and swelling at posterior pole.

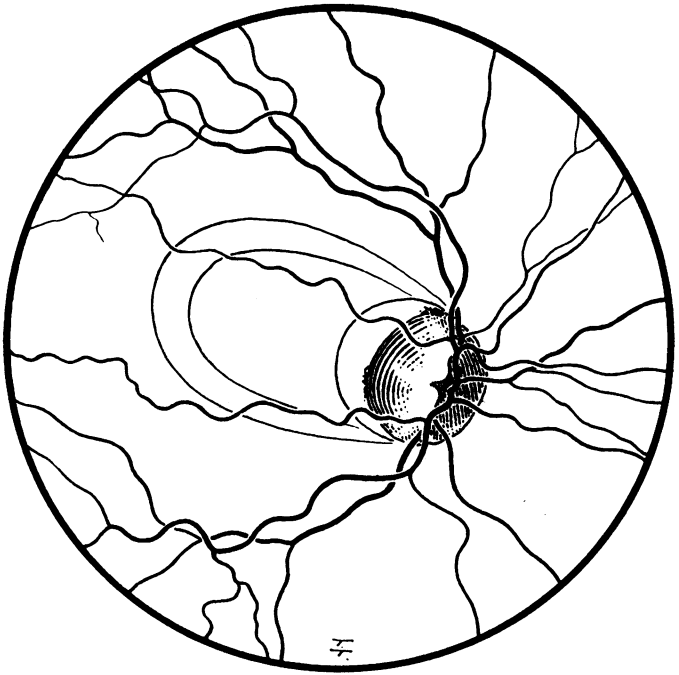


FIG. 2.—Diagrammatic sketch of the appearances shown in Fig. 1.

Three months later the outer ridge seemed to have disappeared and the inner one was less conspicuous. The bulge was less, but the whitish dots more noticeable, and the surface almost looked as if it was slightly wrinkled.

The patient then went abroad, and I did not see him again until 1940, seven years after the beginning of the trouble. Vision was then 6/5 (2) in the right eye and 6/5 full in the left, and the disk showed a typical hole. At the macula there was some faint disturbance with a little mottling, and a few dots of pigment (Fig. 3).

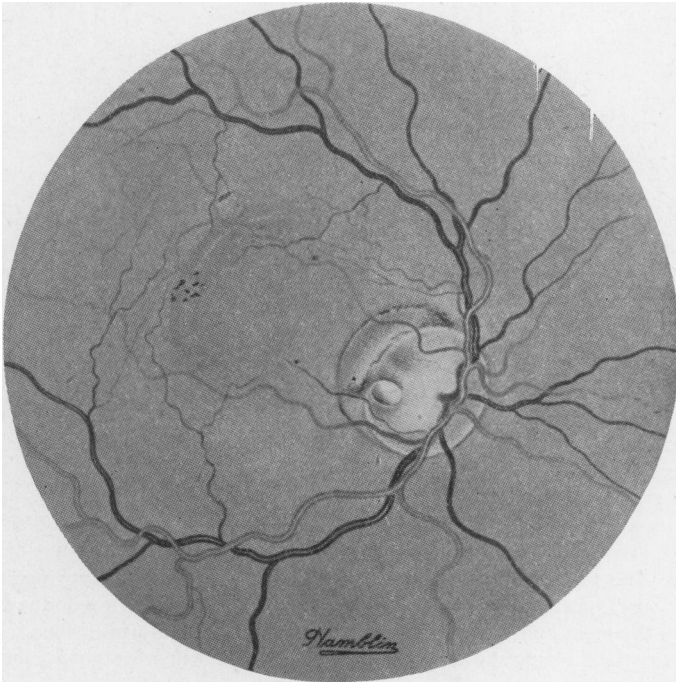

FIG. 3.—Fundus in 1940, showing hole in disk and mottling at the macula.

In 1948 the visual fields showed no loss in the periphery, and no scotoma of any sort on the Bjerrum screen. There was some enlargement of the blind spot towards the macula. The disk showed a deep pit with a depth of about three dioptres.

As most of the other recorded cases have presented very definite arcuate scotomata it may be that this is a point of differential diagnosis between the congenital and acquired macula hole.

At the present time—1951—the patient is perfectly fit and no developments have occurred of either a general or a local nature which could throw any light on the aetiology of the condition.

SUMMARY

A case of macular hole is described, which was seen to develop in a perfectly normal fundus.