

COMMUNICATIONS

FUNDUS DYSTROPHY WITH UNUSUAL FEATURES*

A HISTOLOGICAL STUDY

BY

NORMAN ASHTON AND ARNOLD SORSBY

London

IN an earlier communication (Sorsby and Mason, 1949), an account was given of a fundus dystrophy observed in five families, which showed onset at about the age of 40, dominant inheritance, and a progressive course. The earliest ophthalmoscopic reactions in this affection are a central retinal lesion showing oedema, haemorrhage, and exudates. Subsequently, there is considerable scarring, with exposure or actual sclerosis of the choroidal vessels over a wide area, and associated pigmentary proliferation, sometimes massive. The end stage, reached after the disease has run its course for about 30 years, is a more or less uniform, widespread atrophy of the choroid with some pigmentation. In the early stages, therefore, the affection simulates a toxic, metabolic, or vascular macular reaction; in the intermediate stages the lesion spreads peripherally and the evidence for choroidal sclerosis may be very marked; and in the end stages there is sub-total retinal and choroidal atrophy. The clear-cut features of this affection were observed in another family by Burn (1950), whose patients were mainly of late middle age and showed strikingly the intermediate feature of choroidal sclerosis.

In discussing the nature of the affection, the questions were raised whether this condition is related to "Doyne's choroiditis", and whether the primary disturbance is choroidal or retinal. The opportunity has now presented itself of examining histologically the eyes of the two affected members in one of the families recorded. Whilst this material has its value, it has also the considerable limitation that in this particular family the evidence for dominant inheritance was lacking. The two patients in question were elderly sisters, whose father had died at the age of 40†. The family history was incomplete, as the two sisters did not know of any relatives, but they were certain that both their parents had good sight. Since their mother died at the age of 64, it is unlikely that they inherited the affection from her, but one cannot exclude the father as poten-

*Received for publication August 7, 1951.

† Not 49 as originally recorded; the exact age has now been ascertained from the death certificate.

tially an affected individual. However, in the absence of definite evidence that there was in fact dominant inheritance in the case of these two sisters, the histological findings cannot be offered unreservedly as illustrative of the group as a whole.

MATERIAL

Miss G. C., the younger of the two sisters, died at the age of 70 on August 8, 1950.

Miss E. C., the elder sister, died at the age of 71 on March 13, 1951.

The *post-mortem* examinations were carried out by Dr. R. L. Janes, of the Royal Sussex County Hospital, Brighton.

Technique of Histological Study.—The two eyes from the first case (Miss G. C.) were fixed in Zenker's fluid, and those from the second case (Miss E. C.) were preserved in 10 per cent. formol saline. Serial sections were made from each of the four eyes, the following staining techniques being used:

haematoxylin and eosin,
 haematoxylin and Van Gieson,
 Mallory's phosphotungstic haematoxylin,
 Mallory's triple stain,
 orcein (Duval),
 Verhoeff's elastic stain and Van Gieson,
 Verhoeff's elastic stain and Masson's ponceau-fuchsin and light green,
 Wilder's silver stain,
 PAS (Hotchkiss-McManus),
 Kossa's stain for calcium,
 Turnbull blue for iron.

In the second case an attempt was made to inject the choroidal vessels with Indian ink *via* the posterior ciliary arteries, but, owing to the presence of clotted blood, this succeeded with the larger vessels only. From the same case a portion of choroid from the posterior fundus was examined flat, unstained, and stained with PAS (Hotchkiss-McManus) and with Verhoeff's elastic stain.

HISTO-PATHOLOGICAL FINDINGS

(1) Miss G. C. (aged 70 years).

Right Eye: Horizontal Sections.—The lens is not present in the section. The cornea and corneo-iridic angle are normal. Pingueculae are not present. Mild atrophic changes are present in the iris and the ciliary body is hyalinized. Throughout its entire extent the choroid is sclerosed and atrophic and shows mild focal lymphocytic infiltration. There is a marked loss of the chorio-capillaris which is absent posteriorly and atrophic anteriorly; the few remaining vessels show thickening of their walls with fibrous tissue replacement of their muscular coats (Fig. 1). Many large colloid bodies may be seen on Bruch's membrane (Fig. 2).

The main pathological features are confined to the posterior polar region, where clean-cut breaks may be seen in Bruch's membrane (Fig. 3, overleaf); through these gaps newly-formed blood vessels and serous fluid have extended from the choroid into the sub-retinal region, where they have formed a partially-organized, hyalinized vascular mass which blends imperceptibly with the degenerate retina and binds it firmly to the choroid. In these areas, the outer layers of the retina have been replaced with glial tissue, which merges with the hyaline element from the choroid, so that the inner nuclear layer is directly adherent to this sub-retinal proliferation. Bruch's membrane

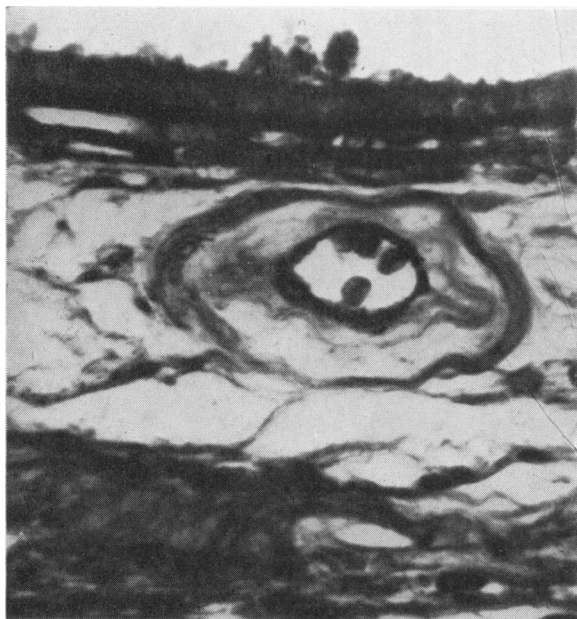


FIG. 1 (Case 1).—Right eye, showing choroidal atrophic changes and thickening of a vessel wall by fibrous tissue replacement of its muscular coats. Mallory stain. $\times 626$.

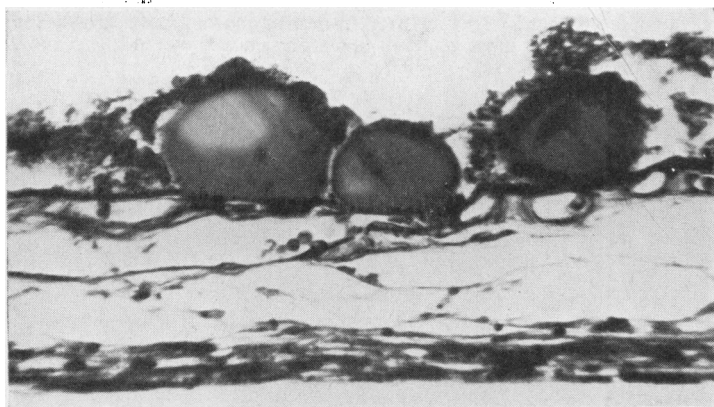


FIG. 2 (Case 1).—Right eye, showing large colloid bodies on Bruch's membrane. Note atrophic changes in choroid. Haematoxylin and eosin. $\times 360$.

itself is uniformly thickened so that it appears more conspicuous than in a section of a normal eye; it stains normally with haematoxylin and eosin and shows no basophilia. The pigment cells have exfoliated and migrated into the retina where they have aggregated into masses around the vessels in the sub-retinal newly-formed tissue (Fig. 4, overleaf). All these changes are most marked in the macular area. An early stage of the pathological process is seen at one point where, over a rupture in Bruch's membrane, an intact pigment epithelium is elevated and separated from the membrane by a thin eosinophilic amorphous layer.

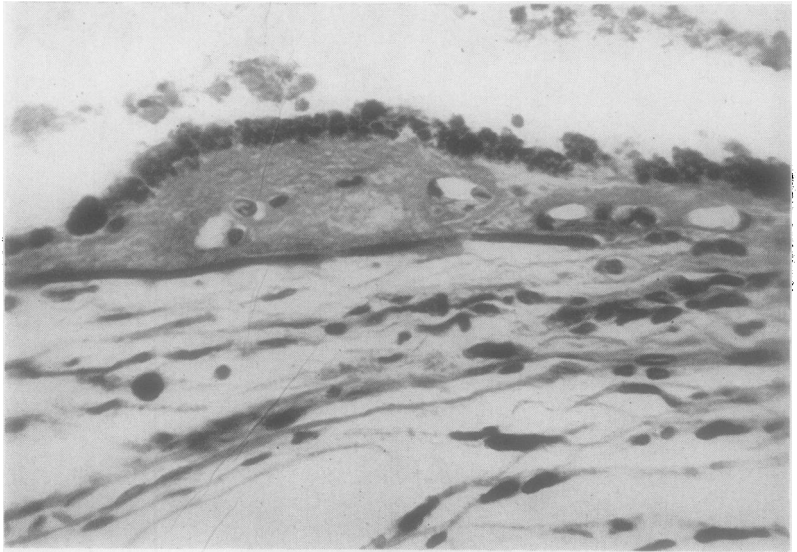


FIG. 3 (Case 1).—Right eye, showing “moth-eaten” appearance of Bruch’s membrane. To the right there is a wide gap in the membrane through which serous fluid has entered from the choroid and elevated the pigment epithelium. New vessels from the choroid have grown into this hyaline mass. Later stages of this process are shown in Figs 5 and 9. Haematoxylin and eosin. $\times 427$.

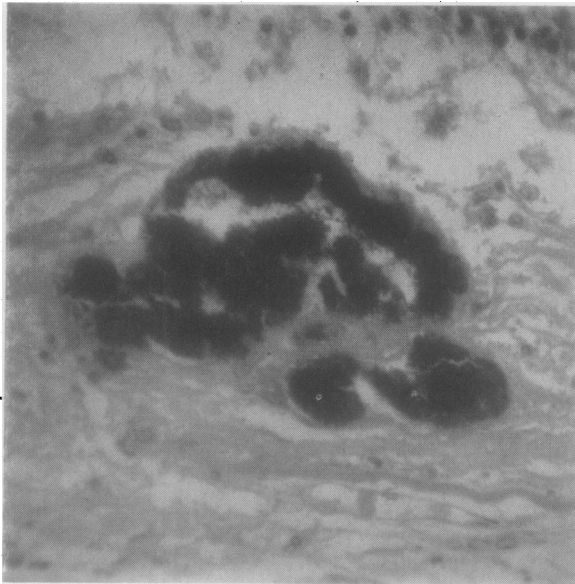


FIG. 4 (Case 1).—Right eye, showing mass of proliferating pigment in sub-retinal newly-formed tissue. Cuticular substance, staining positively with PAS, is associated with the pigment cells. PAS. $\times 369$.

There is a severe loss of ganglion cells, although many persist at the macula. Anteriorly, the retina shows little pathological change, there being only peripheral cystic degeneration and *post-mortem* disintegration of the rods and cones. The optic nerve appears normal, there is no abnormality of the sclera, and the posterior ciliary arteries appear normal.

Left Eye: Horizontal Sections.—These present an exactly similar histological picture except that the migration and aggregation of pigment are more marked and the destruction of the outer layers of the retina is more extensive.

(2) Miss E. C. (aged 71 years).

Left Eye: Horizontal Sections.—The cornea, corneo-iridic angle, and lens are normal. Pingueculae are not present. The iris stroma shows mild atrophic changes and the ciliary body shows early atrophy and hyalinization. Throughout its entire extent the choroid is atrophic and shows a mild focal lymphocytic infiltration; there is a marked diminution in the vascular element, and the remaining vessels show a moderate fibrous thickening of their walls without any apparent occlusion of the vessel lumen. While the paucity of vessels is most marked in the posterior fundus, the mural fibrous thickening is more evident anteriorly. Bruch's membrane is uniformly thickened throughout (Fig. 5), and, in the posterior polar region, it shows

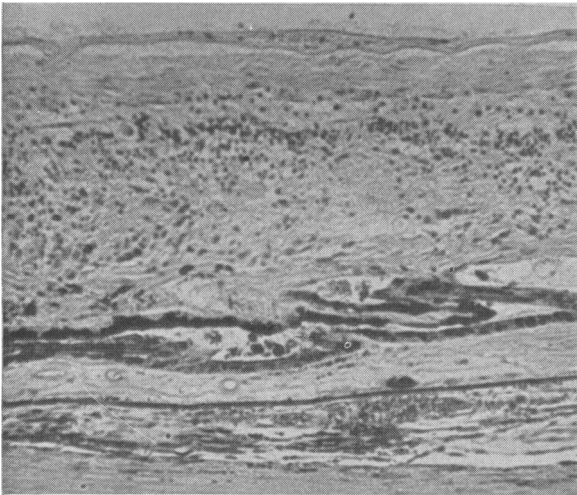


FIG. 5 (Case 2).—Right eye, showing choroidal atrophy, thickening of Bruch's membrane, and sub-retinal fibro-vascular tissue with aggregated pigment, which fuses with the gliosed and disorganized retina. Haematoxylin and eosin. $\times 111$.

numerous clean-cut breaks (Figs 6, 7, and 8) through which newly-formed vessels from the choroid, fibroblasts, histiocytes, and hyaline eosinophilic material, have extended to form a partially-organized, sub-retinal plaque of tissue which firmly binds the degenerate retina to the choroid. The retinal pigment has migrated into this mass where it may be seen clustered around the newly-formed vessels (Figs 5 and 9). Some of the eosinophilic hyaline material stains intensely with the PAS stain, and this suggests that it may be cuticular substance elaborated by the pigment epithelium. In the circumpapillary and macular regions, the ganglion cells have atrophied, and the outer nuclear layer of rods and cones have completely disappeared and have been replaced with glial tissue. These zones of choroido-retinal fusion are seen on either side of the disk but the sub-retinal new-formed tissue is most marked in the macular

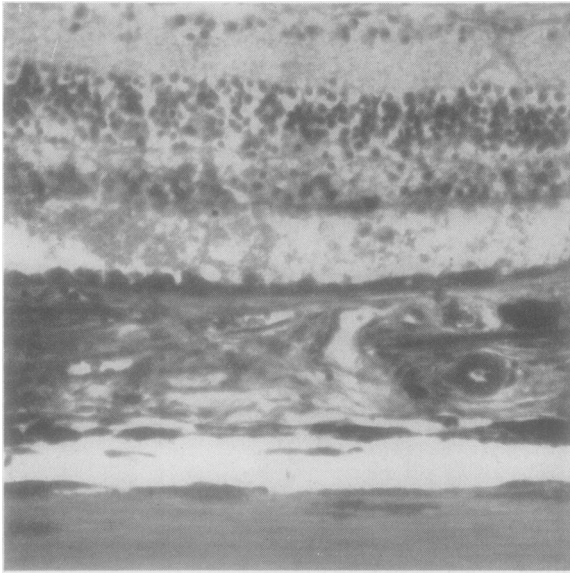


FIG. 6 (Case 2).—Left eye, showing vessels growing into the sub-epithelial tissue, through a wide gap in Bruch's membrane. The outer layers of the overlying retina are completely degenerate. Masson stain. $\times 198$.

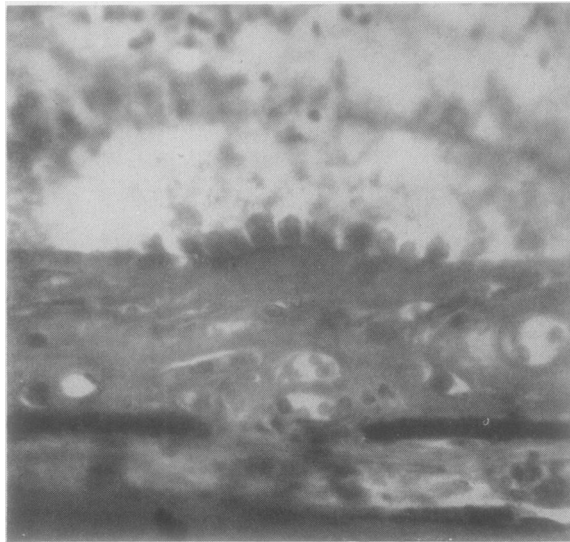


FIG. 7 (Case 2).—Left eye. High-power view of clean-cut break in the thickened Bruch's membrane. Note the newly-formed tissue beneath the pigment epithelium, containing vessels from the choroid. Masson stain. $\times 360$.

area. No colloid bodies are seen on Bruch's membrane. Anteriorly the retina shows only *post-mortem* degeneration of the rods and cones and peripheral cystic degeneration. The optic nerve and sclera show no abnormality; the posterior ciliary arteries appear normal.

Right Eye: *Flat Preparations* of the choroid, bleached with potassium permanganate followed by oxalic acid and stained with PAS (Hotchkiss-McManus), clearly showed the irregular craggy splits in Bruch's membrane; they were not related to the underlying

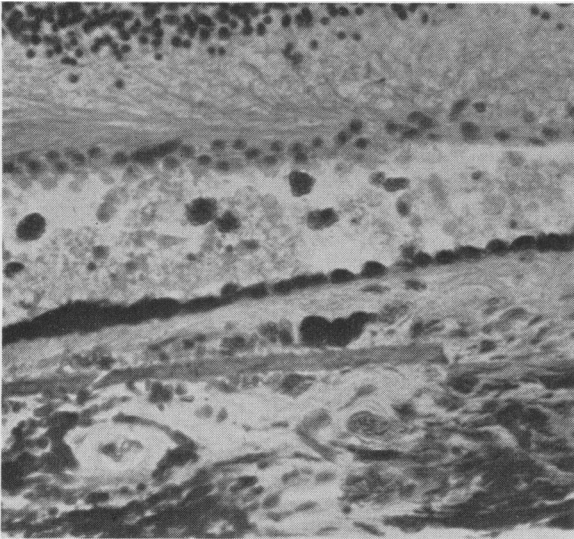


FIG. 8 (Case 2).—Left eye, showing two clean-cut breaks in Bruch's membrane with formation of vascularized tissue beneath detached pigment epithelium. Note also the loss of the layer of rods and cones and the outer nuclear layer. Early gliosis is seen in the remaining retinal tissue. Haematoxylin and eosin. $\times 240$

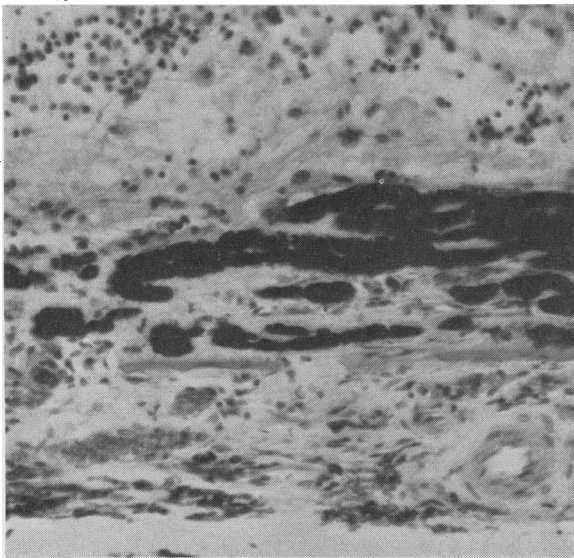


FIG. 9 (Case 2).—Left eye, showing wide gaps in Bruch's membrane. Into the vascularized sub-retinal tissue, originating from the choroid, the pigment epithelium has migrated and become aggregated around the vessels. The overlying retina is disorganized and gliosed. This is a later stage than Figs 3 and 8. Haematoxylin and eosin. $\times 180$.

vessels and in many cases ran across the vessels (Fig. 10). Flat preparations of the bleached choroid, stained with Verhoeff's elastic stain and examined flat with transillumination, also showed the irregular and branching nature of the ruptures in Bruch's membrane.

SUMMARY OF FINDINGS

The histological picture in all four eyes was thus almost identical, and there can be no doubt that the fundus dystrophy in the two sisters arose

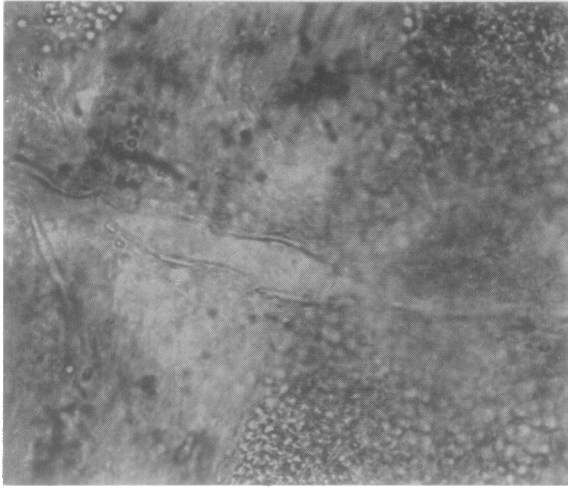


FIG. 10 (Case 2).—Right eye. Flat preparation of bleached choroid showing linear rupture of Bruch's membrane. PAS (McManus). $\times 360$

from an identical pathological process. The main pathological changes, which will subsequently be discussed separately, may be summarized as follows:

- (1) Sclerosis and atrophy of choroid with fibrous mural degeneration of remaining vessels (Fig. 1).
- (2) Numerous ruptures of Bruch's membrane in posterior fundus with degeneration of elastic layer in the same area (Figs 3, 6, 7, 8, and 9).
- (3) Sub-retinal newly-formed vascular tissue originating from the choroid, and related to the dehiscences in Bruch's membrane (Figs 3, 6, 7, 8, and 9).
- (4) Disturbance of pigmentary epithelium (Figs 4 and 5).
- (5) Destruction of outer layers of retina with glial replacement (Figs 5, 8, and 9).

CHOROIDAL CHANGES.—As already noted, the atrophy of the choroid has affected the vascular element most markedly, there being a great reduction in the number of vessels and widespread atrophy of the chorio-capillaris. The inter-vascular stroma is moderately sclerosed, and the remaining vessels show fibrous thickening of their walls: a change most marked anteriorly. The vessels are surprisingly free from arteriolosclerosis and their lumens are not reduced in calibre. The posterior ciliary arteries appeared normal in all sections.

In attempting to understand the pathogenesis of the fundus dystrophy it is important to assess the significance of these vascular changes. It should, therefore, be emphasized that the diminution of the number of vessels in the choroid was not greater than is commonly seen in the eyes of old people showing no associated changes in Bruch's membrane and no sub-retinal newly-formed tissue. It is to be noted, furthermore, that the fibrous mural degeneration was exactly comparable with that described by Cohen (1938) in focal choroidal sclerosis in a patient suffering from Paget's disease of bone; but he did not record any secondary changes in Bruch's membrane, as might have been expected in such a case, and, apart from depigmentation of the pigment epithelium, there were no retinal or sub-retinal changes. In our cases, the fibrous mural degeneration was

most marked anteriorly where Bruch's membrane and the retina showed no gross pathological changes, and we have frequently seen this type of vascular degeneration as a completely uncomplicated change in a number of eyes during the course of routine histological examination.

Though that possibility cannot be definitely excluded, it is unlikely that the fundus dystrophy in these two cases is the result of atrophy or sclerosis of the choroidal vessels. The choroidal vessels, stained with orcein and Verhoeff's elastic tissue stain, showed a marked reduction in elastic tissue; however, a control series of eyes showed variable staining of the vascular elastic tissue and caution must therefore be exercised in interpreting these changes as indicative of a generalized degeneration of elastic tissue.

INVOLVEMENT OF BRUCH'S MEMBRANE.—In all four eyes, Bruch's membrane was moderately and uniformly thickened so that it could be readily seen and easily studied (Fig. 5). There were numerous breaks in the posterior polar region and they were usually clean cut (as shown in Figs 7 and 8), but occasionally the free ends tapered to a point consisting of the cuticular layer, and in some areas, where rupture had not yet occurred, the membrane showed a "moth-eaten" appearance of its outer layer (Figs 3 and 9); these points suggest that the degeneration begins in the elastic lamina. Sections stained for elastic tissue (orcein) showed a granular degeneration and a patchy disappearance of the elastic layer in the posterior polar region; anteriorly the elastic tissue in the membrane stained normally. The fact that colloid bodies were found in one case only indicates that they are simply further evidence of degeneration in Bruch's membrane and not an essential part of the pathological process. In view of the studies by Hagedoorn (1939), Klien (1947), and Verhoeff (1948), it should be noted that there was no basophilia of Bruch's membrane which was eosinophilic; Kossa's stain for calcium and the Turnbull blue reaction for iron were both negative.

RETINAL AND SUB-RETINAL CHANGES.—A striking feature of the histological picture is the presence of sub-retinal newly-formed tissue in the circumpapillary and sub-macular regions. All stages in its formation can be seen in the sections, and it would appear that the process begins at the ruptures in Bruch's membrane. Through the resulting gaps serous fluid passes, seeps under the pigment epithelium, and leads to its detachment (Figs 3 and 8). At this stage the pigment epithelium appears normal. Wandering histiocytes and fibroblasts migrate from the choroid, and proceed to form connective tissue (collagen) in the sub-epithelial coagulated transudate, and new vessels from the choroid grow through the dehiscences in Bruch's membrane to supply the organizing tissue (Figs 6 and 7). As the disease progresses, the pigment epithelium becomes disorganized and migrates into the retinal and sub-retinal tissue, where it aggregates around the vessels (Figs 5 and 9), to form masses of cuticular hyaline tissue which stains intensely with PAS (Hotchkiss-McManus), as seen in Fig. 4. Thus, the sub-retinal tissue consists of four elements:

- (i) serous transudate from the choroid,
- (ii) fibrous tissue from the choroid,
- (iii) glial tissue from the retina,
- (iv) cuticular substance from the pigment epithelium.

An exactly similar structure was reported by Klien (1947) in a study of two eyes with angiod streaks.

The outer layers of the retina, replaced by glial tissue, merge with the sub-retinal fibrous tissue from the choroid, but the two types of tissue are clearly differentiated with Mallory's phosphotungstic haematoxylin stain.

The surviving retinal tissue consists of a nerve fibre layer, a reduced ganglion cell layer, the inner plexiform layer, and a partially disorganized inner nuclear layer which rests directly on the sub-retinal glial and fibrous tissue. Anteriorly, where Bruch's membrane is intact, the retina shows no gross abnormality and there are only very mild sclerotic changes in the retinal vessels.

DISCUSSION

As pointed out by Sorsby and others (1949), the clinical course of this fundus dystrophy would suggest that the lesion is primarily choroidal, and, if Bruch's membrane is regarded as part of the choroid, the supposition is borne out by the pathological findings in this sibship. The present study, dealing with material in the final stages of the dystrophy in only two cases, does not allow us with certainty to localize the fault more particularly. Nevertheless, the pathological picture so closely resembles the microscopical changes of angiod streaks and disciform degeneration of the macula that it is justifiable to compare the three conditions.

ANGIOID STREAKS.—It must first be emphasized that the term "angiod streaks" refers only to the ophthalmoscopic appearance of lines or streaks in the fundus of the eye, and that, although it has been established by thorough histological studies (Böck, 1938; Hagedoorn, 1939; Klien, 1947; Verhoeff, 1948) that the streaks are determined, in some cases, and probably in the majority, by breaks in Bruch's membrane, it by no means follows that all angiod streaks have such a pathology, or that all breaks in Bruch's membrane must necessarily give rise to the ophthalmoscopic appearance of angiod streaks. In this connection it is interesting to note that Law (1938) found no rupture of Bruch's membrane in the histological study of a case of angiod streaks and held that the appearances were due to a plication of the retina. Verhoeff (1948) stated that angiod streaks result from ruptures of a *basophilic* Bruch's membrane and that it is the basophilic condition (calcification) which brightens the contiguous fundus and makes conspicuous the exposed chorio-capillaris. Klien (1947) also believes that calcification of the lamina is essential to the production of angiod streaks. Verhoeff (1948) stated that similar ruptures which occasionally occur in senile eyes do not widen into visible streaks, presumably because the senile choroid loses its elasticity before Bruch's membrane becomes calcified. The fact, therefore, that despite the presence of numerous dehiscences in the posterior part of Bruch's membrane, angiod streaks were not seen ophthalmoscopically in our two cases of fundus dystrophy, is not difficult to understand, for there was no evidence of calcification in Bruch's membrane, many of the gaps had not widened, and those which had were obscured by new-formed tissue.

Behr (1931) drew attention to the role of Bruch's membrane as a regulator of the nutrition of the external layers of the retina, and held that any alteration of this membrane would, therefore, produce severe consequences in the retina and especially in its most delicate part, the macula: but it is known that many cases of angioid streaks remain stationary indefinitely. According to Scholz (1941), of all the cases in the literature observed for over one year, 33 per cent. showed an increase in the number of streaks, 56 per cent. remained unchanged, and in 10 per cent. the streaks decreased in number. Hagedoorn (1939) pointed out that the choroid shows no reaction to a great number of the tears which occur in angioid streaks, and remarked upon the inactivity of the choroid in producing scar tissue. He concluded that disease of Bruch's membrane alone does not suffice to explain the appearance of newly-formed tissue, and it is possible that a haemorrhage (Verhoeff, 1928) or an exudate (Behr, 1931; Rintelen, 1936) may present the additional stimulus necessary for its formation.

The histological picture in these two cases of fundus dystrophy is almost identical with that described by Hagedoorn (1939) in his case of angioid streaks (female, aged 48) with pseudo-xanthoma elasticum, and with that described by Klien (1947) in her case of angioid streaks (male, aged 53); it differs only in that the breaks in Bruch's membrane were seen clinically as angioid streaks and were associated with a basophilic degeneration of the lamina. The case of angioid streaks (male, aged 44) described by Böck (1938) also showed many similarities in its histology (see Figs 10 and 11 in Böck's article).

Like the affection studied here, angioid streaks is an hereditary disturbance, but shows several features that distinguish it sharply from dominant fundus dystrophy. It is recessive in behaviour and, though met as an isolated ocular anomaly, is frequently associated with pseudo-xanthoma elasticum of the skin constituting the Grönblad syndrome, and sometimes also—as the term elastosis dystrophica suggests—with vascular hypertension due to a widespread systemic disease of the elastic tissues including those of the arteries. Whilst the age at which angioid streaks first appear is not known, the more serious complications, such as massive haemorrhages and exudates, do not generally set in till middle life—and in this particular respect it is similar to fundus dystrophy.

DISCIFORM DEGENERATION IN THE MACULA.—As the result of numerous histological examinations of this condition it is now generally agreed that the underlying basis of the disease is the pathological change in Bruch's membrane which leads to its rupture. Although theoretically an actual break is not regarded as essential by either Behr (1931) or Brown (1940), it is necessary to cut serial sections before breaks can be excluded, and in the absence of such a negative examination it would appear more probable that a break or hole of some kind is pre-requisite to the formation of sub-retinal tissue of choroidal origin. Both Behr (1931) and Sandoz (1939) have demonstrated degeneration in the elastic layer of Bruch's membrane in the area of newly-formed tissue, and dehiscences have been demonstrated by Vogt (1935), Verhoeff and Grossman (1937), and Brown (1940). Wölflin (1926) considers that exudate from the choroid passes through holes in Bruch's membrane to reach the sub-retinal area.

The primary process then is a change in the elastic layer of Bruch's membrane, leading to ruptures through which transudate exudes from the chorio-capillaris, or through which, according to Verhoeff and Grossman (1937), a haemorrhage occurs, and the plasma or blood forms the medium in which fibroblasts and capillaries from the choroid proliferate. Ruptures in Bruch's membrane are, therefore, common to both angioid streaks and disciform degeneration.

FUNDUS DYSTROPHY.—It will thus be seen that the three conditions of angioid streaks, disciform degeneration, and this fundus dystrophy, have striking similarities, and that the most important common factor is the degeneration and rupture of Bruch's membrane followed by the formation of sub-retinal tissue. That these changes can occur without vascular disease has been emphasized by Hagedoorn (1939); in the case of Klien (1947) the chorio-capillaris was intact in the region of the break, and Hagedoorn (1939) has also pointed out that, though vascular changes in the choroid may be sufficiently severe to lead to retinal atrophy, yet newly-formed sub-retinal tissue does not develop. It is important to remember, however, that in a case of disciform degeneration (Brown, 1940), there was extensive sclerosis of the choroidal vessels which was more marked behind the lesion than elsewhere, and that Verhoeff and Grossman (1937), who carefully examined three cases of disciform degeneration and surveyed the literature referring to 129 eyes, came to the conclusion that the condition was primarily due to some disturbance in the chorio-capillaris: they considered that a localized angio-sclerosis was probably the cause, since the disorder was usually a senile disease. Andersen (1950) holds the view that the exudative process which leads to macular changes is most likely to be found in the pathological changes of the elastic membrane of the choroidal blood vessels. On the other hand, if the elastic tissue of Bruch's membrane degenerates with advancing years, either primarily or as a result of calcification in the membrane, it is not surprising that breaks with a newly-formed sub-retinal tissue should co-exist with choroidal vascular sclerosis as separate phenomena of the ageing process, without any direct causal relationship. Díaz Dominguez and Arqués Gironés (1950) regard the lesions of Bruch's membrane as an expression of a generalized degeneration of elastic tissue, as a manifestation either of senility or of pseudo-xanthoma elasticum.

With regard to the role of the choroidal sclerosis in our cases of fundus dystrophy, we have already advanced reasons for supposing that it was not the primary cause but an associated change. It would appear that the fundamental pathology is rather to be sought in a primary degenerative change in the elastic lamina of Bruch's membrane, with the secondary organization of a sub-retinal haemorrhage from the chorio-capillaris, originating possibly in a capillary herniation through a rupture (Brown, 1940), or with the organization of a sub-retinal transudate. Haemorrhages and exudates may in fact be seen in the early stages of the fundus dystrophy and Krummel (1950) has advanced the view that sudden ruptures of Bruch's membrane lead to sub-retinal haemorrhages and exudates. Gifford and Cushman (1940) have given added evidence that the primary change is in the lamina vitrea rather than in the vascular system.

Nevertheless, the physico-chemical changes which lead to degeneration of the elastic tissue of Bruch's membrane are not understood (Pautrier, 1948), and it must be admitted that the possibility remains that such a degeneration may result from vascular sclerosis in some instances and that this fundus dystrophy may be an example of such a process. The final decision whether the primary fault lies in the choroidal vessels or in Bruch's membrane must await the histological study of the earlier stages of the disease.

RELATIONSHIP TO "DOYNE'S CHOROIDITIS".—The possibility that fundus dystrophy is the same condition as that described by Doyne and known as Doyne's choroiditis has been discussed on clinical grounds elsewhere (Sorsby and Mason, 1949). The one histological report on Doyne's choroiditis (Collins, 1913), recorded the presence of a newly-formed hyaline substance, like Drusen, but longer, between the retina and choroid; where the hyaline substance was present, Bruch's membrane could not be made out satisfactorily. It is not clear from this report whether the changes observed were similar to those recorded here.

THEORETICAL CONSIDERATIONS.—If fundus dystrophy is indeed an affection induced by disturbances in Bruch's membrane, it links up pathologically with angioid streaks and disciform degeneration of the macula, though each of these affections is clinically distinct. A common anatomical basis for diverse clinical entities is of course not unknown in pathology, as is shown by the diverse clinical forms of vascular retinopathy, of lipoidosis, or of the blood dyscrasias. It is conceivable that the feature which distinguishes one clinical entity from another is determined by the type of pathological changes rather than by the tissue in which these changes occur. Be this as it may, there is nothing inherently improbable in the theory that angioid streaks, disciform degeneration of the macula and fundus dystrophy may have a common anatomical basis, and that there should be a different genetic basis for at least two, and possibly for all the three, of these affections.

One puzzling feature in fundus dystrophy is the marked appearance of choroidal sclerosis clinically as against the relative paucity of changes in these vessels histologically. The question arises whether choroidal vessels showing ophthalmoscopically as white streaks are indeed obliterated vessels or merely vessels whose outlines are patterned by an overlying sub-retinal white exudate. If the latter view is correct, then the whitish fundus reflex frequently seen between sclerosed choroidal vessels is due not to exposed sclera but to organized sub-retinal exudate showing through the translucent retina. Such a view—hypothetical at present—would harmonize the apparently contradictory ophthalmoscopical and histological changes observed in this—and possibly in other—affections.

SUMMARY

Four eyes from two sisters affected with fundus dystrophy described by Sorsby and Mason (1949) and Burn (1950) were removed *post mortem* and examined histologically. The findings are reported in detail. The main features noted were these:

(1) Sclerosis and atrophy of the choroid with fibrous mural degeneration of the remaining vessels.

(2) Numerous ruptures of Bruch's membrane in the posterior fundus with degeneration of the elastic layer in the same area.

(3) Sub-retinal newly-formed vascular tissue, originating from the choroid and related to the dehiscences in Bruch's membrane.

(4) Disturbance of the pigmentary epithelium.

(5) Destruction of the outer layers of the retina with glial replacement.

Reasons are given for regarding these changes as analogous to those reported in angioid streaks and disciform degeneration of the macula, and it is pointed out that the fundamental change common to the three conditions is the rupture of Bruch's membrane.

The role of choroidal sclerosis in the production of the degeneration in the lamina vitrea is discussed, and it is concluded that, in the absence of a knowledge of the histological changes in the early stages of the fundus dystrophy, the evidence is in favour of regarding the vascular degeneration as an associated phenomenon rather than as a causative factor.

It is tentatively suggested that the fundus dystrophy results primarily from genetically determined dehiscences in Bruch's membrane; this theory links this affection pathologically with angioid streaks and disciform degeneration of the macula.

We are indebted to Mrs. Helena Simpson, Matron of Armitage House, Worthing, and to Dr. L. R. Janes, Pathologist to the Royal Sussex County Hospital, Brighton, for their help in securing the histological material. Our thanks are also due to Dr. Peter Hansell for the photographs, to Mr. A. McNeil for technical assistance, and to Miss E. FitzGerald and Miss E. M. Gower for secretarial help.

REFERENCES

- ANDERSEN, O. C. (1950). *v. Graefes Arch. Ophthalm.*, **151**, 209.
 BEHR, C. (1931). *Z. Augenheilk.*, **75**, 216.
 BÖCK, J. (1938). *Ibid.*, **95**, 1.
 BROWN, E. V. L. (1940). *Arch. Ophthalm., Chicago*, **23**, 1157.
 BURN, R. A. (1950). *British Journal of Ophthalmology*, **34**, 393.
 COHEN, M. (1938). *Arch. Ophthalm., Chicago*, **19**, 487.
 COLLINS, E. TREACHER (1913). *Ophthalmoscope*, **11**, 537.
 DÍAZ DOMÍNGUEZ, D., and ARQUÉS GIRONÉS, A. (1950). *Arch. Soc. Oftal. hispano-amer.*, **10**, 1043.
 GIFFORD, S. R., and CUSHMAN, B. (1940). *Arch. Ophthalm., Chicago*, **23**, 60.
 HAGEDOORN, A. (1939). *Ibid.*, **21**, 746.
 KLIEN, B. A. (1947). *Amer. J. Ophthalm.*, **30**, 955.
 KRÜMMEL, H. (1950). *v. Graefes Arch. Ophthalm.*, **151**, 167.
 LAW, F. W. (1938). *Trans. Ophthalm. Soc. U.K.*, **58**, 191.
 PAUTRIER, L. M. (1948). *Arch. belges Derm. Syph.*, **4**, 259.
 RINTELEN, F. (1936). *Klin. Mbl. Augenheilk.*, **97**, 673.
 SANDOZ, Y. L. (1939). *v. Graefes Arch. Ophthalm.*, **140**, 725.
 SCHOLZ, R. O. (1941). *Arch. Ophthalm., Chicago*, **26**, 677.
 SORSBY, A., MASON, M. E. JOLL, and GARDENER, N. (1949). *British Journal of Ophthalmology*, **33**, 67.
 VERHOEFF, F. H. (1928). *Trans. Sect. Ophthalm., Amer. med. Ass.*, p. 243.
 ——— (1948). *British Journal of Ophthalmology*, **32**, 531.
 ——— and GROSSMAN, H. P. (1937). *Arch. Ophthalm., Chicago*, **18**, 561.
 VOGT, A. (1935). *Klin. Mbl. Augenheilk.*, **95**, 93.
 WÖLFELIN, E. (1926). *v. Graefes Arch. Ophthalm.*, **117**, 33.