

## SURGERY OF MALIGNANT MELANOMA OF THE IRIS\*

BY

H. B. STALLARD

*London*

THE prognosis after adequate and careful surgical removal of malignant melanoma of the iris is good, for such neoplasms are commonly slow growing, and a feature of their morbid histology which substantiates this fact is the absence of karyokinetic figures. They are composed of spindle cells, a cytological type which, together with a rich argentophil reticulin, in the case of malignant melanomata of the choroid, has a better prognosis than other cellular varieties.

Neoplastic infiltration of the posterior surface of the cornea and of the structures at the filtration angle including the base of the ciliary body used to be considered a contraindication to the local removal of a malignant melanoma by iridectomy; however, although these neoplastic extensions are undesirable they are not insuperable barriers to effective surgical extirpation, for it is possible with a trephine of appropriate size to remove in some cases the affected part of the cornea with an adequate surround of normal cornea and to replace this with a corneal graft. When the periphery of the neoplasm has reached the filtration angle and it is suspected that only a thin sheet of cells may have infiltrated the base of the ciliary body, surface diathermy has been successful in their destruction (Case 3). This treatment is of course unwarranted when there is gross involvement of the ciliary body. Radiotherapy is quite ineffective for malignant melanoma of the iris, a fact verified by the morbid histology of the tumour removed after irradiation (Case 1, Fig. 2). Excision of the eye when the neoplasm is limited to the iris is quite unjustifiable. The majority of malignant melanomata of the iris are situated in its lower half, and are obviously more conspicuous in blue irides than in the heavily pigmented irides typical of the coloured races.

### CLINICAL TYPES

(1) **Nodular.**—The neoplasm is roughly circular, projects well forward from the anterior surface of the iris, has a fluffy nodular surface and

---

\* Received for publication July 26, 1951.

shows thin-walled vascular loops from which blood may leak into the anterior chamber and temporarily impair vision (see Fig. 3, p780). Several smaller satellite nodules of growth may be present in the adjacent iris.

**(2) Flat and Plaque-like.**—This variety of malignant melanoma which is slow growing, relatively avascular, causes distortion of the iris with early ectropion uveae and sectoral immobility of the affected part of the iris in its reaction to light and accommodation. Ultimately this type of neoplasm spreads along vascular and lymphatic sheaths in a diffuse infiltration of the uveal tract.

**(3) Diffuse, so-called " Ring " Sarcoma.**—This reduces the depth of the anterior chamber and ultimately causes glaucoma. This type is of course unsuitable for removal by iridectomy for it infiltrates the ciliary body extensively and even extends posteriorly into the choroid. In some instances the diagnosis is not realized until the moment of seizing the thickened iris during an operation to relieve glaucoma. When I was pathologist at Moorfields Eye Hospital such a case occurred, and the surgeon, suspecting an abnormal state of the iris, sent the excised piece for section. The eye was removed a week later and sections showed giant-cells of Langhans at the advancing edge of the sheet of malignant melanoma which had extended posteriorly into the choroid, a histological feature significant of rapid growth after the relief of the raised intra-ocular pressure.

The clinical signs of malignancy occurring in a melanoma which has been previously judged benign are increase in size, vascularity, and pigmentation. The last feature does not, of course, apply in cases where the tumour is so sparsely pigmented that the term leucosarcoma has been applied in the past. Irregularity of the pupil and impaired mobility of the affected sector of the iris have been mentioned above.

In cases where the posterior limit of the neoplasm is not clear, eserine is instilled and the filtration angle is examined by the gonioscope. The size of the neoplasm is measured by Lang's 4 D graduated cylinder.

#### SURGICAL TECHNIQUE

It is desirable to remove the neoplasm by an iridectomy which extends from the pupil margin to the root with radial cuts 3 mm. on either side of the growth and to do this without an instrument touching the neoplasm and if possible without the neoplasm making contact with the edges of the wound.

Before operation, eserine is instilled into the eye. Akinesia of the orbicularis oculi and a retro-ocular injection of local anaesthetic into the region of the ciliary ganglion are effected. Pentothal may be given if indicated.

After insertion of the speculum, a traction stitch is passed through the rectus muscle posterior to the site for incision or, if necessary, sutures are passed through the two adjacent recti muscles.

The conjunctiva is incised at the limbus for about half the circumference of the cornea, and is undermined so as to fashion a ' hood ' flap. Two traction sutures are passed through its edge and the flap is retracted by

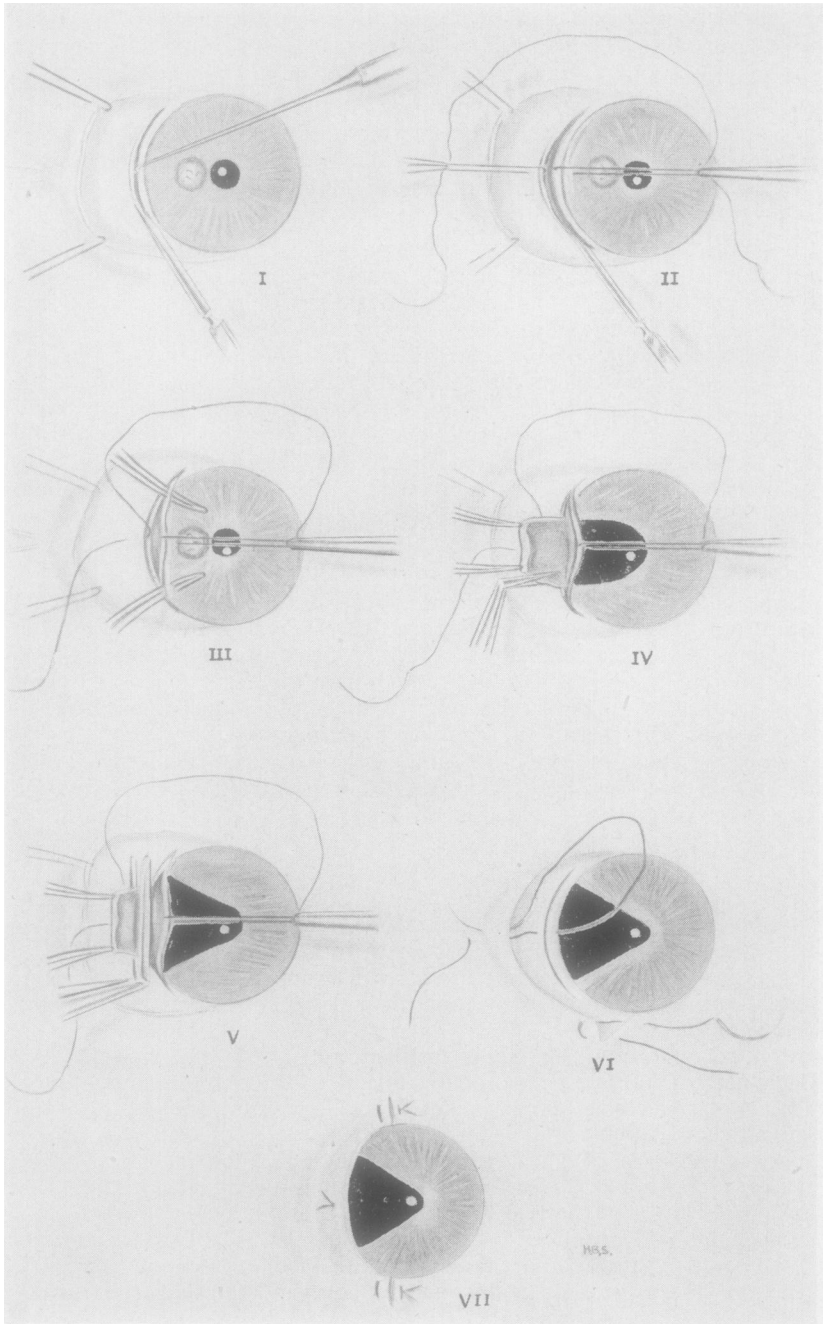


FIG. 1.—Diagram of main steps in iridectomy operation. The following numbers indicate the order, reading from left to right beginning at the top.

- (i) Incision *ab externo*. Fixation of the eye by suture through rectus muscle insertion and fine scleral hook in anterior lip of incision. Conjunctival flap retracted by two sutures.
- (ii) A double-armed scleral suture has been inserted and drawn out into a loop. Retraction of the arms of the loop is made with plane forceps whilst the incision is completed.
- (iii) Two Lang's iris forceps are passed through the wound to grasp the iris 3 mm. on either side of the neoplasm.
- (vii) The scleral wound is closed and covered with the conjunctival-hood flap.
- (iv) The iris with the neoplasm is drawn through the wound and incisions are made with de Wecker's scissors from the pupil margin to the iris root just beyond the grip of each pair of forceps.
- (v) The iris root is cut.
- (vi) The two arms of the scleral suture are brought through the conjunctival flap, 2.5 and 1.5 mm. from its cut edge, and tied. The corners of the conjunctival-hood flap are secured with two mattress sutures.

clamping these sutures to the head towel (Fig. 1, *i*). These sutures may be used at the end of operation to secure the corners of the hood flap. The anterior chamber is entered at the limit of the filtration angle through an *ab externo* incision made concentric with and 1 mm. behind the limbus and extending 5 mm. in each direction from the peripheral limits of the neoplasm. It is essential for this incision to be adequate in order to manipulate two pairs of Lang's iris forceps in the eye at the same time. Before the incision is made it is well to mark its limits with a light touch from a heated probe and also to seal in this way any superficial blood vessels in the line of incision. A fine scleral hook is inserted in the limbus at the centre of the line marked for the incision. This acts for fixation and traction. The incision is made either with a No. 15 Bard Parker knife or a small cataract knife (Fig. 1). Before the incision is completely through the sclera one or two sutures, depending on the length of the incision, of 000 black silk on Grieshaber's needles are passed from the scleral to the corneal lip of the incision and are pulled out into a loop or loops (Fig. 1, *ii*) in order to afford the knife access to complete the incision.

The arms of these sutures may be held in plane forceps by the assistant and the edges of the wound thus retracted. Vitreous loss is unlikely but if this is anticipated it is well to tie a substantial knot on the corneal arm of each suture and to place this on the cornea against the exit of the suture. The purpose of the knot is to effect rapid closure of the incision by pulling on the scleral arm of each suture. The incision into the filtration angle may be completed either by a few light strokes with the knife or, when the filtration angle is open for 2 mm., it may be finished by the careful introduction of the tips of Westcott's scissors with the deeper blade between the iris root and the posterior surface of the limbus, care being taken not to touch the neoplasm.

I think that this *ab externo* incision is preferable to a small keratome section made to one side of the neoplasm and enlarged with scissors, and to the classical section made by a cataract knife traversing the anterior chamber, for in both instances there is some risk of touching the tumour with either the keratome or the knife and so disseminating neoplastic cells into the anterior chamber and the wound. If the iris bulges into the wound it is gently replaced with an iris repositor without touching the neoplasm. Any bleeding points are checked with a fine heated probe.

The surgeon now takes a pair of Lang's iris forceps in each hand. The assistant holds in one hand a pair of de Wecker's scissors ready to give the surgeon whilst with the other hand he seizes in forceps the corneal

arms of the sutures so as to lift the corneal edge of the wound, through which the surgeon passes the Lang's iris forceps one on each side of the neoplasm (Fig. 1, *iii*). A grip is taken of the iris at a point 3 mm. on either side of the neoplasm and as the iris with the neoplasm is drawn into the wound the assistant lifts the corneal lip to clear the neoplasm. The iris is now drawn forwards so that the whole of the neoplasm is exposed (Fig. 1, *iv*) and the iris root is just through the lips of the incision. The surgeon now hands over one of the Lang's forceps to the assistant, and with his other hand he makes a radial cut with de Wecker's scissors from the pupil margin to the iris root 3 mm. from the edge of the neoplasm on one side and with the two pairs of Lang's iris forceps still keeping taut the sector of the iris within their grasp a like cut is made with de Wecker's scissors 3 mm. from the other side of the neoplasm. The sheet of iris with the neoplasm is now drawn well forward and the open blades of de Wecker's scissors placed at a tangent to the wound embrace the iris root and on closing sever it from the ciliary body (Fig. 1, *v*). An iridectomy done in this way gives a neat coloboma (see Fig. 4), whereas the illustrations in the literature of iridectomy done with one pair of forceps show a ragged coloboma.

The assistant immediately spreads the excised piece of iris over a cork moistened with saline to which it is fixed with four small stainless steel pins placed in each corner of the section of iris. The specimen is now immersed in formol saline.

If it is necessary, the wound may be immediately and firmly closed by drawing on the sutures. However, in the 6 cases upon whom I have done this operation to date there was no threatened vitreous presentation, and so rapid closure of the wound was not an urgent necessity and there was no haemorrhage from the cut edges of the iris.

The needle on the scleral arm of each suture is now passed through the conjunctiva from its deep to its superficial surface 2.5 mm. from its edge, and the corneal arm is brought through 1 mm. closer to the edge (Fig. 1, *vi*). If a knot has been tied on the corneal arm of each suture for the purpose of quick closure of the wound, then the suture is drawn forward so that the knot is well clear of the corneal surface. The knot is cut off and the suture threaded through a needle which is passed through the conjunctiva in the manner described above. These sutures are firmly tied with a surgical knot so that the edges of the limbal wound are accurately coapted and covered by the conjunctival flap. The corners of the hood conjunctival flap may each need closure by sutures, and to achieve this the sutures which have been retracting the conjunctival flap are used. If there is any unsightly 'dog's ear' fold, the excision of a small triangle of conjunctiva with its base at the limbus will adjust this (Fig. 1, *vi* and *vii*). Atropine is instilled and a dressing applied.

The sutures which close the limbal incision and hold the conjunctival flap over this are removed 10 days after operation, and the sutures at the corners of the conjunctival flap are removed on the 6th day.

Healing is uneventful. With careful suture of the wound hyphaema is improbable, and indeed did not occur in this series of 6 cases. Also I think that suturing the wound may lessen astigmatism to 0.5 D.

## Case Reports

**Case 1.** K. A., aged 15 in June, 1932, when she came to St. Bartholomew's Hospital. One year after birth (1918) a brown swelling was noted on the iris in the 12 o'clock meridian. In 1929 at the age of 12, this swelling became larger and it had gradually increased since then. In January, February, and March, 1932, at 6-week intervals she received three applications of unscreened radium (10 mg. in a 10 mm. diameter monel metal applicator) at the Radium Institute.

In the 12 o'clock meridian of the iris of the right eye there was a circular raised, nodular pigmented neoplasm with vascular loops showing on its anterior surface. The neoplasm had infiltrated the pupil margin and was not attached to the cornea, and the root of the iris and filtration angle were clearly free from the growth. There was melanosis of the iris elsewhere. The left iris was blue without any sign of melanosis. The patient's hair and complexion were fair and there were a few scattered benign melanomata in the skin of the face, neck, and arms. There were no enlarged regional lymph nodes. Vision was 6/9 in the right eye, and 6/6 in the left eye.

On July 1, 1932, a keratome section was made at 9-10.30 o'clock and the section completed with scissors. The neoplasm was removed in a wide iridectomy.

*Pathological Report* (see Fig. 2).—Malignant melanoma of the iris composed of spindle cells in irregular interlacing bundles. Intra- and extra-cellular pigment. Thin-walled blood vessels with hyaline degeneration in some of the vessel walls. No areas of necrosis and no histological evidence of effective irradiation. The line of excision is clear of the neoplasm.

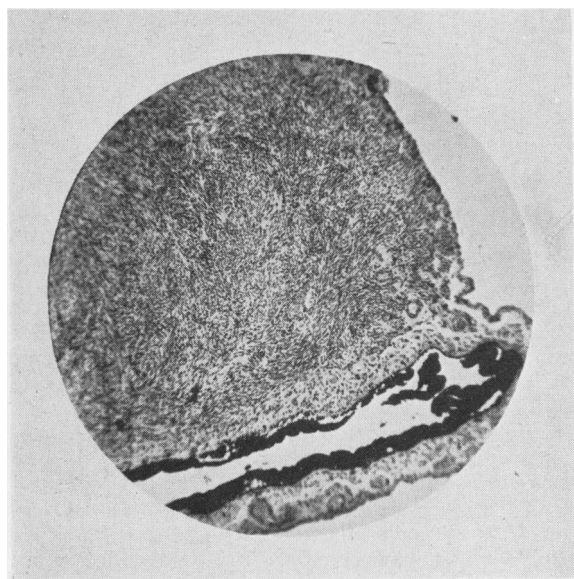


FIG. 2.—Case 1, photomicrograph of section of iris malignant melanoma. Spindle cells quite unaffected by unscreened radium.

*Follow-Up.*—On January 10, 1933, the incision had become a cystoid cicatrix, the anterior chamber was shallower than normal and the intra-ocular pressure was low. To date (June, 1951), she has remained well and free from recurrence of the neoplasm. Vision in the right eye is 6/9, 6/6 (partly) J.4 with  $-0.75$  sph  $+6.0$  cyl. ax.  $150^\circ$ . Since 1933 the astigmatism in the right eye has increased from  $+2$  D to  $+6$  D.

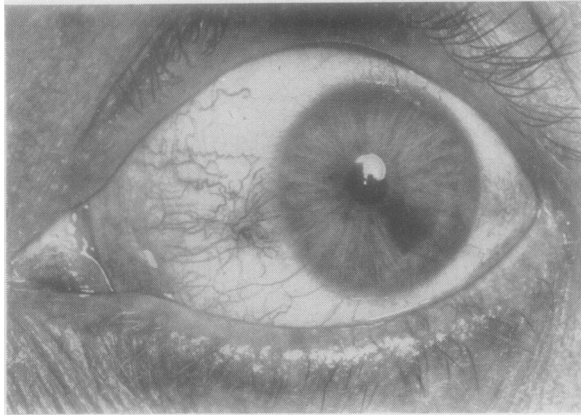


FIG. 3.—Case 2, left eye, malignant melanoma of iris in lower temporal quadrant of iris.

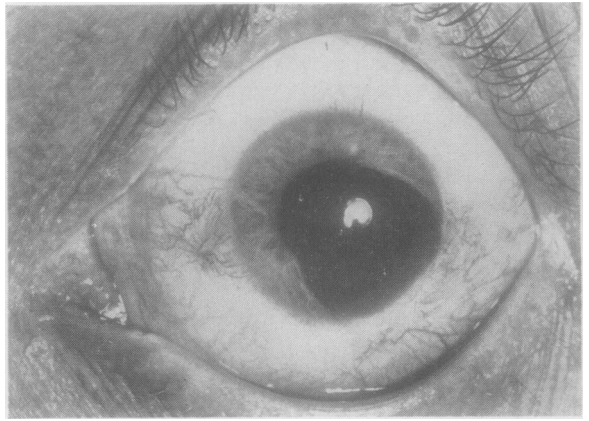


FIG. 4.—Case 2, after operation.

**Case 2.** C. M., female, aged 30, by profession a doctor, had had a melanoma on the iris of the left eye in the 4 o'clock meridian all her life. In January, 1951, vision became blurred in the left eye from a small hyphaema which absorbed in 48 hours, and the visual acuity returned to 6/5 with  $-5$  sph. On February 12 she came to Moorfields Eye Hospital. Fig. 3 shows the neoplasm, which had a dilated vessel running to it from the periphery of the iris, and another conspicuous vessel running horizontally from the neoplasm's pupillary border. A number of loops of thin-walled vessels stood out from the surface of the neoplasm. On February 16, 1951, the operation described above was performed. The *ab externo* post-limbal incision was closed by one suture which also took in the hood conjunctival flap. A mattress suture was used at each corner of the flap. Healing was uneventful. There was no hyphaema. The visual acuity on April 9, 1951, was 6/5 with  $-5$  sph.  $-0.5$  cyl. as  $180^\circ$ . The cylinder in the right eye was also  $-0.5$  D. Fig. 4 shows the large iris coloboma with neat edges.

Fig. 5 shows a contact lens with painted iris and Fig. 6 a contact lens darkened over the site of the iris coloboma. The former was preferred cosmetically and functionally.

The morbid histology of the spindle-celled neoplasm, showing its blood spaces and absence of the karyokinetic figures, is seen in Fig. 7 (opposite) and Fig. 8 (overleaf).

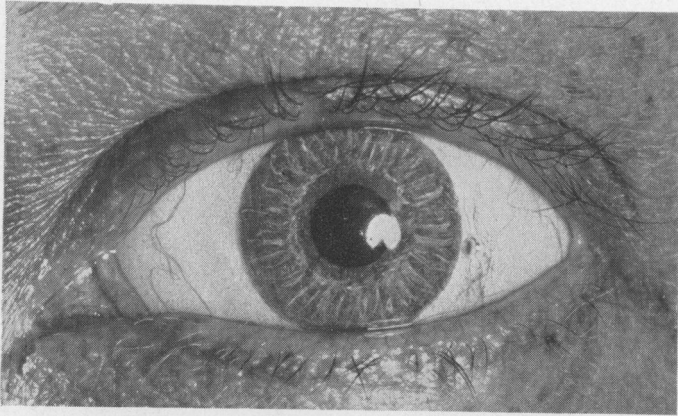


FIG. 5.—  
Case 2, photo-  
graph of con-  
tact lens with  
iris painted on  
lens.

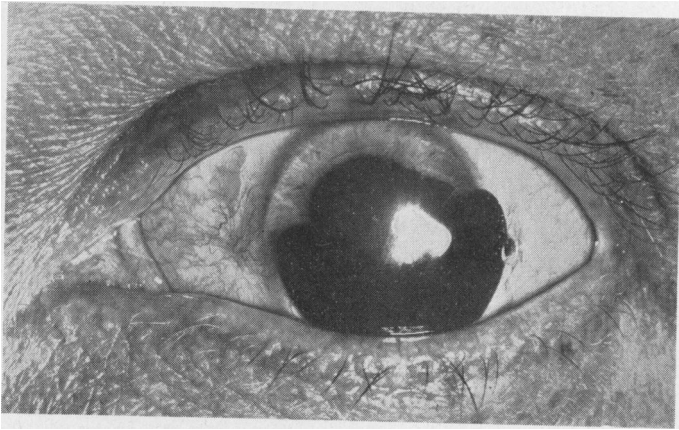


FIG. 6.—  
Case 2, con-  
tact lens with  
shaded area to  
cover col-  
boma.

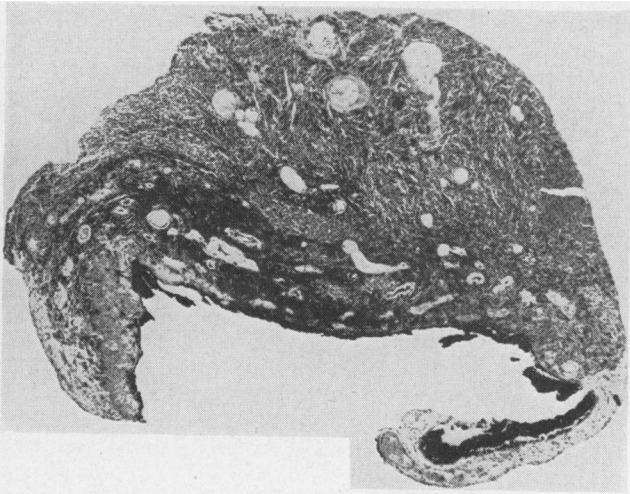


FIG. 7.—Case 2,  
low-power photo-  
micrograph of sec-  
tion of iris malig-  
nant melanoma.



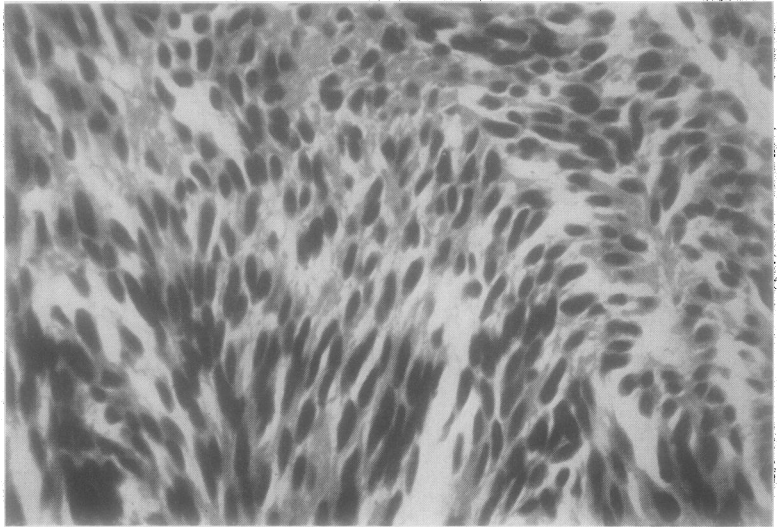


FIG. 8.—Case 2, high-power photomicrograph of section of iris malignant melanoma.

**Case 3.** Corporal J. F. McC., aged 22, of the R.C.A.S.C., attached to 22 Canadian Field Ambulance, was sent to 108 General Hospital in Belgium on January 2, 1945. He had a malignant melanoma of the iris between the 5 and 7 o'clock meridians of his left eye, in which the vision was 6/6. A thin sheet of the neoplasm had extended to the iris root and, as it was possible that the posterior advancing edge might have involved the base of the ciliary body surface, diathermy 70 milliamps for 5 sec. was applied just posterior to the limbus. The incision was made through this diathermized area and the neoplasm removed with 3 mm. of iris on either side of it. Serial sections showed a spindle-celled malignant melanoma. The radial incisions on either side of the growth were well clear of it, but the diathermy had so affected the iris root that it was difficult to be sure whether the line of excision was clear of the neoplasm in the centre of the iris root. Healing of the wound was uneventful and the lens remained transparent. The patient was evacuated to the United Kingdom. Subsequently the eye became irritable and the intra-ocular pressure was low. It was decided to excise the eye and this was done in a Canadian Hospital in England. Serial sections of the eye made at Moorfields Eye Hospital revealed no histological evidence of malignant melanoma. The strip of conjunctiva over the wound which was removed with the eye was vascular but showed no trace of neoplastic cells. The anterior chamber contained some granular coagulum and the ciliary body showed evidence of necrosis. Pigmentary disturbance was evident in the ciliary body and ora serrata. The choroidal vessels were dilated and there were haemorrhages in the anterior part of the choroid and one large haemorrhage close to the optic disk. Oedema was present in the supra-choroidal lymph space and in the optic nerve.

It seems evident in this case that the ciliary body resented the amount of diathermy which was used. Perhaps the intra-ocular irritation following the diathermy might have settled in time, and the patient might have retained some measure of vision.

**Case 4.** A. H., male, aged 45, had a malignant melanoma of the iris in the lower nasal

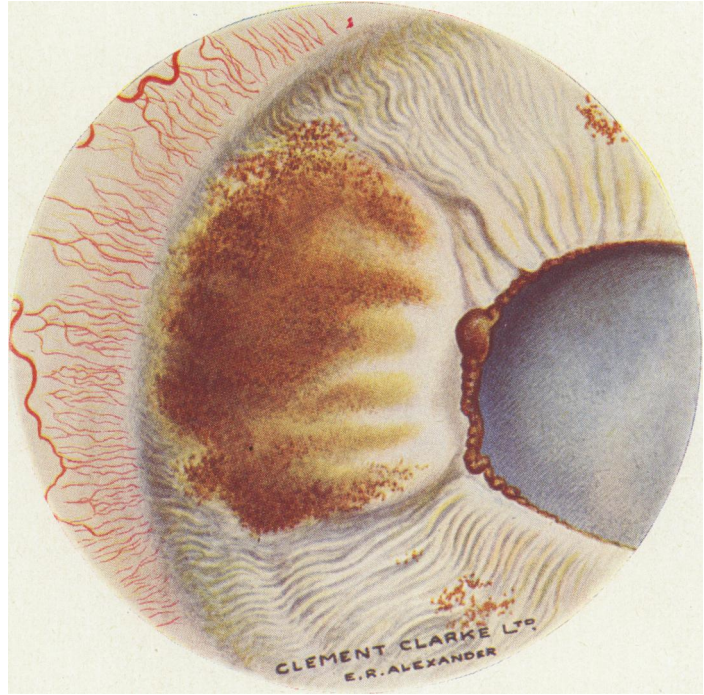


FIG. 10.—Case 5, left eye, painting of iris, showing malignant melanoma.

quadrant of the right eye. The neoplasm was in the root of the iris and extended for 2.5 mm. forwards in the stroma, and its measurement concentric with the limbus was 3.5 mm. It was buff-coloured and of the flat, plaque-like variety. The pupil action was disturbed and its shape irregular in the sector affected by the neoplasm. Vision in the right eye was 6/9.

On August 8, 1950, the neoplasm was excised, leaving the sphincter iridis and pupil intact. Before making an *ab externo* incision 1.5 mm. behind the limbus, two applications of diathermy were made to the base of the ciliary body, where it was thought

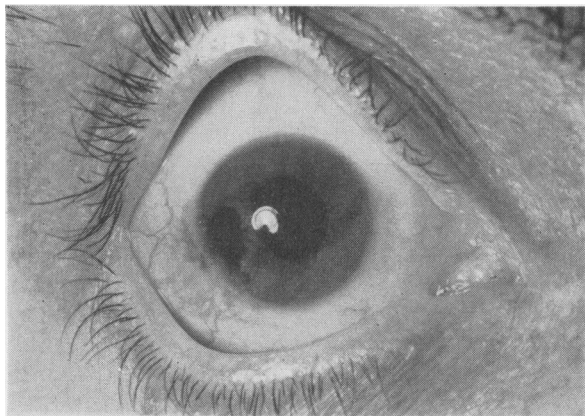


FIG. 9.—Case 4, coloboma after operation.

that a thin sheet of the neoplasm might have invaded it. The *ab externo* incision in the sclera was closed by two sutures. Healing was uneventful. Fig. 9 shows the coloboma which is somewhat ragged; indeed, except for a so-called complete iridectomy, it is very difficult to effect clean cuts with iris scissors in a somewhat folded iris drawn into the wound. There has been no recurrence to date.

**Case 5.** Mrs. I. P., aged 48\*, had a malignant melanoma of the iris in her left eye in the 9 o'clock meridian. It was nodular in type, roughly circular, and 3.5 mm. in diameter (Fig. 10). It was removed by the technique described above, and at present date (2½ years after operation) there is no evidence of recurrence. Vision in the left eye has remained 6/9, but the intra-ocular pressure has fallen to 13 mm. Hg from 23 mm. Hg before operation.

\*I wish to thank Mr. W. E. Heath for referring this patient to me, for his help when we operated on her, and for his notes about her progress.

#### REFERENCES

- BLACK, G. W. (1943). *Trans. ophthalm. Soc. U.K.*, **62**, 304.  
 CARTER, R. B. (1874). *Trans. clin. Soc.*, **7**, 60.  
 DUKE-ELDER, S. (1940). "Text-book of Ophthalmology". Vol. 3, p. 2488. Kimpton, London.  
 ——— and STALLARD, H. B. (1930). *British Journal of Ophthalmology*, **14**, 158.  
 GIFFORD, S. (1918). *Arch. Ophthalm.*, Chicago, **47**, 241.  
 KNAPP, H. (1879). *Ibid.*, **8**, 82.  
 LEBRUN (1868). *Anr. Oculist.*, Paris, **60**, 203.  
 MARSHALL, C. D. (1897). *Trans. ophthalm. Soc. U.K.*, **17**, 30.  
 MAYOU, M. S. (1930). *British Journal of Ophthalmology*, **14**, 152.  
 NEAME, H. (1943). *Trans. ophthalm. Soc. U.K.*, **62**, 103.  
 ST. JOHN ROOSA, D. B. (1869). *Trans. Amer. ophthalm. Soc.* (6th ann. meeting), **1**, 14.  
 THOMPSON, J. T. (1899). *Trans. ophthalm. Soc. U.K.*, **19**, 47.  
 THORINGTON, J. (1910). *Trans. Amer. ophthalm. Soc.*, **12**, Pt. 2, p. 409.  
 TOOKE, F. T. (1938). *British Journal of Ophthalmology*, **22**, 153.  
 WILLIAMSON, G. E. (1893). *Brit. med. J.*, **2**, .  
 WOOD, C. A., and PUSEY, B. (1902). *Arch. Ophthalm.*, Chicago, **31**, 323.