

OCULAR ONCHOCERCIASIS*

BY

J. W. R. SARKIES

Accra, Gold Coast

ONCHOCERCIASIS is caused by infection with the adult filarial worm *Onchocerca volvulus*; the microfilariae of this worm develop in the body of man and sometimes penetrate the tissues of the eye where they set up pathological changes leading to blindness; embryos may also be found in the skin, in lymph glands, in the fluid of hydroceles, and in effusions into joints. The disease has been reported from central America, and from scattered areas in equatorial Africa in a vast belt of territory which extends from latitude 15° N. to 20° S. (Hughes, 1949); in W. Africa the distribution closely follows that of the fast flowing rivers and streams in which the vector, *Simulium damnosum*, breeds. This association with rivers is known to many Africans. The Moshi tribe of the French Upper Volta have a saying recently translated by Puyelo and Holstein (1950):

La proximité des grandes rivières ronger les yeux.

Hughes noted that Gold Coast fishermen have long blamed the foam on the rapids of the River Volta for their high incidence of blindness.

The incidence of eye complications, based largely on figures for incidence of blindness, appears to vary considerably in different areas: in a recent survey of some 88,000 inhabitants of the French Upper Volta district, Puyelo and Holstein reported blindness rates up to 35 per cent. in one village; Hissette (1932) found 15 per cent. blind in a village in the Belgian Congo; Waddy (1949) reported 10 per cent. in villages in the Northern Territories of the Gold Coast; Strong (1934) found that 5 per cent. among his Guatemala cases of onchocerciasis had "eye disturbances". At the other end of the scale, Blacklock (1926) in Sierra Leone and Sharp (1927) in the Cameroons found no associated blindness with onchocerciasis.

The total extent of the sociological problem of onchocerciasis cannot at present be assessed, but there is no doubt that it is considerable; the incapacitating effect of the eye lesions, which can be inferred from the published blindness rates in some districts, is tragic, and the general lesions in the skin and other organs cause serious distress to the inhabitants of highly infected areas. Ridley (1950) has pointed out that the possibility that ocular onchocerciasis is the cause of obscure ophthalmic conditions in

* Received for publication August 2, 1951.

persons who have spent some time in equatorial America or Africa, must be borne in mind by ophthalmologists in other countries.

The bibliography on onchocerciasis has now reached considerable proportions, one published by the Pan-American Sanitary Bureau (1950) giving abstracts of over a thousand contributions to the literature. Few of these dealt with the ocular manifestations and even fewer appeared in English journals. Since the original description by Robles (1919) and Pancheco Luna (1919) from Central America, the eye lesions in established cases have been fully described by Hissette from the Belgian Congo, and by Ridley (1945) from the Gold Coast. These manifestations consist of a vascular conjunctival injection, interstitial nummular opacities of the cornea which may be so extensive as to become confluent, anterior uveitis, choroido-retinal degeneration, complicated cataract, secondary glaucoma, and optic atrophy. In the skin the typical lesion is a dry wrinkling which gives the appearance of premature age, to which Hughes applied the term "presbydermia". Subcutaneous nodules, consisting of numbers of encysted adult worms, are often found over such bony prominences as the ribs, iliac crests, sacrum, knees, and skull. In severe cases with gross pruritus, lichenification may occur and papular eruptions follow secondary infection. The occurrence of elephantiasis in cases of onchocerciasis has been noted by many writers though a causal relationship has yet to be demonstrated.

The present study is concerned mainly with early cases seen in the Gold Coast, and is an attempt to assess the importance and the diagnostic value of the early ocular manifestations. The necessity for complete ophthalmic examination and investigation in all cases is emphasized in the light of the paucity of signs seen in the eyes of such cases. Tables are given where necessary to support findings, and some cases are reported in full to illustrate specific points. The effects of treatment with Hetrazan and Antrypol are described with special reference to the ophthalmic manifestations; the surgical treatment of two cases complicated by secondary glaucoma is discussed, and comments are made upon the results of administration of riboflavine in a limited number of cases which showed early visual defects. All the cases were examined by the writer, and any pathological examinations were done personally or by Dr. M. H. Hughes of the Medical Research Institute in Accra. The principal difficulties, already mentioned by Ridley, arose from the illiteracy and low intellectual standards of the majority of sufferers; these often make it impossible to obtain accurate estimates of visual acuity and fields by subjective methods, and also cause many patients to postpone seeking medical advice until the disease is fairly advanced. In the hope of overcoming these difficulties, surveys were done on 270 industrial labourers and 224 schoolchildren in the Lower Volta district, shown by Hughes and Daly (1951) to be highly endemic for onchocerciasis. These surveys, did produce a number of early cases for investigation and treatment. Also a group of literates was collected, who were sufficiently intelligent to

give accurate visual acuities, though not unfortunately visual fields. For the rest, 31 cases which presented at the out-patient department in Accra are cited; these were usually advanced cases with established eye lesions.

Methods of Examination

In all cases the following routine of investigation was adopted. In the first place a general examination was made of the skin, and regions of bony prominences, such as the skull, ribs, pelvic girdle, and knees, were searched for nodules. The general findings in respect of these examinations during the course of surveys are reported elsewhere by Hughes and Sarkies (1951). It was noted then that the severity of most of the manifestations of onchocerciasis increased in direct proportion to the duration of exposure.

With regard to the ophthalmic examination, it was found possible to make accurate estimates of visual acuity only in those subjects who were literate or with whom some common language could be found. The use of such types as Landolt's "C" and the illiterate "E" gave such misleading results in a large number of patients in the lower intelligence levels, that only a rough classification of vision into three categories (blind, some visual loss, and normal) was undertaken. After a general examination using a condensing lens, the eye was investigated under a mydriatic. Both eyes were then examined with an electric ophthalmoscope, starting with a +20 D lens and racking down through the media to the fundus; in nearly all cases a further examination was made with a slit lamp and corneal microscope.

PATHOLOGICAL INVESTIGATIONS.—Various confirmatory investigations have been used in diagnosing onchocerciasis. The method principally employed in the hospital cases of this series was a combination of skin snips and skin smears modified from the techniques of Corson (1922) and Sharp (1926). A slip of skin was lifted with stitch forceps and the epidermis sliced off with a scalpel; this produced a piece of skin about 2 mm. in diameter which was immediately mounted in saline and examined under the low power of a microscope for living microfilariae. One disadvantage of this procedure is that it is not possible to make stained preparations, without which differentiation of the *mf. volvulus* from others, such as *mf. streptocerca* and *mf. perstans*, is not certain. When a stained preparation was required, it was found convenient to make a thick film of the sero-sanguineous exudate from the raw surface of corium left by the skin snip, this was dried and subsequently stained with Giemsa in the laboratory. As a rule, four such "snips" were made from each case from different parts of the body, before it was assumed that a case with negative findings was not one of onchocerciasis. Case K.154 may be cited to support the necessity for this: in this exceptional instance, twelve snips were done over a period of 3 weeks before one proved positive; this boy had active trachoma which was causing symptoms, but nummular opacities of the lower segment of the cornea were so typical that, although microfilariae were not seen in the anterior chamber or in conjunctival snips, a provisional diagnosis of onchocerciasis had been made on clinical grounds.

For cases seen during surveys, and for controlling those treated in schools, fresh skin snips were not examined, but the exudate from four superficial scarifications was smeared on a slide, dried, and examined later after staining

The commonest ocular manifestation of onchocerciasis in this series of cases was the presence of microfilariae in the anterior chamber, frequently with no demonstrable lesion whatever in the eye. A rather similar observation was made by Scott (1945) in a report on African soldiers in the Cameroons. In 22 schoolchildren, in whom embryos were seen in the aqueous, all except one had visual acuities of 6/6 or better; in one whose visual acuity was 6/36 in each eye, there was early macular degeneration. The parasites could be seen with a slit lamp and corneal microscope, when they appeared as fine golden threads up to 50 μ long, swimming freely in the aqueous; when seen with a 10 \times loupe and oblique illumination, they appeared silvery in colour probably on account of the nature of the light. Alternatively, they could be seen fairly easily even in the less co-operative patients with an ordinary electric ophthalmoscope, using a plus 20 to 30 lens in the eyepiece. This technique, which is often more successful with nervous or illiterate patients, has been described elsewhere (Sarkies, 1951a). The existence of an invasive stage of the disease, when microfilariae are present in the eyes but before irreversible tissue changes occur, is of obvious practical importance. For example, in one patient (Case S.200), the anterior chamber seemed to be alive with embryos, but he had visual acuities of 6/5 in each eye and no lesions whatever. Two months later, during the course of treatment, a few nummular opacities of the cornea appeared and persisted, but these were insufficient to affect his vision. It was found during the course of prolonged observation and follow-up of cases with microfilariae in the aqueous, that the number of embryos (in fact their very presence when they were scanty) varied from hour to hour and from day to day; at one examination they would be present in one eye only and at the next in the other eye; there was no numerical relationship between microfilariae in the eye and the severity of the eye lesions.

Nummular opacities of the cornea due to the presence of dead or dying microfilariae in the substantia propria were reported by Ridley, and the microscopic appearances of this condition have been described by Hughes and Daly (1950). In the present series, ten cases showed microfilariae in the cornea with a surrounding area of infiltration which constitutes the nummular opacity. Nummular opacities were seen most commonly at the periphery of the cornea close to the limbus, though occasionally they were near the centre encroaching on the pupillary area. In their early stages they consisted of irregular infiltrations up to 0.5 mm. in diameter, during treatment they tended to become denser with a more regular edge, and finally the smaller ones disappeared while others left circular opacities usually situated in the deeper layers of the cornea. The clinical appearance of these lesions, when seen with a corneal microscope or a loupe, was found to be sufficiently typical to be diagnostic of ocular involvement with onchocerciasis; in every case in which they were seen, a skin snip was found to be positive for *mf. volvulus*, although embryos were not necessarily seen in the anterior chamber.

One other early ocular manifestation was noted; namely, a macular degeneration clinically similar to the senile form. This occurred in Patient K.2, the only schoolboy to show diminished visual acuity; there was a very slight patchy increase of pigment in the macular area, with intervening lighter areas, suggesting that the sclera was shining through an atrophic retina. It seems likely that this condition would progress to the fully developed picture described by Ridley, but unfortunately no case was seen which showed an intermediate stage. Of the advanced choroido-retinal lesions, only one resembled Ridley's description; in the others the appearance was not specific. Disseminated choroido-retinitis, isolated peripheral patches of choroido-retinitis, and diffuse atrophy of the choriocapillaris were all seen, with varying degrees of optic atrophy.

Two factors which were constant in all the advanced fundus lesions were a marked increase in pigment, and a perivascular cuffing of the retinal vessels extending from the point where they emerge from the optic disk to a distance of two or three disk diameters towards the periphery of the fundus. This appearance, thought to be due to fibrous thickening of the vessel wall following cellular infiltration, was seen in seven advanced cases of onchocerciasis either in one or in both eyes; it is worthy of note that in any eye which showed this particular appearance the visual acuity was less than counting fingers at one metre. Case H.44, which is fully described later, showed this perivascular cuffing very clearly in the right eye, in which the visual acuity was reduced to recognition of hand movements (Fig. 1), whereas in the left eye, in which the vessels were normal, the vision was 6/12. Hughes and Daly (1950) demonstrated sections of a blind eye excised from a patient with onchocerciasis; that was an advanced case and sections stained with Van Gieson show marked thickening of the walls of the retinal vessels in the region of the optic disk (Figs 2 and 3). While it would be more conclusive still to reproduce sections of an eye of which the fundus had been seen, the African's reluctance to part with even a blind, painful eye made the obtaining of sections impossible. However, the presence of a fibrous thickening of the walls of the retinal vessels in sections of an eye known to be affected by onchocerciasis does accord with the clinical findings seen in other cases *in vitro*.

It was found impossible to establish any definite symptomatology for early ocular onchocerciasis. Even in a literate group of 224 schoolchildren, most of whom were between 12 and 18 years of age, such symptoms as were found, were at least as common amongst those who showed no signs of the disease whatever, as amongst those who had microfilariae and lesions in the eyes; the latter also frequently denied having any trouble. The tolerance of Africans is high in this respect, and this observation does not necessarily apply to other races.

Diagnosis.—Early recognition of ocular onchocerciasis is of vital importance, as it is in this stage that treatment will offer hope of success. In this series, the

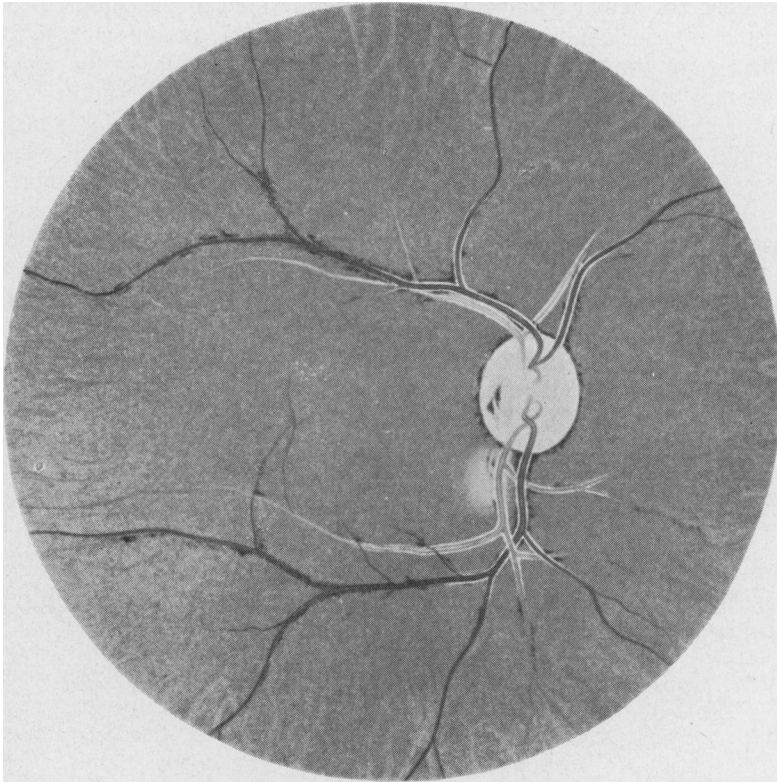


FIG. 1.—Copy of oil sketch made by the writer, from right fundus of Case H.44, showing typical perivascular cuffing and optic atrophy.

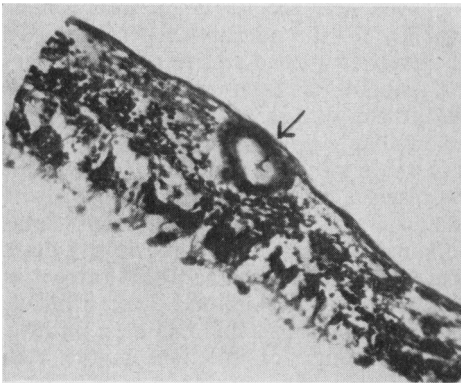


FIG. 2.—Section of retina from a case of onchocerciasis (Van Gieson $\times 146$) cut near optic disk.



FIG. 3.—Section from same eye as in Fig. 2 (Van Gieson $\times 70$).

earliest evidence of ocular involvement was often limited to the finding of microfilariae in the anterior chamber without any demonstrable pathological lesion; in others, there were scanty patches of nummular keratitis which, in the opinion of the writer, may be regarded as diagnostic if accompanied by nodules or presbydermia, or by laboratory evidence of the disease. It was found that a history of having visited an endemic area could often be elicited, but on the other hand no reliance could be placed on a denial of this in the class of patient most often affected. Repeated clinical and laboratory examinations were often necessary to establish a diagnosis. Microfilariae in the anterior chamber are almost certainly those of *O. volvulus* and attempts to find embryos of *D. streptocerca* have proved unsuccessful (Sarkies, 1951). Seven cases in this series, which showed microfilariae in the aqueous at the first examination in the absence of any other ocular or systemic manifestations of onchocerciasis, ultimately showed positive skin smears.

Therapeutic tests with Hetrazan were suggested as a confirmatory diagnostic measure by Ridley (1950). This technique has undoubted value, especially outside the tropics when infection with other filariae can be excluded; in lightly infected cases, however, the allergic reaction which occurs may be so mild that it cannot be distinguished from that which occurs with *Loa loa* or *Wuchereria bancrofti*, either of which may be coexistent with *O. volvulus*.

Diagnosis of infection with *O. volvulus* rests in demonstrating the microfilariae in the skin, but recognition of ocular involvement necessitates patient and repeated examinations of the eyes by all available methods.

Course of the Disease.—Very little is known of the course of the disease in onchocerciasis either with or without treatment: this is because patients come from remote villages, and when they return home follow-up becomes impossible. For this reason the following case is worth recording as the patient had been examined 5 years earlier by the Command Ophthalmologist on being invalided from the army, and brief notes were available from the documents of his medical board.

Case H.11, K. A., a farmer, aged 25, who lived near the R. Volta, was seen on January 12, 1951, during a review of his disability for the ministry of pensions. On examination he had slight presbydermia, and there was a small scar in the midaxillary line over the right seventh rib, where, he stated, a nodule had been removed. His visual acuity was 6/36 right and counting fingers left, there were scanty microfilariae in the aqueous of both eyes; the right fundus showed a clearly circumscribed patch of choroiditis with gross pigment aggregations in the upper nasal quadrant, and in the left there was a similar lesion involving the macula; there was optic atrophy with atrophic cupping of the disk on both sides. Skin smears showed numerous microfilariae of *O. volvulus*. A copy of this patient's original medical board proceedings dated October, 1945, showed that exactly similar patches of choroiditis had been present at that time, and there had been no change in his visual acuity since that date; a nodule containing an adult onchocerca had been removed and his skin snip had been positive. The pensioner stated that he had been given "a course of injections in the V.D. Department" before his discharge from the army.

The retinal lesions in this case were not typical of onchocerciasis and it is doubtful if they were in fact the result of this disease. The Command Ophthalmologist had reported "Bilateral choroido-retinitis possibly due to onchocerciasis", having evidently had similar doubts. This was therefore a patient with

onchocerciasis known to have had the infection for at least 5 years without any definite deterioration in his condition.

Treatment.—Various drugs have been used in the treatment of onchocerciasis, but with two exceptions few have given much promise of success. Van Hoof and others (1947) found that “Antrypol” B.P.C. Suraminum, other proprietary names Bayer 205, Naphuride, and Germanin) showed a filaricidal effect against both the adult onchocerca and the microfilaria. Hewitt and others (1947) reported striking results using “Hetrazan”, one of the piperazine derivatives, against other filarial infections in the cotton rat and dogs. Since then Burch (1949) has compared the effect of these drugs and was able to conclude that Antrypol was the more effective against both microfilariae and adult *O. volvulus*.

Considerable difficulties have been encountered in attempting treatment of African patients in this series of cases. In the first place, only a few were willing to come into hospital for treatment; the occurrence of side-reactions of any severity acted as a powerful deterrent to their continuing treatment, and conversely, in a number of cases, the absence of any early and dramatic signs of improvement resulted in the patient losing interest and ceasing to attend. It was only possible to collect 33 cases, all of which showed ocular involvement, which were treated with Antrypol alone or with a combination of Antrypol and Hetrazan. Two cases complicated by secondary glaucoma were treated surgically by trephining.

Five cases were treated primarily with “Banocide”, another piperazine derivative, the dosage being 1.35 g. daily for 20 days; this resulted in a minimum dosage of 367 mg./kg. body weight, which is a good deal higher than that employed by Burch. In all five cases microfilariae had disappeared from the aqueous within 8 days of starting treatment: in one case, skin smears were positive throughout treatment; in the remaining four, the skin had become clear of embryos by the 10th to the 15th day but was showing embryos once again within 3 weeks of completing treatment; of these four, two had numerous microfilariae again visible in the aqueous within 3 weeks of completing their course of treatment. All these cases showed side-effects in the course of treatment, the main change in the eyes being a marked ciliary injection starting on the first day of treatment and clearing by the sixth day; one case which showed evidence of a localized retrobulbar neuritis is described elsewhere (Case S.200). Allergic skin eruptions, though they did occur, were not so severe as to necessitate stopping treatment, as all were hospital cases. The comparative mildness of these side-reactions may have been due to the fact that Anthisan 0.2 mg. was given with each dose of Banocide for the first few days. Four of the cases were subsequently treated with Antrypol, and it was found that side-reactions were noticeably less severe than in cases which had not previously had Banocide.

In all, 32 cases of onchocerciasis were treated with Antrypol; these had microfilariae in the anterior chamber, with or without other clinical lesions; 1 g. was given intravenously once weekly for 8 to 9 weeks. Four of these cases had previously received a full course of Banocide, 22 received Antrypol alone, and six were given 6.75 g. Hetrazan after completing a course of Antrypol. The periods over which it was possible to follow the cases varied; one was seen 9 months after beginning treatment. The effects of Antrypol on the eyes were remarkably constant. It was found that the microfilariae disappeared from the aqueous between the fourth and sixth weeks of treatment. At about this time, in

twenty of the cases, there was evidence of a mild iridocyclitis; fine deposits of iris pigment appeared on the anterior surface of the lens or festooned on the threads of persistent pupillary membrane which are commonly seen in African eyes. Ciliary injection was slight if it occurred at all, and no patient complained of any ocular symptoms in the course of treatment. Patches of nummular keratitis appeared for the first time in twelve of the cases, during the fourth week of treatment, and became more numerous in nine other cases in which they had been present before. Pruritus and allergic skin eruptions occurred in every case during the fifth or sixth week of treatment, but in only one case were they so severe as to warrant admission to hospital; in general the side-effects were less severe than with Banocide. Five cases developed albuminuria but this cleared up after temporary cessation of treatment. Anthisan was given only after the onset of skin manifestations.

TABLE II
EFFECTS OF TREATMENT ON DEGREE OF INFESTATION

Case No.	Treatment	Initial Skin Smears	Week of Treatment						3 Months after Completion		Antrypol mg./kg.
			5th		7th		9th		Eyes	Skin	
			Eyes	Skin	Eyes	Skin	Eyes	Skin			
S.176	X	+++	O	P	O	O	O	O	P	—	120
S.200	X	+++	O	P	O	P	O	P	O	—	170
H.26	X	+	O	—	O	—	O	—	O	—	106
H.27	X	—	P	P	O	P	O	O	—	—	169
K.59	Y	—	O	O	O	O	O	O	O	O	133
K.72	Y	+	O	O	O	O	—	—	—	—	150
K.160	Y	+++	O	P	O	O	O	O	O	—	161
S.174	Y	—	O	P	O	O	O	O	O	O	158
S.180	Y	+	O	P	O	O	O	O	O	O	127*
S.192	Y	—	O	P	O	P	P	O	O	O	137
K.2	Y	—	P	P	—	—	P	P	—	—	26
K.64	Y	+	P	O	O	P	O	O	—	—	121
K.121	Y	+++	P	P	—	—	—	—	—	—	31
S.189	Y	+	P	P	P	—	—	—	—	—	62
S.190	Y	+++	P	P	P	P	—	—	—	—	143
S.227	Y	+++	P	P	—	—	—	—	—	—	38
H.2	Y	+++	O	P	O	P	O	P	O	—	153†
H.4	Y	+++	P	P	P	P	P	—	—	—	140
H.5	Y	+++	P	P	P	P	P	—	—	—	147
H.7	Y	—	O	P	O	P	O	O	O	O	117
H.16	Y	—	O	P	O	O	O	O	—	—	122†
H.20	Y	—	O	O	O	O	O	O	O	O	101
H.28	Y	+++	P	P	O	P	O	P	O	+	163
H.29	Y	—	O	P	O	O	O	O	O	O	114
H.6	Y	+++	O	P	O	P	—	—	—	—	69
H.10	Y	+	O	+	—	—	—	—	—	—	43
K.158	Z	+++	P	P	P	P	P	—	O	O	169‡
K.103	Z	+++	P	P	P	P	O	O	O	O	146‡
K.159	Z	+++	P	P	P	P	O	P	O	+	138‡
K.154	Z	+++	O	P	O	P	O	—	O	+	37‡
H.3	Z	+++	O	P	O	P	O	O	O	O	161‡
H.69	Z	+++	P	P	O	P	O	+++	O	+	167‡

X Antrypol preceded by full Banocide course.

Y Antrypol alone.

Z Antrypol followed by short course of Hetrazan.

P *Mf* present not counted.

O No *mf* seen.

*Trachoma.

† Bilateral glaucoma.

‡ Skin negative in 10th week of treatment.

+ = 1-20 *Mf* in thick drop.

++ = 20-40 *Mf* in thick drop.

+++ = 40-100 *Mf* in thick drop.

++++ = 100 *Mf* in thick drop.

No case showed deterioration in visual acuity during treatment with Antrypol; conversely, there was no improvement in the vision of any patient who showed loss of visual acuity due to retinal lesions. The effects of treatment on the degree of infestation with onchocerciasis are summarized in Table II.

In the course of observation an attempt was made to estimate the intensity of infection at different stages of treatment. In all cases the numbers of microfilariae seen in a skin smear were counted before starting treatment, and counts were made again in some cases at the end of the course of Antrypol and at the final examination in all those cases which could be followed for 3 months. This is obviously a very rough guide, but as far as possible smears of a constant size were made.

At the end of treatment, ten out of 25 patients still had positive skin smears and five still had microfilariae in the aqueous; 3 months after finishing treatment, nine out of twenty patients had positive skin smears, one showing microfilariae in the aqueous, and of these two had been free previously and had relapsed. All cases showed an appreciable reduction in the number of parasites in skin smears either during or after treatment, and in every case but one the parasites had disappeared from the eyes. The administration of Hetrazan after Antrypol caused a temporary disappearance of the embryos in those cases which still had positive smears. In eight cases, the serum Antrypol was estimated at varying periods after completing treatment (Table III). These results show that relatively high concentrations of the drug may be expected in the blood for periods up to 3 months, but it was not possible to correlate the level of the serum Antrypol with the presence or absence of parasites in skin smears.

TABLE III
ESTIMATION OF SERUM ANTRYPOL AFTER COMPLETING TREATMENT

Case No.	Antrypol mg./kg.	Weeks since last Injection	Serum Antrypol mg./100 ml.	Skin Smear	Mf in Eyes
K.59	133	10	8.0	Negative	Nil
K.154	37	10	5.5	Positive	Nil
K.158	159	10	10.0	Negative	Nil
S.174	158	11	9.6	Negative	Nil
S.176	120	10	9.5	Positive	Present
S.180	127	14	6.0	Negative	Nil
S.200	170	10	7.6	Positive	Nil
H.69	167	8	4.7	Positive	Nil

In general, it may be deduced that with the dosage employed, damage to the eyes in individual cases of onchocerciasis may be prevented or arrested by means of Antrypol and that this effect lasts longer than that of the Banocide group of drugs: the administration of Banocide or Hetrazan after Antrypol is of value in those cases which still have strongly positive skin smears at the end of a course of Antrypol. The easier method of administration, the less severe side-reactions, and the better retention in the tissues make Antrypol the drug of choice, especially where there is a likelihood of re-infection. The fact that infection persisted in nearly 50 per cent. of cases 3 months after completion of treatment makes it seem unlikely that either Antrypol or Banocide is a cure for onchocerciasis, and in

order to prevent visual loss or blindness it is necessary to keep cases under repeated observation, so that at any sign of recurrence of microfilariae or actual lesions in the eye, further treatment can be given. There is some evidence to show that the administration of Anthisan with filaricidal drugs to some extent ameliorates the allergic side-reactions.

Surgical Treatment.—Surgical treatment in cases of onchocerciasis in this series was limited to the relief of ocular hypertension in two cases complicated by secondary glaucoma.

Case H.16, Y. O., a farmer, aged 68, complained of increasing loss of vision for about 4 months, with a vague history of "pains in the eyes" and skin irritation. On examination there was presbydermia excessive for his age, visual acuity was reduced to recognition of hand movements, and there was marked sclerosis of both lenses. The tension as recorded by a Schiötz tonometer was 35 mm. Hg in the right eye and 40 mm. Hg in the left; the average diurnal variation over 3 days was 9 mm., and the tension after eserine fell to 28 mm. in the right eye and 32 mm. in the left. Skin smears showed numerous microfilariae of *O. volvulus*, but there were no microfilariae in the anterior chamber or in conjunctival snips. On October 11, 1950, he was given eserine drops twice daily and Antrypol 1 g. weekly. On November 18, 1950, the tension was still high and it was evident that he was not using the eserine regularly; he was therefore admitted to hospital and the eyes were trephined, allowing a week between operations; there was no undue reaction after operation. When last seen on January 3, 1951, the eyes were quiet, the tension being 20 mm. Hg right and 24 mm. Hg left, both trephines were draining well, and the visual acuity was unchanged. He had finished his course of Antrypol and skin smears were negative for microfilariae. Sections of the scleral disk and the excised slip of iris showed no microfilariae, nor did the aqueous which escaped at operation. In the right eye projection was fair, and the patient was advised to return later for cataract extraction.

Case H.2, K. W., a farmer, aged 26, complained of dimness of vision, which he said had been getting worse for about a year; he denied ever having had any pain in the eyes. On examination he was found to have presbydermia but no nodules. His visual acuity was reduced to hand movements in the right eye and 6/36 in the left, but as he was illiterate these must be regarded as approximations. He had a few nummular opacities in both corneae, the right eye showed numerous cells in the aqueous with a few fine cellular deposits on the posterior corneal surface, and in the left eye there were a few definite pigmented keratic precipitates; no microfilariae were seen, but conjunctival biopsies from both eyes showed microfilariae and there were numerous *m. volvulus* in skin smears. The pupils were small and reacted sluggishly to light, the tension was 62 mm. Hg Schiötz in both eyes, and both optic disks showed deep glaucomatous cupping.

He was admitted to hospital on February 7, 1951, and treated with atropine and local heat; 3 days later the tension had fallen to 40 mm. Hg in the right eye and 44 mm. Hg in the left. This level being maintained, on February 25, 1951, the left eye was trephined under retrobulbar anaesthesia, and a similar operation was done on the right eye 4 days later. In each case the post-operative course was uneventful. He had been given Antrypol by injection from the outset, and it is interesting that microfilariae were seen for the first time in the aqueous during the fourth week of this treatment. After the completion of his Antrypol course on May 14, 1951, the aqueous was again clear and the conjunctival and skin biopsies were negative; the trephines were draining well and the tension was 22 mm. Hg in the right eye and 24 mm. Hg in the left. The visual acuities were 6/60 in the right eye and 6/24 in the left.

The treatment of glaucoma occurring as a complication of onchocerciasis poses some interesting problems. The mechanism of the aetiology of glaucoma in this

disease is by no means clear. In Case H.2 it seems probable that the hypertension was secondary to uveitis caused by the presence of *mf. volvulus* in the anterior segment of the eye, and the presence of marked glaucomatous cupping suggested that the condition had been present for some considerable time; if this hypothesis were correct, then the logical approach was to treat the uveitis with mydriatics and heat, at the same time eliminating the exciting parasite. It has been shown, however that the known methods of treating onchocerciasis are themselves liable to cause a mild iridocyclitis which could be expected to aggravate the glaucoma still further. In Case H.16, although there was no evidence of uveitis and microfilariae were at no time demonstrated in the eye, onchocerciasis as an exciting cause of glaucoma cannot be excluded, since it has been shown that vascular and other lesions of the posterior segment occur in onchocerciasis in the absence of demonstrable microfilariae. In both cases, therefore, medical treatment was applied on general principles with partial success. Antrypol was chosen as a filaricide in preference to one of the piperazine derivatives, as its action was known to be slower and the allergic side-reactions less severe.

The principal indication for surgical intervention was the necessity for prevention of further visual loss due to prolonged ocular hypertension; but in dealing with the rural population of tropical countries, other factors have to be taken into account. Elliot (1920), after experience in India, pointed out that surgery was often necessary in cases which would be treated conservatively if only patients could be followed-up. Trephining was the operation of choice, as it has been found that manipulation of the iris during iridencleisis in deeply pigmented African eyes often results in dense deposits of pigment on the anterior surface of the lens, which in itself causes a lowering of the visual acuity. By gentle pressure on the prolapsed knuckle of iris with a repositor after completion of the trephine, the aqueous can be released slowly and the risks of sudden decompression are avoided; further, any pigment which is released during this stage and during the subsequent iridectomy does not find its way into the anterior chamber.

Riboflavine in Onchocerciasis.—While working in the Northern Territories of the Gold Coast, Saunders (1929) noticed the presence of onchocerciasis, but he attributed the blindness which he found in the area to malnutrition rather than to that disease. Fitzgerald Moore (1930–1936) described optic atrophy associated with vitamin B deficiencies in schoolboys in Nigeria. This work was done in a district subsequently shown by Nwokolo (1950) to be endemic for *O. volvulus*. Recently, the present writer saw a case of onchocerciasis in which there were numerous microfilariae in the anterior chamber and in snips from the conjunctiva but no other demonstrable lesions, and the visual acuity in this case improved from 6/12 to 6/5 with riboflavine by mouth in dosages of 9 mg. daily for 21 days. Since then an attempt had been made to collect a series of literate cases of a similar nature; three literates have been seen, and also two illiterates whose intelligence enabled the visual acuity to be assessed fairly accurately; these cases are reported more fully below.

Case H.26, E. T., a lorry driver, aged 25, who had one year's service in the army, complained of "soreness of the eyes for two weeks"; he had visited many areas known to be endemic for onchocerciasis. Examination showed numerous active microfilariae in the anterior chamber, and there was a patch of presbydermia over right scapula, but no nodules were found. A conjunctival snip showed microfilariae, and stained skin

smears showed microfilariae of *O. volvulus*, and of *D. streptocerca*. Visual acuity was 6/12 in both eyes and there were no other abnormalities.

He was given riboflavine tablets by mouth (9 mg. daily) and after 14 days his visual acuity was 6/6 in both eyes; after a further 7 days' treatment vision had improved to 6/5 in both eyes, though microfilariae were just as numerous in the anterior chamber and laboratory findings were still positive.

Case H.27, E. N., a schoolboy, aged 14, complained of "black wormlike objects" obscuring his vision. Visual acuity was 6/9 in both eyes; there were numerous microfilariae in both anterior chambers, two faint nummular opacities in the left cornea and one in the right, and a few fine pigmented keratic precipitates in the left eye only; the fundus was normal and there was no refractive error.

He was given 10 mg. riboflavine per day intravenously for 21 days, and at the end of this time vision was 6/5 in both eyes. Examination with ophthalmoscope and slit lamp showed no change in the eye condition.

This patient was seen 3 months later, after a course of Banocide, again complaining of loss of distant vision. He had microfilariae in the anterior chamber, skin snips were positive, and his vision was down to 6/9 in both eyes. On this occasion he was given riboflavine 9 mg. per day by mouth and after 18 days vision was 6/5 in both eyes. He then had a course of 8 g. Antrypol, and a month after this the eyes were clear and repeated skin snips were negative.

Case S.200, A. K., a schoolboy, aged 14, was discovered during the course of a survey to have presbydermia and five typical subcutaneous nodules. He was free of symptoms, but examination of his eyes revealed more numerous microfilariae in the anterior chambers than the writer has ever seen in any other case of onchocerciasis; his visual acuity was 6/5 in both eyes, there were no corneal opacities, and careful examination showed no other clinical manifestations, though smears from the skin were full of microfilariae of *O. volvulus*. He gave a history of having lived all his life in a village on the R. Volta.

He was admitted to hospital on November 9, 1950, and was given Banocide 450 g. with Anthisan 2 mg. As he was an intelligent boy, visual fields were estimated and there were no abnormalities. After one day of treatment he had slight injection of the bulbar conjunctiva and a fairly well marked urticarial rash. On the fourth day the rash was less, he had no microfilariae in the eyes, and skin snips were negative; both optic disks showed a slight vascular congestion but visual acuity was still 6/5 in both eyes. On the fifth day one microfilaria was seen in the right anterior chamber; the patient felt better, but there were fine pigment deposits on the anterior surface of the lens on the right side. On the seventh day the skin had cleared, leaving a fine branny desquamation, but visual acuity in the left eye was only 6/9, that in the right eye being 6/5; both disks showed the same vascular congestion, and investigation of the central fields showed a small paracentral scotoma in the left eye to a 1/1,000 white target; the blind spots were not enlarged. At this point, 10 mg. riboflavine were given intravenously daily and the Banocide was continued at the same dosage. Two days later the visual acuity was again normal, the scotoma had disappeared, and no microfilariae were seen in either eyes or skin. After 21 days, during which the patient had received 28.35 g. Banocide (0.301 g./kg. body weight), he was discharged from hospital; there were no microfilariae in the eyes or skin, vision was normal, and no nummular opacities were present, but there were a few fine pigment granules on the anterior surface of the lens in both eyes.

Case K.2, J. Y., schoolboy, aged 18, found during a survey, complained of loss of distant vision for a period of 10 years, having lived in a known onchocercal area all his life. His skin was normal and he showed no nodules. Distant vision was 6/36 in both eyes, and he could read only J8. Both eyes showed a few embryos in the aqueous,

there were numerous nummular opacities of both corneae, examination of the fundus showed a fine degree of pigimentary mottling of the macula on both sides, which closely resembled senile macular degeneration, and the optic disks were normal. *Retinoscopy was normal and the vision did not correct.*

The patient was given 9 mg. riboflavine daily by mouth as an out-patient, and when seen a week later his vision had improved to 6/24 in both eyes; another week later there had been no further improvement, and, as he was an unreliable patient, he was admitted to hospital and given riboflavine 10 mg. daily intravenously to ensure that he got his treatment. After a week of intravenous riboflavine, the vision had improved to 6/18 in both eyes, when the boy discharged himself from hospital to attend some festival in his village. When seen 7 weeks later he had embryos in the aqueous, positive skin smears, and numerous nummular opacities of the cornea, but his vision remained 6/18 in both eyes. He has now left school and has not been seen since.

Case H.6, M. M., labourer, aged 24, complained of loss of vision which had come on rapidly during the preceding fortnight. On examination vision was 6/36 in the right eye (illiterate "E"), and reduced to counting fingers at 1 metre in the left eye. There were signs of a chronic plastic iridocyclitis which appeared to be of some considerable duration, and in the right eye the fundus showed a disseminated choroiditis with peripheral patches of bone corpuscle pigmentation, perivascular cuffing of the central parts of the retinal vessels, and optic atrophy. He had a marked presbydermia and there was cheilosis and papillary hypertrophy of the tongue. No microfilariae were seen in the aqueous or in conjunctival biopsies, but skin smears showed numerous microfilariae of *O. volvulus*.

This patient was treated with 10 mg. riboflavine intravenously once daily, and atropine drops 1 per cent. to the left eye; after one week the vision had improved to 6/12 right and 4/60 left, and the cheilosis and sore tongue had cleared. The patient was not able to do accurate visual fields, but to confrontation there was a marked restriction of the right peripheral field. There was no further improvement.

Case H.44, B. B., labourer, aged 22, was first seen complaining of loss of vision and of night blindness which had increased during the last 4 months. Visual acuity in the right eye was reduced to hand movements and in the left to 6/12; the corneae were free of any opacities but scanty microfilariae were seen in the aqueous. The right fundus showed an advanced degree of optic atrophy with well marked cuffing of the retinal vessels as they emerged from the disk, and there were patchy areas of retinal degeneration with marked macular involvement. The left fundus showed some pallor of the optic disk, but was otherwise normal apart from a slight increase in pigmentation, which is difficult to assess in Africans. The patient could not co-operate sufficiently to plot the visual fields, though to confrontation they seemed to be reduced almost to fixation on the left side. It was very noticeable that, although he could see well in daylight, as soon as he went into a dim light he was unable to move around the room. Skin snips and smears showed an extremely heavy infestation with onchocerciasis, though there was only a moderate degree of presbydermia.

He was given 10 mg. riboflavine intravenously for 16 days, at the end of which time vision in the left eye had improved to 6/6; there was no improvement in the right eye.

Case H.3, T. K., tailor's apprentice, aged 23, complained of photophobia and lacrimation for some months. He had lived all his life in a riverside town and had attended school there. His visual acuity was 6/5 in both eyes, there was slight vascular injection of the bulbar conjunctiva of both eyes and evidence of marked photophobia. Copious lacrimation was elicited during examination of the eyes. There were numerous peripheral nummular opacities of the corneae, most of which were irregular in outline and in a state of active development, many showing dead microfilariae in the centre of the areas of infiltration; scanty living microfilariae were seen in the aqueous, and both fundi

were normal. The skin showed marked presbydermia and there was one nodule over the occyx; skin smears showed a heavy infestation with *O. volvulus*.

Riboflavine 6 mg. by mouth thrice daily for 14 days had no effect whatever on the symptoms or signs in the eyes.

From the foregoing it is evident that the administration of large doses of riboflavine, either by mouth or by injection, produces functional improvement in cases of onchocerciasis when the visual acuity is diminished as a result of lesions of the posterior segment, though not in corneal lesions. This improvement is most marked in early cases, though some effect may be expected when there is retinal damage and early optic atrophy; in some cases improvement is limited to one eye in which the lesion is less advanced. There is no conclusive evidence to show at which point in the visual arc riboflavine acts; the clinical findings, supported by pathological evidence from advanced cases, suggest that the lesion may be primarily vascular, either in the retina or in the optic nerve. Stannus (1944) suggested that stasis or "capillary dysergia" may result from riboflavine deficiency, and Axelrod and others (1942) showed experimentally that riboflavine takes part in tissue cell metabolism; a reaction specific to riboflavine and unaffected by biotin or pantothenic acid.

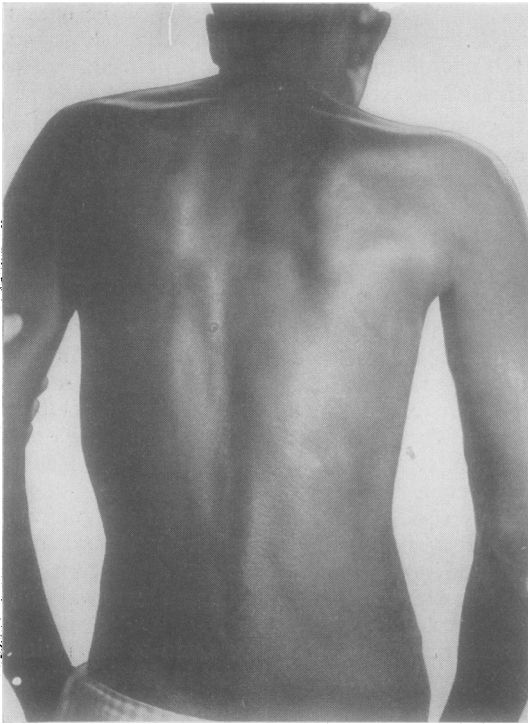


FIG. 4.—Limited presbydermia in African with onchocerciasis, localized around a subcutaneous nodule in the lumbar region.

One of the cases described above (H.6) showed other manifestations of riboflavine deficiency, a condition which can be expected in the Gold Coast where the intake of animal protein is low. Such animal protein as is taken often consists in sun-dried fish, and all food is usually exposed to strong sunlight for considerable periods, a factor shown by Williams and Cheldelin (1942) to reduce the riboflavine content to a considerable extent. In another case (S.200) there was evidence of a limited optic neuritis developing during treatment with hetrazan; the pathological lesion here was probably similar to the localized cellular infiltration around dead microfilariae in the optic nerve (Hughes and Daly, 1950).

It seems probable that other factors may also play a part.

Colbourne and others (1950) showed that the Gold Coast villager, even in the more prosperous agricultural areas, lives in equilibrium with several parasites, such as those of malaria, schistosomiasis, and hookworm; it may be that when

a further infection with onchocerciasis becomes too heavy, the host-parasite balance is disturbed and lesions of malnutrition result. In cases of this nature, riboflavine or treatment of other intercurrent disease might be equally effective. Therefore, in the absence of scientific proof of a true riboflavine deficiency in cases of onchocerciasis, for the time being this line of treatment must remain largely empirical.

Comment

The early signs of ocular involvement in onchocerciasis are so slight that any estimates of the incidence of this complication made without careful examination to exclude the presence of microfilariae in the eye must be low; this fact probably accounts for the considerable variations in published figures. In the present series of 319 cases of proved onchocerciasis, 14 per cent. showed microfilariae in the eye with no ocular lesions, and 16 per cent. showed nummular opacities which were often very scanty; it must be remembered that the great majority of these cases were mild ones but there is no means of knowing how many would ultimately go blind. Scott who examined the eyes of fit soldiers from the Cameroons also found a high proportion of cases with microfilariae. It seems likely therefore that some other factor, such as malnutrition or intercurrent disease, may play a part in the onset of actual lesions.

While it appears that damage to the eyes can be arrested, or in early cases prevented, by the use of Antrypol, it is extremely doubtful on the evidence of this series that this effect is permanent. There is some indication for the use of one of the piperazine derivatives after completion of a course of Antrypol in those cases in which skin smears still show embryos, but in all cases a prolonged follow-up is necessary to avoid damage to the eyes in the event of relapses. Glaucoma occurring in the course of ocular onchocerciasis requires treatment on general principles.

The above measures offer reasonable hope of preventing blindness in individual cases but are not applicable on a wide scale in rural tropical areas where the incidence of the disease is highest. A reduction in transmission could be expected from treatment of one hundred per cent. of the population in such areas by reducing the infectivity of the human host. For work of this nature, however, a drug is needed which does not cause severe side-reactions and is reasonably cheap, and the administration of which can safely be left in the hands of semi-skilled assistants. None of these conditions is fulfilled by antrypol or by the piperazine derivatives. In limited areas the incidence of the disease has been successfully reduced by eradication of the *Simulium damnosum* vector with D.D.T.; Garnham and McMahon (1947) have reported favourably on this method from Kenya, and it has also been used by Wanson, Courtois, and Lebiéd (1949) in Leopoldville.

Little is known of the life history of the causative parasite, e.g., the development of the mature embryo from the time of its injection into the tissues of man until it forms a fully mature adult producing numerous microfilariae;

when more is known it may be found that at some stage in this process it is susceptible to treatment.

Summary

A brief review is given of the general and ocular findings in onchocerciasis as previously described in the literature, followed by a description of the ocular manifestations as they were seen during the investigation of 319 cases in the Gold Coast. The great majority of these cases were mild ones and emphasis is laid on the early signs of ocular involvement which occur before irreversible damage is done to the eyes. Confirmatory diagnostic measures are discussed in the light of personal experience.

Cases are described suggesting a vascular origin for the lesions seen in the posterior segment of the eye; this finding is supported by pathological evidence and the clinical appearance is considered to be specific.

Results are summarized of filaricidal therapy in 33 cases with ocular involvement treated with Antrypol, or with a combination of Antrypol and one of the piperazine derivatives. The drugs are shown to have at least a palliative effect, and no dangerous side-reactions occurred in the eyes during treatment.

Two cases complicated by a secondary glaucoma are described in full and their medical and surgical treatment discussed.

The effect of riboflavine administration in cases with visual loss and early optic atrophy is described. While no indication of the mechanism could be found, the beneficial effect of this form of therapy in six cases showing those features is demonstrated.

I wish to thank Dr. R. L. Cheverton, D.M.S. Gold Coast, for permission to carry out this investigation and to publish the results.

Dr. M. H. Hughes of the Medical Research Institute, Accra, has carried out many of the laboratory investigations quoted and has very kindly allowed me to reproduce photomicrographs of some of his slides; further he has been an unfailing source of invaluable advice.

I also have to thank Mr. J. B. Johnston of the West African Council for taking the clinical photograph reproduced in Fig. 3, and Mr. Hepple for the photomicrographs in Figs 2 and 3.

REFERENCES

- ASHBURN, L. L., BURCH, T. A., and BRADY, F. J. (1949). *Bol. Ofic. sanit. pan-amer.*, **28**, 1107.
 AXELROD, A. E., POTTER, V. R., and ELVEHJEM, C. A. (1942). *J. biol. Chem.*, **142**, 85.
 ——— SWINGLE, K. F., and ELVEHJEM, C. A. (1942). *Ibid.*, **145**, 297.
 BLACKLOCK, D. B. (1926). *Ann. trop. Med. Parasit.*, **20**, 1.
 BRYANT, J. (1935). *Trans. roy. Soc. trop. Med. Hyg.*, **28**, 523.
 BURCH, T. A. (1949). *Bol. Ofic. sanit. pan-amer.*, **28**, 233.
 CORSON, J. F. (1922). *Ann. trop. Med. Parasit.*, **16**, 407.
 COLBOURNE, M. J., EDINGTON, G. M., and HUGHES, M. H. (1950). *Trans. roy. Soc. trop. Med. Hyg.*, **44**, 271.
 ELLIOT, R. H. (1920). "Tropical Ophthalmology". Hodder and Stoughton, London.
 GARNHAM, P. C. C., and MCMAHON, J. P. (1947). *Bull. ent. Res.*, **37**, 619.
 HEWITT, R. I., WALLACE, W. S., WHITE, E., and SUBBAROW, Y. (1947). *J. Lab. clin. Med.*, **32**, 1293.
 HISSETTE, J. (1932). *Ann. soc. belge Méd. trop.*, **12**, 433.
 ——— (1938). *Amer. J. trop. Med.*, **18**, Suppl. 1, p. 58.
 HUGHES, M. H. (1949). Dissertation for degree of Doctor of Medicine, University of Oxford.
 ——— and DALY, P. J. (1950). *Trans. roy. Soc. trop. Med. Hyg.*, **43**, 362.
 ——— (1951). *Ibid.*, **45**, 243.
 ——— and SARKIES, J. W. R. (1951). *Ann. trop. Med. Parasit.*, **45**, 73.

- NWOKOLO, C. (1950). *Trans. roy. Soc. trop. Med. Hyg.*, **43**, 493.
- PANCHECO, LUNA (1919). *Bull. Soc. Path. exot.*, **12**, 461.
- PUYUELO, R., and HOLSTEIN, M. H. (1950). *Bull. Méd. trop. Marseilles*, **3**, 397.
- RIDLEY, H. (1945). *British Journal of Ophthalmology*, Monograph Supplement No. 10.
- and ANDERSON, J. (1950). *British Journal of Ophthalmology*, **34**, 688.
- ROBLES, R. (1919). *Bull. Soc. Path. exot.*, **12**, 442.
- SARKIES, J. W. R. (1951). *Lancet*, **1**, 1205.
- (1951). *Trans. roy. Soc. trop. Med. Hyg.*, **44**, 608.
- SAUNDERS, G. F. T. (1929). Gold Coast Colony. Report on the Medical and Sanitary Dept., 1928/29, p. 126. Government Printing Office, Accra.
- SCOTT, J. G. (1945). *Amer. J. Ophthal.*, **28**, 624.
- SHARP, N. A. D. (1926). *Trans. roy. Soc. trop. Med. Hyg.*, **19**, 373.
- (1927). *Proc. roy. Soc. Med.*, **20**, 927.
- (1927). *Ann. trop. Med. Parasit.*, **21**, 415.
- STRONG, R. P. (1934). In R. P. Strong and others, "Onchocerciasis", Part I, Harvard Univ. Press, Cambridge, Mass.
- (1938). *Amer. J. trop. Med.*, **18**, Suppl. 1, p. 1.
- VAN HOOF, L., HENRARD, C., PEEL, E., and WANSON, M. (1947). *Ann. Soc. belge Méd. trop.*, **27**, 173.
- WADDY, B. B. (1949). Personal Report to D.M.S., Gold Coast.
- WANSON, M., COURTOIS, L., and LEBIED, B. (1949). *Ann. Soc. belge Méd. trop.*, **29**, 373.
- and HENRARD, C. (1945). *Rec. Sci. méd. Congo belge*, **4**, 113.
- and PEEL, E. (1945). *Ibid.*, **4**, 122.
- WILLIAMS, R. R., and CHELDELIN, V. H. (1942). *Science*, **96**, 22.
- Bibliography of Onchocerciasis (1950). Published by the Pan-American Sanitary Bureau, New York.