

ANATOMICAL STUDY OF SCHLEMM'S CANAL AND AQUEOUS VEINS BY MEANS OF NEOPRENE CASTS*

PART II. AQUEOUS VEINS (CONTINUED)

BY

NORMAN ASHTON

From the Department of Pathology, Institute of Ophthalmology, London

AN anatomical study of six aqueous veins by means of Neoprene casts has already been reported (Ashton, 1951); it was shown that two arose directly from Schlemm's canal while the remaining four communicated with it indirectly *via* anastomotic branches between the superficial and deep scleral plexuses. All the aqueous veins were of the striated or laminated variety. It has now been possible to study the anatomy of a pure aqueous vein by the same technique and the purpose of this paper is to report the findings.

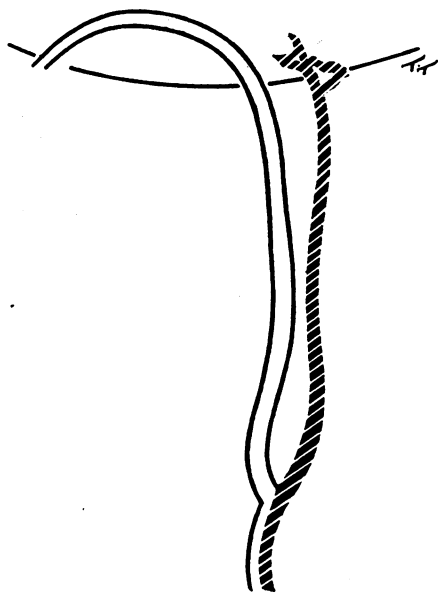


FIG. 1.—Diagram of pure aqueous vein made before operation. Note that it joins with an ordinary vein to form a laminated vein. The vessel was marked with a tantalum wire loop.

MATERIAL AND TECHNIQUE

The patient was a male aged 58 years (Case of Mr. C. Dee Shapland); enucleation was performed for a malignant melanoma of the posterior choroid. An unusually large pure aqueous vein was identified near the limbus at 8 o'clock and a drawing was made (Fig. 1); immediately before enucleation a tantalum wire suture was tied loosely around the vessel.

After operation the anterior part of the eye was removed and a radial cut to the centre of the cornea was made at 12 o'clock.

* Received for publication February 8, 1952.

Neoprene coloured red with carmine was injected into Schlemm's canal and the aqueous vein filled with Neoprene ; the specimen was then digested in pepsin followed by trypsin and after examination it was mounted in gelatin (Figs 2 and 3).

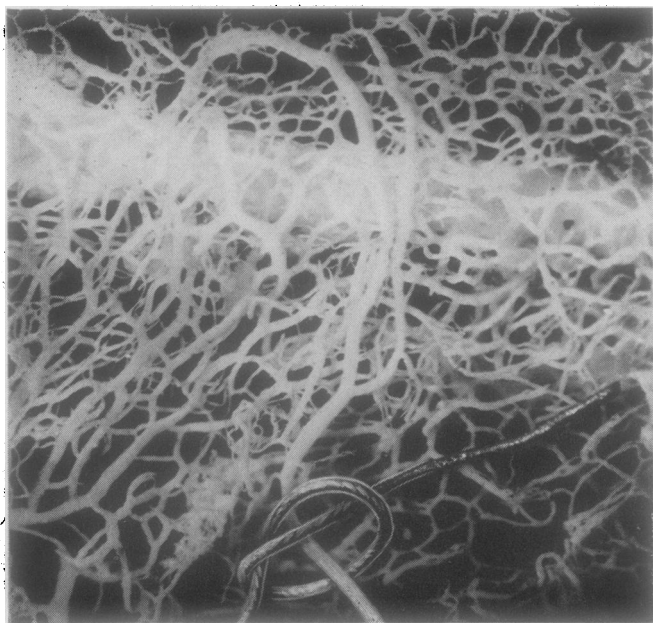
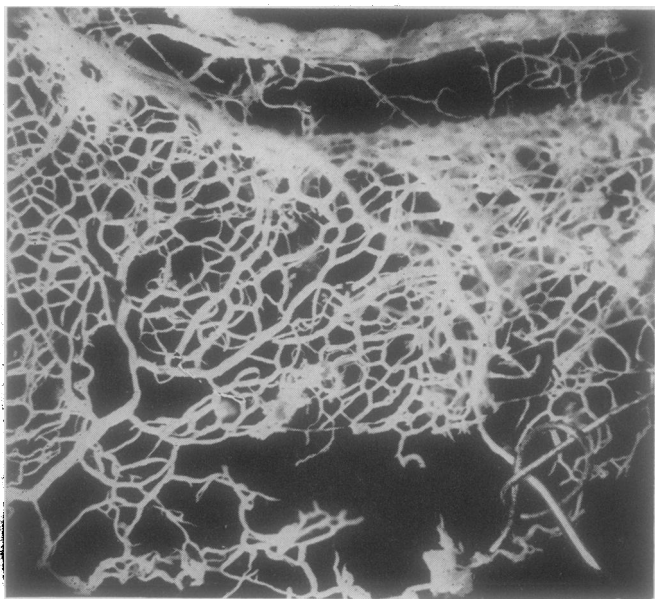


FIG. 2.—Neoprene cast of Schlemm's canal and limbal vessels showing sector containing marked aqueous vein. The tantalum wire loop is still to be seen *in situ*. Details of the origin of the vessel are shown in Figs 3 and 4. $\times 20$.

FIG. 3.—Neoprene cast shown in Fig. 2. The superficial vessels containing the aqueous vein are now deflected downwards to show the direct connections between the vein and the canal. The exact structure can be made out only by microdissection and the details are shown in Fig. 4. $\times 14$.



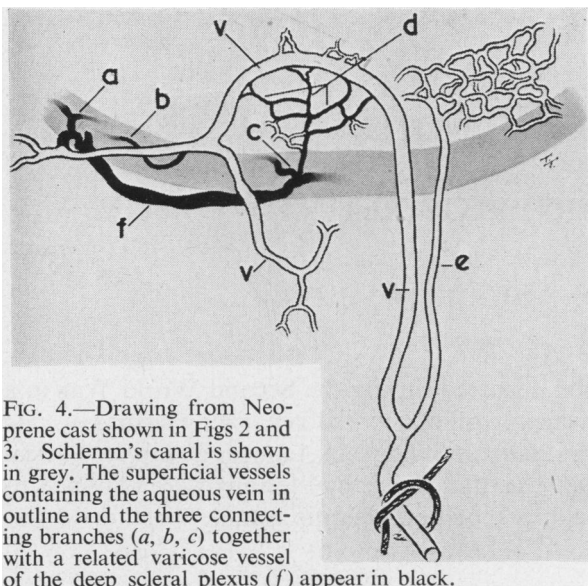


FIG. 4.—Drawing from Neoprene cast shown in Figs 2 and 3. Schlemm's canal is shown in grey. The superficial vessels containing the aqueous vein in outline and the three connecting branches (*a*, *b*, *c*) together with a related varicose vessel of the deep scleral plexus (*f*) appear in black.

FINDINGS

Micro-dissection of the Neoprene cast (Fig. 4) showed that the pure aqueous vein (*v*) did not itself branch out of the canal but communicated with it directly via three channels (*a*, *b*, *c*), two of which (*a* and *b*) opened directly into the vein, while the third (*c*) broke into several small twigs (*d*) before anastomosing with the arch of the vein. The connecting branches (*a* and *c*) communicated with each other at their origin through a large varicose vessel of the deep scleral plexus (*f*). The venous limb (*e*), which in life contained

only blood, was not connected, in its immediate vicinity, either directly or indirectly with the canal.

DISCUSSION

Thus in the seven aqueous veins we have studied, whether they were pure or striated, the source of the aqueous was undoubtedly from Schlemm's canal and their connecting branches varied only in detail. It can therefore be concluded that whether or not a vessel contains aqueous, blood, or a mixture of aqueous and blood, is to a certain extent fortuitous, in that it depends upon the quantity of aqueous inflow permitted by the almost infinite variation in the minute anastomotic connections between Schlemm's canal and the superficial vessels, and upon the opposing venous blood pressure within the receiving vascular bed. Consequently, it is not difficult to understand why the aqueous vein here described, being both a large vessel and having three direct tributaries from Schlemm's canal, should have been, in the early part of its course, a pure aqueous vein.

It is a pleasure to acknowledge my indebtedness to Mr. Arthur Lister who kindly identified and sutured the aqueous vein.

REFERENCE

ASHTON, N. (1951). *British Journal of Ophthalmology*, **35**, 291.

(This study is to be continued in a future issue of this Journal.)