

## HEXAMETHONIUM AND GLAUCOMA\*

BY

A. J. CAMERON AND R. A. BURN

*From the Royal Eye Hospital, London*

THIS investigation was undertaken in an endeavour to decide if the methonium ganglion blocking compounds could be administered to cases of vascular hypertension who were known to be suffering from glaucoma, or to similar vascular hypertensive cases of a glaucomatous disposition although this might not be known, without the danger of subsequent sequelae such as an increase in intra-ocular pressure.

The report by Ullman and Mossman (1950) of the occurrence of glaucoma in cases treated by the belladonna alkaloids administered orally, has raised the question as to whether or not similar dangerous side-effects might result from the administration of the alkamethonium ganglion-blocking agents in vascular hypertension. These authors state that the peripheral action of the alkaloids of belladonna is on the autonomic effector cells and not on nerve endings, producing in the eye (*i*) mydriasis, (*ii*) cycloplegia, and perhaps (*iii*) vasodilatation.

This may elevate the intra-ocular pressure in the following way:

- (*i*) by the mydriasis narrowing the filtration angle,
- (*ii*) by the paresis of the ciliary muscle abolishing the pull on the radial fibres of the scleral spur with loss of pumping action,
- (*iii*) by the vasodilatation leading to a general vascular stasis.

Since pentamethonium and hexamethonium and their similar compounds—now known as the methonium halides—were first used for tentative clinical trial in vascular hypertension, it has been appreciated that, although they possess no true atropine-like activity, using this term in the pharmacological sense of a specific depressor of parasympathetic neuro-effector junctions, the parasympathetic ganglionic synapse depression which is part of their basic pharmacological response might give rise to the same end results as atropine, and produce in predisposed subjects a raised intra-ocular tension subsequent to mydriasis.

The six cases reported by Ullman and Mossman (1950) were receiving extract or tincture of belladonna for general systemic disorders, such as gastric or duodenal ulcer, colitis, hyperacidity, etc., and the advent during such treatment of an ocular hypertension was a complication which had not hitherto been reported with the exception, perhaps, of a case (reported in

---

\* Received for publication May 24, 1952.

1913 by Myashita and quoted by Duke-Elder, 1940) in which acute glaucoma followed the subcutaneous injection of atropine.

Although not an atropine-induced glaucoma, the following unpublished case (recently noted in S. Africa by A. G.) is also of considerable interest:

A female, 75 years of age, who was being treated for hypertension by "Vegolysen" (hexamethonium) tablets administered orally, developed acute glaucoma necessitating operation. This occurred after increasing the dosage of the methonium compound to two tablets (0.25 g. each) three times a day, it having been noted that one tablet produced no effect on the blood pressure. The doctor concerned was of the opinion that glaucoma was a contraindication to the use of the drug, and at the time of administration there was absolutely no evidence of the possibility of this existing.

In the light of the findings of this investigation, this case is very difficult to explain, unless, perhaps, on the basis of coincidence. On the other hand, very many cases of glaucoma have been reported as resulting from the mydriasis subsequent to the local or topical use of atropine and its associates.

Davson and Matchett (1951) report that in the rabbit, section of the cervical sympathetic is sometimes followed by a marked rise in intra-ocular pressure, but there is no clinical evidence that this would occur following the removal of such sympathetic control as only one of the more widespread effects of hexamethonium. Indeed, in the increasing clinical experience with hexamethonium, including in some cases the administration for periods of upwards of 2 years, few untoward ocular effects have been reported, yet it would seem likely that since the clinical potentialities of these compounds were first reported by Organe, Paton, and Zaimis (1949) some cases of potential glaucoma must have been treated for vascular hypertension and other conditions.

Many reports are now available of the findings in series of cases of vascular hypertension after carefully checked and supervised courses of treatment with the various methonium compounds. Burt and Graham (1950) investigating the effect of (C.6) hexamethonium iodide and (C.5) pentamethonium iodide in peripheral vascular disease and hypertension, noted *inter alia* that the pupils became slightly dilated in all of 27 cases (no further details of this visual change being given), that two cases showed transient loss of accommodation, and that the peripheral retinal vessels beyond the second division appeared dilated. Kay and Smith (1950), investigating the effects of these compounds on gastric secretion, note among the side-effects only a suffusion of the conjunctiva as an almost constant finding discernible within a few minutes of intramuscular injection. Campbell and Robertson (1950), reporting treatment by hexamethonium bromide of eight cases of severe hypertension with papilloedema, note among side-effects a blurring of vision which occurred in every case from the beginning of treatment, but unfortunately there is no ophthalmic report on the cause of this or even if it referred only to the use of the eyes in close work.

Rycroft and Romanes (1952), discussing the use of these compounds together with postural ischaemia anaesthesia in ophthalmic surgery, state

that the intra-ocular pressure may fall so low that it fails to register with the Schiötz tonometer, and that the cornea may remain concave until manipulated back into the normal position.

In view of the reported effect of these compounds on ocular accommodation, Locket, Swann, and Grieve (1951), reporting on the use of pentamethonium bromide and hexamethonium bromide in 34 cases of essential hypertension, actually had the intra-ocular pressure checked before and after using the drug. The result indicated that the intra-ocular pressure did not change in any particular direction.

Barnett (1951), comparing the clinical results of pentamethonium and hexamethonium and the side-effects which resulted from the unselective action of these compounds in producing a generalized interruption of the autonomic nervous system, gives ophthalmic information of some importance: 12 cases of vascular hypertension equally divided into pentamethonium and hexamethonium groups showed in every case a fall of intra-ocular pressure.

Mackey and Shaw (1951), reporting a series of 15 cases treated by hexamethonium bromide administered orally, remarked in discussing parasympathetic effects that "almost all patients state that methonium therapy weakens the power of accommodation so that it may be difficult, for example, to read a newspaper". Later, in referring to changes in the "eye grounds", it is stated that no conclusion could be drawn regarding the degree of hypertension necessary to reverse retinopathy.

Turner (1951), in reporting on current therapeutics in the methonium compounds, states that after their use blurring of vision from paresis of accommodation is common and may be persistent.

### Material

Eighteen patients in all were investigated while in-patients; of these seventeen were known cases of glaucoma and the eighteenth was a control. The cases of glaucoma were divided into two unequal groups:

- (i) acute and sub-acute,
- (ii) chronic simple.

It was considered that vascular hypertensives of unknown ocular history, but who were of a glaucomatous predisposition, would be most likely to fall into this latter and larger group.

### Dosage and Method of Administration

The in-patient investigations were carried out in the recumbent position without a pillow. Restall and Smirk (1951) note that after hexamethonium bromide the blood pressure in the arm with the patient erect is usually lower than when he is horizontal. Estimations were made of the blood pressure; intra-ocular tension measured on the Schiötz tonometer; size of pupils measured by the pupillometer; power of accommodation checked against reading capabilities at a known distance; and charting of the visual fields for the presence, or absence, of defects. The

results are set out in Table I. As far as possible, this and all subsequent data in any given case were obtained by the same observer using the same methods and

TABLE I

Case No.	Age	Blood Pressure	Intra-ocular Pressure	Pupil Size (mm.)	Field Defects	Classification of Glaucoma	Clinical Comments
1	54	142/75	R. 25 L. 25	R. 5 L. 5	Markedly contracted	{ Chronic primary	—
2	75	175/100	R. 45 L. 38	R. 3 L. 3	Contracted	{ Bilateral chronic primary	{ R. and L. miotics (Fig. 1)
3	52	155/90	R. 25 L. 60	R. 4 L. 4	Minimal	{ Chronic	{ R. and L. miotics
4	63	134/95	R. 29 L. 72	R. 3 L. 3	Present	{ Simple chronic primary	{ R. and L. miotics
5	39	115/70	R. 38 L. 18	R. 4 L. 4	Sector contraction	{ Simple chronic primary	R. miotics L. trephine, draining well
6	75	188/99	R. 38 L. 38	R. 4 L. 5	Peripheral contraction	{ Chronic primary	(Fig. 2)
7	66	145/98	R. 27 L. 27	R. 4 L. 4	R. Bilateral arcuate scotoma L. Contracted to centre	{ Chronic primary	Circulatory insufficiency extra-systoles ++ (Fig. 3)
8	66	186/115	R. 28 L. —	R. 4 L. —	R. Contracted all round	Chronic primary	R. broad iridectomy, 1951. R. miotics L. enucleated, following haemorrhagic glaucoma
9	56	195/100	R. 40 L. 40	R. 4 L. 4	Full	Chronic primary	—
10	77	125/60	R. 16 L. 16	R. 3 L. 3	Sector contraction	{ Bilateral chronic primary	R. cyclodialysis, 1949 R. miotics L. trephine, 1951
11	56	180/120	R. 20 L. 50	R. 5 L. 5	R. Contracted above L. Peripheral constriction to near centre	{ Bilateral chronic	R. trephine, 1949 L. trephine, 1949
12	58	138/88	R. 36 L. 26	R. 2 L. 2	{ None	Sub-acute primary	{ R. and L. miotics (Fig. 4)
13	68	165/85	R. 41 L. 33	R. 1.5 L. 1.5	{ Full	? Secondary	R. miotics
14	46	100/40	R. 54 L. 35	R. 2 L. 2	{ Full	R. Primary acute L. Chronic	R. and L. miotics R. anterior sclerotomy 1951
15	69	185/115	R. 65 L. 55	R. 2 L. 2	Sector contraction to near centre	{ Chronic primary	R. and L. miotics L. decompression, 1952
16	80	130/75	R. 25 L. 21	R. 3 L. 3	Peripheral contraction	Bilateral chronic	{ R. and L. miotics
17	50	165/58	R. 30 L. 25	R. 4 L. inactive	{ Full	Bilateral chronic primary	{ R. and L. miotics. No visible synechiae (Fig. 5)
18	28	126/70	R. 26 L. Active corneal ulceration	R. 5	{ Full	{ Non-glaucomatous	Under treatment for ulcerative keratitis

instruments. This was considered very important with regard to intra-ocular pressure because of the individual variation in the Schiötz tonometers, in some of which the norm is represented by a pressure of 18 mm. Hg while in others it is as high as 22 mm. Hg.

To minimize any individual idiosyncrasy to the drug and to observe any undue

side-effects each case was given an initial trial injection of 10 mg. hexamethonium bromide intramuscularly.

For the purpose of these investigations and to obviate over-lapping and accumulation, it was considered that it was sufficient to give one dose in 24 hours starting from 10 mg. and increasing to 20, 40, 60, 80, and 100. Locket, Swann, Grieve, and Player (1952) assessed the maximum excretion of the drug to be within 24 hours.

Where the state of the patient's intra-ocular tension called for the administration of miotics these were given and noted in the graphs. It was also noted where one or both eyes had been operated upon; this accounts for some of the very low intra-ocular pressure readings.

Any case which, after an injection, showed signs of distress or collapse (and this did occur several times) was quickly restored by raising the foot of the bed, and thereafter the drug was stopped.

In each case the blood pressure and intra-ocular pressure were taken:

- (i) at the time of the injection,
- (ii) 15-30 min. afterwards,
- (iii) 1½-2 hrs afterwards.

The curves are accurate for the times of the injections and readings concerned but not necessarily for limits in between. To avoid confusion with the intra-ocular pressure curves only the systolic blood pressure curves are recorded.

On discharge from hospital each case continued under observation as an out-patient and was given two 25 mg. tablets hexamethonium bitartrate by mouth thrice daily. It was realized, of course, that the dose by mouth should be of the order of ten times that given by injection. Two patients whose cases were complicated by cardiac conditions and in whom such medication without supervision was considered unsafe, were exempted from this further treatment. Every seventh day the patients reported to the hospital to have their blood pressure and intra-ocular pressure noted. The results are discussed below.

### Clinical Findings

It was soon apparent that pupillary changes and alterations in the power of accommodation were so inconstant and variable as to render further estimation valueless. These variations were caused by the fact that many patients were under miotics, and others were of such an age that little of their power of accommodation remained. Attention was therefore focused on the blood pressure and intra-ocular tension.

**Case Reports.**—The details of five patients considered to be representative of the eighteen examined, are described below. The accompanying graphs (Figs 1 to 5) exemplify the typical curve changes noted in the text.

**(1) Case 2, aged 75.**—*Bilateral Chronic Primary Glaucoma with Vascular Hypertension* (on miotics, Fig. 1, opposite).

Intra-ocular pressure fell 9 mm. after the initial dose of 10 mg. Pressure tended to rise again in the next 24 hrs but after the second injection there was a fall of 15 mm. A slight rise followed in each 24 hrs but with a greater fall after each injection. At the end of 5 days, the intra-ocular pressure was about 10 mm. less than at the beginning.

Systolic blood pressure fell an average of 25 mm. Hg after each injection.

Mean fall in intra-ocular pressure was 10 mm.

The fourth injection was omitted and neither the blood pressure nor the intra-ocular pressure fell noticeably.

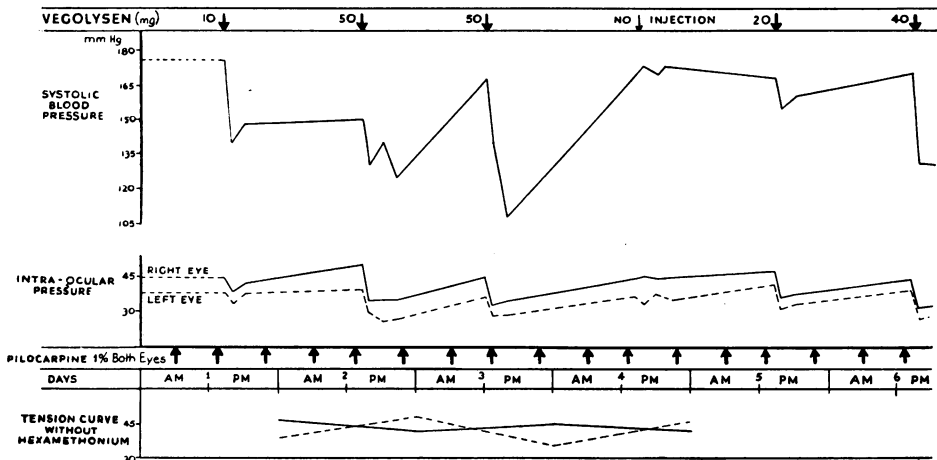


FIG. 1.—Case 2, aged, 75, bilateral chronic primary glaucoma.

(2) Case 6, aged 75.—Chronic Primary Glaucoma with Vascular Hypertension. (Fig. 2).

Intra-ocular pressure showed a marked drop after each injection with a very gradual tendency to rise prior to the next.

Systolic blood pressure on the whole seemed to fall steeply after each injection, but rose again relatively quickly.

Mean fall in intra-ocular pressure *c.* 10 mm.

After the fourth injection the blood pressure even tended to rise although the intra-ocular pressure tended to fall a little.

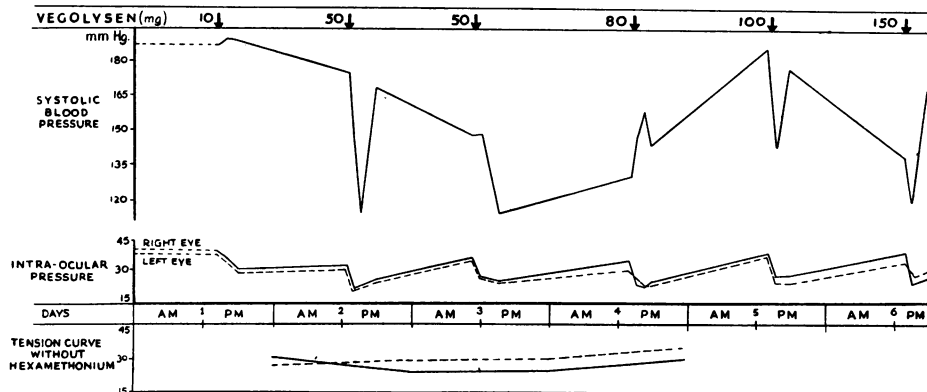


FIG. 2.—Case 6, aged 75, chronic primary glaucoma.

(3) Case 7, aged 66.—Chronic Simple Glaucoma with Circulatory Insufficiency and Extra Systoles. (Fig. 3, overleaf).

Intra-ocular pressure showed only a very slight variation in each eye after each injection, but that tended downwards. At the end of the investigation the reading was much the same as at the beginning and throughout the whole period the excursion was very limited.

Systolic blood pressure oscillations, very variable; prior to the fourth injection rose from about 140–190 to fall very steeply immediately afterwards.

A similar curve variation was not noticeable in the intra-ocular pressure readings.

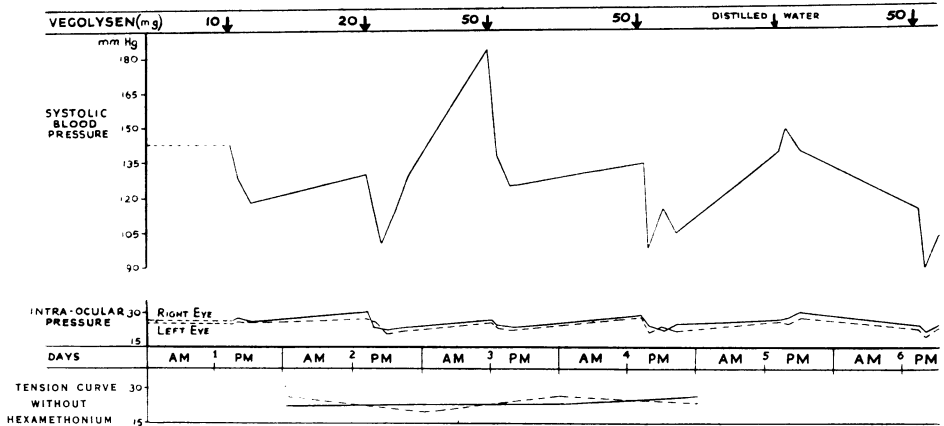


FIG. 3.—Case 7, aged 66, chronic primary glaucoma, circulatory insufficiency, extra-systoles ++.

(4) Case 12, aged 58.—*Sub-acute Congestive Glaucoma* (on miotics, thrice daily). This curve followed the pattern of the others. (Fig. 4, opposite).

Intra-ocular pressure diminished after each injection, with a very gradual return to normal in between.

Systolic blood pressure showed a considerable initial drop of 50 mm. Hg after the initial dose and this was maintained.

(5) Case 17, aged 50.—*Bilateral Chronic Primary Glaucoma* (on miotics, Fig. 5, opposite).

Intra-ocular pressure same as already noted.

Systolic blood pressure fell sharply.

Mean fall in intra-ocular pressure c. 10–12 mm.

(6) Case 18, aged 28.—This case, used as a control, had neither glaucoma nor vascular hypertension. No graph is shown, but the findings were of some general interest.

Intra-ocular pressure fell about 5 mm. after each injection and rose slowly in between.

Systolic blood pressure. The patient got out of bed quickly after the third injection and immediately felt faint and giddy. He was put back to bed, and the foot was raised and he quickly recovered, but meanwhile the systolic blood pressure rose very steeply between 30 and 40 mm. This happened again after a further injection and the investigation was stopped. The sudden rises in systolic pressure seemed to have no effect on his intra-ocular pressure.

### Out-Patient Findings

The findings at the end of the period of oral treatment as out-patients are shown in Table II.

TABLE II

Case No.		1	2	3	4	5	6	7	8	9	10	11	12	13	14
Pre-investigation Intra-ocular Pressure	Right eye	25	45	39	38	38	27	28	40	20	36	41			
	Left eye	25	38	72	—	38	27	—	40	50	26	33			
Intra-ocular Pressure after Oral Treatment	Right eye	18	35	35	28	35	25	30	32	20	30	40			
	Left eye	20	29	55	—	35	25	—	34	45	28	35			

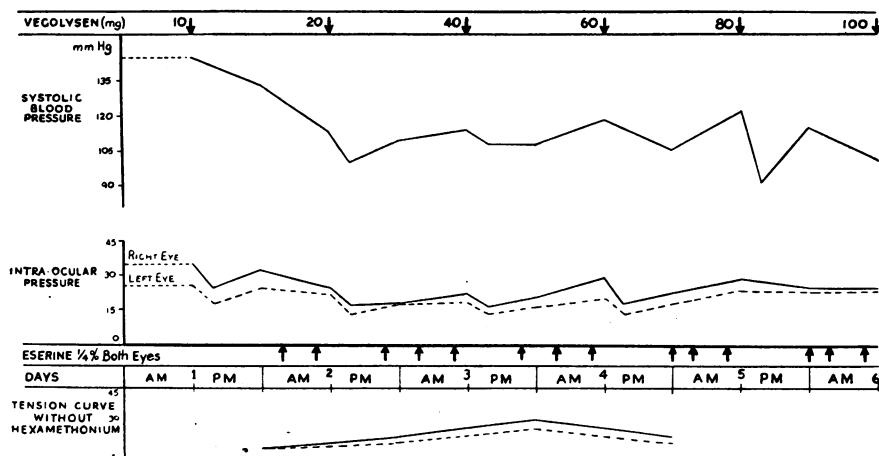


FIG. 4.—Case 12, aged 58, sub-acute congestive primary glaucoma. Right eye, no operation or field defect. Both eyes, eserine 0.25 per cent. thrice daily.

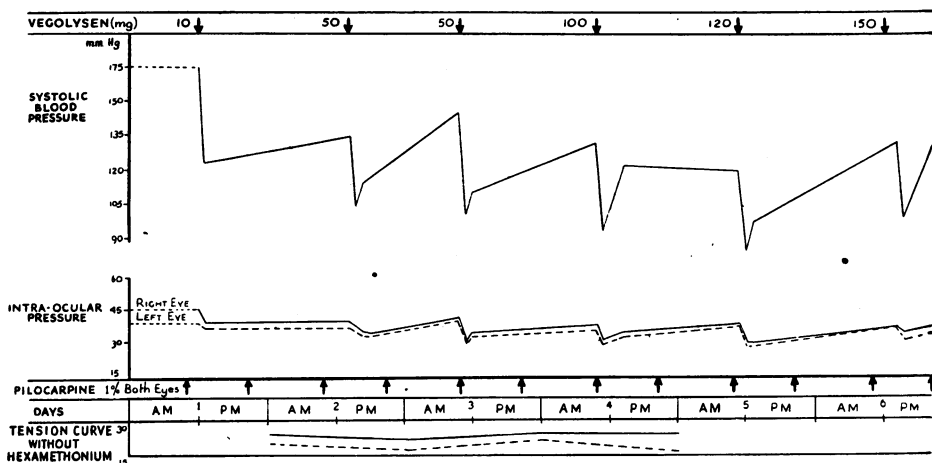


FIG. 5.—Case 17, aged 50, bilateral chronic primary glaucoma. Both eyes, pilocarpine 1 per cent. twice daily.

**Side-Effects**

The following side-effects were noted, but for more detail on this point papers relating to the use of the methonium compounds for vascular hypertension should be consulted.

Symptom	No. of Cases
Giddiness ... ..	1
Dry mouth ... ..	2
Malaise and pallor ... ..	3
Sweating ... ..	1
Temporary loss of sense of smell ... ..	1
Drug discontinued; Operation ... ..	2
No ill-effects ... ..	11



### Conclusions

#### Cases with High Blood Pressure and Glaucoma:

##### A. *Glaucoma not compensated* (Cases 6 and 9):

The blood pressure in Case 6 showed some very steep falls and rises. The intra-ocular pressure curve showed a drop of about 8 mm. Hg after each injection and rose again to about its original level. This type of curve was maintained throughout the experiment. Case 9 was similar.

##### B. *Glaucoma compensated by either miotics or operation* (Cases 2, 8, 11, and 15):

Considerable fluctuation of the intra-ocular pressure took place. There was a sharp decline after each injection of hexamethonium and a tendency to rise prior to the next. Case 15, in which the subsequent rises reached dangerous levels but fell sharply after each succeeding injection, was an exception. This patient came to operation on the sixth day of the injections.

#### Cases with Low Blood Pressure and Glaucoma:

##### A. *Glaucoma not compensated* (Cases 1, 7, and 18):

Despite considerable fluctuations in the blood pressure, the intra-ocular tension kept very even, showing just the smallest falls after each injection and a slight tendency to rise, the changes were at no time more than 1-2 mm. Hg.

##### B. *Glaucoma compensated by either miotics or operation* (Cases 3, 4, 5, 10, 12, 13, 14, 16, and 17):

The general pattern of the intra-ocular pressure curve roughly followed that of the blood pressure curve, falling after each injection and rising again prior to the subsequent one. Case 14 showed a very high rise of intra-ocular pressure on one or two occasions, which fairly definitely followed rises and falls in the blood pressure curve. In most of the other cases the excursions in the intra-ocular pressure curve were minimal, despite considerable swings in the blood pressure curve (*e.g.*, Case 10.) Case 3 behaved peculiarly, showing very marked fluctuations between a low and a dangerously high intra-ocular pressure which followed the pattern of the blood pressure curve fairly closely.

It would seem that there is no clear-cut pattern for any given type of case, although it is, perhaps, suggestive that in the high blood pressure cases the oscillations in the intra-ocular pressure curve seemed greater than in those with low blood pressure, as if the balance of intra-ocular pressure maintenance was in some way upset.

In no case was a dangerous rise of intra-ocular tension produced immediately after an injection of hexamethonium, although eighty injections in all were given. This is, perhaps, of some significance when it is remembered that the duration of the action of the hexamethonium is short-lived.

On eleven occasions the drug was omitted and replaced by distilled water, and, as the graphs show, the falls which usually followed the injection were not so marked.

It would appear that the drug has little to offer in the treatment and management of chronic glaucoma. It would also seem that there is little risk of a sudden or dangerous rise of intra-ocular tension when the drug is exhibited for therapeutic reasons.

Since this paper was written, four of the patients who had a relatively high intra-ocular pressure at the end of the investigation have come to operation.

### Summary

(1) Increasing doses of hexamethonium bromide were administered intramuscularly to seventeen known cases of glaucoma under treatment in hospital.

(2) In no case was a rise in intra-ocular pressure noted after any injection. The general and consistent change in each case was a slight fall.

(3) On eleven occasions the hexamethonium was replaced by an injection of distilled water. It was then noticed that the usual fall in intra-ocular pressure was not so marked.

We wish to record our indebtedness to Dr. John Harper of the Medical Trials Unit, May and Baker, Ltd., for his willing help and for putting at our disposal adequate supplies of the compounds.

### REFERENCES

- BARNETT, A. J. (1951). *Lancet*, **1**, 1415.  
BURT, C. G., and GRAHAM, A. J. P. (1950). *Brit. med. J.*, **1**, 455.  
CAMPBELL, A., and ROBERTSON, E. (1950). *Ibid.*, **2**, 804.  
DAVSON, H., and MATCHETT, P. A. (1951). *J. Physiol., Lond.*, **113**, 387.  
DUKE-ELDER, W. S. (1940). "Text-book of Ophthalmology", vol. 3, p. 3340. Kimpton, London.  
KAY, A. W., and SMITH, A. N. (1950). *Brit. med. J.*, **1**, 460.  
LOCKET, S., SWANN, P. G., and GRIEVE, W. S. M. (1951). *Ibid.*, **1**, 778.  
——— and PLAYER, H. P. (1952). *Ibid.*, **1**, 254.  
MACKEY, W. A., and SHAW, G. B. (1951). *Ibid.*, **2**, 259.  
MYASHITA (1914). Abs. from *Nippon Gankwa Zasshi*, April 1913, in *Klin. Mbl. Augenheilk.*, **52**, 561. Quoted by Duke-Elder, 1940.  
ORGANE, G., PATON, W. D. M., and ZAIMIS, E. J. (1949). *Lancet*, **1**, 21.  
RESTALL, P. A., and SMIRK, F. H. (1951). *Proc. Univ. Otago med. Sch.*, **29**, 10.  
RYCROFT, B. W., and ROMANES, G. J. (1952). *British Journal of Ophthalmology*, **36**, 29.  
TURNER, R. W. D. (1951). *Practitioner*, **167**, 541.  
ULLMAN, E. V., and MOSSMAN, F. D. (1950). *Amer. J. Ophthal.*, **33**, 757.