

## CHOROIDEREMIA\*

### CLINICAL AND GENETIC ASPECTS

BY

ARNOLD SORSBY, A. FRANCESCHETTI, RUBY JOSEPH,  
AND J. B. DAVEY

#### Review of Literature

(1) HISTORICAL.—In the fully-developed state, choroideremia presents a characteristic and unmistakable picture of which Fig. 1 and Colour Plate 1(*a* and *b*) may be taken as examples. The almost total lack of choroidal vessels strongly suggests a developmental anomaly. In fact most of the early writers on the subject, such as Mauthner (1872) and Koenig (1874), stressed the likeness to choroidal coloboma. As cases accumulated, less extreme pictures were observed, and these raised the possibility that choroideremia was a progressive affection and not a congenital anomaly—a view that gained some support from the fact that, apart from showing some choroidal vessels, these less extreme cases also showed pigmentary changes, sometimes reminiscent of retinitis pigmentosa (Zorn, 1920; Beckershaus, 1926; Werkle, 1931). Furthermore, the recognition of gyrate atrophy as a separate entity (Cutler, 1895) fitted in well with such a reading. The patches of atrophy seen in that affection could well be visualized as an early stage of the generalized atrophy seen in choroideremia, and since there was some evidence that gyrate atrophy was itself a variant of retinitis pigmentosa—for the affection is reputed to have been observed in families diagnosed as suffering from retinitis pigmentosa (*see* Usher, 1935)—the suggestion emerged that choroideremia, far from being a congenital stationary affection, was an extreme variant of retinitis pigmentosa. The occurrence of nightblindness as a cardinal symptom in all three affections appeared to lend additional support to the idea of their unity—a view still further supported by the fact that retinitis pigmentosa had been recorded in families with choroideremia by Smith and Usher (1916) and by Beckershaus (1926).

Three possible readings of choroideremia therefore emerged. At the one extreme it was regarded as an independent, congenital, stationary affection; in sharp contrast to this view it was regarded as an extreme variant of retinitis pigmentosa with its abiotrophic character; thirdly it figured as an independent affection, possibly congenital, but undoubtedly progressive. These difficulties, which could not be resolved by the case reports, have been cleared up in recent years by genetic studies. It is now established that choroideremia is an independent affection unrelated to retinitis pigmentosa. Whether the

---

\* Received for publication March 22, 1952.

affection is congenital is still not known, though there is no doubt that it is progressive. It is likewise certain that choroideremia is unrelated to gyrate atrophy, whatever doubts may still exist regarding the status of gyrate atrophy as an affection independent of retinitis pigmentosa—or indeed as a genuine clinical entity.

(2) CASE REPORTS WITHOUT CRITICAL GENETIC STUDIES.—Between 1872, when Mauthner recorded the first case of choroideremia, and the year 1948, some fifty cases have been reported in the literature (Table I). These are all fairly convincing examples of the affection, though not all were originally recorded as choroideremia. Six essential points emerge:

(i) Excepting the cases recorded by Grimsdale (1917) and by Shapira and Sitney (1943), all the patients were men.

(ii) In twelve instances, one or more brothers were affected (Mauthner, 1872; Koenig, 1874; Bullar, 1898; Alexander, 1910; Wolf, 1930; Bedell, 1937; Bencini, 1938; Sorsby, 1939; Scobee, 1943; Saebø, 1948).

(iii) A maternal grandfather was recorded by Würdemann (1935) as having had a similar condition, and Zorn (1920) and Schutzbach (1938) noted the affection in a man and in his sister's son respectively.

(iv) In one instance, a maternal uncle had "typical retinitis pigmentosa" [not further specified] (Beckershaus, 1926); in another, a maternal uncle had "bad sight" (Alexander, 1910); two uncles [relationship unspecified] were reported to have poor vision (Esterman, 1947); "similar trouble" was noted in a grand-uncle (Thompson, 1899).

(v) "Typical" or "atypical" retinitis pigmentosa, or other indefinite fundus lesions, were observed in some of the women in the families of patients with choroideremia by Smith and Usher (1916), Zorn (1920), Beckershaus (1926), Schutzbach (1938), Bencini (1938), Sorsby (1939), and Saebø (1948).

(vi) Progressive increase in the ophthalmoscopic changes were observed in five cases:

- (1) Thompson (1899) and Wardale (1906),
- (2) Smith and Usher (1916) and Riddell (1939),
- (3) Connor (1919) and Bedell (1937),
- (4) De Schweinitz's case in Parker and Fralick (1931) and Bedell (1937),
- (5) Zorn (1920) and Schutzbach (1938).

One case was recorded as having been stationary for 6 years (Cowgill, 1892).

(3) CRITICAL GENETIC STUDIES.—Goedbloed (1942) and Waardenburg (1942) independently drew attention to the possibility that choroideremia is an intermediate sex-linked affection. Goedbloed based his observation on an affected man whose sister and mother showed a fundus anomaly of the pepper and salt type without visual symptoms, and he found support for his reading in a brief survey of previously reported cases. Waardenburg's conclusion was based on a detailed analysis of the literature. In particular, the follow-up study by Schutzbach (1938) of the cases originally reported by

TABLE I

CASES OF CHOROIDEREMIA RECORDED BETWEEN 1872 AND 1948

Author and Date	Sex	Age at Examination	Duration of Symptoms	Family History	Remarks
Mauthner (1872)	M	32	Poor vision as long as he could remember, worse at night	Family of nine children, seven sisters well, one brother said to have same type of visual defect	
Koenig (1874) ...	M	20	Poor vision as long as he could remember, nightblind	Brother similarly affected, parents and grandparents said to have normal vision Brother of above	
	M	Younger brother of above—age not given	—ditto—		
Cowgill (1892) ...	M	17	Poor vision all his life	Not given	Followed for 6 years, no worse
Bullar (1898) ...	M	16	Poor vision all his life	Family of seven children, two brothers said to have bad sight, no consanguinity	
Thompson (1901) and Wardale (1906)	M	18 in 1899	Since early infancy	No consanguinity, parents had good vision, a grand-uncle said to have similar trouble	When seen by Wardale in 1906, condition of fundus stationary but vision declined later
Landmann (1906)	M	44	Vision had always been poor	Father myopic, no further family history	
Marbaix (1908)	M	40	Nightblind as long as he could remember	Not given	
Alexander (1910)	M	31	Had always been nightblind	One of a family of eleven children, nine siblings healthy, one older brother similarly affected, mother had a brother and cousin (? sex) with bad sight—particularly in dim light, no consanguinity	
Smith and Usher (1916)	M	24	Nightblind since childhood	One of a sibship of four, mother and one sister said to have atypical retinitis pigmentosa, father had congenital stationary blindness	
Grimsdale (1917)	F	23	No history available	Not recorded	Family history unobtainable retrospectively (Bridgeman)
Connor (1919) ...	M	25	Nightblind as long as he could remember	Parents not consanguineous, sister and brother well, maternal uncle had repeated attacks of sore eyes	Fundi remained the same 16 years later, but fields were more contracted
Zorn (1920) ...	M	29	Helpless in the dark, nightblind since childhood	One of a sibship of three, mother, one sister and her son, one of his three daughters and one son of the normal sister were nightblind	
Beckershaus (1926)	M	33	Nightblindness noticed in school	No consanguinity recorded, two first cousins and maternal uncle with typical retinitis pigmentosa	
Dimmer and Pillat (1927)	M	44	—	—	No other details beyond a typical illustration
Wolf (1930) ...	M	42	Poor vision since childhood	One of a sibship of five, three brothers normal, one brother similarly affected, father had good vision, mother said to have poor vision—cause not known	
	M	40	—ditto—	Younger brother of above	
de Schweinitz (1931)	M	14	Always had poor vision	No consanguinity; parents both healthy	Constant lateral nystagmus and lens opacities

—continued overleaf

TABLE I—*continued*

Author and Date	Sex	Age at Examination	Duration of Symptoms	Family History	Remarks
Parker and Fralick (1931)	M	33	Nightblind as long as he could remember, always near-sighted	Parents not consanguineous, two sisters said to be normal	
Werkle (1931) ...	M	10	Nightblind	Mother, her sister's son, and his daughter, affected by nightblindness and milder fundus changes	Recorded as gyrate atrophy, but these cases are almost certainly early stages of choroideremia
	M	20	—ditto—	Brother of above No consanguinity recorded, has a blind sister—cause not known	
	M	50	Nightblind since childhood		
Bahn (1932) ...	M	42	Nightblind		No further details
Wilmer (1934)	M	65	Nightblind	Not given	Photographic exhibit, atlas plate; after 8 years, lens opacities not increased, but slight increase of atrophy of choroid
Bhaduri (1934)	M	17	Sight noted defective at the age of 3 years	One brother myopic	
Würdemann (1935)	M	40	Practically blind since childhood	Grandfather (maternal) has similar condition	
	M	35	Always near-sighted		
Benedict (1937)	M	48	Nightblind since age 6, and near-sighted since age 12	Parents second cousins, one brother wore glasses but had good vision	
Bedell (1937) ...	M	59	Always nightblind	"One brother had similar condition"	
	M	45	Nightblind since childhood	Brother similarly affected, parents, four sisters, and one brother normal	
	M	57	Vision poor for 29 years	Two brothers similarly affected, own two children normal	
	M	43	Steadily increasing nightblindness	Brother of above	
	M	34	Nightblind for 10 years	Third brother of above	
Schutzbach (1938)	M	27	Nightblind, good central vision	Maternal uncle likewise affected	Member of family recorded by Zorn (1920)
Bencini (1938) ...	M	35	Progressive night-blindness	Three sisters and her children normal	Progressive deterioration in both patients over 3 years
	M	38	—	Brother of above, ? pathological fundus in mother and in the son of elder brother	
Sorsby (1939) ...	M	43	Progressive night-blindness	Two brothers, parents not consanguineous	Recorded as cases of choroidal sclerosis, more fully studied in this paper
	M	54	— ditto —	A sister shows lesions suggestive of old "central choroiditis"	
	(1940)	M	28	Progressive symptoms	Wrongly recorded as clear
Goedbloed (1942)	M	38	Progressive symptoms	Mother and sister show pepper and salt fundus	
Shapira and Sitney (1943)	F	52	Poor vision since childhood	Not given	Hypertensive disease, Wassermann reaction ... family history not obtainable retrospectively (Shapira, 1951)
Scobee (1943) ...	M	24	Nightblindness recently	Brother of above: another brother and two sisters normal	Mother shows mild arteriosclerotic retinopathy
	M	18	No subjective symptoms, examined because of findings in brother		

—*continued opposite*

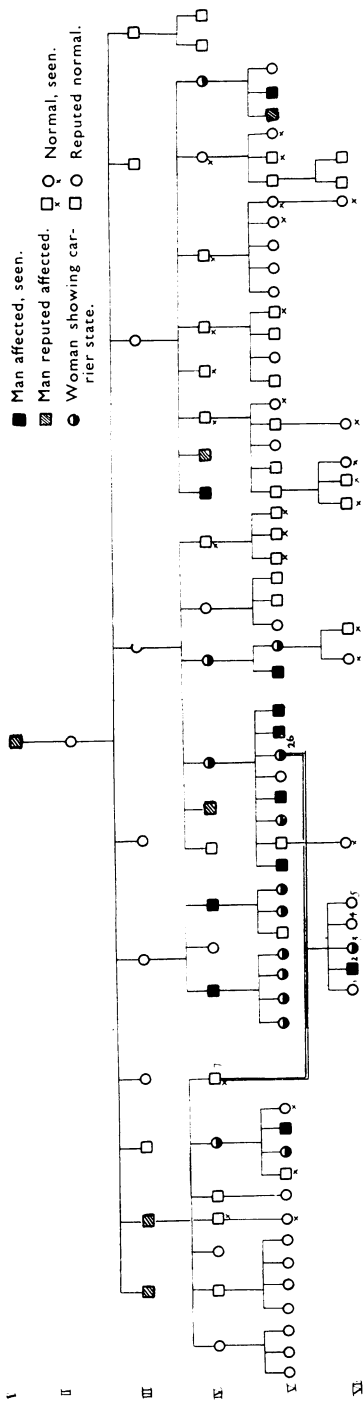
TABLE I—*continued*

Author and Date	Sex	Age at Examination	Duration of Symptoms	Family History	Remarks
Magder (1945)	M	58	Progressively night-blind since childhood	Isolated case in large sibship, parents normal	
Esterman (1947)	M	29	Nightblind	Two uncles said to have poor vision	
Meyran (1948)	M	7			Case seen in abstract
Saebö (1948) ...	M	27	Nightblind since childhood Nightblind at 20 Nightblind in youth Blind at 40	Four affected brothers Two brothers and three sisters normal, mother shows indefinite changes around disks	Reported as cases of gyrate atrophy
	M	38			
	M	44			
	M	46			

Zorn (1920) strongly suggested that possibility. Schutzbach, who like Zorn had noted an unusual fundus reaction in some of the women in that family, concluded that choroideremia is a dominant and sex-linked affection. He based his assumption of dominance on the fact that the affection had been transmitted over three generations, and his reading of sex-linkage on the fact that only the men were markedly affected—an unnecessarily complicated reading which is in any case inconsistent with genetic theory. The interpretation given by both Goedbloed and Waardenburg is of course more satisfying. The assumption that choroideremia is transmitted in an intermediate sex-linked manner implies that it produces the full affection in men (as they possess only one X-chromosome which carries the pathogenic gene), and an abortive form in women (as they have a normal gene to modify the pathogenic gene). Though Waardenburg appears to accept the pedigree by Werkle (1931) as illustrative of gyrate atrophy, that pedigree is also suggestive of the inheritance of choroideremia in an intermediate sex-linked manner. The illustrations given for the two brothers aged 20 and 10 years respectively, and the nightblindness and indefinite fundus appearances in their mother, and in her sister's son and daughter, all conform better with choroideremia than with gyrate atrophy. Waardenburg's careful analysis left some difficulties unanswered, the chief of which was the reputed occurrence of four cases in women.\* He excluded only that of Werkle as doubtful, but actually the cases of Hutchinson (1900) and Thompson (1899)—the record of the latter he could not obtain in the original—should likewise be excluded, so that only one authentic case in a woman—that recorded by Grimsdale (1917)—is left for consideration. Whatever doubts may have remained were dissipated by the model study of McCulloch and McCulloch (1948) of a family with over 600 members, including 33 affected and 53 carriers—a study further supported by that of a second family of eighteen members with five affected and five carriers.

These extensive pedigrees (of which Pedigree Chart 1, overleaf, is an extract) further cleared up the confusion in the early literature as to 'atypical' retinitis pigmentosa occurring in the women of choroideremia families. This

\* The case subsequently reported by Shapira and Sitney (1943) would have raised the number to five.



PEDIGREE CHART 1.—Inheritance of choroideremia. Pedigree after McCulloch and McCulloch (1948, Figs 1 and 4) and subsequent personal communications. In the pedigree as originally published, the relationship between the mother and father of VI 1-5 was not indicated, so that it appeared that an unaffected man (IV, 7) had affected children, whereas in fact their affection derived from the carrier mother (V 26), who was the father's second cousin. We are indebted to Dr. R. J. P. McCulloch for the additional information shown here.

difficulty is adequately resolved by the conception of the carrier state as an essentially symptomless disorder producing somewhat variable ophthalmoscopic changes.

The earliest ages at which the affection was observed in boys by the McCullochs were 6 and 7 years—and possibly also 22 months—which makes it likely that choroideremia is a congenital and not an abiotrophic defect. Their material also confirmed the earlier findings that the affection is progressive.

One further pedigree has since been published (Lowe, 1951). This shows the affection in a man, transmitted through a carrier daughter to one of her three sons (Pedigree Chart 2, opposite).

(4) SOME OUTSTANDING DIFFICULTIES

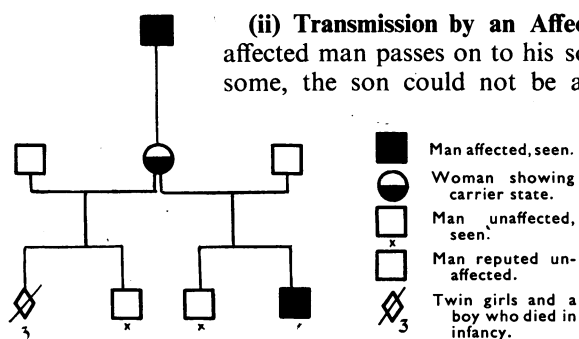
(i) Transmission by Unaffected Men.—

No unaffected man should pass on an intermediate sex-linked disorder. This expectation does not appear to have been realized in two families:

(a) *Schutzbach's Pedigree*.—This pedigree shows an affected son of a normal father, whose brother showed typical choroideremia. On Schutzbach's own findings this case must be regarded as most doubtful.

(b) *The McCullochs' Pedigrees*.—These contain two deviations from expectation. In one case a normal man has a carrier daughter (McCulloch, Fig. 2); in another case a normal man has a carrier daughter and an affected son (*ibid.*, Fig. 4). Actually, as Dr. R. J. P. McCulloch informs us, the affected individuals were the offspring of carrier women. The carrier daughter of a normal man shown in McCulloch's Fig. 2 was the offspring of a marriage of cousins—III, 4 having married III, 31, a woman

who was a known carrier. Likewise the affected son, V, 3 and his carrier sister, V, 4 (McCulloch, Fig. 4) were the offspring of a marriage between an observed carrier IV, 31 and her cousin once removed, III, 7. The amended data in this second case are shown in Pedigree Chart 1, where the parents in question appear as IV, 7, and V, 26.



PEDIGREE CHART 2.—Inheritance of choroideremia (after Lowe, 1951).

(ii) **Transmission by an Affected Man to his Son.**—As an affected man passes on to his son only his normal Y-chromosome, the son could not be affected. Apparent exceptions are recorded by di Marzio (1937) and by Bencini (1938).

In di Marzio's case, illustrated and briefly described in his Atlas as a case of "total congenital sclerosis of the choroidal vessels (choroideremia)", a man is recorded as having a brother and a son affected with "atypical retinitis pigmentosa". But

the diagnosis of choroideremia seems unwarranted; the illustration shows a pigmented central area with sclerosed choroidal vessels rather than the characteristically retained normal central area, and the disk and vessels are of the retinitis pigmentosa type.

In Bencini's case an affected man is reported as having an affected son, but as the son showed indefinite peripheral fundus changes without functional disturbances the findings are hardly conclusive.

(iii) **Occurrence in Women.**—Since the publication by Grimsdale (1917) of a case of choroideremia in a woman, there is another case report to consider (Shapira and Sitney, 1943). Theoretically a woman can show choroideremia only if her father was affected and married a carrier. Unfortunately, neither case report gives a family history, and attempts to obtain them retrospectively proved unsuccessful (Bridgeman, 1951; Shapira, 1951). A case, reported by Thompson (1899) as "superficial choroidal atrophy without subjective symptoms, in a member of a family subject to nightblindness", is a good example of the carrier state, and not of choroideremia. The case of Hutchinson (1900) is one of choroidal sclerosis included in the original cases of the Laurence-Biedl syndrome (Laurence and Moon, 1866); it is recorded by Hutchinson as a case not of choroideremia, but of "disease of the choroids".

(iv) **Relationship to Retinitis Pigmentosa.**—If choroideremia is an entity distinct from retinitis pigmentosa, this latter should not occur as a variant of choroideremia in a choroideremia family. Two of the older pedigrees do not appear to conform:

(a) *Smith-Usher Pedigree.*—Here the sister of a markedly affected man showed 'atypical' retinitis pigmentosa, while the mother was recorded as showing retinitis pigmentosa. It is not unlikely that the mother merely showed a more severe form of the carrier state than the daughter (Usher, 1935; Riddell, 1939; 1950).

(b) *Beckershaus (1926).*—The occurrence of retinitis pigmentosa in the maternal uncle of a man with choroideremia and in this uncle's son and daughter is reported without any further detail. This account is too scanty to allow a critical judgment.

(5) **A POSSIBLE CONGENITAL TYPE.**—The existence of choroideremia as a progressive affection seen early in childhood suggests that the affection is congenital in origin, but does not exclude the possibility which emerges from the older literature that there is a congenital stationary type. For the present this remains hypothetical.

(6) **MORBID HISTOLOGY.**—So far only two studies are available:

(i) *McCulloch (1950).*—Four eyes from the families studied by the two McCullochs (1948) came to histological examination. The choroidal vessels were either sclerosed or absent, and the outer layers of the retina extensively degenerate or totally lacking. The retinal changes were proportionate to the choroidal changes throughout; where the choroid was relatively intact the retina appeared to be least involved. The choroidal changes were regarded as the primary lesion.

(ii) *Fornes Peris (1947).*—This is a doubtful report based exclusively on *post-mortem* findings. A girl aged 3 was found to show complete absence of the choroid. In the absence of a clinical report, and in view of the sex and age of the patient, the exact status of the finding must be regarded as uncertain.

(7) **CLINICAL APPEARANCES.**—There is room for a clearer appreciation of the range of changes, and rate of progress of the affection as seen in men, and of the anomalies as seen in women. The present study was undertaken largely with this object in view.

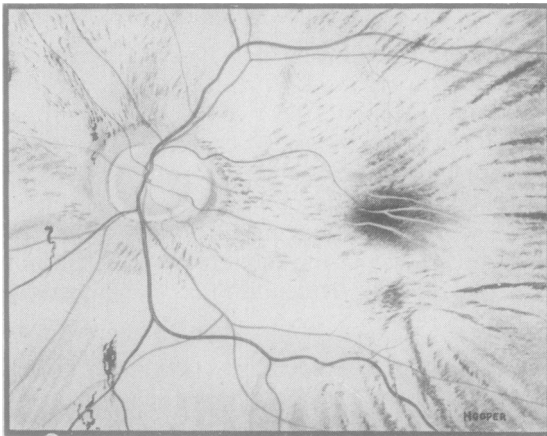

FIG. 1.—Left fundus of S II, 1, male, aged 69. Note almost total atrophy of retina and choroid, including atrophy in central areas where some pigmentation persists. Nightblindness has been present since early childhood, and the patient has been blind since the age of about 55, his vision being perception of light only.

### Material of Present Investigations\*

Three families, one fairly large, and the other two rather small, were investigated. One member of each of the first two families had previously been recorded as an isolated case of an unusual form of choroideremia (Sorsby, 1939, 1940).

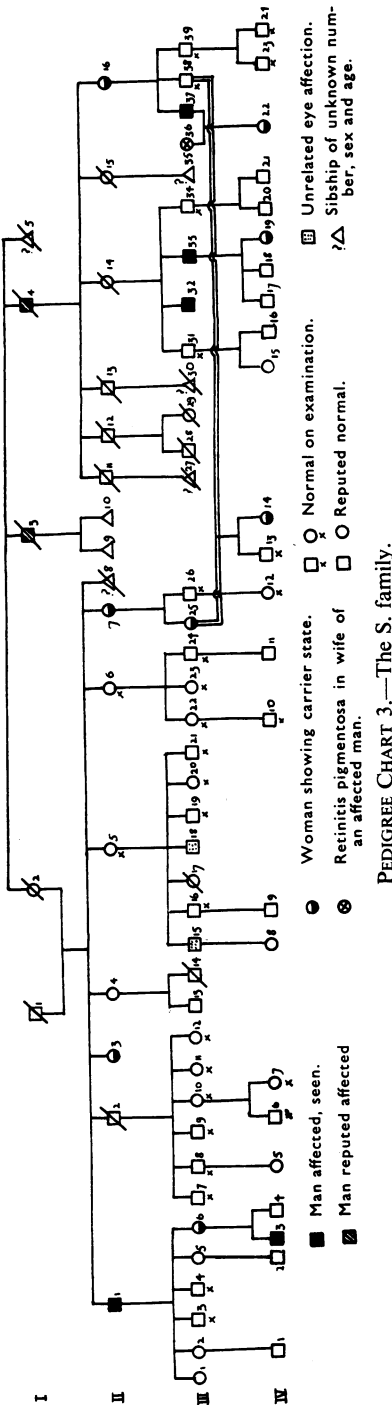
#### (1) The S. Family (Pedigree Chart 3, opposite)

The members of the first generation are all dead. Two men in this generation are reputed to have been affected.

In the second generation seven members are alive and six could be examined. Of these six, one

\* The contribution of one of us (A. F.) was limited to the study of the descendants of S II, 14.





(S II, 1) is an affected man, and the remaining five are women, two of whom are normal while three (S II, 3, 7, and 16) show variable ophthalmoscopic appearances without any subjective symptoms.

In the third generation three affected men (S III, 32, 33, and 37) were observed, and there were also two women (S III, 6 and 25) with symptomless ophthalmoscopic changes.

In the fourth generation there is an affected boy (S IV, 3) and three girls with ophthalmoscopic anomalies (S IV, 14, 19, and 22).

Taking the family as a whole there are therefore five affected men and eight women with symptomless ophthalmoscopic lesions. The personal details are shown in the Appendix and are summarized in the legends to the relevant illustrations.

*Ophthalmoscopic Appearances and Subjective Symptoms in the Men.*—The five affected males (S II, 1; S III, 32, 33, and 37; S IV, 3) were aged 69, 56, 55, 41, and 6½ respectively. The range of fundus appearances in the patients aged 69, 56, 41, and 6½ is shown in Fig. 1 and Colour Plate 1(a), (b), and (f); fundus drawings of S III, 33, a man aged 55, could not be obtained, but the appearances were almost identical with those of his brother (S III, 32) seen in Colour Plate 1(a). The outstanding subjective features in the four adult cases were consciousness of nightblindness in the early years of life and increasing constriction of the visual fields. The progressive character of the affection was noted ophthalmoscopically in one case (S III, 37). He was first seen in 1937 when he was 28 years old and already certifiably blind. The fundus at that time is shown in Colour Plate 1(c) which, in contrast with Colour Plate 1(b) taken in 1950, still shows some choroidal vessels. In this man serious visual defect, which compelled him to give up his work as a tailor, had become established by the age of 18.

[Two brothers in the S family (S III, 15 and 18) show bilateral central fundus lesions with evident choroidal sclerosis and patches of choroidal atrophy and pigmentation. Their mother is normal and there is nothing to suggest choroideremia in the sons, the elder of whom also shows lens changes.]

*Ophthalmoscopic Appearances in the Women.*—The ages of the eight unaffected females showing ophthalmoscopic lesions (S II, 3, 7, and 16; S III, 6 and 25; S IV, 14, 19, and 22) ranged from 6

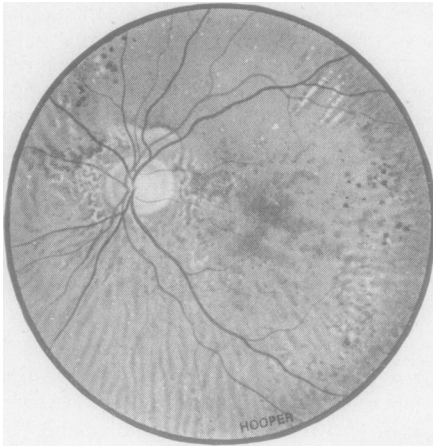


FIG. 2.—Left fundus of S II, 3, female, aged 65, sister of an affected man, S II, 1 (Fig. 1). No children.

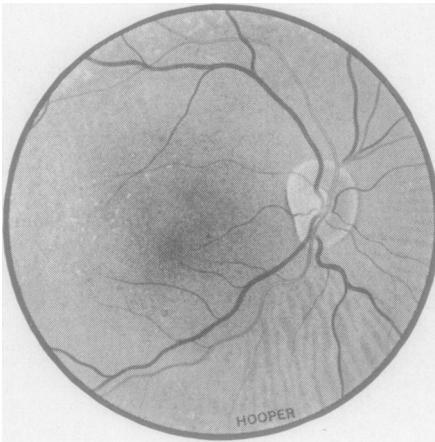


FIG. 3.—Right fundus of S II, 7, female, aged 55, sister of an affected man, S II, 1 (Fig. 1) and mother of a carrier daughter, S III, 25 (Fig. 4), and a carrier granddaughter, S IV, 14 (Fig. 6). The anomalies are not very marked.

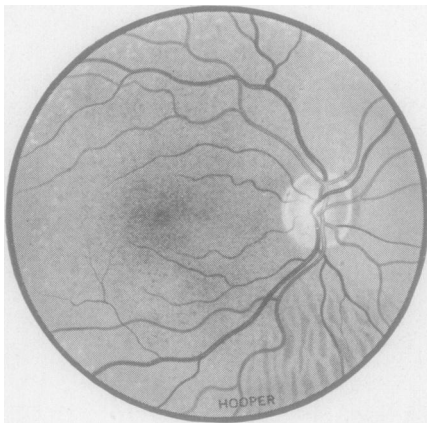


FIG. 4.—Right fundus of S III, 25, female, aged 31, daughter of S II, 7, a carrier (Fig. 3), and mother of S IV, 14, also a carrier (Fig. 6). Note the similarity to the mother's fundus (Fig. 3).

to 65 years. Fig. 2, Colour Plate 2(b), Figs 3, 4, 5, Colour Plate 2(a), and Figs 6 and 7 give the appearances in chronological order. Subjectively none was conscious of

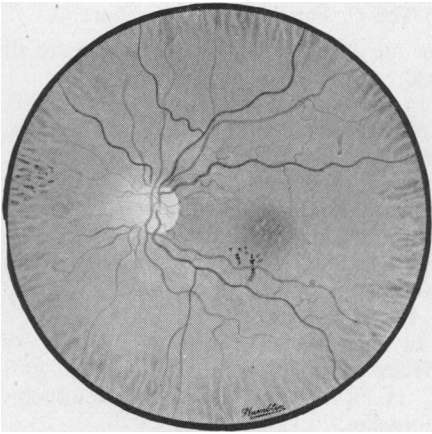


FIG. 5.—Left fundus of S III, 6, female, aged 27, daughter of an affected man, S II, 1 (Fig. 1), and mother of an affected son, S IV, 3 (Colour Plate 1f).

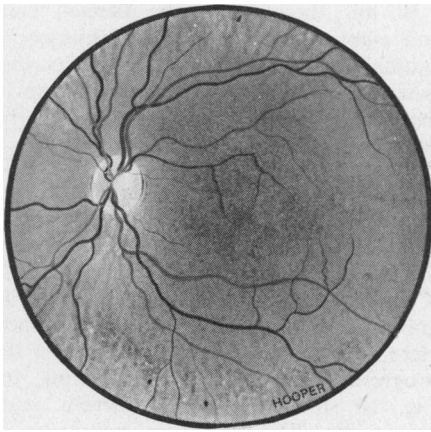


FIG. 6.—Left fundus of S IV, 14, female, aged 6, daughter of S III, 25 a carrier (Fig. 4) and grand-daughter of S II, 7 a carrier (Fig. 3); she thus represents the third generation of presumed carriers.

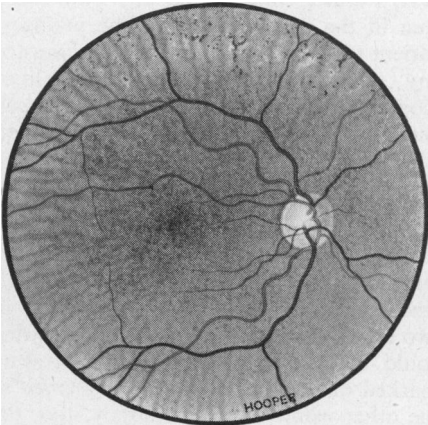
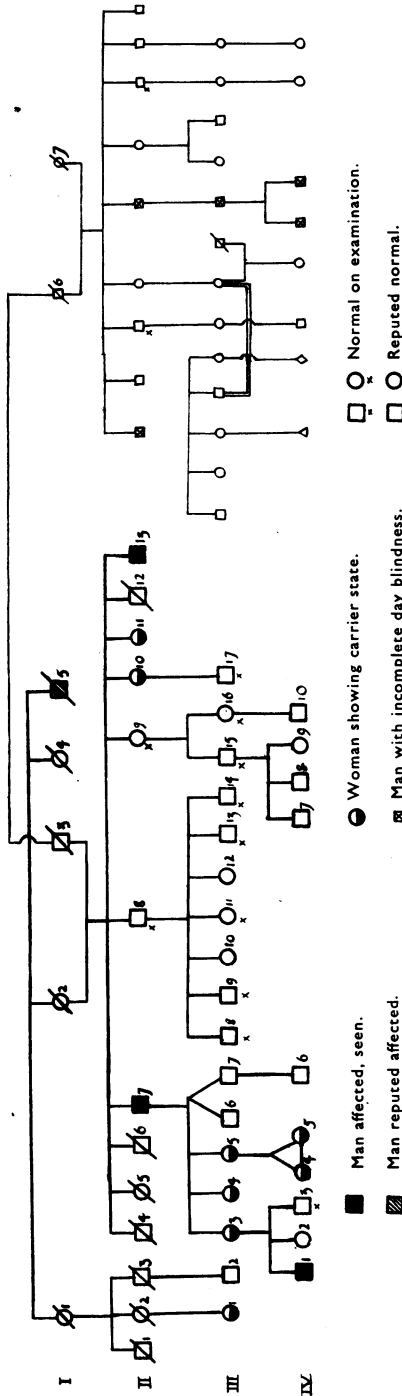


FIG. 7.—Right fundus of S IV, 22, female, aged 6, daughter of an affected man, S III, 37 (Colour Plate 1b and c). Her mother (S III, 36) suffers from retinitis pigmentosa.

any visual trouble, nor was any defective visual acuity demonstrated objectively, except that a dark-adaptation curve carried out on S IV, 19 showed some reduction (Fig. 21).



PEDIGREE CHART 4.—The C. family. Note:—C IV 2, should be shown as “normal on examination.”

(2) The C. Family (Pedigree Chart 4)

The members of the first generation are all dead.

In the second generation there are six survivors, three men and three women. Two of the men (C II, 7 and 13) are affected, and two of the women (C II, 10 and 11) show ophthalmoscopic anomalies.

In the third generation there are no affected men, but four women with ophthalmoscopic lesions were observed (C III, 1, 3, 4, and 5).

In the fourth generation there is an affected man (C IV, 1) and twin girls (C IV, 4 and 5) with ophthalmoscopic anomalies.

In all, therefore, three affected men and eight women with ophthalmoscopic anomalies have been observed in this group. The personal details are shown in the Appendix and are summarized in the legends to the relevant illustrations.

*Ophthalmoscopic Appearances and Subjective Symptoms in the Men.*—Figs 8 and 9, and Colour Plate 1(e) show appearances in the two affected brothers, aged 72 and 56 (C II, 7 and 13), and in the 18-year-old grandson (C IV, 1) of the elder brother. Here, too, there is objective evidence of the progressive nature of the affection, for Fig. 10 shows C II, 13 thirteen years previously. The subjective symptoms in C II, 7 and 13 differ in no way from those seen in the first family, but the youngest patient (C IV, 1) is as yet not conscious of any abnormality. In fact, ophthalmoscopically and subjectively, he fits much better with the women of the group than with the men.

*Ophthalmoscopic Appearances in the Women.*—These are shown in Fig. 11, Colour Plate 2(b), Fig. 12, Colour Plate 2(f) and 2(d), and Fig. 13, for six individuals whose ages range from 65 to 14 years; in two cases (C II, 11 and C III, 1) no drawing could be made but their fundi showed no marked differences from those observed in the other women. In this family, too, the women were not conscious of any subjective defect, nor could such defects be shown objectively.

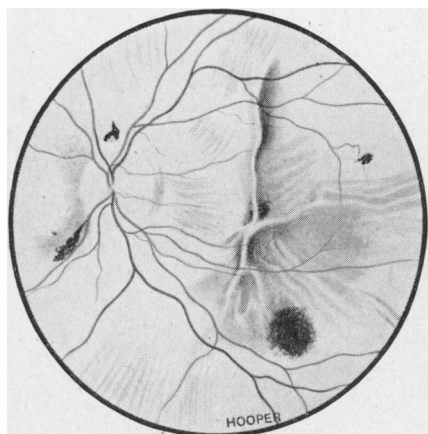


FIG. 8.—Left fundus of C II, 7, male, aged 72, who was first seen in 1938, when vision was 6/9 in each eye with some contraction of the field. The subjective symptoms of nightblindness and restricted field were so mild that he was hardly handicapped. When he was seen again in 1951, 13 years later, vision was reduced to perception of light, and it was found that he had continued at work until shortly after the 1938 examination, when vision had begun to decline rapidly.

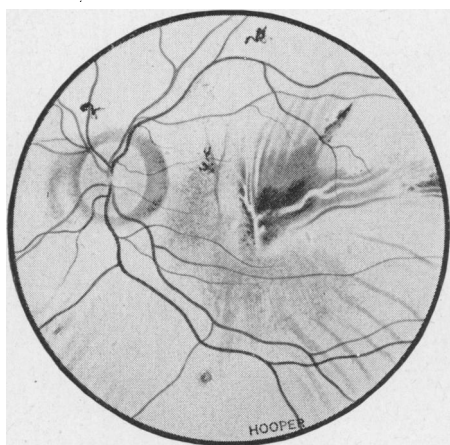


FIG. 9.—Left fundus of C II, 13, male, aged 57, brother of C II, 7 (Fig. 8). Though he is 15 years younger than his brother, the anomalies are almost as advanced. The patient has been conscious of nightblindness all his life, and has had serious visual trouble since the age of 25. When seen in 1938 at the age of 44 (see Fig. 10) his vision was 6/24 in the right eye, and 6/6 in the left, with fields reduced to the fixation point. Vision had declined steadily since, and is now only perception of light in the right eye, and 2/60 in the left.

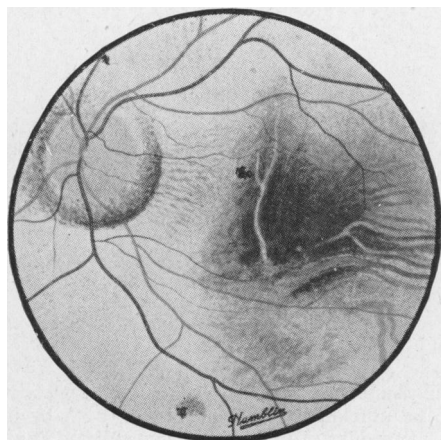


FIG. 10.—Left fundus of C II, 13, when first seen, aged 44, in 1938. Comparison with Fig. 9 shows the deterioration that has occurred over 13 years.

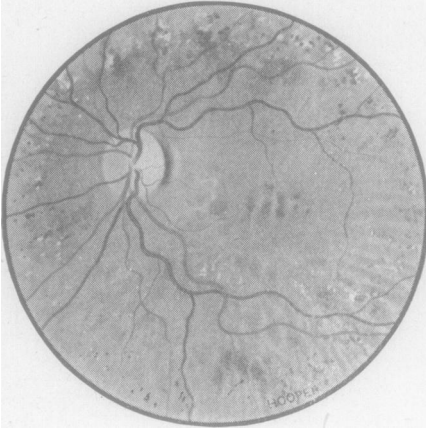

FIG. 11.—Left fundus of C II, 10, female, aged 65, a sister of two affected men, C II, 7 and 13 (Figs 8-10). When first seen in 1938 her vision was 6/9, and her fundi "suggestive of an old central choroiditis". There has been no subjective deterioration, and there is no nightblindness.

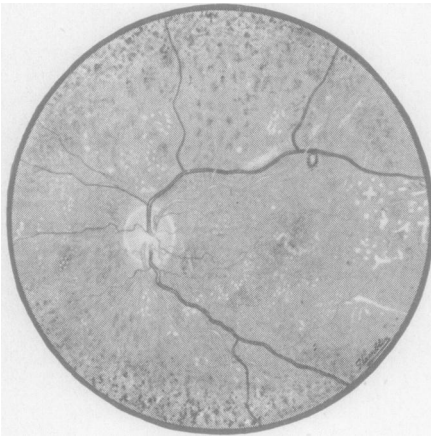


FIG. 12.—Left fundus of C III, 4, female, aged 41, a younger sister of C III, 3 (Colour Plate 2*b*). The anomalies are rather more marked than in the elder sister.

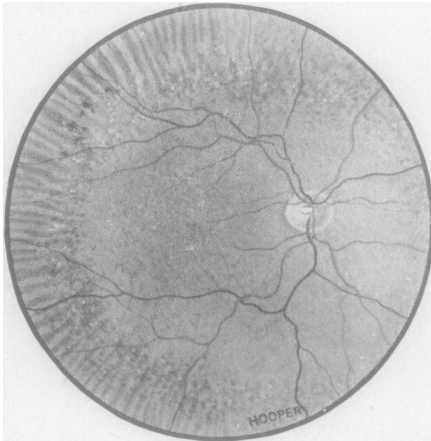
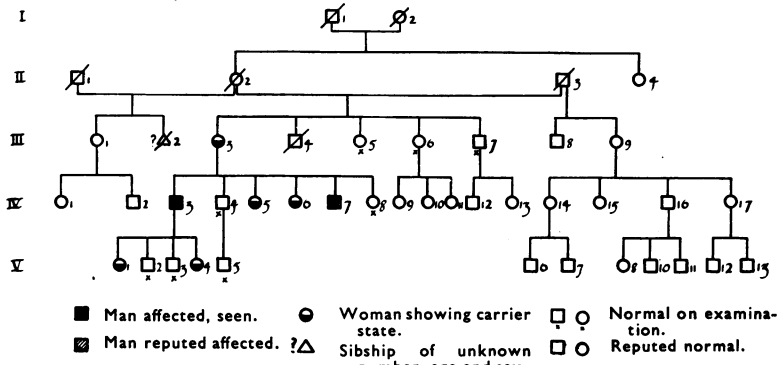


FIG. 13.—Right fundus of C IV, 5, female, aged 14, twin sister of C IV, 4 (Colour Plate 2*d*).

[It is to be noted that a collateral branch of the family suffers from an incomplete and progressive form of day blindness. This affection appears to be unrelated to choroideremia, both by its mode of inheritance and by its symptomatology. An account of this, as yet, incompleting study will be reported in a subsequent communication.]

(3) The G. Family (Pedigree Chart 5)

Ophthalmoscopic changes were observed in three generations, as can be seen from Pedigree Chart 5. There were two affected men (G IV, 3 and 7) and five women (G III, 3; G IV, 5 and 6; G V, 1 and 4) with asymptomatic ophthalmoscopic anomalies.



PEDIGREE CHART 5.—The G. family.

*Ophthalmoscopic Appearances and Subjective Symptoms in the Men.*—Colour Plate 1(d) and Fig. 14 show the fundus appearances in two brothers (G IV, 3 and 7), aged 35 and 25. The elder brother has 6/9 vision, and the younger 6/5, but both are conscious of visual disturbances.

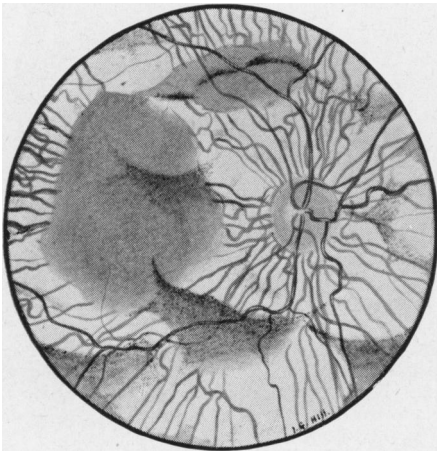


FIG. 14.—Left fundus of G IV, 7, male, aged 25, brother of G IV, 3 (Colour Plate 1d). Note that the retina is intact over a considerably larger area than in his brother who is 10 years older. Vision is 6/5, but the field is greatly affected (see Fig. 20a-d).

The elder brother (G IV, 3) first became conscious of visual disturbances at about the age of 20. He has a low hypermetropic error (right, +1.00 D. sph  $\ominus$  +0.50 D. cyl; left, +1.50 D. sph  $\ominus$  +0.50 D. cyl). His colour vision tested by Ishihara plates is normal. His dark adaptation is markedly abnormal for rod vision (Fig. 22e). His field of vision is intact centrally and at the extreme periphery (Fig. 19a and b, overleaf).

The younger brother (G IV, 7) was kindly seen for us by Mr. Ronald F. Lowe of Melbourne, who reported that the patient had become vaguely conscious of night-blindness at the age of 17. He has hypermetropia of 2.00 D. in the right eye, and 3.75 D.

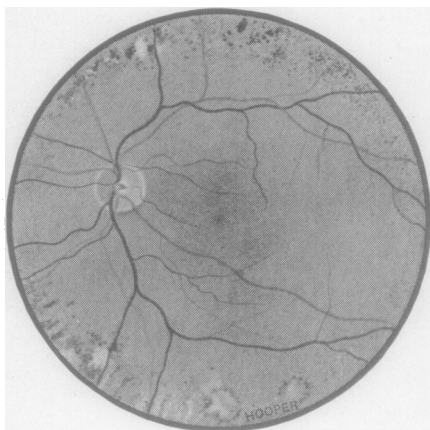


FIG. 15.—Left fundus of G III, 3, female, aged 56, mother of two affected sons, G IV, 3 and 7 (Colour Plate 1*d* and Fig. 14).

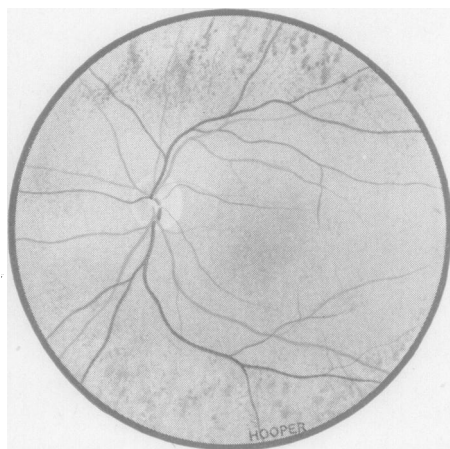


FIG. 16.—Left fundus of G IV, 5, female, aged 31, daughter of G III, 3 (Fig. 15).

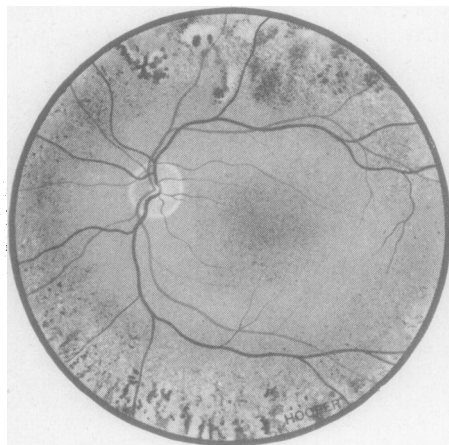


FIG. 17.—Left fundus of G IV, 6, female, aged 28, another daughter of G III, 3 (Fig. 15).

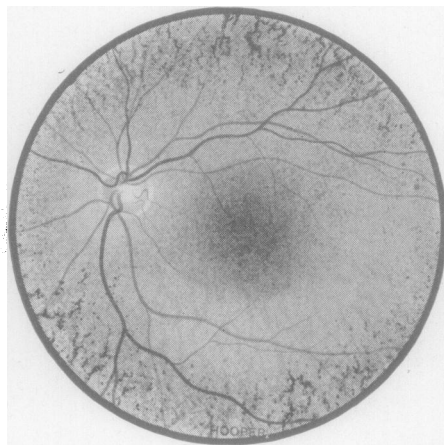


FIG. 18.—Left fundus of G V, 1, female, aged 8, daughter of G IV, 3 (Colour Plate 1*d*). Note the heavy peripheral involvement which is very similar to that seen in G V, 4 (Colour Plate 2*c*).

in the left. His field of vision is more patchily affected than that of his brother (Fig. 20*a-d*, opposite).

*Ophthalmoscopic Appearances in the Women.*—Figs 15, 16, 17, 18, and Colour Plate 2(*c*) show the ophthalmoscopic appearances in the five affected women (G III, 3; G IV, 5 and 6; G V, 1 and 4) whose ages ranged from 56 to 3½ years. The three adults had no subjective symptoms, and the two children appeared to have none. The observations are set out in Table II (overleaf). Curves of dark adaptation are shown in Fig. 22(*a-d*) which may be contrasted with Fig. 21.



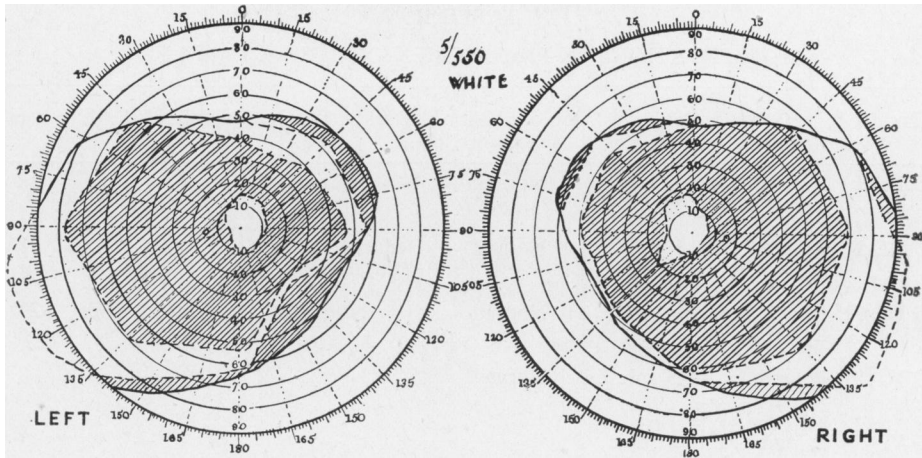


FIG. 19(a and b).—Peripheral fields of G IV, 3 (Colour Plate 1d and Pedigree Chart 5).

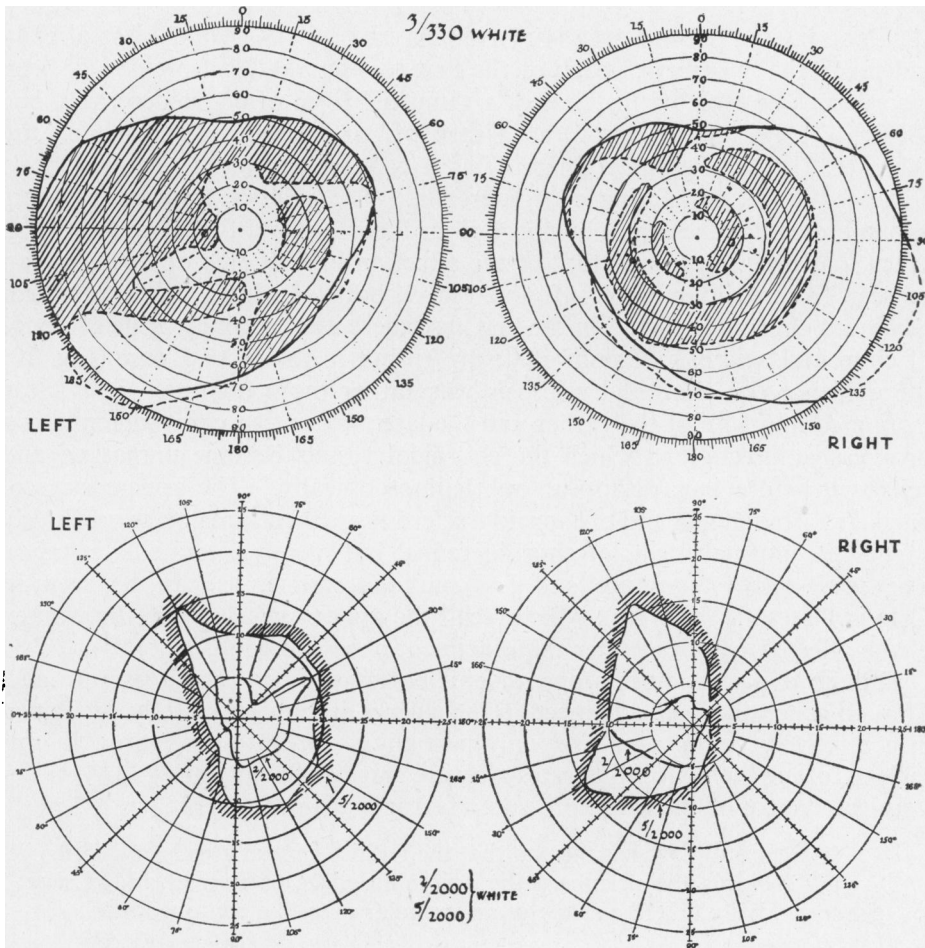


FIG. 20(a-d).—Peripheral and central fields of G IV, 7 (Fig. 14 and Pedigree Chart 5), kindly taken by Mr. R. F. Lowe (Melbourne).

TABLE II  
OBSERVATIONS IN FIVE WOMEN OF THE G. FAMILY

Patient	Refraction	Colour Vision (Ishihara)	Dark Adaptation	Visual Fields	Age
G III, 3	R. and L. +5.0 D. sph. c̄ +0.5 cyl.	Normal	Normal	—	56
G IV, 5	R. and L. +1.5 sph.	Normal	Reduced rod curve (? due to pregnancy)	—	31
G IV, 6	R. +2.5 sph. L. +3.0 sph.	Normal	Normal	Central fields normal	29
G V, 1	R. and L. +0.5 sph. c̄ +1.0 cyl.	Normal	Normal	—	8
G V, 4	R. and L. Emmetropic	—	—	—	3

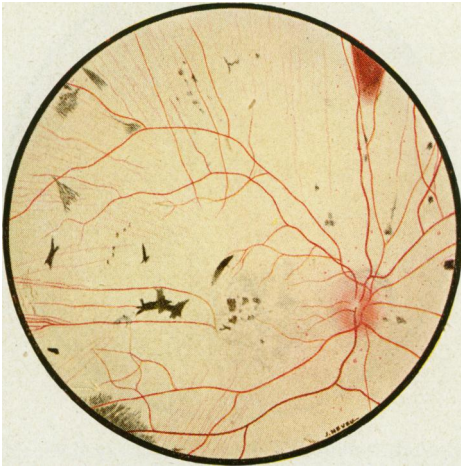
### Discussion

(1) PROGRESSIVE CHARACTER OF THE AFFECTION IN MEN.—As already indicated, one member of each of the first two families had previously been recorded as an isolated instance of an unusual form of choroideremia: one (S III, 37; Pedigree Chart 3) as a case of partial choroideremia, and the other (C II, 13; Pedigree Chart 4) as a case of choroidal sclerosis in an advanced stage, simulating choroideremia. The original findings 13 years ago in these two cases are shown in Colour Plate 1(c) and Fig. 10 respectively. Since that time the true nature of the affection has become obvious, as can be seen from Colour Plate 1(b) and Fig. 9, both of which illustrate typical advanced choroideremia. In the first case there was originally little evidence of choroidal sclerosis (Colour Plate 1(c)); but in the second case (Fig. 10) the evidence for choroidal sclerosis was rather more definite. It is clear from a comparison of the earlier and the later stages that choroideremia is a progressive affection in which the choroidal vessels become unmasked and sclerosed before they disappear ophthalmoscopically. The appearances of partial choroideremia and of choroidal sclerosis are therefore not, as previously suggested, unusual forms of choroideremia, but merely intermediate stages. The very early stages are still less pathognomonic, as can be seen in Colour Plates 1(f) and 1(e), which recall the appearances seen in the women of the affected families rather than incipient choroideremia.

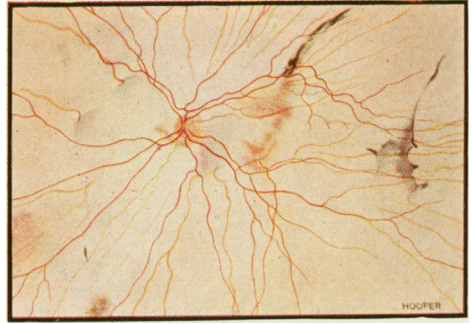
Though the affection is progressive, it bears no direct relationship to age. Though generally more advanced in the elderly, it may yet be fully developed in a relatively young man and only partially so in an older man. In this series, Colour Plate 1(b) illustrates a severe stage at the age of 41.

In the course of the affection, some features are prominent:

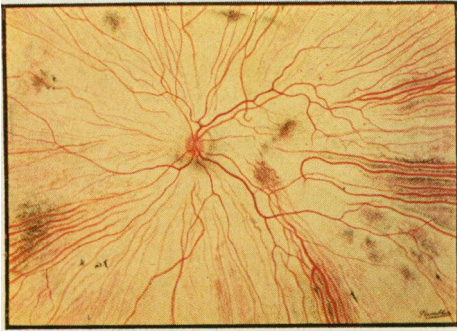- (i) It is only towards the end that the reddish central area is engulfed.
- (ii) Towards the periphery the adjoining edges of normal and damaged tissue generally take the shape of an irregular map-like contour line.



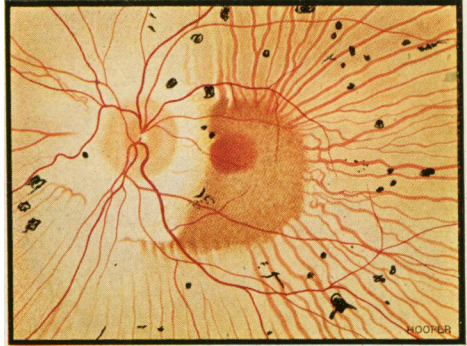
1(a).—Right fundus of S III, 32, male, aged 57. Extensive atrophy of choroid. Remnants of choroidal vessels seen temporally, and island of retained red reflex present above. Patient is myopic and conscious of defective vision since childhood; deterioration steady.



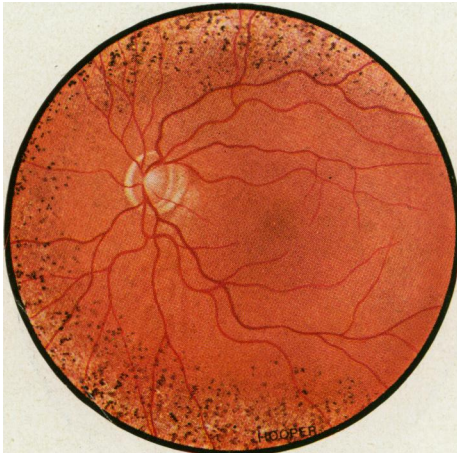1(b).—Left fundus of S III, 37, male, aged 41. Extensive atrophy of retina and choroid. Remnant of retained choroid seen at left of central area. Nightblindness since childhood with progressive deterioration; vision is perception of light only.



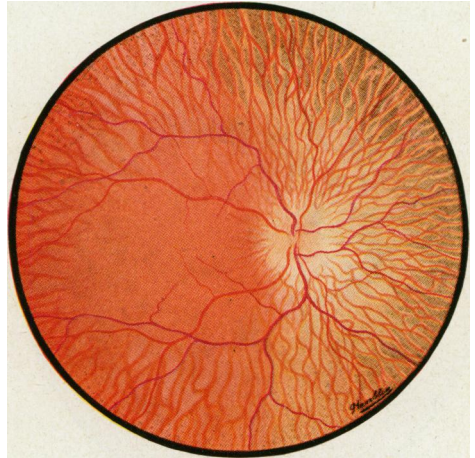
1(c).—Left fundus of S III, 37 (earlier stage of 1b), showing appearances observed 13 years previously, when the patient was aged 28 and vision was 3/60. The right eye showed an essentially similar picture.



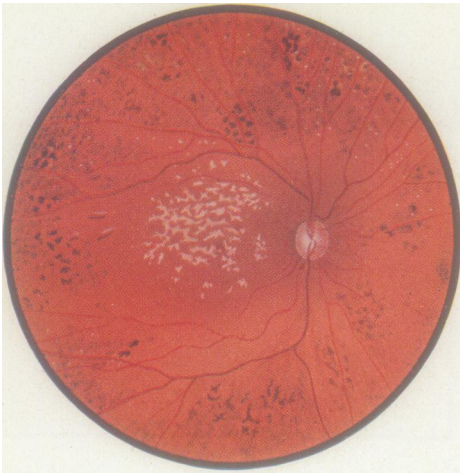
1(d).—Left fundus of G IV, 3, male, aged 35. Note retained central fundus area and golden ring of relatively intact retina around disk. Vision 6/9 in each eye, but fields greatly reduced (Fig. 19a-b).



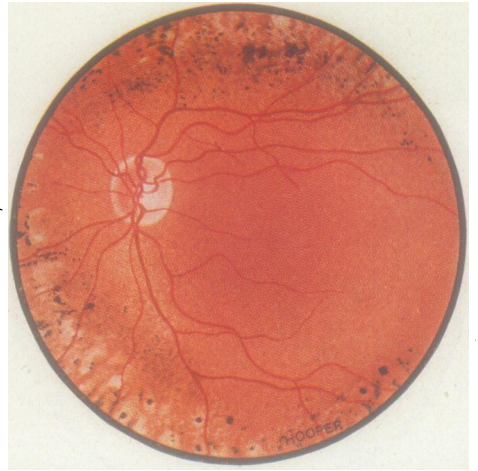1(e).—Left fundus of C IV, 1, aged 18, grandson of C II, 7 (Fig. 8). No nightblindness, vision with correction 6/9. His fundi recall the anomalies seen in carrier women, the appearances being less marked than in his mother (C III, 3, 2b).



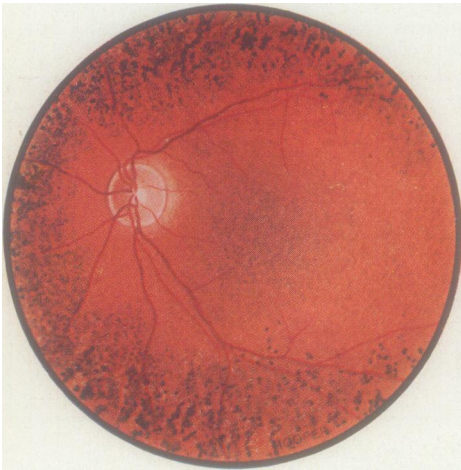1(f).—Right fundus of S IV, 3, male, aged 4½. His mother (S III, 6, Fig. 5) has noticed that he does not see well in the dusk. Note exposure of choroidal vessels with slight atrophy around disk, and fine pigimentary mottling peripherally.



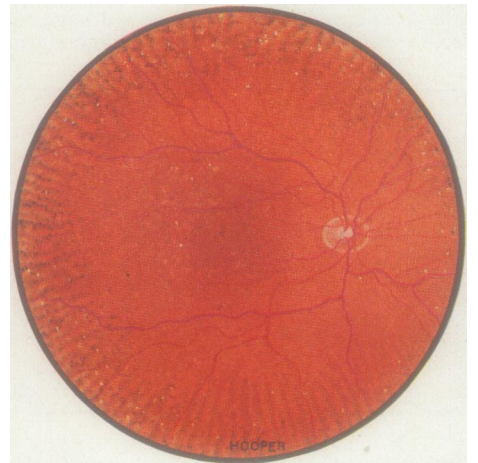
2(a).—Right fundus of S IV, 19, female, aged 23. Besides the characteristic peripheral pigmentation there is a marked central reaction which does not affect vision.



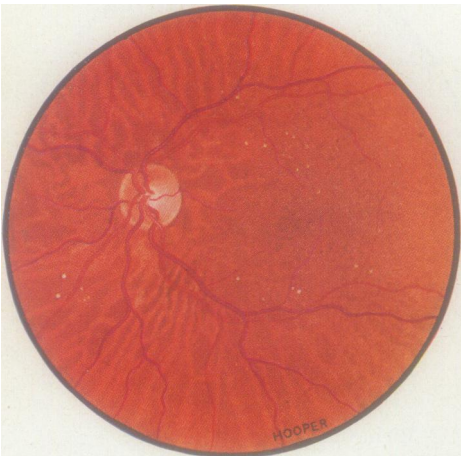2(b).—Left fundus of C III, 3, female, aged 45, eldest daughter of C II, 7 (affected man, Fig. 8).



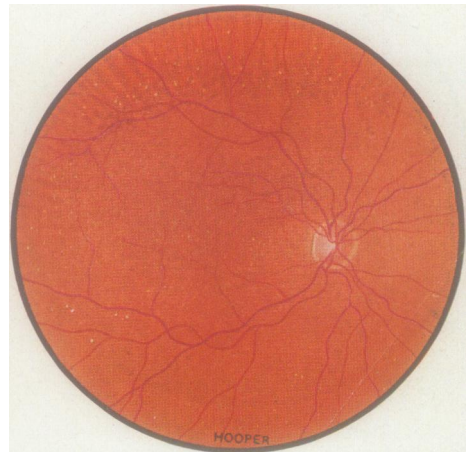
2(c).—Left fundus of G V, 4, female, aged 3½, daughter of G IV, 3 (1d). Heavy peripheral involvement very similar to that of her elder sister (G V, 1, Fig. 18).



2(d).—Right fundus of C IV, 4, aged 14, daughter of C III, 5 (carrier, 2f), and grand-daughter of C II, 7 (affected man, Fig. 8). Appearances in identical twin sister, C IV, 5, are shown in Fig. 13.



2(e).—Left fundus of S II, 16, female, aged 65, cousin of S II, 1 (affected man, Fig. 1), and mother of S III, 37 (affected man, 1b and 1c). Two of her nephews (S III, 32, (1a) and S III, 33) are also affected.



2(f).—Right fundus of C III, 5, female, aged 39, younger sister of C III, 3 (2b) and C III, 4 (Fig. 12). Appearances much less marked than in the other two sisters.

(iii) Some relatively healthy tissue tends to remain like a golden halo around the disk until towards the very end. This is seen in Colour Plates 1(c) and 1(b), and Figs 1, 8, and 9, and is especially marked in Colour Plate 1(d) and Fig. 10.

(2) STATIONARY CHARACTER OF THE AFFECTION IN WOMEN.—There is no actual evidence that the fundus changes in women remain stationary, for there is no record of any woman who has been followed-up critically for some years. It may, however, be assumed that the condition is essentially stationary in women for two reasons:

(i) There is nothing to suggest that symptoms develop in women later in life. This series includes three women, aged 60 or over, who, though they show substantial ophthalmoscopic changes (Colour Plate 2(e) and Figs 2 and 11), are free from any subjective symptoms.

(ii) A less cogent reason, there is no relationship between the fundus appearances and the age of the women carriers. In fact, in this series, some of the most marked ophthalmoscopic features were seen in two little girls aged 8 and 3½ (Fig. 18 and Colour Plate 2(e)). Furthermore, in a woman aged 55 (Fig. 3), in her daughter aged 31 (Fig. 4), and in her grand-daughter aged 6 (Fig. 6), the appearances are fairly similar. Probably the most marked changes of all were seen in women aged 41, 28, and 23 (Figs 12 and 17 and Colour Plate 2(a)).

### (3) RANGE OF MANIFESTATIONS

(a) **In Men.**—Colour Plate 1(a-f) and Figs 14, 10, 1, 8, and 9 may be taken as illustrative of the range of ophthalmoscopic appearances in men. On the whole the range follows a chronological order, but not strictly so, for a most severe reaction (Colour Plate 1(b)) was found in a man aged 41.

(i) *Earliest Stages.*—Colour Plate 1(f) shows the earliest stage, observed in a boy aged 6½; here there is little more than some peripheral atrophic reaction with exposure of choroidal vessels. Colour Plate 1(e) shows rather more marked changes observed in a boy aged 18.

(ii) *Intermediate Stages.*—Colour Plate 1(c) shows appearances at the age of 28; here there is exposure of the choroidal vessels with considerable atrophy in between. Somewhat similar appearances are shown in Colour Plate 1(d) and Fig. 14. In Fig. 10 choroidal sclerosis approaching the stage of disappearance of the choroidal vessels is in evidence at the age of 43.

(iii) *Advanced Stages.*—The diagnosis in Fig. 1, observed in a man aged 67, is now undoubted. Figs 8 and 9 and Colour Plates 1(a) and (b) represent the most severe phases observed in this series, at the ages of 72, 57, 57 and 41 respectively.

It would seem that the earliest phases show nothing characteristic and do not differ greatly from the appearances seen in carrier women. The subsequent developments are not as yet fully elucidated. Exposure of the choroidal vessels probably occurs relatively early, but conversion of these vessels into white streaks appears to be exceptional. Instead they slowly disappear, the process spreading from the periphery towards the centre with retained islands here and there. The fundus reflex assumes a yellowish

coloration and ultimately ends in the dead white reflex seen in the advanced stage. Complete disappearance of all the choroidal vessels, so that no vestige of the choroidal circulation remains, is apparently exceptional.

**(b) In Women.**—Here the range is more limited, though it is sufficiently wide to have been reported in the literature under such varying appellations as superficial atrophy of the choroid, pepper and salt fundus, and typical or atypical retinitis pigmentosa. Schematically the appearances may be classified into three groups:

(i) *Exclusively Peripheral Disturbances.*—These are illustrated by Colour Plates 2(f) and (b). In the first there is very mild peripheral disturbance of the pepper and salt type, and in the second the peripheral disturbance is of a gross pigmentary type overlying a pepper and salt reaction. Both these women were mothers of affected children.

(ii) *Peripheral Involvement with Mottling of the Central Areas.*—This is seen in most cases (Colour Plate 2(e) and (c) and Figs 3, 4, 6, 7, 13, 15, 16, 17, and 18). In some the peripheral involvement is mild (Colour Plate 2(e) and Figs 4, 6, 3, and 13). In others the periphery is more heavily affected; succeeding degrees of severity are shown in Figs 16, 7, 15, 17, and 18, and Colour Plate 2(c).

(iii) *Peripheral Involvement with Considerable Central Involvement going beyond the Stage of Mottling.*—This is shown in a progressive series in Figs 2 and 11, Colour Plate 2(d), Figs 5 and 12, and Colour Plate 2(b). There is no relationship between the severity of the peripheral reaction and that seen centrally. A particularly marked central reaction is seen in Colour Plate 2(a).

#### (4) SUBJECTIVE SYMPTOMS AND REFRACTION

**(a) In Men.**—The pointing symptom in choroideremia is nightblindness. In the present series, the mother of the boy aged  $6\frac{1}{2}$ , whose fundi are shown in Colour Plate 1(f), had noted that the boy stumbled over things in poor light. In contrast, the young man aged 18, whose fundi are shown in Colour Plate 1(e), was not conscious of nightblindness. Likewise in the G. family, two brothers, now aged 35 and 25 respectively, were not conscious of nightblindness in childhood, and the symptom appeared only at the ages of 20 and 17 respectively. At what age defects in the visual fields became manifest is not known, but in these two men the visual fields were severely involved at the relatively early ages at which they were seen (Colour Plate 1(d) and Fig. 14). In all cases central vision remains good after the fields are grossly involved, but is ultimately lost. The symptoms are, in fact, not unlike those seen in retinitis pigmentosa—as is shown objectively by the dark-adaptation curve of the elder of the two brothers in the G. family (Fig. 22e, overleaf).

It would appear that choroideremia only rarely advances so rapidly that central vision suffers markedly early in life,—as in the case of S III, 37, who was blind by about the age of 25. It is probably true that in most cases blindness does not set in until about the age of 40.

In his analysis of the literature, Waardenburg (1942) suggested that an excess of refractive errors of the low myopia type is to be found in affected men. This reading would have to be evaluated against the incidence of

refractive errors in the normal members of families with choroideremia. In the present series, as can be seen from Table III, almost every type of refractive error (as well as emmetropia) was observed in the affected men in whom refraction was determined.

TABLE III  
REFRACTION IN AFFECTED MEN

Patient	Age	Right Eye	Left Eye
S II, 1 ...	67	Not determined	Not determined
S III, 32 ...	57	-7.50 D. sph.	-7.50 D. sph.
S III, 33 ...	55	Not determined	Not determined
S III, 37 ...	41	-7.00 D. sph. $\bar{c}$ -1.00 D. cyl. 60°	-8.00 D. sph. $\bar{c}$ -2.00 D. cyl. 90°
S IV, 3 ...	6½	Emmetropic	Emmetropic
C II, 7 ...	72	Emmetropic	Emmetropic
C II, 13 ...	56	-0.50 D. sph. $\bar{c}$ -1.50 D. cyl. 90°	-0.50 D. sph. $\bar{c}$ 1.50 D. cyl. 90°
C IV, 1 ...	18	-1.50 D. sph.	-1.50 D. sph.
G IV, 3 ...	35	+1.00 $\bar{c}$ +0.50 D. cyl. 45°	+1.50 D. sph. $\bar{c}$ +0.50 D. cyl. 45°
G IV, 7 ...	25	+2.00 D. sph.	+3.75 D. sph.

(b) **In Women.**—The present study confirms that the carrier state, though ophthalmoscopically fairly obvious, is asymptomatic. The dark-adaptation curves were fully normal in three carrier women examined (Figs 22*a-c*, overleaf) and doubtfully pathological in two (Figs 22*d* and 21, overleaf).

(5) **DIFFERENTIAL DIAGNOSIS.**—The fully developed picture of choroideremia is pathognomonic, but in the earlier stages the affection presents a considerable diagnostic puzzle. How difficult the diagnosis in women carriers may be is obvious from the discussion of the range of appearances seen in such women. Without a full family history the diagnosis of choroideremia during the early and middle stages, and of the carrier state, must frequently remain problematic. It is also not unlikely that the affection is not so rare as is generally believed.

(6) **PATHOLOGY.**—Excluding the doubtful case of Fornes Peris (1947), our knowledge of the affection is confined to a report on two cases by McCulloch and McCulloch (1948). As already indicated, there is histological evidence not only of the disappearance of the choroidal vessels but also of sclerosis of these vessels. This conforms to the clinical observations that sclerosis of the choroidal vessels may be seen ophthalmoscopically during the early and middle stages of the affection.

(7) **MODE OF INHERITANCE.**—The following are the criteria for intermediate sex-linkage:

- (i) only men are fully affected;
- (ii) all their daughters show a modified form of the disturbance;
- (iii) all their sons are unaffected;

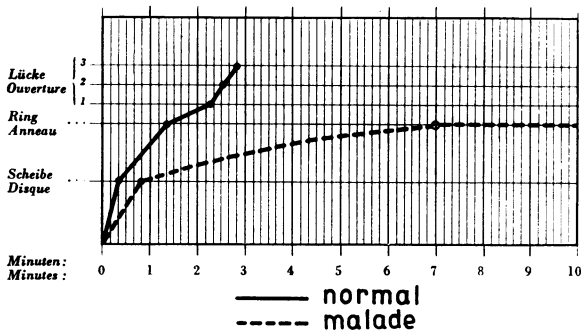


FIG. 21.—Dark-adaptation curve (Della Casa Adaptometer) of a woman carrier aged 23 (S IV, 19 in Pedigree Chart 3). This curve, like that in Fig. 22*d*, shows some reduction in contrast with the normal curves obtained in three women carriers of the G family (Fig. 22*a-c*).

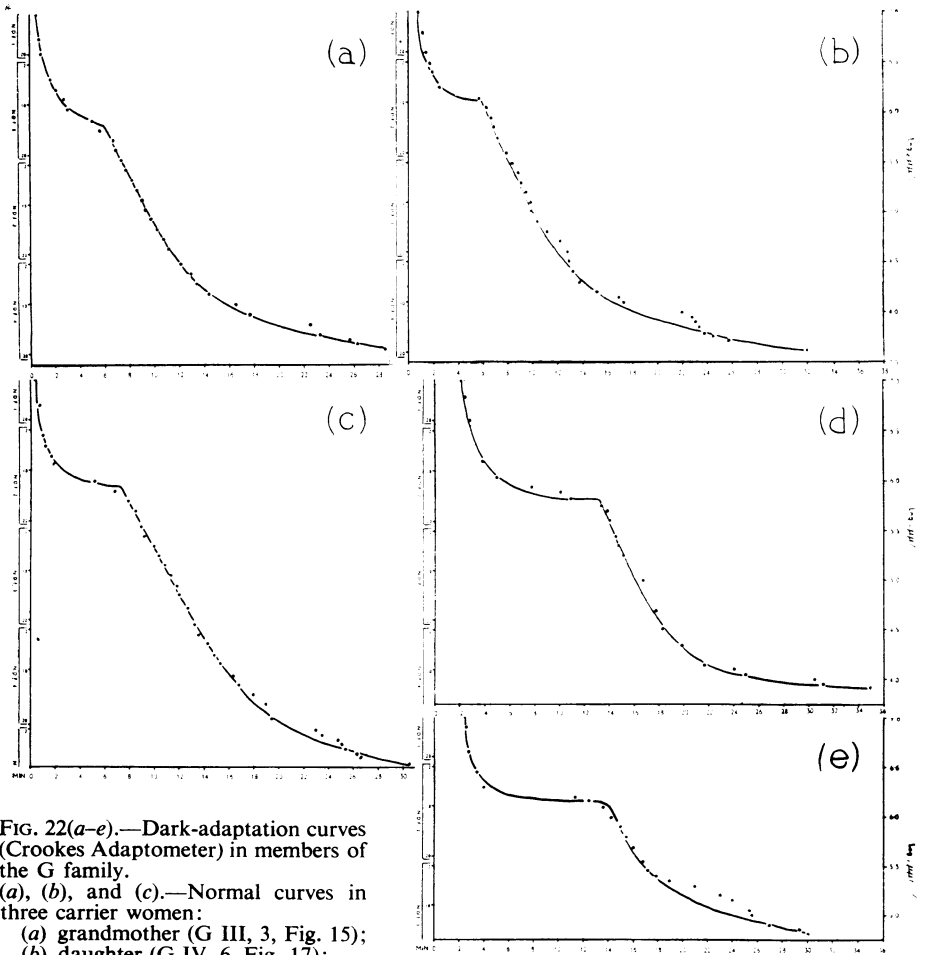


FIG. 22(*a-e*).—Dark-adaptation curves (Crookes Adaptometer) in members of the G family.  
 (*a*), (*b*), and (*c*).—Normal curves in three carrier women:  
 (*a*) grandmother (G III, 3, Fig. 15);  
 (*b*) daughter (G IV, 6, Fig. 17);  
 (*c*) grand-daughter (G V, 1, Fig. 18).

(*d*) Curve showing reduced rod function in a carrier woman (G IV, 5, Fig. 16); daughter of G III, 3. The abnormality may be physiological owing to pregnancy.  
 (*e*) Markedly abnormal curve in an affected man (G IV, 3, proband, Colour Plate 1*d*) son of G III, 3. There is some anomaly in the cone component of the curve; the rod component is grossly abnormal.



(iv) fifty per cent. of the sons of the carrier daughters are affected, and 50 per cent. of daughters are likewise carriers.

(v) no unaffected man transmits the affection, nor does any woman free from the stigmata of the carrier state;

(vi) there should be twice as many carrier women in the population as affected men.

Applying these criteria *seriatim* to the families studied here and recorded in Pedigree Charts 3 to 5, the following observations are valid:

(i) *Only men are fully affected.*

This applies, except that it is necessary to appreciate that choroideremia is a progressive affection, and that the early stages—as already indicated—differ markedly from the end stage of the affection, and are not easy to diagnose.

(ii) *All daughters of an affected man show the carrier state.*

In the S family there are three affected men (S II, 1; S III, 33; and S III, 37) with daughters. In the C family there is one affected man (C II, 7) with three daughters. In the G family there is one affected man (G IV, 3) with two daughters. In all there were five men with eleven daughters. Of these eleven women, only eight could be seen, and they all showed the carrier state (Figs 5, 7, 12, and 18, and Colour Plate 2 (a, b, c, f), and all but one had affected children (Table IV).

TABLE IV  
CHILDREN BORN TO WOMEN SHOWING OPHTHALMOSCOPIC CHANGES

Parents	Children					
	Affected Men or Carrier Women		Unaffected		Not Known	
	M	F	M	F	M	F
S II, 7 ... ..	—	1	1	—	—	—
S II, 16 ... ..	1	—	2	—	—	—
S III, 6 ... ..	1	—	—	—	1	—
S III, 25... ..	—	1	1	—	—	—
	2	2	4	0	1	0
C II, 10 ... ..	—	—	1	—	—	—
C III, 3 ... ..	1	—	1	1	—	—
C III, 5 ... ..	—	1*	—	—	—	—
	1	1*	2	1	—	0
G III, 3 ... ..	2	2	1	1	—	—
Total ... ..	5	5*	7	2	1	0

\*An identical twin counted as one.

(iii) *All sons of affected men are unaffected.*

Five affected men in these three families had eight sons; of these eight sons only four could be seen, but they were all normal. (The remaining four are reputed normal.)

(iv) *Fifty per cent. of sons of carrier women are affected, and 50 per cent. of daughters of carrier women are carriers.*

These families included nine observed carrier women with children. The findings in their children are shown in Table IV. Excluding the one son who could not be seen, there were five affected sons in a total of twelve, and five carrier daughters in a total of seven—a distribution consistent with the theoretical expectation of 1:1.

(v) *No unaffected man transmits the affection, nor does any woman free from the stigmata of the carrier state.*

In these families there is no instance of a normal individual passing on the affection.

(vi) *There is a ratio of 2 : 1 of women carriers: affected men.*

The mathematical expectation that in the population there would be twice as many carrier women as affected men arises from the fact that a woman has two chances of having an abnormal X chromosome to a man's one chance. In these families eleven affected men were observed. In contrast there were 21 observed women carriers. (It should however be pointed out that there were three daughters of affected men who could not be seen and who would presumably be carriers: S III, 1, 2, and 5.)

The evidence for intermediate sex-linkage is therefore conclusive. It may be noted that in these pedigrees there are five instances of observed transmission over three generations.

In the S family an affected man (S II, 1) has passed the affection to his grandson (S IV, 3) through his carrier daughter (S III, 6), whilst a carrier woman (S II, 7) has passed the carrier state on to her daughter (S III, 25) and grand-daughter (S IV, 14). The grandmother's first cousin (S II, 16) has transmitted the affection to one of her sons (S III, 37) and through him the carrier state to his daughter (S IV, 22).

In the C family, a man (C II, 7) has passed the carrier state on to his three daughters (C III, 3, 4, and 5), one of whom (C III, 3) has transmitted the affection to a son (C IV, 1), while another (C III, 5) has transmitted the carrier state to her twin daughters (C IV, 4, and 5).

In the G family a carrier woman (G III, 3) has two affected sons (G IV, 3 and 7) and two carrier daughters (G IV, 5 and 6), and her elder affected son has two carrier daughters (G V, 1 and 4).

(8) CLINICAL IMPLICATIONS OF INTERMEDIATE SEX-LINKAGE.—In intermediate, as in recessive sex-linkage, observations over at least three generations are necessary to establish the mode of inheritance, though in the case of intermediate sex-linkage observations over two generations may be adequate. With a recessive sex-linked affection, the evidence is convincing if an affected man has affected grandsons through unaffected daughters. It may, however, happen that the affection is carried over two or three generations of women, and that an affected man will appear who has derived his affection not from his grandfather, but from his great-grandfather, or a more remote ancestor.

In a direct line four or more generations would therefore have to be known; actually the key in such cases is the occurrence of the affection in maternal uncles. With intermediate sex-linkage the fact that the women carrier can be identified makes it possible to diagnose the condition by a study of two generations only. An affected man will have a mother who shows the carrier state.

The frequency with which a recessive or intermediate sex-linked affection becomes manifest is considerably less than the frequency observed in dominant autosomal inheritance. In dominant inheritance 50 per cent. of the children of affected individuals are affected in successive generations. With recessive or intermediate sex-linkage the situation is otherwise; it can be visualized in the following scheme postulating idealized families (Fig. 23):

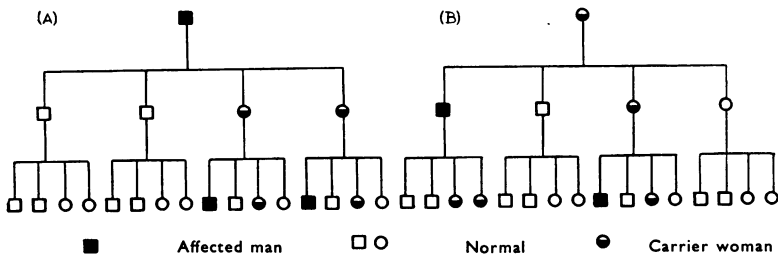


FIG. 23.—Schematic representation of transmission of pathological and carrier states in intermediate sex-linkage in idealized families of four children.  
 (A) Transmission by an affected man. (B) Transmission by a carrier woman.

In pedigree (A) an affected man has only carrier daughters, and these pass the affection on to 50 per cent. of their sons. In three generations comprising an idealized family group of 21 individuals, there are therefore three affected men.

In pedigree (B) a woman carrier in an identical group has an affected son and a carrier daughter. In the third generation only one boy will be affected. In this idealized family group also comprising 21 individuals there will therefore be two affected men in three generations.

With an autosomal dominant affection, the idealized family group of 21 individuals would give seven affected persons over three generations and there would be no sex distinction.\* With an autosomal recessive affection, cases would occur in only one generation, and they would theoretically constitute a quarter of the sibship.

The frequency with which a recessive or intermediate sex-linked affection manifests itself, lies therefore between the frequency given on the one hand by dominant and on the other hand by recessive autosomal affections. Clinically this compels a more exhaustive investigation in a recessive or intermediate sex-linked affection than in either recessive or dominant autosomal affections, in which the family background may be more obvious. In the case of a dominant affection, affected members in the preceding generation

\* There would be a sex difference but no numerical difference with dominant sex-linkage; for the purpose of the present discussion this can be ignored.

are more common; in the case of a recessive affection, particularly an uncommon one, consanguinity may be present in a fair proportion of cases.

Intermediate sex-linked inheritance—at any rate in such conditions as choroideremia, where the carrier state is non-pathological—carries this considerable diagnostic advantage over recessive sex-linkage. All the daughters of a man with a recessive or intermediate sex-linked affection are carriers, and genetic advice can be given on the basis of this knowledge. All the daughters of a woman carrier must be regarded as potential carriers in a recessive sex-linked affection, for it is impossible to distinguish the carrier from the non-carrier clinically. In intermediate sex-linkage the carrier can be picked out clinically: in choroideremia the carrier state is betrayed by the ophthalmoscopic changes. Thus any daughters of a carrier woman who have normal fundi can be dismissed from consideration.

(9) NOMENCLATURE.—The term choroideremia is not altogether satisfactory. The name emphasizes the terminal appearances and implies a static condition. Progressive choroidal atrophy would therefore seem to be a more appropriate designation.

### Summary

(1) Choroideremia is an affection inherited in an intermediate sex-linked manner, as suggested independently by Goedbloed and Waardenburg (1942), and proved by McCulloch and McCulloch (1948). There is nothing in the older literature that is not consistent with this reading.

(2) An account is given of three families with choroideremia. They all show intermediate sex-linkage. The progressive character of the affection in men is shown by the range of appearances at different ages and by records in two cases re-examined after 13 years. In women, though the ophthalmoscopic changes may be quite marked, there is nothing to suggest that they are progressive, and there are no subjective symptoms.

(3) The clinical implications of intermediate sex-linkage are discussed.

(4) It is suggested that the affection would be better designated “progressive choroidal atrophy”.

We are indebted to Professor Marc Amsler (*Zurich*), Dr. J. D. Blum (*Geneva*), Dr. J. H. Dowds (*Bulawayo*), Lt.-Col. George, R.A.M.C., Dr. B. Kay (*Cape Town*), and Mr. R. F. Lowe (*Melbourne*) for information kindly supplied concerning some individuals we have not been able to see for ourselves. Mr. R. F. Lowe was also good enough to send us Figs 14 and 20. We are further indebted to the Hon. G. J. O. Bridgeman, Dr. H. Kaye (*Johannesburg*), and Dr. T. M. Shapira (*Chicago*) for personal communications, and to Mr. D. W. A. Mitchell for referring to us the proband in the third family recorded here. Drs. R. J. P. and Clement McCulloch have kindly supplied information elucidating the pedigrees published by them.

We are also indebted to the National Institute for the Blind for a grant towards the cost of a publishing the colour illustrations. Two of us (R. J. and J. B. D.) are obliged for grant to the Board of Governors of the King's College Hospital Group.

### REFERENCES

- ALEXANDER, E. W. (1910). *Ophthalmology*, 6, 343.  
 BAHN (1932). *Recorded by* Bedell, A. J. (1937).  
 BECKERSHAUS, F. (1926). *Klin. Mbl. Augenheilk.*, 76, 384.  
 BEDELL, A. J. (1937). *Arch. Ophthal.*, Chicago, 17, 444.

- BENCINI, A. (1938). *Boll. Oculist.*, **17**, 217.
- BENEDICT (1937). *Recorded by Bedell, A. J. (1937)*.
- BHADURI, B. N. (1934). *Calcutta med. J.*, **28**, 428.
- BRIDGEMAN, G. J. O. (1951). Personal communication.
- BULLAR, J. F. (1898). *Trans. ophthal. Soc. U.K.*, **18**, 183.
- CONNOR, A. B. (1919). *Amer. J. Ophthal.*, ser. 3, **2**, 553.
- COWGILL, W. M. (1892). *Arch. Ophthal., Chicago*, **21**, 105.
- CUTLER, C. W. (1895). *Ibid.*, **24**, 334.
- DIMMER, F., and PILLAT, A. (1927). "Atlas photographischer Bilder des menschlichen Augenhintergrundes", Plate 74. Deuticke, Leipzig.
- ESTERMAN, B. (1947). *Arch. Ophthal., Chicago*, **37**, 716.
- FORNES PERIS, E. (1947). *Arch. Soc. oftal. hisp-amer.*, **7**, 134.
- GOEDBLOED, J. (1942). *Ophthalmologica, Basel*, **104**, 308.
- GRIMSDALE, H. (1917). *Proc. roy. Soc. Med.*, **10** (Sect. Ophthal. p. 29).
- HUTCHINSON, J. (1900). *Arch. Surg. Lond.*, **11**, 118.
- KOENIG, H. (1874). "Zwei Beobachtungen von mangelhafter Entwicklung der Chorioidea verbunden mit Hemeralopie". Kunike, Greifswald.
- LANDMAN, O. (1906). *Arch. Augenheilk.*, **54**, 63.
- LAURENCE, J. Z., and MOON, R. C. (1866). *Ophthal. Rev.*, **2**, 32.
- LOWE, R. F. (1951). *British Journal of Ophthalmology*, **35**, 31.
- MAGDER, H. (1945). *Arch. Ophthal., Chicago*, **33**, 468.
- MARBAIX, O. (1908). *Bull. Soc. belge Ophthal.*, No. 24, p. 18.
- DI MARZIO, Q. (1937). "Fundus Oculi", fig. 194. Salomone, Rome.
- MAUTHNER, L. (1872). *Ber. naturw.-med. Ver. Innsbruck*, **2**, 191.
- MCCULLOCH, C., and MCCULLOCH, R. J. P. (1948). *Trans. Amer. Acad. Ophthal. Otolaryng.*, **52**, 160.
- (1950; 1951). Personal communications.
- MEYRAN, J. (1948). *Bol. Hosp. Oftal. Nues. Sen. Luz.*, **4**, 21. (Abstract in *Ophthal. Lit., Lond.*, **2**, 93).
- PARKER, W. R., and FRALICK, F. B. (1931). *Arch. Ophthal., Chicago*, **6**, 213.
- RIDDELL, W. J. B. (1939). *Trans. Ophthal. Soc. U.K.*, **59**, 275.
- (1950). Personal communication.
- SAEBØ, J. (1948). *British Journal of Ophthalmology*, **32**, 824.
- SCHUTZBACH, M. (1938). v. Graefes *Arch. Ophthal.*, **138**, 315.
- DE SCHWEINITZ, . (1931). *Recorded by Parker and Fralick (1931)*.
- SCOBEE, R. G. (1943). *Amer. J. Ophthal.*, **26**, 1135.
- SHAPIRA, T. M. (1951). Personal communication.
- and SITNEY, J. A. (1943). *Amer. J. Ophthal.*, **26**, 182.
- SMITH, H. E., and USHER, C. H. (1916). *Roy. Lond. ophthal. Hosp. Rep.*, **20**, 157.
- SORSBY, A. (1939). *British Journal of Ophthalmology*, **23**, 423, figs 20 and 21.
- (1940). "Modern Trends in Ophthalmology", vol. I, ed. F. Ridley and A. Sorsby, p. 464. Butterworth, London.
- THOMPSON, J. T. (1899). *Trans. Ophthal. Soc. U.K.*, **19**, 140.
- USHER, C. H. (1935). *Ibid.*, **55**, 164.
- WAARDENBURG, P. J. (1942). *Acta ophthal., Kbh.*, **20**, 235.
- WARDALE, J. D. (1906). *Northumberland and Durham Med. J.*, **14**, 3.
- WERKLE, F. (1931). *Klin. Mbl. Augenheilk.*, **87**, 173.
- WOLF, S. (1930). *Arch. Ophthal., Chicago*, **3**, 80.
- WÜRDEMANN (1935). *Recorded by Bedell, A. J. (1937)*.
- WILMER, W. H. (1934). "Atlas Fundus Oculi", Plate 83. Macmillan, New York.
- ZORN, B. (1920). v. Graefes *Arch. Ophthal.*, **101**, 1.

## APPENDICES

### (1) The S. Family (Pedigree Chart 3)

#### Generation I

- S I, 1 and 2, Mr. and Mrs. L.* Dead, reputed normal.
- S I, 3, Michel A.* Dead, reputed affected.
- S I, 4, Berel A.* Dead, reputed affected.
- S I, 5.* Number and sex not known.

#### Generation II

- S II, 1-8.* Children of *S I, 1 and 2*, both reputed normal.

1. *Nathan L.* First seen in 1948, aged 67, affected. Visual acuity: perception of light only. Poor projection. Nightblind since early childhood, and incapacitated since about the age of 55. Fundi showed advanced stage of choroideremia (Fig. 1).
2. *Lewis L.* Died aged 62, reputed normal.
3. *Mrs. Julie P.* Seen February 4, 1951, aged 65. No subjective symptoms. Visual acuity: 6/9 each eye. Fundi: typical carrier, fairly severe changes (Fig. 2). No children.
4. *Mrs. Annie W.* Aged 64, lives in New York, not seen.
5. *Mrs. Katie C.* Seen November 22, 1950, aged 62. Visual acuity: right, 3/60, with  $-4.0$  D. sph. 6/18 or more; left, 3/60, with  $-3.0$  D. sph. 6/18 or more. Fundi: normal except for mild arteriosclerosis.
6. *Mrs. Millie Le.* Seen January 4, 1951, aged 60, no eye trouble. Visual acuity: 6/6 in each eye. Fundi: normal.
7. *Esther B.* Seen October 10, 1950, aged 55. Visual acuity: 6/6 each eye. Fundi: carrier type, mild (Fig. 3).
8. Unknown number and sex. Died young.

*S II, 9-10.* Children of *S I, 3*, sex not known.

*S II, 11-16.* Children of *S I, 4*, reputed affected.

11, 12, and 13. *Harry, Leon, and Nathan A.* This branch of the family and their descendants were murdered in Nazi concentration camps. They are reputed to have been normal.

14. *Nrs. Nacha T.* 1866-1944, reputed normal.

15. *Mrs. Sarah G.* Dead.

16. *Mrs. Rebecca S.* Seen in 1950, aged 65. Early lens changes both eyes. No subjective symptoms. Fundi: carrier type, medium (Colour Plate 2*e*).

### Generation III

*S III, 1-6.* Children of *S II, 1*, affected.

1. *Mrs. Gertie C.* Aged 39, could not be seen.

2. *Mrs. Annie V.* Younger sister, could not be seen.

3. *Sidney L.* Seen February 22, 1951, aged 34. Visual acuity: 6/6 each eye. Fundi: normal. Emmetropic.

4. *Harry L.* Seen May 22, 1951, aged 32. Visual acuity: 6/6 each eye. Fundi: normal.

5. *Mrs. Renie D.* Aged 31, could not be seen.

6. *Mrs. M.* Seen in 1950, aged 27. Visual acuity: right, 6/18, with  $+4.00 \ominus -2.75$  at  $175^\circ = 6/9$ ; left, 6/18, with  $+4.00 \ominus -2.75$  at  $175^\circ = 6/9$ . Fundi: carrier type (Fig 5).

*S III, 7-12.* Children of *S II, 2*, reputed normal.

7. *Norman L.* Seen December 19, 1950, aged 36. Visual acuity: 6/5 each eye with correction. Fundi: normal.

8. *Harold L.* Seen December 19, 1950, aged 34. Visual acuity: 6/6 each eye. Fundi: normal.

9. *Bernard L.* Seen December 18, 1950, aged 30. Visual acuity: right, 6/36, with correction 6/6; left, 6/60, with correction 6/6. Fundi: normal.

10. *Mrs. M. E. S.* Seen March 3, 1951, aged 28. Visual acuity: 6/6 each eye. Normal colour vision (Ishihara). Fundi: normal.

11. *Miss Irene L.* Seen March 3, 1951, aged 27. Visual acuity:  $-2.75 \ominus +0.50$  at  $180^\circ = 6/5$ , each eye. Normal colour vision (Ishihara). Fundi: normal.

12. *Miss Anita L.* Seen March 3, 1951, aged 22. Visual acuity: 6/6 each eye. Fundi: normal.

*S III, 13-14.* Sons of *S II, 4*, not traced.

13. *Mr. W.*  
14. *Mr. W.* Dead } In U.S.A., not seen.

*S III, 15-21.* Children of *S II, 5*, normal.

15. *Ben C.* Aged 35. Visual acuity: right, 6/60; left, 6/36. Lens changes in both fundi similar to those of his brother *Percy* (*S III, 18*).

16. *Harry C.* Aged 32. Fundi: normal.

17. *Miss C.* Died young.

18. *Percy C.* Aged 28. Royal Eye Hospital No. 49/1676. First seen in 1948. Poor sight and nightblindness since childhood. Visual acuity: 6/18, each eye. Colour vision normal (*Ishihara*).

April 6, 1951. Visual acuity: right, 6/18; left, 6/24. Emmetropic. Very slight nystagmus. Object under regard "jumps about". Fundi show a central lesion with evident choroidal sclerosis and patches of choroidal atrophy and pigmentation.

19. *Martin C.* Aged 25, no subjective symptoms. Visual acuity: 6/5. Fundi: normal.

20. *Rose C.* Aged 22. Visual acuity: 6/5 each eye. Fundi: normal.

21. *Maurice C.* Aged 18. Visual acuity: 6/5 each eye. Fundi: normal.

*S III, 22-24.* Children of *S II, 6*, normal.

22. *Mrs. Pearl T.* Aged 28. Visual acuity: right, 6/9; left, 6/6. Colour vision normal (*Ishihara*). Fundi: normal.

23. *Rene Le.* Aged 25. Visual acuity: 6/6 each eye. Fundi: normal.

24. *Harry Le.* Aged 23. Visual acuity: 6/6 each eye. Colour vision normal (*Ishihara*).

*S III, 25-26.* Children of *S II, 7*, a woman showing the carrier state.

25. *Mrs. Sh.* Seen October 3, 1950, aged 31. Visual acuity: right refraction:  $+1.50 \ominus -4.25$  at  $15^\circ = 6/9$ ; left,  $+1.25 \ominus -4.25$  at  $165^\circ = 6/9$ . Fundi: mild carrier type (*Fig. 4*).

26. *Alfred B.* Aged 29. Visual acuity: 6/6 each eye. Fundi: normal.

*S III, 27-30.* Children of *S II, 11-13*, all massacred during the war.

*S III, 31-34.* Children of *S II, 14*, all live in Switzerland.

31. *Salomon Tu.* Aged 59. Fundi: normal (*Prof. Marc Amsler*).

32. *Leon Tu.* Aged 57. Affected. Nightblind since childhood (*Colour Plate 1a*). Refraction  $-7.5$  D. each eye. Left,  $\bar{c}$  correction = 6/60. Fields greatly reduced. Advanced choroideremia.

33. *Isidor Tu.* Aged 55. Affected. Appearances as in his brother (not drawn).

34. *Max Tu.* Aged 43. Normal (*Prof. Amsler*).

*S III, 35.* Children of *S II, 15*, deceased. Number and sex not known.

*S III, 36.* *Mrs. S.* Aged 38, wife of *S III, 37*, is blind from retinitis pigmentosa. She is unrelated to this family.

*S III, 37-39.* Children of *S II, 16*, a woman showing carrier state.

37. *Sid (Sole) Sch.* Now aged 41. Proband. First seen in 1938, aged 28, and recorded as a case of partial choroideremia without family history (*Sorsby, 1940*); fundi were then as in *Colour Plate 1(c)*. The appearances now, 13 years later, are shown in *Colour Plate 1(b)*. He suffered from nightblindness since childhood, but owing to steady deterioration of vision had to give up his work as a tailor at the age

of 18, and has been blind since the age of 25. Vision is now barely perception of light. Refraction: right,  $-7.00$  D.S.  $\ominus -1.00$  cyl. axis  $60^\circ$ ; left,  $-8.00$   $\ominus -2.0$  axis  $130^\circ$ .

38. *Mr. Sh.* Seen November 4, 1950, aged 33. Visual acuity: 6/6 each eye. Fundi: normal.

39. *Ben Sa.* Aged 42. Visual acuity: 6/6 each eye. Fundi: normal.

#### Generation IV

*S IV, 1-4.* Grandsons of *S II, 1*, affected.

1 and 2. Not seen.

3. *Howard M.* Affected. Seen January 8, 1951, aged  $6\frac{1}{2}$ . His mother, *S. III, 6*, shows the carrier state. His parents have noticed that he collides with objects in the dark. Emmetropic. Fundi: see Colour Plate 1(f).

4. *Stewart M.* Aged  $4\frac{1}{2}$ , not seen.

*S IV, 5.* Daughter of *S III, 8*, normal. Aged 3 months, not seen.

*S IV, 6-7.* Children of *S III, 10*, normal.

6. *David S.* Aged 6. Deaf-mute. Emmetropic. Colour vision normal (Ishihara). Fundi: normal.

7. *Carol S.* Aged 4. Emmetropic. Colour vision normal (Ishihara). Fundi: normal.

*S IV, 8.* Daughter of *S III, 15*, not seen.

*S IV, 9.* Son of *S III, 16*, not seen.

*S IV, 10.* *Lewis T.* Son of *S III, 22*, normal. Seen April, 1951, aged 9 months. Fundi: normal.

*S IV, 11.* Son of *S III, 24*, normal. Reputed normal.

*S IV, 12.* *Miriam B.* Seen October 3, 1951, aged 2. Fundi: normal.

*S IV, 13-14.* Children of *S III, 25*, a woman showing the carrier state, and her second cousin, *S III, 38*, normal.

13. *Frank Sh.* Seen October 3, 1950, aged 7. Visual acuity: 6/6 each eye. Fundi: normal, though with a heightened macular reflex.

14. *Charlotte Sh.* Seen October 3, 1950, aged 5. Visual acuity: 6/6 each eye. Fundi: carrier type, mild (Fig. 6).

*S IV, 15-16.* Children of *S III, 31*, normal.

15. *Mima Tu.* Aged *c* 34, at Buenos-Aires, not seen, reputed normal.

16. *Moritz Tu.* Aged 32, at Zurich, not seen, reputed normal.

*S IV, 17-19.* Children of *S III, 33*, affected.

17. *Raphael Tu.* Aged 27, at Zurich, not seen, reputed normal.

18. *Max Tu.* Aged 25, at Zurich, not seen, reputed normal.

19. *Bertha Lu.* Aged 23. Vision full. Refraction:  $+3.75$   $\ominus +0.50$  at  $90^\circ$  each eye. Fields full. Slightly defective dark adaptation (Fig. 21). Fundi: carrier type, severe. (Colour Plate 2a).

*S IV, 20-21.* Children of *S III, 34*, normal.

20. *Ludwig Tu.* Aged 17, reputed normal.

21. *Harold Tu.* Aged 11, reputed normal.



*S IV, 22. Evelyn Sch.* Seen December 1, 1950, aged 6. Daughter of *S II, 37*, himself affected, and of *S II, 36*, a woman blind from retinitis pigmentosa. Fundi: carrier type, severe (Fig. 7).

*S IV, 23-24.* Children of *S III, 39*, normal.

23. *Wallis Sa.* Seen November 4, 1950, aged 16. Refraction: right,  $-4.00 \ominus -0.50$  at  $90^\circ = 6/9$ ; left,  $-4.00 \ominus -0.50$  at  $90^\circ = 6/9$ . Fundi: normal.

24. *Philip Sa.* Seen November 4, 1950, aged 9. Refraction: right,  $-1.75 \ominus -0.50$  at  $90^\circ = 6/7.5$ ; left,  $-2.00 \ominus -0.50$  at  $90^\circ = 6/7.5$ . Fundi: normal.

## (2) The C. Family (Pedigree Chart 4)

### Generation I

*C I, 1. Mrs. Sarah H.* Died when over 60 years old, reputed normal.

*C I, 2. Mrs. Hannah C.* Dead, reputed normal.

*C I, 3. Mr. C.* Husband of Hannah C., dead, reputed normal.

*C I, 4. Miss Janie P.* Dead, reputed normal.

*C I, 5. Mr. George P.* Dead, reputed affected.

*C I, 6-7. Mr. and Mrs. C.* This branch of the family and their descendants will be the subject of a subsequent report.

### Generation II

*C II, 1-3.* Children of *C I, 1*, herself reputed normal.

1. *Thomas W.* Dead, reputed normal.

2. *Mrs. Caroline Sarah K.* Dead, reputed normal.

3. *John W.* Dead, reputed normal.

*C II, 4-13.* Children of *C I, 2* and *3*, both reputed normal.

4. *Thomas C.* Died aged 70, reputed normal.

5. *Edith C.* Dead, reputed normal.

6. *Harold C.* Dead, reputed normal.

7. *Charles C.* Aged 72. Affected. First seen in 1938, when vision was 6/9 each eye (Sorsby, 1939). The subjective symptoms were then so mild that he was barely handicapped (he was, however, an unwilling witness). When seen again in 1951, vision was perception of light in both eyes, and he reported that his sight began to fail at 60. The fundus appearance in 1951 is shown in Fig. 8. Emmetropic.

8. *Arthur C.* Aged 70. Visual acuity: 6/6 each eye, with +2.00 D. sph. Fundi: normal.

9. *Mrs. Nellie We.* Aged 66, was seen by Dr. J. H. Dowds (*Bulawayo*) and reported to be normal.

10. *Mrs. Ada Pr.* Aged 64. First seen with *C II, 7* and *13*, in 1938. Her vision was then 6/9 and "suggestive of an old central choroiditis". When seen again in 1951, there was probably some extension peripherally (Fig. 11).

11. *Mrs. Rosie A.* Aged 63, was seen by Dr. B. Kay (*Cape Town*). Vision 6/18 each eye, with +1.00 D. sph. 6/9 each eye. No subjective symptoms. Fundi: carrier state.

12. *Ernest C.* Died aged 56, reputed normal.

13. *William A. C.* Aged 57. His sight has always been defective; he has been handicapped since the age of 25, and nightblind ever since he remembers. Refraction:  $\ominus -0.50 -1.50$  at  $90^\circ$ , each eye. Proband (Sorsby, 1939). In 1937, when he was 44 years old, his vision was 6/24 in the right eye and 6/6 in the left; the fields were reduced to the fixation points. The fundus appearance is shown in Fig. 10.

When seen again in 1948, his vision had declined to right, hand movements, and left, 6/60. Fundus appearance in 1948 is shown in Fig. 9.

Two years later, in 1950, his vision had deteriorated still further to right, perception of light, and left, 2/60.

### Generation III

*C III, 1. Miss N. K.* Aged 61, no subjective symptoms. Visual acuity: 6/9 each eye. Fundi: carrier state.

*C III, 2. Mr. W.* Whereabouts and age not known, reputed normal.

*C III, 3-7.* Children of *C II, 7*, himself affected.

3. *Mrs. Florence F.* Seen April 5, 1951, aged 45. Visual acuity: 6/6 each eye. Colour vision normal. Fundi: carrier state (Colour Plate 2*b*).

4. *Mrs. Doris J.* Aged 41. Visual acuity: 6/6 each eye. Fundi: carrier state (Fig. 12).

5. *Mrs. He.* Seen January 28, 1951, aged 39. Visual acuity: 6/6 each eye. Fundi: carrier state (Colour Plate 2*f*).

6. *Jack C.* Aged 32, no subjective symptoms, emmetropic. Visual acuity: 6/6 each eye. Colour vision normal (Ishihara). Fundi: normal.

7. A twin brother of *C III, 6*. Reputed normal.

*C III, 8-14.* Children of *C II, 8*, himself normal.

8. *Arthur C.* Aged 42. Visual acuity: 6/5 each eye. Fundi: normal.

9. *Henry C.* Aged 41. Visual acuity: 6/6 each eye. Fundi: normal.

10. *Ivy C.* Aged 39, reputed normal.

11. *Florence C.* Aged 33. Visual acuity: 6/6 each eye. Fundi: normal.

12. *Phyllis C.* Aged 32, reputed normal.

13. *Alfred C.* Aged 30. Visual acuity: 6/6 each eye. Fundi: normal.

14. *Frederick C.* Aged 28. Refraction: right,  $-0.50 \text{ C} - 1.00$  at 90; left, emmetropic = 6/5. Fundi: normal.

*C III, 15-16.* Children of *C II, 9*, herself normal.

15 and 16. Son and daughter, seen and found normal by Dr. D. H. Dowds (*Bulawayo*).

*C III, 17. Mr. Pr.* Son of *C II, 10*, a woman showing the carrier state. Aged 27. Visual acuity: 6/9 each eye. Fundi: normal.

### Generation IV

*C IV, 1-3.* Children of *C III, 3*, a woman showing carrier state.

1. *Douglas B. F.* Aged 18. Affected. Not conscious of nightblindness. Visual acuity: 6/9 each eye, with  $-1.50 \text{ D. sph.}$  Colour vision normal (Ishihara). Fundi: resemble those of a carrier (Colour Plate 1*e*).

2. *May F.* Aged 17. Visual acuity 6/6 each eye. Fundi: normal.

3. *David F.* Aged 14. Visual acuity: 6/6 each eye. Fundi: normal.

*C IV, 4-5.* Identical twin daughters of *C III, 5*, a woman showing carrier state.

4. *Barbara He.* Aged 14. Visual acuity: 6/6 each eye. Fundi: carrier state (Colour Plate 2*d*).

5. *Joan He.* A twin sister. Visual acuity: 6/6 each eye. Fundi: carrier state (Fig. 13).

*C IV, 6.* Son of *C III, 7*, reputed normal.

*C IV, 7-9.* Two sons and a daughter of *C III, 15*, a normal man, reputed normal.

*C IV, 10.* Son of *C III, 16*, a normal woman, reputed normal.

### (3) The G. Family (Pedigree Chart 5)

#### Generation I

*G I, 1. Mr. H.* Died when over 70. No history of any eye trouble, was a gamekeeper and then a Metropolitan policeman.

*G I, 2. Mrs. H.* No history of any eye trouble. Nothing further known.

#### Generation II

*G II, 1. Mr. S.* Died in his thirties. First husband of Mrs. Agnes G. (*G II, 2*), reputed normal.

*G II, 2. Mrs. Agnes G.* Died at 64. "Had good sight". One daughter (*G III, 3*) of her second marriage is a carrier.

*G II, 3. Mr. G.* Died when over 70. Wore spectacles but had good sight. Second husband of Mrs. Agnes G. (*G II, 2*).

*G II, 4. Mrs. Charlotte C.* Possibly still alive but not traced. Nothing known of her sight.

#### Generation III

*G III, 1-2.* Children of *G II, 2* by her first marriage.

1. *Mrs. Isabella S.* Aged 70. Refraction: right,  $+5.75 \ominus -1.00$  at  $180^\circ = 6/9$ ; left,  $+4.25$  D.S. =  $6/9$ . Could not be examined, but when seen some years ago at the London Refraction Hospital (Case No. 14088) changes suggestive of arteriosclerosis were noted. Nothing else in the fundus appearance was remarked upon.

2. There were other children of the first marriage of *G II, 2*, but these could not be traced.

*G III, 3-7.* Children of *G II, 2* by her second marriage.

3. *Mrs. Mary Ann G.* First seen May, 1951, aged 56. Refraction:  $+5.00$  D.S.  $\ominus +0.50$  at  $180^\circ = 6/6$  each eye. Colour vision normal (Ishihara). Fundi: carrier type, medium (Fig. 15). Dark adaptation: normal (Fig. 22a).

4. *William G.* Pilot in Royal Flying Corps, killed in the first world war at the age of 26, reputed normal.

5. *Mrs. Nina J.* Seen May, 1951, aged 51. Refraction: right  $+1.50$  at  $170^\circ = 6/6$ ; left  $+1.00$  at  $15^\circ = 6/6$ . Colour vision normal (Ishihara). Fundi: arteriosclerotic changes but otherwise normal.

6. *Mrs. Margaret H.* Refraction:  $-0.50 = 6/9$  each eye. Colour vision normal (Ishihara). Fundi: normal.

7. *Alfred John G.* Seen August 22, 1951, aged 52. Refraction: right  $+5.00 \ominus +3.50$  at  $90^\circ = 6/9$ ; left  $+4.50 \ominus +1.50$  at  $90^\circ = 6/9$  partly. Fundi showed arteriosclerotic changes with narrowed vessels and macular changes; the condition was more marked in the left eye and there was evidence of an old macular haemorrhage. Blood pressure 130/80. No evidence of choroideremia. Colour vision normal. Dark-adaptation curve showed a slightly restricted rod curve.

*G III, 8-9.* Children of *G II, 3* by his first marriage.

8. *Albert G.* Not seen, reputed normal.
9. *Mrs. Alice Elizabeth M.* Not seen, reputed normal.

#### Generation IV

*G IV, 1-2.* Children of *G III, 1*, a normal woman.

1. *Daughter.* Married and lives in Canada, whereabouts not known.
2. *Stanley Sm.* Could not be examined, reputed normal.

*G IV, 3-8.* Children of *G III, 3*, herself a carrier.

3. *Mr. Albert Charles Ga.* Proband. First seen April, 1951, aged 35. Colour vision normal (Ishihara). Fields of vision: central field about  $10^\circ$  horizontally and  $15^\circ$  vertically, in the extreme periphery there was a band of vision some  $5^\circ$  wide on the nasal side and some  $20^\circ$  wide on the temporal side (Fig. 19*a* and *b*). Dark adaptation: both rod and cone curves abnormal. He found the test difficult because of his very small central field (Fig. 22*e*). Refraction: right,  $+1.00 \odot +0.50$  at  $45^\circ = 6/9$ ; left,  $+1.50 \odot +0.50$  at  $45^\circ = 6/9$ .

He has been aware of his trouble since the age of 20 and recently has had trouble when reading small print. He has been conscious of his field restriction since 1939. Fundus appearance shown in Colour Plate 1(*d*).

4. *Mr. Ernest Ga.* Seen April, 1951, aged 33. Refraction: right,  $+1.50 = 6/6$ ; left,  $+2.00 \odot +1.50$  at  $180^\circ = 6/6$ . Colour vision normal (Ishihara). Dark adaptation: normal. Fundi: normal.

5. *Mrs. Hilda B.* Seen April, 1951, aged 31. Refraction:  $+1.50$  D.S. =  $6/5$  each eye. Colour vision normal (Ishihara). Dark adaptation: rod curve (Fig. 22*d*) very reduced but this was attributed to her being pregnant. Fundi: carrier type, medium (Fig. 16).

6. *Miss Olive Ga.* Seen April, 1951, aged 29. Visual fields, central and peripheral normal. Fundi: carrier state (Fig. 17). Dark adaptation: normal (Fig. 22*b*). Refraction: right,  $+2.50$  D.S. =  $6/6$ ; left,  $+3.00$  D.S. =  $6/6$ .

7. *Mr. Wilfred Ga.* Affected. Seen by Mr. R. F. Lowe (*Melbourne*) in May, 1951, aged 25. Refraction: right,  $+2.50 \odot -0.50$  at  $180^\circ = 6/6$ ; left,  $+3.75$  D.S. =  $5/6$ . "He had no trouble with his eyes until 17, when he found his vision for fine print failing". This later improved but about 4 months ago he found that during his work as a piano tuner he would lose detail when peering at things inside the piano. This was only a transient phenomenon and passed off after a few seconds. Some difficulties with night vision appear to go back to this period. Colour vision was not taken but the patient made no mention of being colour blind. Visual fields: right eye (Fig 20*a* and *c*) shows annular scotomata with upper nasal peripheral erosion, while the central area is spared; left eye (Fig 20*b* and *d*) shows annular scotomata which have broken through to peripheral erosions, while the central area is spared. Fundus appearance shown in Fig. 14.

8. *Miss Mary Ga.* Aged 23. Refraction:  $+2.50$  D.S. =  $6/5$  each eye. Colour vision normal (Ishihara). Fundi: normal.

*G IV, 9-11.* Children of unaffected woman (*G III, 6*), reputed normal.

*G IV, 12-13.* Children of unaffected man (*G III, 7*), reputed normal.

*G IV, 14-17.* Grandchildren of *G II, 3* through *G III, 9*, unaffected daughter of his first marriage, reputed normal.

**Generation V**

*G V, 1-4.* Children of *G IV, 3*, an affected man (Proband).

1. *Ann Marie Ga.* Seen May, 1951, aged 8. Refraction:  $+0.50 \supset 1.00$  at  $120^\circ = 6/5$  each eye. Colour vision normal (Ishihara). Dark adaptation: normal (Fig. 22c). Fundus: carrier type (Fig. 18).

2. *Norman Joseph Ga.* Aged 6. Refraction;  $+1.00 = 6/6$  each eye. Colour sense slightly depressed but no definite anomaly detectable. Fundi: normal.

3. *James Kanice Ga.* Aged 5. Refraction:  $+1.50 = 6/6$  each eye. Fundi: normal.

4. *Dorothy Theresa Ga.* Aged 3. Emmetropic. Fundi: carrier type (Colour Plate 2c).

*G V, 5. Michael G.* Aged 6. Colour vision normal. Fundi: normal.

*G V, 6-12.* Great-grandchildren of *G II, 3* by his first marriage, reputed normal.