

## OCULAR FINDINGS IN HAEMOCHROMATOSIS\*

BY

J. R. HUDSON

*Institute of Ophthalmology, London*

HAEMOCHROMATOSIS is a rare condition, the chief clinical features of which are pigmentation of the skin, cirrhosis of the liver, diabetes mellitus, and hypogonadism. The opportunity of examining the eyes of five patients in whom the diagnosis had been confirmed by liver biopsy arose through the kindness of my colleague, Dr. N. F. Coghill, who is incorporating the clinical and pathological investigations in a forthcoming publication. Detailed clinical histories have not, therefore, been included in the present communication.

A review of the literature since 1930 has revealed very few references to the ocular findings. Maddox (1933) describes the retinal appearances observed in four cases, and this reference is quoted by Duke-Elder (1940). Lawrence (1949), in his Banting Memorial lecture, commented upon the absence of vascular changes in the pure and primary forms of islet and pancreatic destruction, and contrasted these with appearances found in primary diabetes; he suggested that a common factor, perhaps the pituitary, might be responsible for both the vascular degeneration and the diabetes, and then referred to two case-reports (relapsing pancreatitis—Sprague, 1947; haemochromatosis—Stawell, personal communication), in which the retinal changes of diabetes were observed.

### Clinical Findings

There is to date no record in the literature (apart from Lawrence's mention of Stawell's case), of fundus changes similar to those of diabetes mellitus occurring in patients with primary destruction of pancreatic tissue. Changes of this type have been observed (Fig. 1) in one patient (Case 2) of the present series. The

ocular findings in all five cases are described in detail below, and a summary of the appearances in individuals is given in Table I.

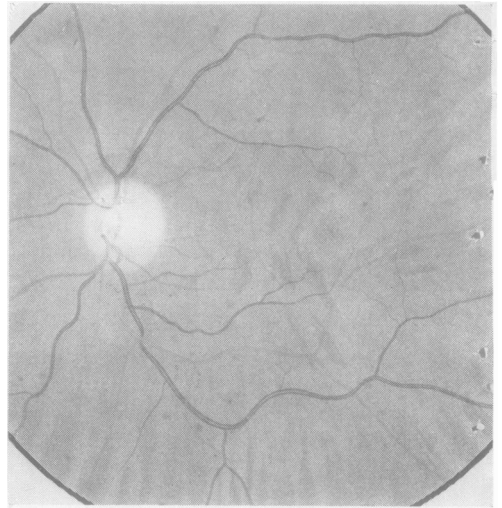

FIG. 1.—Left fundus of Case 2.

\* Received for publication November 11, 1952.

TABLE I  
OCULAR APPEARANCES IN FIVE CASES OF HAEMOCHROMATOSIS

Case No.	1	2	3	4	5	
Conjunctiva ...	Occasional fusiform aneurysms	Fusiform and "berry" aneurysms	Fusiform and "berry" aneurysms	Fusiform and "berry" aneurysms	Normal	
Cornea ...	Normal (arcus senilis)	Normal	Normal	Normal	Normal	
Iris ...	Brownish-green	Brownish - green	Brownish - green	Brownish - green Melanoma of left iris	Brownish - green	
Lens ...	Clear	Few vacuoles Relief of adult nucleus	Fine white dot opacities in nucleus, R<L	Clear	Few vacuoles in right lens	
Vitreous ...	Normal	Normal	Normal	Normal	Normal	
Fundus...	Normal	Early diabetic and arteriosclerotic changes (Figs 1 and 2).	Normal	Normal	Irregular reflex at right macula	
Visual Acuity	R	+ 2.50/-1.75 × 95°=6/5	- 2.00/+ 1.25 × 80°=6/5	+ 4.00/+ 0.75 × 165°=6/6	- 0.25/+ 0.75 × 95°=6/5	+ 0.50 =6/5
	L	+ 2.75/ - 1.35 × 85°=6/5	- 1.25/ - 1.25 × 95°=6/5	+ 3.75/+ 0.75 × 180°=6/6	- 1.00/+ 2.25 × 40°=6/6	+ 0.50/+ 0.50 × 110°=6/5

*Conjunctiva.*—The conjunctival vessels showed both fusiform and saccular aneurysmal dilatations in three cases, fusiform aneurysms in one, and no micro-aneurysms in the fifth. The changes were found particularly in the superficial vessels within about 5 mm. of the limbus (Fig. 2; see also Fig. 3 overleaf). The relationship between diabetes and the presence of aneurysms is given in Table II (below). Only two patients were suffering from diabetes mellitus.

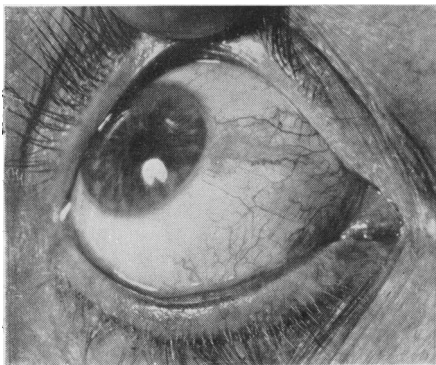


FIG. 2.—Conjunctival aneurysms in Case 4.

*Cornea.*—No characteristic changes seen.

*Iris.*—The irides in this group were all of a similar brownish-green colour, but no significance is attached to this. The microscopic appearances in one case are recorded below.

TABLE II  
RELATIONSHIP BETWEEN DIABETES AND MICRO-ANEURYSMS

Case No.	Age (yrs)	Duration of Illness (yrs)	Micro-aneurysms		Glucose Tolerance Curves
			Conjunctival	Retinal	
1	63	7	+	—	"Lag" type
2	50	15	++	+	Diabetic
3	50	2	++	—	"Lag" type
4	66	2	++	—	Diabetic
5	45	6	—	—	Normal

*Lens.*—The appearances varied in individual patients; the lens changes described in Table I are those which would be expected in a group of normal subjects of the same age.

*Vitreous.*—No characteristic changes were observed.

*Retina.*—In Case 2 (Fig. 1) the fundi showed changes consisting of a few micro-aneurysms of the "berry" type along the course of the main retinal vessels in the right eye between the disc and the equator, a few micro-aneurysms along the main vessels, and two small patches of retinal haemorrhage along the course of the inferior temporal artery in the left eye. The fundus ground around the disc appeared to be rather more deeply pigmented than in a normal subject, but this was not a gross change.

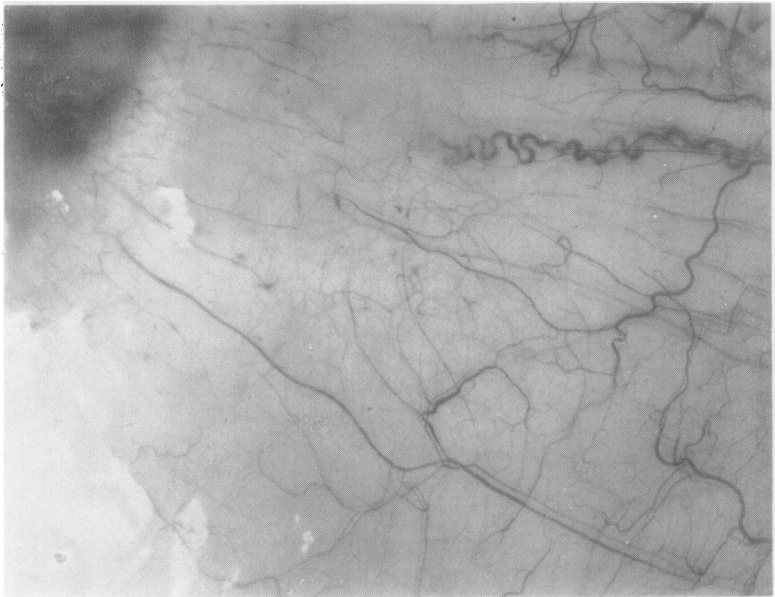


FIG. 3.—Conjunctival aneurysms in Case 4 (high-power magnification).

One patient (Case 4) was found on examination to have a melanoma of the left iris, and he subsequently attended Moorfields for further opinions as to the possible malignancy of the condition. As the majority of the opinions favoured a malignant aetiology, it was decided to perform a complete iridectomy, with a fairly wide margin of normal tissue around the tumour. From the point of view of the present paper, it is of interest that no free iron pigment was detected in any of the serial sections. The full pathological report on Case 4 states:

Sections show a highly cellular benign pigmented naevus of the iris. The lesion is surrounded on both sides with normal tissue and has, therefore, probably been completely removed. No free iron pigment was detected in any of the serial sections.

### Discussion

The presence of conjunctival aneurysms has been observed in four of the five cases, two being truly diabetic, and two showing a "lag" type of glucose

tolerance curve. With the possible exception of the case in which the fundus around the disc appeared unduly dark, no changes characteristic of haemochromatosis have been observed. The most obvious fundus changes were those which could be attributed to diabetes. The absence of free iron pigment in Case 4, in whom an iridectomy was performed for a suspected malignant melanoma, supports the view that free iron pigment is probably not deposited in uveal tissue. With one possible exception, the primary change referred to by Maddox (1933) has not been observed in any of the cases described. The exact pathology of the vascular lesions must remain a matter for discussion until pathological material has been examined.

The ocular changes in diabetes have been described several times, and attention has recently been drawn to the presence of retinal micro-aneurysms in "normal" eyes, and in many diseases other than diabetes (Ashton, 1951). The significance of the vascular changes observed clinically in one of the present series of cases of haemochromatosis is, therefore, a matter for speculation, and it is not possible to say more than that the fundus changes are *similar* to those found in diabetes.

McCulloch and Pashby (1950) have examined the conjunctival vessels in normal subjects, and in two groups of diabetic patients; one group with an associated diabetic retinopathy, and the other group without. They found conjunctival aneurysms in 55 per cent. of diabetic and 14 per cent. of non-diabetic patients, the aneurysms being of the "berry" type described by Ballantyne and Loewenstein (1943) in their observations on the vascular changes in the fundus. No comment is made on the glucose tolerance curves in the "non-diabetic" group. Ashton (1949) reported the *post-mortem* findings in 21 diabetics, and in these cases conjunctival aneurysms were not observed. Their absence in normal subjects is supported by the work of Dobree (1950), who describes the perilimbal vessels in the normal and congested eye, and does not mention the presence of aneurysmal dilatations of either of the types described by Ballantyne and Loewenstein. In view of the inconclusive evidence so far presented in the literature, it is proposed further to investigate the relationship between conjunctival micro-aneurysms and diabetic conditions, and the incidence of these vascular anomalies in normal subjects.

The observations recorded above give no indication of the occurrence of ocular changes characteristic of haemochromatosis. The appearances are similar to those found in diabetes, which occur in about three-quarters of patients with the condition.

### Summary

The ocular findings in five cases of haemochromatosis are reported. Conjunctival micro-aneurysms and fundus changes similar to those of early

diabetic retinopathy are recorded. No other ocular findings characteristic of haemochromatosis have been observed. The significance of the findings is discussed.

## REFERENCES

- ASHTON, N. (1949). *British Journal of Ophthalmology*, **33**, 407.  
——— (1951). *Ibid.*, **35**, 189.  
BALLANTYNE, A. J., and LOEWENSTEIN, A. (1943). *Trans. ophthal. Soc. U.K.*, **63**, 95.  
DOBREE, J. H. (1950). *British Journal of Ophthalmology*, **34**, 720.  
DUKE-ELDER, S. (1940). "Text-book of Ophthalmology," vol. 3, p. 2744. Kimpton, London.  
MADDOX, K. (1933). *British Journal of Ophthalmology*, **17**, 393.  
MCCULLOCH, C., and PASHBY, T. J. (1950). *Ibid.*, **34**, 495.  
LAWRENCE, R. D. (1949). *Lancet*, **2**, 401.  
SPRAGUE, R. G., (1947). *Proc. Mayo Clin.*, **22**, 553.