

CASE NOTES

THREE THERAPEUTIC LAMELLAR GRAFTS*

BY

H. E. HOBBS

London

INDICATIONS for lamellar corneal grafts are somewhat more numerous than those for penetrating keratoplasty, and Paufigue, Sourdille, and Offret (1948) mention, besides the usual optical reason for replacing a corneal scar, tectonic, preparatory, aesthetic, and therapeutic indications. This last, designed to interrupt the course of chronic and recurrent corneal disorders, is of peculiar interest, because, although it possibly provides the widest field of application of lamellar grafts, its rationale is less well understood. It is possibly for this reason that its employment depends even more on its proven successes than does keratoplasty performed on other indications. The idea of utilizing the trophic effects of a graft in this way is attributed to Filatov, in whose theory of "biogenic stimulants" it played but a small part, and it is perhaps because the success of other applications of this theory (*e.g.*, the use of subconjunctival injections of cod liver oil or implantations of placenta in the treatment of various forms of ocular disease) has not been as great as one had been led to expect that the therapeutic functions of the corneal graft have received less attention than might have been expected.

On the continent of Europe the therapeutic value of lamellar grafts was first demonstrated in France, notably by Paufigue (1947, 1948), and Paufigue and Bonnet (1948), and the largest series of reported cases (41) comes from his clinic (Hugonnier-Clayette, 1949). In Great Britain cases have been reported by Black (1949), Foster (1950), and Rycroft and Romanes (1952), and this effect of grafting was treated in some detail by Lister (1951) in his review of keratoplasty. The purpose of this paper is to add three more illustrative cases to those mentioned.

Case Reports

(1) A man aged 58 was first referred to me in December, 1950, because for rather more than a year he had had an irritable eye resistant to all forms of treatment elsewhere. Some 43 years previously bilateral congenital cataracts had been needled by Mr. J. H. Fisher at St. Thomas's Hospital, and after this the patient had enjoyed excellent vision until July, 1949, when he began to experience periodic irritation of the left eye with clouding of vision.

Examination.—Extensive corneal epithelial oedema of the left eye obscured any view of the fundus, but through it heterochromia of the iris could be seen. The possibility of this being due to glaucoma, either of the aphakic type, or resulting from late uveitis, was discarded in view of the absence of ocular hypertension or of inflammatory signs, and I accepted the condition as primarily corneal, a form of post-extraction corneal dystrophy.

* Paper delivered with demonstration of cases at the Royal Society of Medicine (Section of Ophthalmology) on June 11, 1953.

Therapy.—Since the usual medicaments had had no effect, I treated the eye with cortisone by sub-conjunctival injection and drops. At first there did appear to be some effect in that there were periods of diminished epithelial oedema and clearer vision, which tended to occur early in the day, and in February, 1951, when he came to my morning out-patients session, his corrected visual acuity, which had presented as finger-counting 2 months earlier, was 6/12. This improvement, however, did not last, and 6 months later cortisone was producing no effect. As time went on the irritative symptoms began to increase and early in 1952 he discussed with me the alternatives of retiring early on a disability pension, or having the eye removed.

Operation.—It seemed to me then that, although therapeutic grafts in oedematous corneal conditions are not universally successful (Hugonnier-Clayette, 1949), a graft ought to be given a trial in these circumstances. On March 29, 1952, therefore, I performed a 7-mm. lamellar graft.

Result.—His convalescence was uneventful so that within 3 weeks the eye was quiet, and since then it has remained so in spite of the fact that some epithelial oedema has reappeared during the last 6 months. Visual improvement was not primarily sought here and none has been obtained, and the prognosis must still be considered doubtful in view of the recurrent epithelial oedema; but I feel that, in the circumstances, keratoplasty has been justified, and I should not hesitate to repeat the operation if the irritation recurs.

(2) A man aged 62 was referred to me by Mr. Frederick Ridley in December, 1951, with an irritable eye resulting from a disciform keratitis of some 2 months' duration.

Therapy.—He showed some subjective improvement under local treatment with cortisone during the first 6 weeks; but it became apparent as the cornea cleared that there was an accompanying uveitis with firm posterior synechiae which tethered the pupil, and although treatment was continued over the next 9 months the eye still tended to be irritable unless drops were continuously used.

Operation.—In December, 1952, therefore, the question of a therapeutic lamellar graft was considered and on January 21, 1953, I performed a 7-mm. lamellar keratoplasty.

Result.—Convalescence from this was uneventful, and although deep corneal vessels rapidly reformed in the graft bed the graft itself remained clear in spite of the presence of some epithelial oedema, and the eye was quiet without treatment. Vision was not improved because of the lens opacity. The eye has so far remained quiet during the succeeding 5 months, although the vascularity and some epithelial oedema remain.

(3) A man aged 42 was referred to me for cortisone treatment by Mr. Eugene Wolff just 2 years ago with a history of deep keratitis of doubtful origin of 20 years' duration. Little useful vision had been present in the eye since the original attack, and it was subject to recurrent attacks of irritation in which the dense corneal nebula became vascularized. In May, 1951, the eye was suffering one of these relapses and exhibited a vascularized, densely opaque cornea.

Therapy.—Cortisone administered locally rapidly produced a quiet eye; but, somewhat to my surprise, the long-standing nebula began to clear and a month later the iris could be seen above. Continued treatment resulted in further clearing and slight visual improvement to finger counting; but this was the limit of his progress, and although the eye remained quiet on cortisone, one effect of which appeared to be to enable him to tolerate mydriatics, irritation recurred when it was withdrawn. The appearance of the eye in a quiet phase in August, 1951, is shown in Fig. 1 (opposite).

Operation.—In May, 1952, therefore, Mr. Wolff and I discussed the advisability of a therapeutic lamellar graft and this was performed, by him, on September 5.

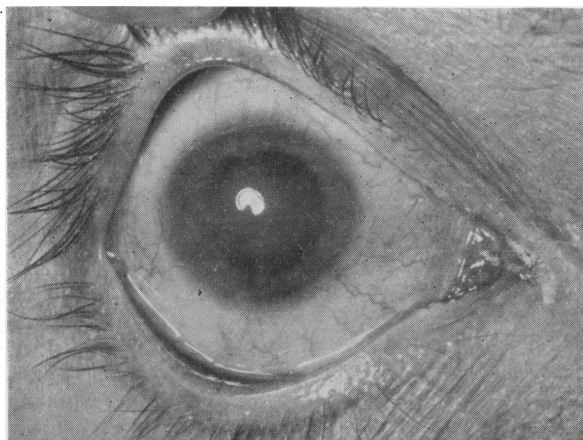


FIG. 1.—Case 3, appearance in August, 1951.

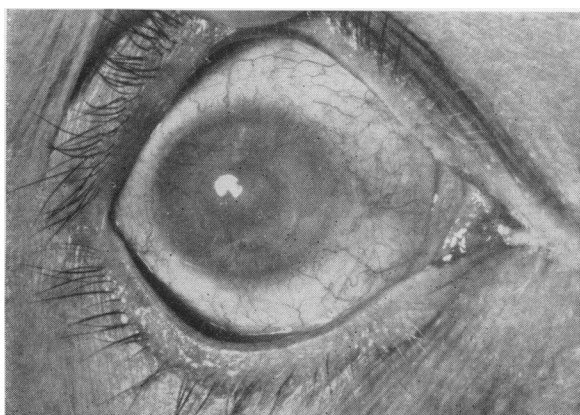


FIG. 2.—Case 3, appearance in June, 1953.

Result.—Convalescence was uneventful, and since this time increased clearing of the surrounding cornea has been seen, so that the condition, as it appeared in June, 1953 (Fig. 2), contrasts quite favourably with the original state. Here again, visual improvement was not a primary indication for the operation, but some degree of improvement has been obtained and he has recently been able to distinguish 6/60.

I am indebted especially to Professor L. Paufigue for his kindness and instruction during the period I spent in his clinics, and I should like to thank Mr. Eugene Wolff and Mr. Frederick Ridley for their permission to include their cases in this report. The photographs of the last case were made by the Department of Medical Illustration, Institute of Ophthalmology, London.

REFERENCES

- BLACK, G. (1949). *Trans. ophthalm. Soc. U.K.*, **69**, 91.
 FOSTER, J. (1950). *Ibid.*, **70**, 110.
 HUGONNIER-CLAYETTE, S. (1949). "Les greffes cornéennes lamellaires thérapeutiques". Audin, Lyons.
 LISTER, A. (1951). "Keratoplasty 1948-1951". Review in *Ophthalm. Lit. (Lond.)*, **5**, 67.
 PAUFIGUE, L. (1947). *J. soc. Ophthalm.* Special Number, pp. 11-13.
 ——— (1949). *Trans. Ophthalm. Soc. U.K.*, **69**, 67-69.
 ——— and BONNET, J. L. (1948). *Bull. Soc. Ophtal. Paris*, 672.
 ——— and PHILPS, S. (1950). *British Journal of Ophthalmology*, **34**, 746.
 ———, SOURDILLE, G. P., and OFFRET, G. (1948). "Les greffes de la cornée", Masson, Paris.
 RYCROFT, B. W., and ROMANES, G. (1952). *British Journal of Ophthalmology*, **36**, 337.