

PRIMARY TUMOURS OF THE OPTIC NERVE IN VON RECKLINGHAUSEN'S DISEASE*

BY

W. A. MANSCHOT

Rotterdam

THE ophthalmological symptoms of von Recklinghausen's syndrome are numerous. Multiple tumours of the superficial nerves may cause a plexiform neurofibromatosis, preferably situated in the superior eyelid and the region around the orbit. The intra-orbital and the ciliary nerves can also be affected. Defects in the bony orbital wall may cause a pulsating exophthalmos, and phakomata in the iris and congenital uveal ectropion may be present. Van der Hoeve (1932) was the first to describe tumours in the retina. An excellent study by Davis (1940) made it clear, however, that primary tumours of the optic nerve are probably the most important sign of von Recklinghausen's disease for the ophthalmologist. This view is also emphasized by the study of Bürki (1944) and the report of Offret (1951).

As the close relation between primary tumours of the optic nerve and von Recklinghausen's disease has not yet become generally known, it seems worthwhile to report the findings in two children of one family, both of whom showed the peripheral signs of von Recklinghausen's disease, and had a tumour in the optic nerve and the chiasm.

Case Reports

Case 1, a boy born on February 24, 1940, was seen for the first time in August, 1951. He was mentally defective and at that time it was not possible to determine the visual acuity. The right eye showed a myopic astigmatism of 2 dioptres; the left eye was emmetropic. The right eye showed a sursumvergent strabismus. The optic disc in both eyes was normal. The mother returned with the child in December, 1951, and stated that the function of the eyes had decreased during the last months. This time it was possible to determine the visual acuity, which was less than 1/10 in the right eye, and 4/10 in the left eye. The nerve head of the right eye was normal; the left eye showed a pale disc. No exophthalmos was present. It was supposed that the insufficient functioning of the right eye was to be considered as an amblyopia ex anopsia due to the myopic astigmatism, and that the visual acuity of the left eye had decreased by some pathological process in the left optic nerve. The boy was admitted to the municipal neurological hospital (B.G. Ziedses des Plantes).

Examination.—The following characteristics were noted:

- (1) Marked mental defect;

*Received for publication July 13, 1953.

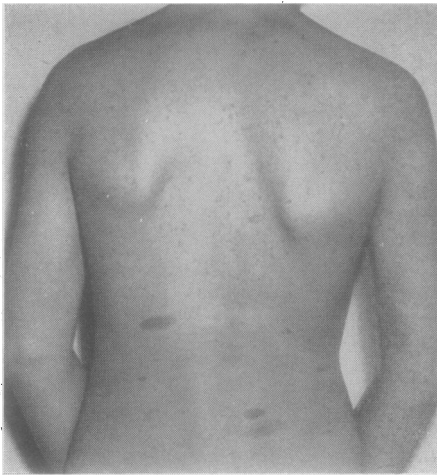


FIG. 1.—Case 1, *café-au-lait* pigmented patches.

(2) Many *café-au-lait* pigmented patches in the skin (Fig. 1); gooseflesh on the trunk and legs, and multiple pin-head fibromata on the right hip.

(3) Supra-symphyseal intra-abdominal tumour the size of a coconut;

(4) X rays showed no abnormal changes in the cranial bones, a minor enlargement of the right optic foramen (Fig. 2), and a marked enlargement of the left (Fig. 3). Ventriculograms could not be produced as it was impossible to fill the ventricles with air by the occipital route. The cerebral spinal fluid was normal. Laboratory examinations revealed no abnormalities.

(5) Ophthalmological examination during February, 1953, in the ophthalmic hospital (H. J. Flieringa), revealed that vitreous opacities had appeared in the right eye. The optic disc still showed a normal colour but a balloon-shaped retinal detachment had occurred in the temporal part of the fundus. Scattered retinal haemorrhages were visible on the detached retina and it seemed probable that a subretinal tumour had developed. The fundus of the left eye showed marked pallor of the disc with-

out other anomalies. The visual field was concentrically narrowed seriously in the right eye and slightly in the left. The electroretinogram was absent in the right eye and normal in the left eye.

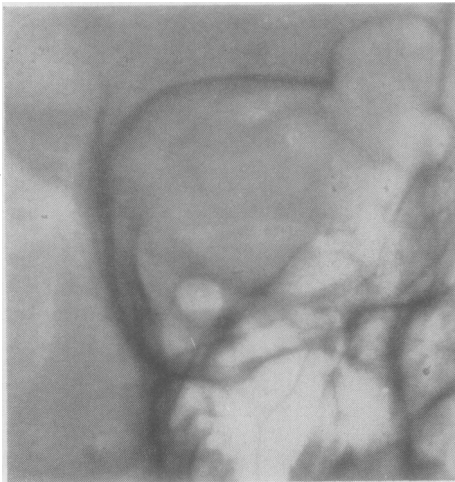

FIG. 2.—Case 1, minor enlargement of right optic foramen.

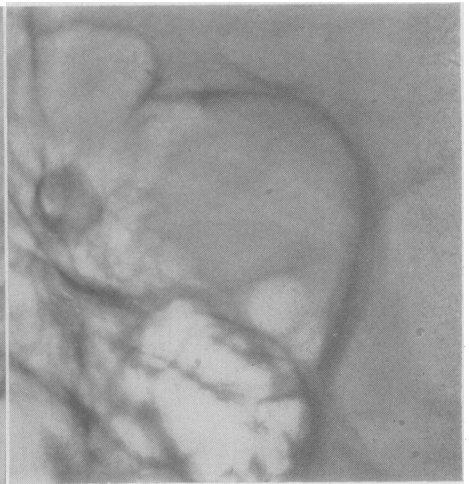


FIG. 3.—Case 1, marked enlargement of left optic foramen.

Operation.—On March 10, 1953, the left optic nerve and the chiasm were exposed by means of a left transfrontal craniotomy (M. P. A. M. De Grood) and a tumour of the left optic nerve and the chiasm was found. No specimen was removed for histological examination as the surgeon was convinced that a glioma of the left optic nerve and the chiasm was present.

Re-examination on July 3, 1953, revealed a slight papilloedema of the right eye. A large detachment of the retina with recent haemorrhages was visible in the lower temporal part of the fundus. It was clear that a growing subretinal tumour was present in this eye.

Case 2, sister of Case 1, born on February 15, 1945, who had been treated by another ophthalmologist since 1948, was first seen in October, 1950. A paralytic right abducens nerve was present; the right eye was amblyopic. The visual acuity of the left eye was 5/5. Both eyes were 3 dioptres hypermetropic. In December, 1951, the visual acuity of the

left eye was still 5/5. The mother came back with the girl in February, 1953, and said that after the Christmas holidays her teacher had complained that her writing had suddenly become very untidy. The visual acuity of the left eye had decreased to 1/10, but the fundus showed no abnormalities. The fundus of the right eye showed a pallor of the nervehead.

The girl was immediately sent to the same neurological hospital as her brother.

Examination.—The following characteristics were noted:

- (1) No mental defect;
- (2) Large *café-au-lait* pigmented patches on the trunk (Fig. 4). Cutaneous fibromata not present;
- (3) X rays of the skull showed no anomalies; the optic foramina were of a somewhat triangular shape but were not enlarged. All the ventricles appeared too narrow, and the inferior anterior part of the third ventricle was not sufficiently filled with air. The tension of the cerebrospinal fluid was normal; it contained 9 lymphocytes in 3 cu. mm. and 0.091 per cent. albumen. The reactions of Nonne and Pandy were both positive; the colloid reactions were about normal.

Operation.—On March 18, 1953, the optic nerves and chiasm were exposed by a right transfrontal craniotomy (M. P. A. M. De Grood). The right optic nerve was white and thin, and emerged half a centimetre behind the optic foramen into a greyish-coloured tumour that could not be separated from the nerve. The chiasm was covered by the same grey tissue. The left optic nerve was also white and thin. A small piece of the tumour was excised for histological examination; a glioma of the right optic nerve and the chiasm was present (M. Straub).

Re-examination on July 3, 1953, revealed that the visual acuity of both eyes was about 1/60. The nervehead of the right eye was atrophic; the left optic disc showed slight temporal pallor.

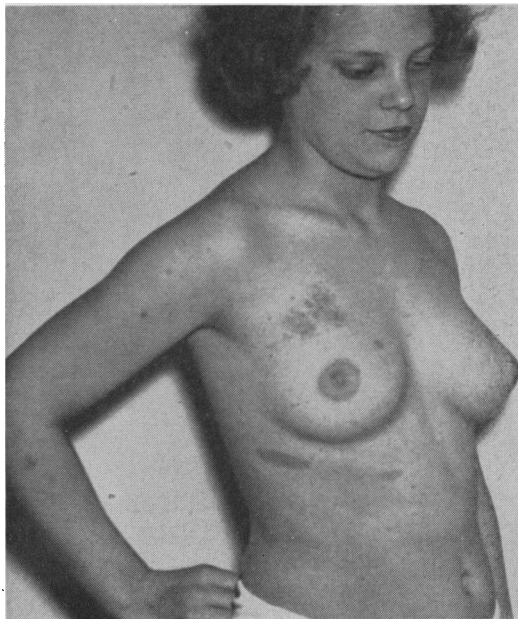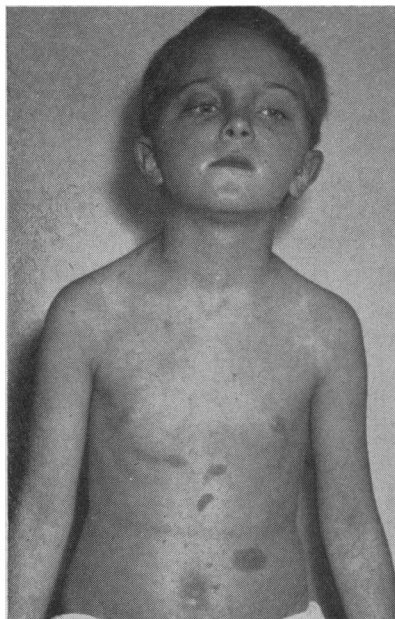


FIG. 4.—Case 2, younger sister of Case 1, *café-au-lait* pigmented patches.

FIG. 5.—Twin-sister of Case 1, *café-au-lait* pigmented patches on trunk.

The family history showed that Case 1 was one of a pair of twins; his twin sister also showed serious mental deficiency, and numerous *café-au-lait* pigmented patches were visible on the trunk (Fig. 5). Her right eye was amblyopic with a myopia of 20 dioptres. The visual acuity of the left eye was 5/5; this eye was half a dioptré hypermetropic. Both the nerveheads appeared normal, and no anomalies were seen in the fundus except for a myopic atrophy in the right eye.

There were no other children. The father showed no signs of von Recklinghausen's disease, but the mother had many cutaneous fibromata and *café-au-lait*

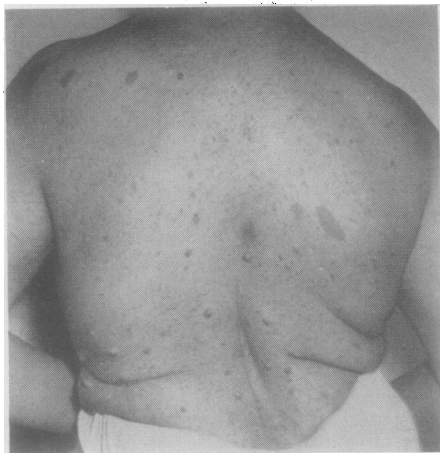

FIG. 6.—Mother of the three children, *café-au-lait* pigmented patches and cutaneous fibromata.

pigmented patches all over the whole body (Fig. 6). Both her eyes were normal.

Comment

It is not our purpose to discuss in detail the histology of the primary tumours of the optic nerve in von Recklinghausen's disease. Comprehensive studies have been made by Davis (1940), Bürki (1944), and Offret (1951). In the older literature the terminology is confused: glioma, gliosarcoma, fibroma, fibrosarcoma, neuroma, endothelioma, meningioma, fibromatosis, sarcoma, myxosarcoma, and so on, but Verhoeff (1922), Lundberg (1935), and Davis (1940) have classified them as:

- (1) Tumours of the nerve: *gliomata*,
- (2) Tumours of the sheaths: *meningiomata* or *endotheliomata*.

In addition to these two types some cases form a third category designated by Hudson (1912) as *fibromatosis*. Posner and Horrax (1948) were the last to publish such a case. Bürki may be right when he uses the names: *tumour-like fibrogliomatosis* and *neurofibrogliomatosis*, but he may cause fresh confusion in the nomenclature of tumours of the optic nerve.

Most of such tumours, especially in children, originate within the nerves, and are gliomata. A totally different structure is seen in a few tumours in older people, which have the characteristics of endotheliomata or meningiomata. Classification by age of patient is rather risky, as Saebø (1949) described a glioma in a patient aged 43 years, and François and Rabaey (1952) described a meningioma in a 5-year-old child.

Davis was the first to stress the close relation between primary tumours of the optic nerve and von Recklinghausen's disease. He found 24 anatomically studied cases in the literature; twenty gliomata and four endotheliomata; his own five cases were also gliomata. Bürki afterwards published two other cases of gliomata of the optic nerve in von Recklinghausen's disease which were studied anatomically. Our two cases, diagnosed during operation, make a total of 29 gliomata against four endotheliomata.

Bürki found that 12.3 per cent. of 430 cases of tumour of the optic nerve showed a general neurofibromatosis, but this percentage has risen to 37.6 per cent. in 93 cases since 1933. Many cases of von Recklinghausen's disease still remain unnoticed as the ophthalmologist's attention is fixed on the ocular lesion and he often overlooks the associated changes in the other parts of the body, as in the five cases of Davis, both patients of Bürki, and our own two patients. The mild general manifestations of von Recklinghausen's disease,

especially the *café-au-lait* pigmented patches on the skin, are so important for the recognition of the true nature of the eye disease, that ophthalmologists should carefully examine every child with unilateral amblyopia for these patches. One may conclude with Bürki that a tumour of the optic nerve is often a phenomenon of von Recklinghausen's disease, and that a solitary tumour of the optic nerve may be the first or only symptom of it.

Gliomata of the chiasm also often are found in von Recklinghausen's disease. Cushing (1930) found symptoms of this disease in six of eighteen patients with the chiasmal syndrome of primary optic atrophy and bilateral field defects in adults with normal sella turcica.

The youth of most patients with a glioma of the optic nerve indicates that the lesion may be congenital in origin. Reese (1951) stated that 60–75 per cent. of all tumours of the optic nerves are encountered in children in the first ten years of life. Davis reported that nineteen of 36 patients with a primary tumour of the optic nerve in von Recklinghausen's disease were under 13 years of age.

This disease has a marked hereditary tendency, and many familial and hereditary histories are given in the literature (Waardenburg, 1932), but familial cases of primary tumour of the optic nerve in this disease are rare. Two of the patients reported by Davis were brother and sister, and Holmström (1928) described two sisters, aged 4 and 5 years, who both showed exophthalmos, reduced visual acuity, and a markedly enlarged optic foramen of the right eye. Cases 1 and 2 above are the third pair of siblings with a primary tumour of the optic nerve in von Recklinghausen's disease.

Summary

Clinical reports are given of two children of one family both with a glioma of the optic nerve and the chiasm. Both the children, the twin of one of them, and their mother, showed generalized symptoms of von Recklinghausen's disease. Tumours of the optic nerve and the chiasm are relatively frequent in von Recklinghausen's disease; most of the tumours are gliomata and some are endótheliomata.

REFERENCES

- BÜRKI, E. (1944). "Über den primären Sehnerventumor und seine Beziehungen zur Recklinghausenschen Neurofibromatose". *Bibl. ophthal. (Basel)*, **30**.
 CUSHING, H. W. (1930). *Arch. Ophthal. (Chicago)*, **3**, 505 and 704.
 DAVIS, F. A. (1940). *Ibid.*, **23**, 735 and 957.
 FRANÇOIS, J., and RABAËY, M. (1952). *Acta ophthal. (Kbh.)*, **30**, 203.
 VAN DER HOEVE, J. (1932). *Trans. ophthal. Soc. U.K.*, **52**, 380.
 HOLMSTRÖM, M. (1928). *Acta ophthal. (Kbh.)*, **6**, 403.
 HUDSON, A. C. (1912). *Roy. Lond. ophthal. Hosp. Rep.*, **18**, 317.
 LUNDBERG, A. (1935). "Über die primären Tumoren des Sehnerven und der Sehnervenkreuzung". *Diss. Karol. Inst. (Stockholm)*.
 OFFRET, G. (1951). "Les tumeurs primitives de l'orbite". Masson, Paris.
 POSNER, M., and HERRAX, G. (1948). *Arch. Ophthal. (Chicago)*, **40**, 56.
 REESE, A. B. (1951). "Tumors of the eye". Hoeber, New York.
 SÆBØ, J. (1949). *British Journal of Ophthalmology*, **33**, 701.
 VERHOEFF, F. H. (1922). *Arch. Ophthal. (Chicago)*, **51**, 120.
 WAARDENBURG, P. J. (1932). "Das menschliche Auge und seine Erbanlagen". Nijhoff, The Hague.