

# **INTRA-OCULAR FOREIGN BODIES\***

## **REPORT OF 102 CASES**

BY

**KAZIMIERZ RUBINSTEIN**

*From the Ophthalmic Department, Royal Hospital, Sheffield*

THERE is no universally accepted "best" method of treating an intra-ocular foreign body apart from its extraction from the globe. The controversial points may be summed up as:

- (a) anterior or posterior route of extraction,
- (b) diathermy of scleral field or simple incision,
- (c) Haab or Mellinger type of giant magnet.

An intra-ocular foreign body is a surgical emergency and it is important to keep operative procedures simple and not above the heads of junior hospital staff; but ultimately the methods proposed must be judged by their results, visual as well as economic. This type of case is not frequently encountered and it is difficult to draw conclusions from the material of one particular clinic, especially as only one approach is usually followed as a routine for a number of years.

### **Material of Present Study**

The purpose of this paper is to make available the material from this department for comparative studies. In the years 1944-1953, 102 consecutive cases (99 male and 3 female) occurred amongst 4,500 in-patients. The criterion for inclusion here was that the foreign body should have penetrated into the eye. Foreign bodies embedded in the cornea or sclera were excluded, and cases of eyes hopelessly lacerated were included only if a foreign body was lodged inside the globe. The liberal use of antibiotics is a new feature of treatment. I assisted at or operated on seventy of these cases myself, the rest being operated by the consultants and other assistants.

### **Previous Reports**

The second world war brought several papers on the management of intra-ocular foreign bodies, in which surgeons summarized their war experience (*e.g.*, Kraus and Briggs, 1945; Skeoch, 1945; Lodge, 1945). The only statistical material is contained in two papers by Stallard (1944, 1947) and one by Somerset and Sen (1948). These cases were treated in field conditions, and few of Stallard's 174 cases from the Middle East Forces and British Land Forces in Asia, or Somerset and Sen's 29 cases from Burma were followed up. The report by Trevor-Roper (1944) from Moorfields gives a well-documented survey of late results in 154 cases

---

\*Received for publication July 14, 1953.

of successful extractions. Of these, 150 were extracted by the anterior route and Haab's magnet was used in 147 cases. The series here under survey differs in that the posterior approach was the routine and the Mellinger magnet was used throughout.

### Surgical Procedure

The principle was accepted that all foreign bodies localized in the anterior chamber or lens should be extracted by the anterior route (by paracentesis or *via* the original corneal wound), and that those in the vitreous should be extracted by the posterior route, unless the scleral or limbal wound of entry was large and needed attention.

No attempt was made to incise the globe over the foreign body in acute cases. The quadrant of the globe was selected according to the localizing x-ray chart, so as to get as near to it as possible with an approach through the region of the pars plana behind the ciliary body, the ora serrata region being invaded only in cases of extreme posterior localization. Diathermy was not used.

### Statistical Particulars

**Age.**—This ranged from 10–70 years with the peak between 25 and 40 years (Fig. 1).

**Sex.**—Of the 102 cases, 99 were male and three female.

**Occupation.**—This is set out in Table I.

**Work at Time of Accident.**—This is set out in Table II.

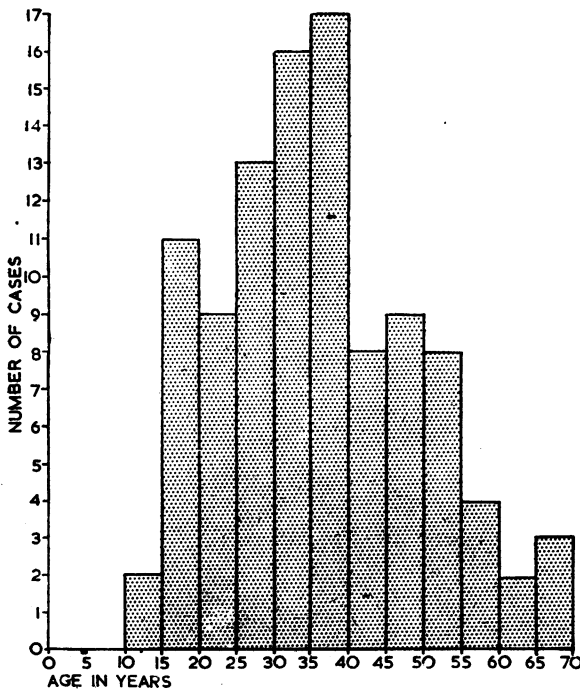


FIG. 1.—Age of patients.

TABLE I  
OCCUPATION OF PATIENTS

Steel works ... ..	32
Mining auxiliaries ... ..	23
Engineering ... ..	21
Building trade ... ..	7
Mining ... ..	4
Railways ... ..	4
Unskilled labour ... ..	3
Other ... ..	5

TABLE II  
WORK AT TIME OF ACCIDENT

Hammer and chisel }*	45
(or wedge) }	
Hammer on metal }	27
Turning ... ..	6
Cutting steel ... ..	4
Picking ... ..	3
Off machine grip ... ..	3
Off mechanical press ... ..	2
Hammer and wire ... ..	3
Car accident ... ..	1
Drilling ... ..	2
Hammer and stone ... ..	2
Bolt against bolt ... ..	1
Steel bearing and stone ... ..	1
Broken tool ... ..	1
Chopping sticks ... ..	1

\*In fifteen of these cases the foreign body came from another worker's tools or material.

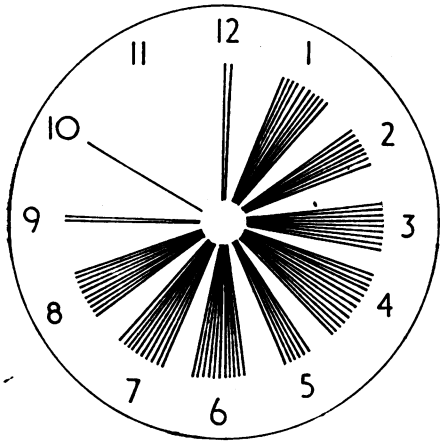


FIG. 2.—Incidence during working hours (hour of shift). Each ray represents one case.

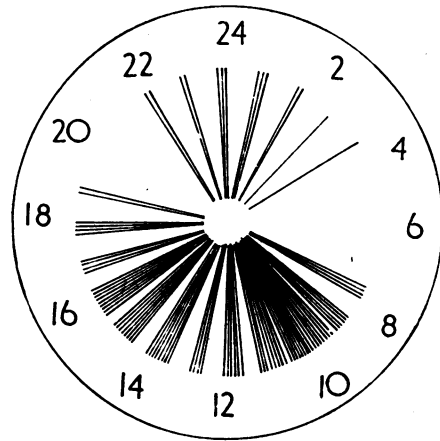


FIG. 3.—Time of incidence (hour of day). Each ray represents one case.

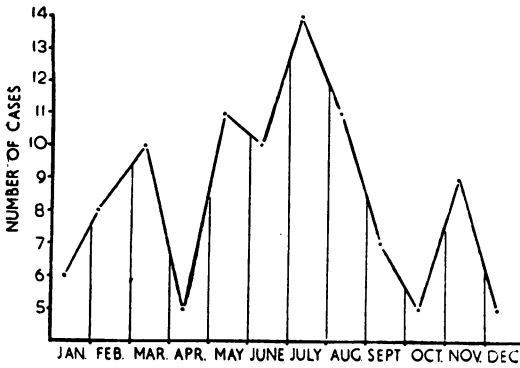


FIG. 4.—Average seasonal incidence (1944-53).

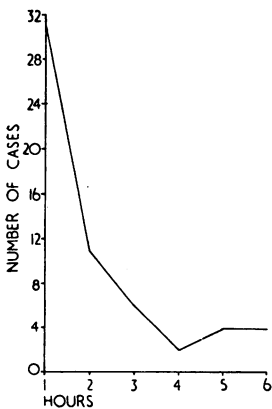


FIG. 5.—Delay in hospital attendance, first 6 hrs analysed.

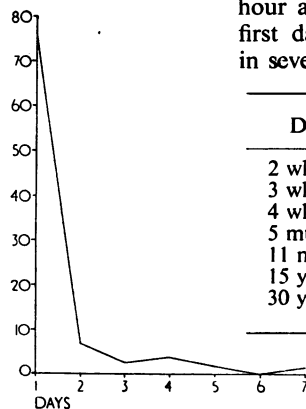


FIG. 6.—Delay in hospital attendance, first week analysed.

**Time of Accident (Figs 2, 3, 4).—**The distribution seems even throughout the working hours. The element of fatigue or poor illumination does not seem to influence the frequency of accidents, but the seasonal distribution shows the odd fact that the highest incidence of this sort of injury is in the summer months.

**Side Involved.—**Right eye 63 cases; left eye 40 cases; bilateral (5 years interval) one case. In both series of Stallard (1944, 1947) the right eye was involved more frequently.

**Delay in Hospital Attendance.—**(Figs 5, 6).—31 cases attended within the first hour after accident, and 77 within the first day. Long delays had occurred in seven cases as follows:

Delay	Visual Result
2 wks	Hand movements
3 wks	6/6
4 wks	6/4
5 mths	6/12
11 mths	Enucleation
15 yrs	6/18
30 yrs	6/6

In nine cases the diagnosis had been missed at the first visit to the Casualty Department of a peripheral hospital (Table III, overleaf).

TABLE III

Case No.	Delay	Visual Result
22	4 days	Enucleation
60	12 hrs	Enucleation
61	4 days	Perception of light—Siderosis
64	2 days	6/6
65	3 days	Enucleation
71	18 hrs	Enucleation
80	3 wks	6/6
91	3 days	6/6
97	4 wks	6/4

**Type of Foreign Body.**—In 95 cases the foreign body was steel, one eye containing two pieces; the remaining seven cases are set out in Table IV.

**Route of Entry.**—This is summarized in Fig. 7 (opposite).

**Localization.**—This is summarized in Fig. 8 (opposite).

TABLE IV  
TYPES OF FOREIGN BODY OTHER THAN STEEL

Case No.	Material	Examination	Treatment and Complications	Visual Result	Future Plans
3	? Zinc	Corneal entry Localization in vitreous	Posterior route extraction unsuccessful Cataract to be extracted soon	Hand movements Eye quiet with good tension until present time (3 yrs)	Extraction of lens
50	Glass from shattered windscreen	Bad corneal-scleral entry wound $\frac{1}{2}$ " long Uveitis Phthisis bulbi	Enucleation	—	—
59	Brass	Foreign body thought to be steel	Anterior route extraction unsuccessful Enucleation	—	—
63	Coal	Corneal entry Localization in anterior chamber	Attendance delayed 2 days Extraction by paracentesis 5 months later	6/5	—
65	Stone	Limbal entry	Attendance delayed 3 days owing to misdiagnosis in peripheral hospital casualty dept. Infection Cataract Enucleation	—	—
79	Manganese steel	Corneal entry Localization in vitreous	Attendance delayed 4 days Extracted by posterior route Cataract unoperated	Hand movements	—
82	Glass from broken spectacles	Corneal entry Localization in lens	Cataract extracted	6/4	—

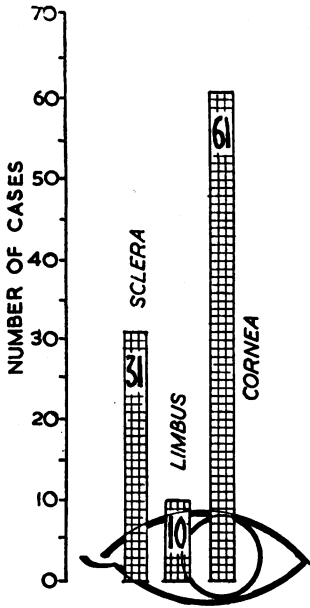


FIG. 7.—Route of entry.

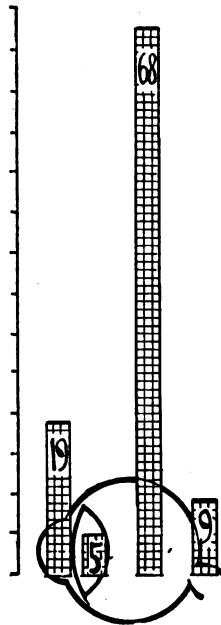


FIG. 8.—X ray localization.

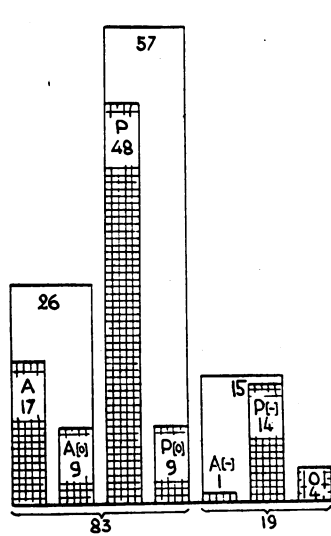


FIG. 9.—Route of extraction.

**Route of Extraction (Fig. 9).**—The analysis of nineteen foreign bodies not extracted is as follows:

A—anterior route extraction  
 A[o]—anterior route extraction through original wound  
 A[-]—anterior route—failure  
 P—posterior route extraction  
 P[o]—posterior route extraction through original wound  
 P[-]—posterior route—failure  
 O—no attempt at extraction

*No Attempt at Extraction (four cases)*

- Case 25. Through and through. Enucleation.
- Case 46. Through and through. Enucleation.
- Case 50. Glass, bad wound of entry. Enucleation.
- Case 44. 30-year-old foreign body, eye quiet. Cataract extracted, after which visual acuity was 6/6 with correction. The patient has binocular vision with contact lens.

*Failures by the Posterior Route (fourteen cases)*

- Case 3. ? Zinc. Eye quiet for past 3 years. Cataract to be extracted soon.
- Case 5. 1 month's delay in attendance. Localized in posterior sclera. Cataract. ? Perception of light (soft eye).
- Case 8. Through and through. Localization at first false and then behind the globe. Partial cataract. Retina detached round original wound. Visual acuity 6/18.
- Case 9. 11 months' delay in attendance. Enucleation.
- Case 12. 7 days' delay in attendance. Cataract extracted after 2 years. Visual acuity 6/9 with correction.
- Case 30. 15 years' delay in attendance. Cataract extracted. Visual acuity 6/18 with correction.
- Case 39. Localization in posterior sclera. Visual acuity 6/12.
- Case 40. Very small foreign body (1 × 2 mm.) in a clot of blood in vitreous. Enucleation.
- Case 45. Localization in optic nerve head. Gliosis from optic papilla (retinitis proliferans). Visual acuity hand movements.
- Case 87. Through and through. Localization at first false. Visual acuity 6/18 (amblyopia).
- Case 91. ?Foreign body between ciliary body and sclera. Visual acuity 6/6.
- Case 95. 3 days' delay in attendance. Localization in optic papilla. Vitreous haze. Visual acuity perception of light.
- Case 97. 4 weeks' delay in attendance. Area of circumscribed scarring in posterior fundus since 1944. Visual acuity 6/4.

Case 98. Localization in optic papilla. Uveal irritation. Enucleation.

*Failure by the Anterior Route (one case)*

Case 59. Brass. Uveitis followed by enucleation.

One point in this analysis is of special interest, namely that in six cases (12, 30, 39, 87, 91, 97) there is excellent visual acuity after an operation by the posterior route in spite of prolonged and—before giving up—intra-ocular search for foreign body. There is no detached retina in any of these. Case 91, in which I operated little more than a year ago, had an area of shallow detachment round the scleral incision after the operation (this involved introducing a magnet point into the vitreous after 1 hour of unsuccessful attempts). The detachment became reattached after a few weeks with some pigment scattering, and the eye settled down with a full visual field and acuity 6/6.

The fundus in Case 8 (accident in 1944) shows a localized detachment round the original (through) wound of the posterior pole, but none at the operative wound which is clearly seen behind the ora serrata.

A few other examples in this series show that a retinal detachment which may occur after the posterior route approach is only very exceptionally caused by the scleral incision.

**Complications.**—These are set out in Table V.

TABLE V  
ANALYSIS OF COMPLICATIONS

	Complications	No. of Cases	Eyes Enucleated
Immediate	Vitreous haemorrhage	37	
	Hyphaema	8	
	Uveal prolapse	8	
	Hypopyon	4	
	Retinal detachment	2	
	Cataract	46	
Late	Uveitis*	23	15
	Infection (pyogenic)	12	10
	Retinal detachment	7	—
	Phthisis bulbi	7	2
	Retinitis proliferans	4	—
	Vitreous opacities	5	—
	Sympathetic ophthalmia	1	1
	Siderosis	1	—

\*Under this heading are grouped cases in which the eye remained red, irritable, and with keratic precipitates for more than 3 weeks after the accident.

### Results

**Visual Acuity** (Fig. 10, opposite).—The cases in this series can be divided into two distinct groups:

- (1) those which did well (6/4–6/12 vision);
- (2) those which did not retain economically useful vision (hand movements, perception of light).

There are hardly any intermediate stages. The eye apparently either survives this kind of injury—and surgery—and returns more or less to normal or it is irreparably damaged.

The anterior route extractions in this series show much better visual results; the reason is obviously not the choice of surgical procedure but the fact of the anterior location of the foreign body. All but three cases in the group showing hand movements or less, had posterior route extractions,

but one must not forget that they also had choroidal wounds, vitreous haemorrhage, vitreous infection, etc.

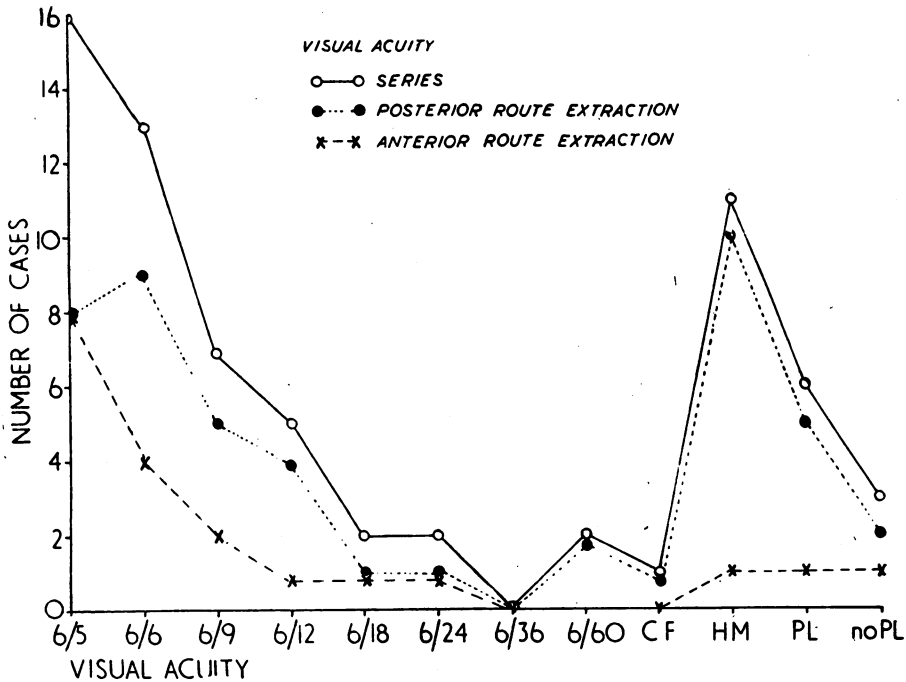


FIG. 10.—Visual results (enucleations and five cases that could not be traced are not included).

**Hospitalization** (Fig. 11).—No patient spent more than 8 weeks in hospital; the majority stayed less than 3 weeks. All patients with posterior route extractions were kept flat in bed for the first few days, and were only allowed to get up after 1 week if the fundus was visible and the retina flat.

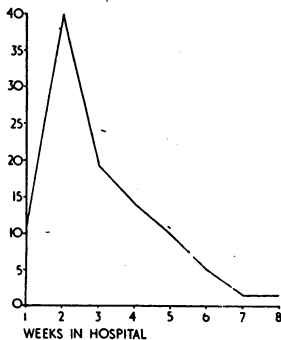


FIG. 11.—Hospitalization.

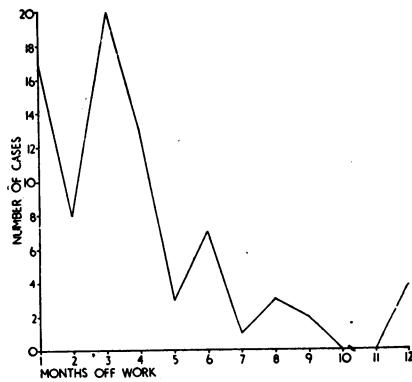


FIG. 12.—Time off work after accident.

**Time off Work** (Fig. 12).—20 per cent. of the patients were back at work within 4 weeks, 54 per cent. within 3 months, and 68 per cent. within 6 months.

The rest were off work longer, up to 1–2 years, and a few cases (mostly old people, or married women) retired entirely after the accident.

**Loss of Wages** (Fig. 13).—There is no appreciable drop in the money earning capacity amongst these patients. The shift to the right of “after accident” curve is caused by the general increase in wages, and normal progress of workers from less skilled to more skilled jobs. One would however expect this shift to be more pronounced in a normal sample of working people in this area. The fact is that twenty cases of the series earn less since the accident. Amongst them ten eyes were enucleated, five did not retain useful vision, and five see 6/9 or better. The common feature is a long convalescence before resuming work, irrespective of visual result.

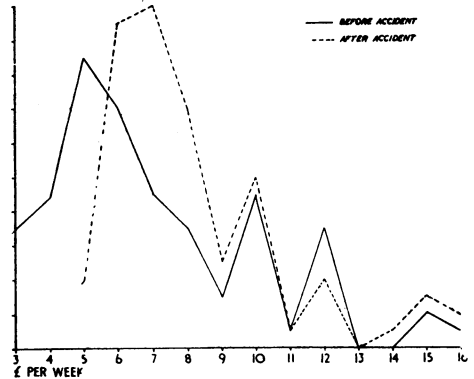


FIG. 13.—Earning capacity of patients. (No information was available in fourteen cases, and “retired” cases are not included).

The common feature is a long convalescence before resuming work, irrespective of visual result.

### Summary

A series of 102 consecutive cases of intra-coular foreign body is analysed. They were all treated according to the same surgical principles. This material is considered too small to draw firm conclusions as to the comparative value of the methods used, but is published so that it may be compared with material from other centres. Certain clinical impressions however seem not out of place:

(a) Exact x-ray localization and “over the F.B.” approach with the magnet is not essential. An incision over the ora serrata seems to be less traumatizing and equally efficient.

(b) Retinal detachment is not a bogey of the posterior route approach. It occurred only in 7 per cent. of cases (two of which were observed pre-operatively, and a few others in whom it did not start at the site of surgical approach). It is the original trauma to the retina and organization of the vitreous body which cause these detachments.

(c) Established vitreous infection is not controlled by antibiotics; ten eyes out of twelve so affected had to be enucleated. Antibiotics seem however to have a prophylactic value in this respect. Fifteen eyes had to be enucleated because of uveal irritation persisting for over 3 weeks and fear of sympathetic ophthalmia.

(d) A quiet eye with a retained metallic foreign body must be kept under observation but can be left *in situ*. In a few cases they remained trouble-free for years with good vision. I believe that these foreign bodies are usually embedded in the sclera and become encapsulated.



(e) Intra-ocular foreign bodies are almost always due to accidents. Hammering is the most frequent cause (76 per cent.). The factors of fatigue and poor illumination do not seem to influence their frequency. 15 per cent. of the cases in this series originated from other people working in the vicinity. For the unexpected seasonal variation (peak in the summer months) I can offer no explanation.

(f) The incapacitating effect of this type of injury does not seem to depend so much on the degree of retained vision as on the degree of psychological trauma to the subject.

All these cases were admitted under the care of Mr. E. G. Mackie and Miss E. Hatherley, to whom I am indebted for permission to report them in this paper.

#### REFERENCES

- KRAUS, J., and BRIGGS, A. W. (1945). *British Journal of Ophthalmology*, **29**, 557.  
LODGE, W. O. (1945). *Ibid.*, **29**, 205.  
SKEOCH, H. H. (1945). *Ibid.*, **29**, 113.  
SOMERSET, E. J., and SEN, K. (1948). *Ibid.*, **32**, 13.  
STALLARD, H. B. (1944). *Ibid.*, **28**, 105.  
——— (1947). *Ibid.*, **31**, 12.  
TREVOR-ROPER, P. D. (1944). *Ibid.*, **28**, 361.