

VASCULARIZATION OF THE OPTIC PATHWAY*

I. LAMINA CRIBROSA AND OPTIC NERVE

BY

J. FRANÇOIS AND A. NEETENS

From the Ophthalmological Clinic, University of Ghent, Belgium

THIS problem has been of only moderate interest to research workers, and publications and monographs on the subject have been sporadic, though a few well-known names must be cited here (Leber, 1865a, b, 1872, 1903; Magitot, 1908, 1947; Behr, 1935; Wolff, 1939, 1940, 1948). The findings being very diverse, it seemed appropriate to try to find experimentally the normal vascular anatomy of the optic pathway, especially because alterations in the vessels play a preponderant role in the visual system.

The finer details of the circulation are practically unknown, less and less data being available as we approach the capillary stage. The capillaries are definitely nutritive, being responsible for metabolism in normal physiological conditions, and even in certain pathological processes.

Embryology and comparative anatomy have been hitherto neglected in the explanation of the experimental results, but the chronology of the embryological processes is very important in providing objective proofs of anatomical conceptions.

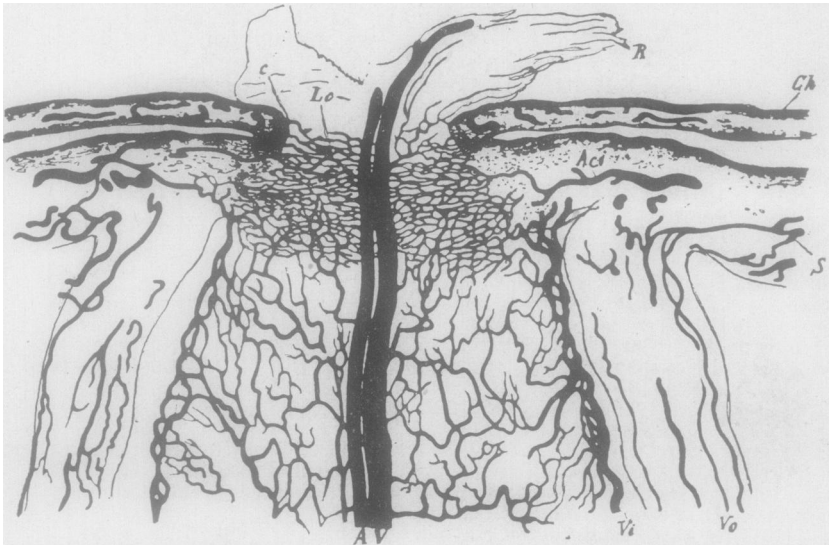


FIG. 1.—Vascularization of optic nerve and lamina cribrosa, according to Leber (1903).

S sclera	A central retinal artery
Ch choroid	Lc lamina cribrosa
R retina	Aci short posterior ciliary artery which sends
Ve vessels of dura	a branch to the optic nerve
Vi vessels of pia	C anastomoses between choroid and optic nerve

*Received for publication December 12, 1953.

Historical Survey

The first investigation of the vascularization of the optic nerve and the eye was performed by Zinn (1755) and Haller (1754). To them is credited the description of numerous branches arising from the short posterior ciliary arteries to build up in the sclera, surrounding the optic nerve, an anastomotic network, resulting in a closed circle: the scleral capillaries which, according to Zinn and Haller, form anastomoses with the capillaries of the anterior part of the optic nerve and with branches from the central artery of the retina. Tiedemann (1824) and Huschke (1844) later described them again. Jaeger (1861) fixed attention on this specialized vascular system, which takes an important part in pathological changes at the level of the optic nerve and its surroundings, emphasizing that the system is not closed at all, branches being given off to the choroid, the retina, and the optic nerve.

The optic nerve was considered by Zinn and Haller to be supplied by the central retinal artery alone.

The ideas put forward by Leber (1865, 1872, 1903), concerning the vessels of the eye and the optic nerve are still of interest (Figs 1 and 2).

The short posterior ciliary arteries, dividing into fine branches, feed the choroid. At the surface of the sclera, they give off branches, resulting in a network with wide meshes, which form ramifications, nourish the posterior sclera, and, after reaching the pia mater, penetrate into the optic nerve. The smallest of these anastomose in the sclera and, at the level of the optic nerve, build up several concentric arcs connected by radial branches, which proceed in a network of irregular meshes

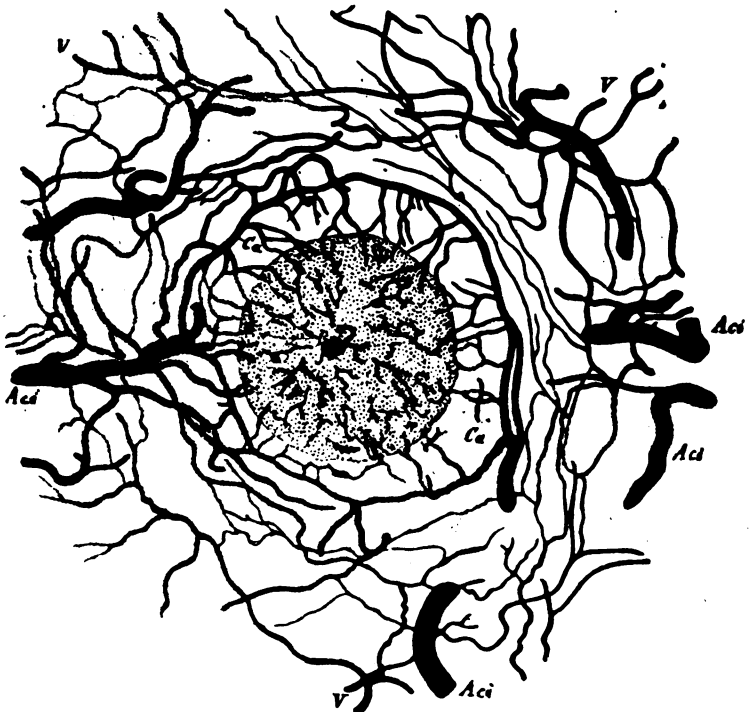

FIG. 2.—Arterial circle of Zinn-Haller, according to Leber (1903).

- | | | | |
|-----|----------------------------------|---|------------------------|
| Aci | short posterior ciliary arteries | a | central retinal artery |
| V | short posterior ciliary veins | v | central retinal vein |
| Ca | Zinn-Haller's arterial circle | | |

placed perpendicularly to one another: the arterial circle of Zinn. As it extends forwards, this network diminishes. The arterial circle sends branches to the optic nerve, choroid, and retina, and the most developed of these becomes the ciliary retinal arteries. From the choroid, numerous branches arise to supply the optic nerve and the lamina cribrosa, *via* the pia mater. The lamina cribrosa is also supplied by ramifications of the central retinal artery, anastomosing with the circle of Zinn.

The optic nerve is nourished by the central retinal artery; the portion posterior to its point of entry being supplied by branches arising from the pia mater. It also gives rise to a branch, which divides in two: one running up anteriorly and the other in the direction of the optic foramen, both being situated in the axis of the optic nerve (Vossius, 1883).

The intracranial part of the nerve is supplied by the ophthalmic artery and the corpus callosum artery, and the orbital part by the ophthalmic artery alone.

Elschnig (1893) inclined to the view that there are no anastomoses between the central retinal artery and the circle of Zinn.

According to Leber (1865a, b), the optic nervehead is dependent upon the central retinal artery; this is contrary to the opinion of Galezowski (1865) who put forward the view that the vessels of the papilla of the optic nerve derived from the pia mater and were of cerebral origin. Again, according to Leber, the circle of Zinn plays the role of the dura and pia mater vessels of the optic nerve (cf. Hyrtl, 1839: the vaginal artery, and the interstitial artery respectively), and in this way the circle of Zinn is a continuation of the sheaths of the optic nerve. Leber denied the existence of anastomoses between the vessels of the pia mater and those of the central retinal artery behind the lamina cribrosa.

Wolfring (1872) defended the idea that in the pia mater branches extended forwards, and helped to form the circle of Zinn with capillaries coming from the short posterior ciliary arteries. Between the pia mater and the optic nerve are vessels forming a second meshwork which extends to the axis of the optic nerve and forwards to form a network in the lamina cribrosa: it is with them that the circle of Zinn anastomoses.

Magitot (1908) drew attention to an embryological factor. The eye and the optic nerve are outgrowths of the diencephalon, and he thus explained why the arteries to the chiasma were short and those to the globe and optic nerve relatively long. He thought that anastomoses existed between the vessels leading to the optic nerve, but only at the level of the pia mater and not in the optic nerve itself. He wondered whether, in the optic nerve, one definite region was reserved for the vessels of the pia mater and another for the central retinal artery, the lamina cribrosa being supplied only by the arterial circle of Zinn, and the central retinal artery giving off no branches at this level. More recently, Magitot (1947) insisted on the existence of a vessel running from the cerebral arteries or from the ophthalmic artery and feeding the intracranial section of the optic nerve. According to Magitot, Beauvieux and Ristitch (1924) and Beauvieux and Gouelmino (1924) described five collateral vessels which arose from the central retinal artery before it entered the optic nerve in the dura mater, and penetrated the optic nerve, either immediately (Leber, 1903), or after running some distance along the nerve in the subarachnoidal space. Having once entered the optic nerve, the central retinal artery gives off no more branches; anastomoses with the other networks do not exist. Proximal to

the point of entry of the central retinal artery, the ciliary arteries help to build up the network of the pia mater, and distal to it branches supply the optic nerve *via* the pia mater. According to Magitot these branches play a part in feeding the lamina cribrosa (Fig. 3).

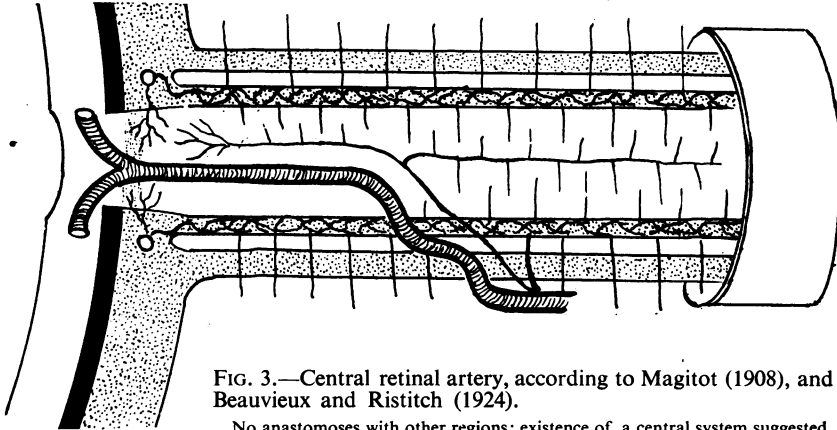


FIG. 3.—Central retinal artery, according to Magitot (1908), and Beauvieux and Ristitch (1924).

No anastomoses with other regions; existence of a central system suggested.

Rochon-Duvigneaud (1933) postulated the existence of two kinds of anastomoses between the central retinal artery and the short posterior ciliary arteries: indirect, through branches from the arterial circle of Zinn, and direct, between the choroidal vessels and the central retinal artery.

Behr (1935) established that the optic nerve in its intracranial part is supplied by both the ophthalmic artery and the anterior communicating artery, and in its intra-orbital and intracanalicular parts by the ophthalmic artery alone. He thought that the lacrimal artery might also assist in nourishing the optic nerve. The central retinal artery gives off in the anterior and middle thirds an anterior optic nerve (para-axial) artery, and in the posterior third the ophthalmic artery gives rise to the posterior optic nerve arteries. Thus an axial system exists for the anterior section, and may also exist for the posterior section (Fig. 4).

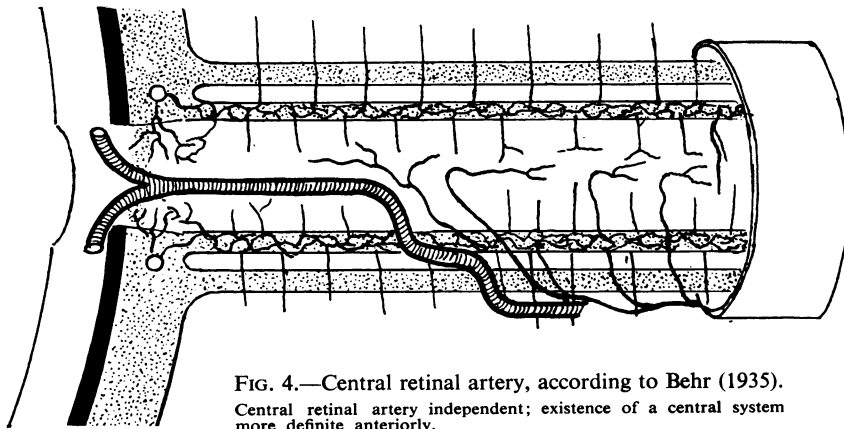


FIG. 4.—Central retinal artery, according to Behr (1935).

Central retinal artery independent; existence of a central system more definite anteriorly.

The lamina cribrosa is supplied by branches of the arterial circle of Zinn and by the central anterior optic nerve artery, which may give off capillaries serving as vasa vasorum for the central retinal artery, which gives off no branch in the optic nerve itself. The anterior part is also nourished by branches of the central retinal artery penetrating into the pia mater, that is to say, centripetally. In the optic nerve all capillaries anastomoses mutually.

Abbie (1938) maintained that the optic nerve is supplied by the central artery of the retina.

Wolff (1939) did not attribute to the central retinal artery a capillary extending at the level of the lamina cribrosa, but in 1940 he reversed this opinion, and described anastomosing branches between the central retinal artery and the circle of Zinn in the lamina cribrosa. The intracranial part is supplied by the anterior cerebral and internal carotid arteries in the superior and inferior aspects respectively. The ophthalmic artery and the anterior communicating artery may also assist in supplying the central retinal artery (Fig. 5).

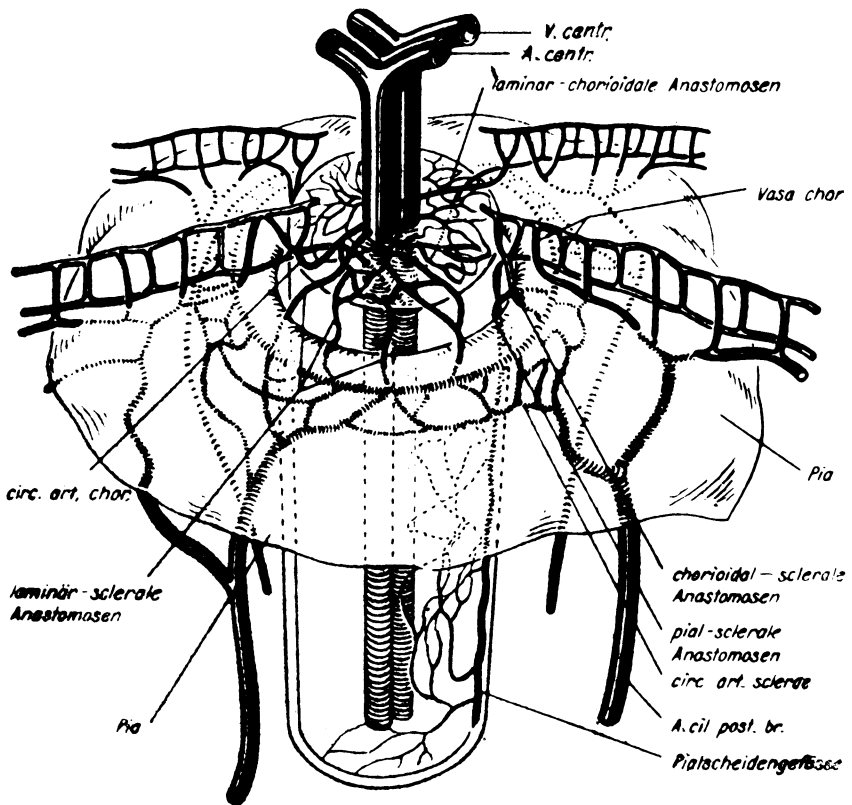


FIG. 5.—Vascular system, according to Sautter and Seitz (1952), after Leber (1903).

The intracanalicular portion is supplied by the ophthalmic artery, but the pial network is poorer than the orbital portion. The orbital part depends on two groups of vessels: those penetrating behind the entry of the central retinal artery, which originate from the ophthalmic artery and its collateral branches (less in the inferior

aspects), and those which are themselves branches of the central retinal artery (Kuhnt, 1879). These were described again by Beauvieux and Ristitch (1924) as collateral central retinal arteries penetrating into the optic nerve *via* the pia mater network. One of these arteries accompanies the central retinal artery to the centre of the optic nerve and divides into anterior and posterior branches feeding the macular fibres. The nerve head is supplied by the central retinal artery and by the arterial circle of Zinn.

Igersheimer (1942) supposed that the central retinal artery might occasionally give off branches with a nutritive purpose behind the lamina cribrosa.

Kiss (1943) mentioned the possibility of the existence of anastomoses between the central retinal artery and the arterial circle of Zinn.

Duke-Elder (1938) maintained that the central retinal artery, running forward and axially, gives off numerous small recurrent branches to supply the optic nerve up to the optic foramen, and then branches to the other parts of the nerve and its sheaths along its course. At the level of the lamina cribrosa several capillary anastomoses exist within the circle of Zinn.

Traquair (1946) thought that no vessel pierced the dura mater distal to the point of entry of the central retinal artery, and that all pial vessels derived from the central retinal artery in this region. The central retinal artery gave off no branches, once it had penetrated the optic nerve, except for the lamina cribrosa, where it anastomosed with the circle of Zinn.

Sautter and Seitz (1952) concluded experimentally that Leber's idea of the lamina cribrosa was correct: it was supplied by the central retinal artery, and there existed, moreover, functional anastomoses between the circle of Zinn and the central retinal artery; this was achieved by glomic cells situated close to the capillaries, which might also have a biochemically antitoxic function. Their experiments were performed on living rabbits. We did not find these glomic cells on the numerous slides we examined, and we are not at all certain of the existence of any central retinal artery in the rabbit (Fig. 6).

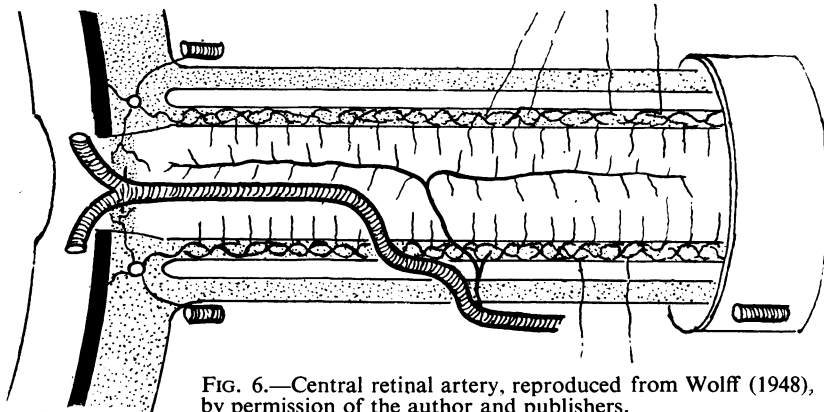


FIG. 6.—Central retinal artery, reproduced from Wolff (1948), by permission of the author and publishers.

Conclusions from the Literature

- (1) For the nutrition of the optic nerve from the outside to the axis (centripetal) the pial vessels give rise to capillaries penetrating to the nerve itself.
- (2) The short posterior ciliary arteries, before running into the choroid, give off

branches building up the arterial circle of Zinn-Haller, from which capillaries ramify into the lamina cribrosa.

(3) Capillary anastomoses may exist between the central retinal artery and the arterial circle of Zinn, which carry out both nutritional and biochemically anti-toxic functions.

(4) The central retinal artery supplies the optic nerve through collateral branches *via* the pia mater, through branches immediately directed to the optic nerve, and through branches given off immediately before, or after penetrating into the optic nerve and lying in the axis; these form a source of nourishment from within to the periphery (centrifugal).

(5) The central retinal artery may give off branches only outside the optic nerve.

(6) Anastomoses may exist, not only between the pial vessels but also at the capillary stage, between the capillaries of one system, and between those of the axial and peripheral systems.

(7) The intra-orbital supply of the optic nerve is probably independent of the intracranial supply.

(8) The lamina cribrosa may be supplied by the circle of Zinn alone, or by the central retinal artery alone, or by both.

(9) The vessels of the optic nerve derive from the central retinal artery and the ophthalmic artery, and the only source of the blood is the internal carotid artery.

(10) The region of supply of the central retinal artery is not yet established.

(11) Galezowski (1865) was the first and only writer to draw attention to the existence of capillaries of directly cerebral origin at the level of the optic nerve, lamina cribrosa, and papilla.

(12) Wolfring (1872) noticed anastomoses in the lamina cribrosa between the circle of Zinn and capillaries coming from behind the lamina cribrosa; he supposed that the latter derived from a secondary network between the pia mater and the optic nerve.

(13) Magitot (1947) was more definite than Leber (1903) and Behr (1935) in excluding the existence of anastomoses; Leber agreed with the concept of anastomoses at the level of the lamina cribrosa only, and Behr with the concept of anastomoses in the optic nerve only.

Discussion of the Literature

(1) Three points, taken from the literature, require elucidation:

(a) The significance of the capillaries of cerebral origin observed by Galezowski (1865).

(b) The possibility of anastomoses in the lamina cribrosa with capillaries from behind this structure (Wolfring, 1872).

(c) The disagreement on the subject of anastomoses; no two authors agree on the existence of an axial system, or about the behaviour, relations, and distribution of the central retinal artery, the circle of Zinn, and the pial vessels.

(2) The central retinal artery penetrates into the optic nerve between 10 and 20 mm. behind the globe, but to supply the optic nerve over a length of 45 mm., having once penetrated into and run inside the nerve over a distance of only 15 mm., is a different matter. The central retinal artery can give off branches in its extra-neural

course, but this is at the inferior aspect of the nerve, and it is this part which is relatively poorly supplied; some fortuitous branches may always exist, but they cannot be considered as taking the leading role in nutrition. This is indicated by comparative anatomy and by our own experiments (See below).

(3) The central retinal artery divides on the papilla, in its end-branches, just behind, or in the lamina cribrosa, or even in the optic nerve itself. It has been recorded experimentally and also by us that these branches never form anastomoses.

They always supply strictly retinal tissues. The existence of capillary anastomoses between the circle of Zinn and the central retinal artery in cases where the central retinal artery divides just behind the lamina cribrosa, is difficult to credit; the cases recorded by Igersheimer (1942) may have been of this kind.

(4) The fact that the central retinal artery always retains the same calibre from its origin to its division, argues against the existence of collateral vessels of any importance.

(5) The capillaries of the circle of Zinn anastomose with other capillaries. Normally there is a transition to the venous side of the capillary system, but the venous circulation in the circle of Zinn seems to be absent, and thus it is necessary for these capillaries to join other vessels possessing the normal relations. The anastomoses offer an easier outlet for the blood.

Before coming to the last three sections of this study (embryology, comparative anatomy, and our own experiments) a few facts should be re-called:

(1) Ordinarily there exists a large margin of variation, based on embryology, for the course of the arteries before they reach the region they must supply: but there can be little variation in the region supplied.

(2) For the neural tissues of the brain and those depending on it, it is not true that arterial anastomoses are impossible and that they are all end-arteries.

(3) Whether this is true for the capillaries, and whether a rete mirabile may be admitted for the optic nerve remains an open question.

Embryology

Up to the third week after the fertilization of the ovum (the 3 to 4 mm. stage) a vascular mesoderm of one layer of cells begins to appear with nucleated erythrocytes.

In the fourth week the optic cup is formed and the foetal fissure can be seen, on the temporal and inferior side of the distal part of the optic stalk, extending up to the brain. The fissure is filled up by mesoderm which penetrates immediately into the cup. From the beginning of their development the retina and the optic stalk are completely avascular.

At the 7-mm. stage (4th-5th week) the internal carotid artery curves over the optic stalk and gives off the ophthalmic artery from which arises the hyaloid artery; it penetrates the foetal fissure and the cup, and in the 5th week is buried by the closure of the lips of the fissure. This hyaloid artery gives off no branches, either the optic stalk, or to the retina.

Not the smallest trace of a choroidal network of vessels is to be found, except the condensation of some small capillaries here and there just in front of those parts of the external wall of the optic cup which take up pigment.

Later still the vessels of the anterior cerebral plexus are built up on the

temporal side of the prosencephalon almost as far as the diencephalon.

Small vessels begin to be distinguished in the orbital mesoderm and help to form the vascular system which will later evolve in the pia mater and near the posterior pole of the globe, and those parts which will later become the orbit. They communicate with the anterior cerebral plexus.

The foetal fissure is closed by the 6th week (12-mm. stage) except where the hyaloid artery penetrates; but at 17-mm. stage the marginal border is obliterated.

But even before this, the ophthalmic artery gives off the ciliary artery on the temporal side of the optic stalk, wherein the axons of the retina start to penetrate.

The mesodermal sheaths of the optic nerve are now formed (17-mm. stage), and immediately afterwards (19-mm. stage) the glial septa are formed by the inner layer of the optic stalk. The hyaloid vessel proper is now in existence.

During the 7th week the anterior ciliary arteries arise from the ophthalmic artery, and the common ciliary artery divides into the long temporal posterior ciliary artery and the long nasal posterior ciliary artery. The latter divides into twenty short posterior ciliary arteries during the 8th week (20-mm stage).

The first condensation of the sclera from the surrounding mesoderm occurs in the 9th week and appears at the posterior pole of the globe.

Between the 2nd and 3rd month (30-mm. stage), the short posterior ciliary arteries reach the vascular choroid; the septa of the optic nerve do not yet exist.

At the level of the lamina cribrosa, glial tissues always predominate (continuations of Bergmeister's papilla).

In the third month, at 12 to 13 weeks (65 to 73-mm. stage), vessels may be seen arising from the ophthalmic artery, accompanying the hyaloid artery for some distance, and then extending forwards, penetrating into the optic nerve by way of the sheaths and starting to supply it.

The hyaloid artery now begins to atrophy through the multiplication of glial cells of the papilla of Bergmeister around it, thus leaving a space between artery and glial sheath. This process proceeds from the proximal to the distal direction.

In the fourth month the bud of the retinal branches of the hyaloid artery becomes evident; this indicates the origin of the retinal branches of the intraneural, proximal segment of the hyaloid artery; it later becomes the central retinal artery. In this way a rupture, not anatomical but physiological, occurs between the intra-ocular and intraneural parts of the hyaloid artery. The retina now begins to be supplied by the proximal parts of the hyaloid artery, and simultaneously the optic nerve begins to be supplied by a definite tubular system. The central artery becomes functionally active in nourishing the retina, and the short posterior ciliary arteries build up the circle of Zinn (eventually developing into the cilio-retinal arteries), and feed the distal part of the optic nerve.

Meanwhile the vessels supplying the optic nerves have reached the region behind the lamina cribrosa, and ramifications probably penetrate and form connections with the circle of Zinn.

By the 7th month the hyaloid artery is not completely obliterated (but so is physiologically), and the medullation of the optic nerve has begun, though this has rarely reached the lamina cribrosa by birth. Elements of the choroid and fibres of the sclera penetrate into the choroidal lamina cribrosa, carrying with them blood vessels to give the scleral lamina cribrosa its final composition.

The hyaloid artery, which first feeds the anterior parts of the optic cup and the lens, loses this function in order to take up its definite work: the supply of the retina by its proximal part, a quality seen only in the primates and in man. Anastomoses with the anterior cerebral vessel may persist.

This process of embryological evolution confirms our experimental ideas. Indeed, during the development of the foetus, the central retinal artery supplies the retina only; the circle of Zinn and the other arterial branches of the ophthalmic artery supply only the optic nerve, and the various periods at which the different systems develop and reach their particular regions indicate that some of them are entirely excluded from nourishing the optic nerve.

Comparative Anatomy

The hyaloid artery is always present in mammals, but tends to disappear later than in man.

It is present at birth in the cat, and disappears only 1 or 2 months after birth. In the mole, which has a very low degree of visual acuity, the hyaloid artery persists throughout life. The hyaloid artery always exists at the beginning; the longer it persists the more likely is the central retinal artery to be absent, and the sooner it goes (as in man) the greater is possibility that a central retinal artery will develop.

The vessels destined for the retina, if they exist, penetrate more nearly into the globe in the other mammals than in man, because in man the central retinal artery must be better attached and protected than in animals, for the higher visual acuity of the human retina to be achieved. The ciliary vessels are more important in animals, because they play the largest part in nourishing the retina. It is not certain that the dog, cat, and fox have any central retinal artery at all. In the dog the retina is supplied by cilio-retinal arteries, deriving from the circle of Zinn. When the central retinal artery is absent, and when the hyaloid artery has disappeared completely, the ciliary system is predominant. It has been established that in these animals central arteries exist in the optic nerve extending forwards by ramifications (Wolff, 1948; Davies, 1928). Bernoulli (1949) reported a rare case of the persistence of a hyaloid artery in a young boy with an anangiomatic retina, and Holm (1923) another case with very small vessels in the retina.

We can conclude that the vessels of the optic nerve and the vessels of the circle of Zinn are the oldest, and that the central retinal artery has the special function in the higher mammals (the primates and man) of supplying the retina according to their more highly developed visual acuity. The human retina belongs both to the central artery type, and to the holangiomatic type.

In man the nutrition of the retina and optic nerve is evenly shared, and the ciliary system is reserved for the choroid, lamina cribrosa, and partly for the optic nerve; whereas in animals the ciliary system has to supply the retina also, at least in paurangiomatic, merangiomatic, and holangiomatic types of fundus. The central optic nerve artery seems to exist in animals as in man.

Experimental Work

Method.—The technique of studying the vascularization of the optic pathway had to be adapted to our special purpose, so that we might observe these vessels in the finest detail.

In the living man or animal we can proceed by arteriography, but by this technique only the greater vessels of the orbit and the brain are visible, and an *x*-ray film taken when the capillaries are filled with the contrast medium gives only a hazy picture.

We used *post-mortem* material by two different methods:

(1) Dissection of arteries and arterioles before and after fixation in formol 10 per cent.

(2) Injection of a plastic material, Neoprene latex 572, with additional colour. We used the apparatus and technique described by Ashton (1951) in his studies of Schlemm's canal. This method was used by Lieb (1940) and by Duff and More (1944), and later by Trueta and others (1947) in studies of the renal circulation.

The injected specimens were immersed in formol 10 per cent. and dissected, or soaked in pepsin and then in trypsin to digest the surrounding non-injected tissues and obtain a vascular tree. This is more difficult with the optic nerve and lamina cribrosa than with the retina and choroid, because the former tissues are more fibrous.

Material.—We injected a total of 34 specimens.

(1) *Ophthalmic Artery* (four times).—The whole tree was filled up, but the capillary regions were not all well filled.

(2) *Central Retinal Artery* (eight times).—The retina was very well injected, and also at times a few pial vessels.

(3) *Central Optic Nerve Artery* (six times).—The optic nerve was filled to the centre, and the lamina cribrosa completely.

(4) *Short Posterior Ciliary Artery* (once).—A small region of the choroid and some capillaries of the lamina cribrosa were filled. Although difficult to obtain, this injection did not teach us much.

We dissected with the binocular microscope after fixation in formol 10 per cent. and partial digestion. For the arteries and arterioles we dissected immediately after fixation or digestion, but the other specimens were either not well injected or were directly dissected without injection or fixation.

Neither after injection of the central retinal artery alone, nor after injection of the ophthalmic artery at a lower point in its course, nor after injection of one of the short posterior ciliary arteries, was it possible to show a clear communication between the central retinal artery and the arterial circle of Zinn. At first we thought that no anastomoses existed, or that the injection-mass did not penetrate into the finest capillaries.

The most interesting point was an obvious axial filling-up in the optic nerve, the origin of which remained obscure.

At one stage, while doing the preliminary dissection of the first collateral arteries of the ophthalmic artery, we detected a small artery, which we supposed to be the central retinal artery; we injected this vessel and filled all the axial system and the lamina cribrosa. After dissection we found the central retinal artery quite empty and the retina not injected. This vessel was injected five times, and gave the following anatomical picture:

A small collateral of the ophthalmic artery arising before the origin of the central retinal artery, extending forwards at the inferior temporal or inferior nasal aspect of the optic nerve (and crossing, in two cases out of six, the optic nerve below to the nasal side) entered into the optic nerve without having divided at all (or having divided into two branches only). Sometimes it entered near the point of entry of the central retinal artery, sometimes 5 to 10 mm. behind it, and it was guided to the axis of the nerve, where it divided (if this division did not already exist) into anterior and posterior branches. At the level of the lamina cribrosa it anastomosed with the capillaries of the circle of Zinn, but at the level of the optic foramen the anastomoses were doubtful. We were then sure that we were dealing with a central optic nerve artery, a collateral of the ophthalmic artery with anterior and posterior branches, the former anastomosing forwards with the circle of Zinn. The anterior branch lay on the temporal side and the posterior branch towards or even below the centre. This vessel appeared to be designed to supply the macular fibres, and the capillaries of the anterior branch might also have acted as vasa vasorum for the central retinal artery.

It was now clear why the injection into the ophthalmic artery at a point in its course lower than the origin of the central optic nerve artery did not fill the lamina cribrosa or the axial system.

When the central retinal artery is injected the retina is very well filled, but no other region becomes clearly evident. Sometimes a few injected small branches are found to derive from the central retinal artery and join the pial network outside the optic nerve. The vessels which run to the pia mater in the neighbourhood of the point of entry of the central retinal artery are not collateral arteries of the latter, but arise further back, coming from the ophthalmic artery, which can give off a recurrent branch to the chiasma, or from the central retinal artery just after its origin. The ophthalmic artery has recurrent branches anastomosing with branches from the internal carotid artery and branches of the anterior cerebral artery; from these, small anastomotic branch arteries also run to the pial sheath.

An axial system and a peripheral system exist in the optic nerve. In the pial network we could not find frequent anastomoses, and we could not establish whether anastomoses existed in the optic nerve itself.

An interesting experiment (although not very helpful in confirming the existence of anastomoses between the central optic nerve artery and the circle of Zinn) is to fill by injection a short posterior ciliary artery; this filling extends into the lamina cribrosa posteriorly and centripetally. After injection the branches issuing from the short posterior ciliary arteries run into the lamina cribrosa and extend forward to the choroid.

Fig. 7 (opposite) shows the arteries which help to supply the optic nerve and lamina cribrosa and also their anastomoses. Moreover, branches of the cerebral anterior artery can, after anastomosing with branches of the internal carotid artery, help to supply the optic nerve. The table also shows that, in conditions of changed position or in pathological processes (not only vascular), a retrograde nutrition *via* the anastomoses with the external carotid artery is certainly possible, besides that from the anterior communicating artery, the anterior cerebral artery, and the arterial circle of Willis.

Conclusions

(I) LAMINA CRIBROSA AND PAPILLA (Fig. 8, overleaf).

(a) *Sclera*

(i) Capillary ramifications issue from the arterial circle of Zinn-Haller, built up by branches of the short posterior ciliary arteries. These ramifications anastomose with the terminal capillaries of the anterior branch of the central artery of the optic nerve, and not with the central retinal artery, which is strictly terminal and gives off no branches throughout its course, apart from some small ones to the pial network.

(ii) Ramifications of the short posterior ciliary arteries first supply the sclera, and then continue to the lamina cribrosa.

(b) *Nervous System*

(i) Branches issue from the vascular network of the pia mater.

(ii) Terminal ramifications of the anterior branch of the central optic nerve artery anastomose with those of the arterial circle of Zinn.

(c) *Choroid*.—Recurrent branches issue from the choroidal vessels.

(II) OPTIC NERVE (Fig. 9, overleaf).

(a) The central retinal artery passes *through* the optic nerve between 10 and 20 mm. behind the posterior pole of the globe.

(b) The optic nerve is supplied by capillaries issuing from the vascular network of the pia mater throughout its length. This network is composed of branches from the following arteries:

(i) from anastomoses between the recurrent collateral twigs of the ophthalmic artery and the collateral twigs of the cerebral part of the internal carotid artery.

(ii) from anastomoses between twigs of the anterior cerebral artery and twigs of the cerebral part of the internal carotid artery.

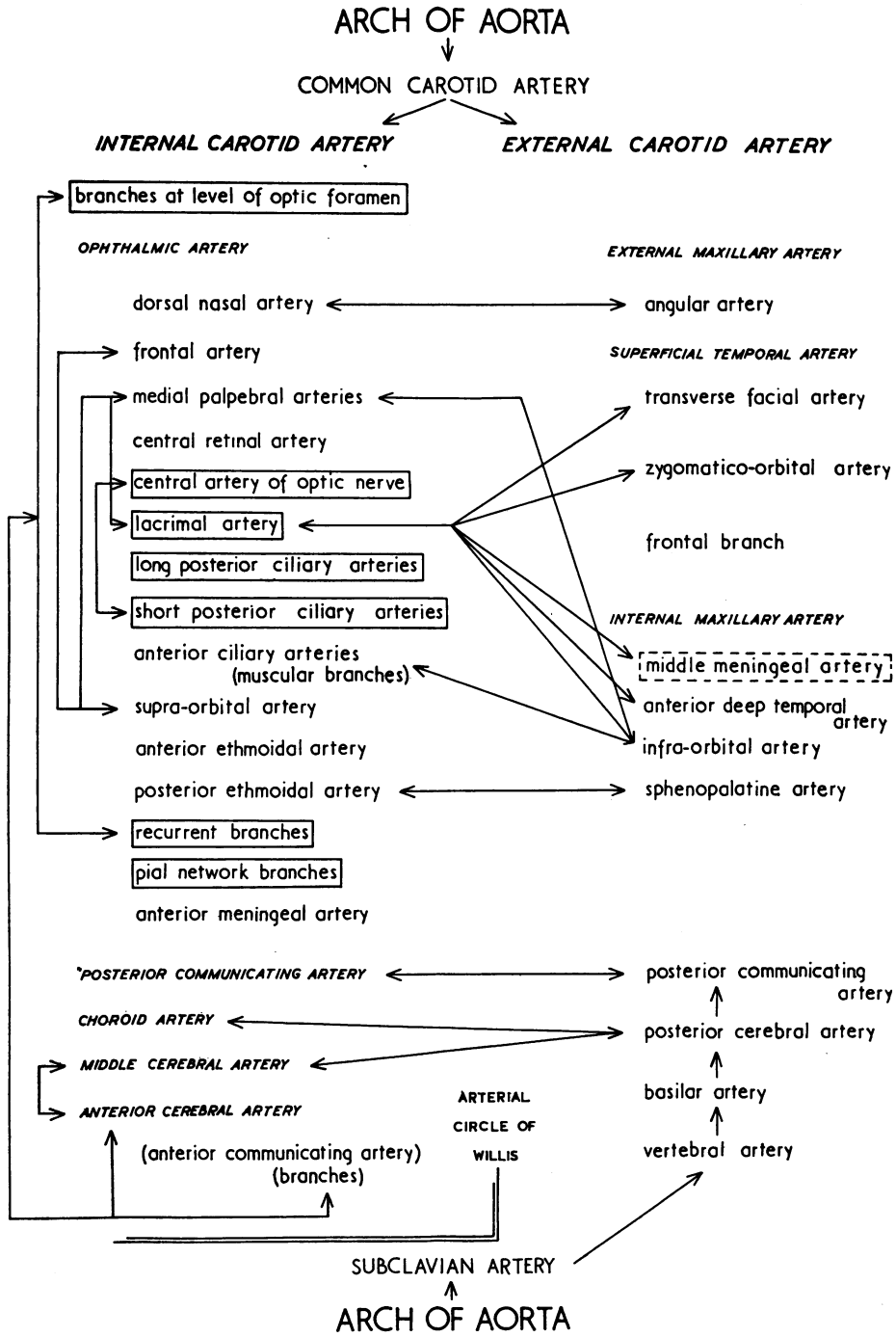


FIG. 7.—Diagram of optic nerve supply and anastomoses of arteries of visual pathway.

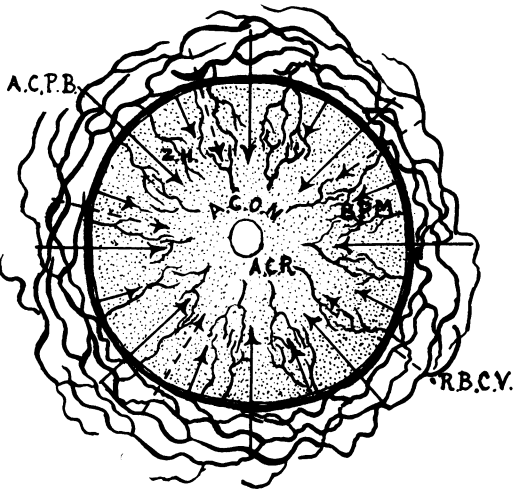


FIG. 8.—Lamina cribrosa and papilla, authors' view.

- | | |
|----------|--|
| A.C. | central retinal artery |
| Z.H. | capillary ramifications of arterial circle of Zinn-Haller. |
| A.C.P.B. | ramifications of short posterior ciliary arteries |
| B.P.M. | branches from pia mater |
| A.C.O.N. | terminal ramifications of central optic nerve artery |
| R.B.C.V. | recurrent branches from choroidal vessels |

(iii) from anastomoses between the lacrimal artery and the cerebral part of the middle meningeal artery.

(iv) from branches of the lacrimal artery, forming numerous anastomoses with the external carotid artery.

(v) branches of the ophthalmic artery and central optic nerve artery.

(vi) branches of the short and long posterior ciliary arteries.

We must add, for the intracranial and intracanalicular part of the optic nerve, branches, from the internal carotid, anterior cerebral, and anterior communicating arteries.

(c) Apart from this peripheral system supplying the optic nerve centripetally, an axial system feeds the nerve centrifugally; and this latter system is destined to supply the macular fibres, and serves, meanwhile, as vasa vasorum for the central retinal artery.

This axial system consists of a central optic nerve artery, a collateral of the ophthalmic artery, dividing at every level into anterior and posterior branches in the

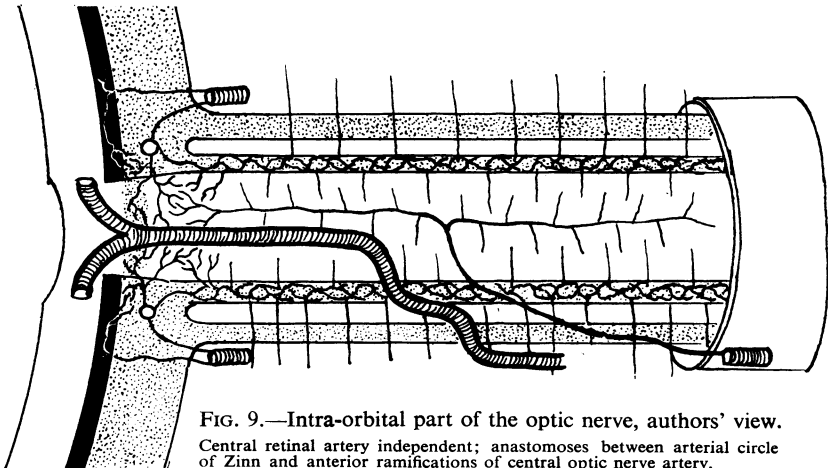


FIG. 9.—Intra-orbital part of the optic nerve, authors' view.
Central retinal artery independent; anastomoses between arterial circle of Zinn and anterior ramifications of central optic nerve artery.

axis of the optic nerve. The anterior branch extends forward to the lamina cribrosa, ramifies for the neural part, and anastomoses with capillaries issuing from the anterior circle of Zinn-Haller. The posterior branch extends to the optic foramen.

Summary of Findings

From these conclusions, the following facts emerge:

- (1) The subdivision agreed upon is based upon embryological development.
- (2) The ophthalmic artery is not the only vessel which supplies the optic nerve. Not only the anastomoses between the lacrimal artery and the middle meningeal artery, but also all the branches shown in the Table may contribute to the nourishment of the optic nerve *via* the pia mater network.
- (3) The central retinal artery does not supply the optic nerve, but only the retina.
- (4) The ophthalmic artery gives off very early in its course a central optic nerve artery, which at various places, both intra-canalicular and intra-orbital, forms the axial nutritional system of the optic nerve.
- (5) Anastomoses exist between the capillaries issuing from the circle of Zinn-Haller and the anterior ramifications of the anterior branch of the central optic nerve artery, which also supply the nervehead.
- (6) Capillaries issue from anastomoses between the extra-orbital cerebral vessels, run into the pial sheath, and help to feed the optic nerve.

Certain opinions and findings of other writers have also been confirmed:*

- (1) A peripheral and a central (axial) vessel system (*via* the pial sheath) exist in the optic nerve (Beauvieux and Ristitch, 1924; Beauvieux and Gouelmino, 1924; Magitot, 1908; Behr, 1935; Wolff, 1948).
- (2) The arterial circle of Zinn-Haller is built up by the short posterior ciliary arteries (Leber, 1903).
- (3) Choroidal vessels run to the optic nervehead (Leber, 1903).
- (4) The axial system seems to be designed to feed the macular fibres and to serve as vasa vasorum for the central retinal artery (Behr, 1935).

The following questions remain unanswered:

- (1) Is the supply of the intracanalicular and intracranial parts independent of that of the intra-orbital part of the optic nerve?
- (2) Do anastomoses exist between the axial and peripheral systems?
- (3) Do anastomoses exist between the vessels of the optic nerve and the chiasma?

REFERENCES

- ABBIE, A. A. (1938). *Med. J. Aust.*, **2**, 199.
 ASHTON, N. (1951). *British Journal of Ophthalmology*, **35**, 291.
 BARCLAY, A. E. (1951). "Micro-arteriography". Blackwell, Oxford.
 BEAUVIEUX, J. and RISTITCH, K. (1924). *Arch. Ophtal.*, **41**, 352.
 ———, and GOUELMINO, R. (1924). *C.R. Soc. Biol. (Paris)*, **90**, 1241.
 BEHR, C. (1935). *v. Graefes Arch. Ophthal.*, **134**, 227.
 BERNOULLI, R. (1949). *Ophthalmologica (Basel)*, **117**, 169.

*We were not able to find the glomic cells described by Sautter and Seitz (1952).

- CONE, W., and MACMILLAN, J. A. (1932). In "Cytology and Cellular Pathology of the Nervous System", ed. W. Penfield, vol. 2, p. 837. Hoeber, New York.
- DAMEL, C. S. (1936). *Arch. Oftal. (B. Aires)*, **11**, 57.
- DUFF, G. L., and MORE, R. H. (1944). *J. techn. Meth.*, **24**, 1.
- DUKE-ELDER, S. (1938). "Text-book of Ophthalmology", vol. 1. Kimpton, London.
- EISLER, P. (1930). "Kurzes Handbuch der Ophthalmologie", ed. F. Schieck and A. Brückner, vol. 1, pp. 36, 135-158, 294-300, 492-493. Springer, Berlin.
- ELSCHNIG, A. (1893). *v. Graefes Arch. Ophthalm.*, **39**, pt. 4, 191.
- FAWCETT, E. (1895). *J. Anat. (Lond.)*, **30**, 49.
- FAZIO, C., and FARINA, P. (1940). *Riv. oto-neuro-oftal.*, **17**, 38.
- GALEZOWSKI, X. (1865). *Gaz. hebdom. Méd. Chir.*, 2 sér., **2**, 811.
- HADEN, H. C. (1944). *Amer. J. Ophthalm.*, **27**, 1.
- (1947). *Ibid.*, **30**, 1205.
- HALLER, A. VON (1754). "Arteriarum oculi historia et tabulae arteriarum oculi". Göttingen.
- HAMILTON, W. J., BOYD, J. D., and MOSSMAN, H. W. (1945). "Human Embryology". Heffer, Cambridge.
- HOLM, E. (1923). *Acta ophthalm. (Kbh.)*, **1**, 66.
- HUSCHKE, E. (1844). "Eingeweide und Sinnesorgane". See Sömmerring (1844).
- HYRTL, H. (1839). *Öst. med. Jb.*, **19**, 1.
- IGERSHEIMER, J. (1942). *Ophthalmologica (Basel)*, **103**, 230.
- JAEGER, E. VON (1861). "Ueber die Einstellungen des dioptrischen Apparates im menschlichen Auge", pp. 52-56. Vienna; Masson, Paris.
- JAYLE, G. E. (1939). "Traité d'ophtalmologie", vol. 1, p. 347. Masson, Paris.
- KEENEY, A. (1951). "Chronology of Ophthalmic Development". American Lecturer Series. Thomas, Springfield, Ill.
- KERSHNER, C. M. (1943). "Blood Supply of the Visual Pathway". Meador Publ. Co., Boston.
- KISS, F. (1943). *Ophthalmologica (Basel)*, **106**, 225.
- KRAYENBÜHL, H., and RICHTER, R. (1952). "Die zerebrale Angiographie". Thieme, Stuttgart.
- KUHNT, H. (1879). *v. Graefes Arch. Ophthalm.*, **25**, pt. 3, 179.
- LEBER, T. (1865a). "Anatomische Untersuchungen ueber die Blutgefasse des menschlichen Auges", Denkschriften der Wiener Wissenschaft Akademie (Math.-Naturwiss. classe), **24**, 297.
- (1865b). *Ibid.*, **11**, pt. 1, 1.
- (1872). *Ibid.*, **18**, pt. 2, 25.
- (1903). "Die Cirkulations- und Ernährungsverhältnisse des Auges", In "Graefes-Saemischer Handbuch der Augenheilkunde", vol. 2, p. 1.
- LHERMITTE, J. (1939). "Traité d'ophtalmologie", vol. 1, p. 617. Masson, Paris.
- LIEB, E. (1940). *J. techn. Meth.*, **20**, 48.
- LOEWENSTEIN, A., and GARROW, A. (1945). *Amer. J. Ophthalm.*, **28**, 840.
- MAGITOT, A. (1908). "La vascularisation du neuf optique et du chiasma". Thèse de Paris.
- (1947). *Ann. Oculist. (Paris)*, **180**, 31.
- MANN, I. (1949). "The Development of the Human Eye", 2nd ed. British Medical Association, London.
- MONRO, T. K. (1895). *J. Anat. (Lond.)*, **30**, 45.
- RISTITCH, K. (1924). "La vascularisation du nerf optique et du chiasma". Thèse de Bordeaux.
- ROCHON-DUVIGNEAUD, A. (1934). "Recherches sur l'oeil et la vision chez les vertébrés". Barnéoud, Laval.
- SAUTTER, H., and SEITZ, R. (1952). *v. Graefes Arch. Ophthalm.*, **152**, 413.
- SCHWALBE, G. (1887). "Lehrbuch der Anatomie der Sinnesorgane". Besold, Erlangen.
- SÖMMERRING, S. T. (1844). "Vom Baue des menschlichen Körpers", vol. 5, "Lehre von den Eingeweiden und Sinnesorganen", ed. E. Huschke. Leipzig.
- SONDERMANN, R. (1948). *v. Graefes Arch. Ophthalm.*, **148**, 331.
- SUDAKEVITCH, T. (1947). *British Journal of Ophthalmology*, **31**, 738.
- TICHOMIROFF, M. A. (1900). "Variations of the Arteries and Veins of the Human Body". Kiev.
- TIEDEMANN, F. (1824). *Z. Physiol.*, **1**, 237.
- TRAQUAIR, H. M. (1946). "An Introduction to Clinical Perimetry", 5th ed. pp. 296-299. Kimpton, London.
- TRUETA, J., BARCLAY, A. E., DANIEL, P. M., FRANKLIN, K. J., and PRICHARD, M. M. L. (1947). "Studies of the Renal Circulation". Blackwell, Oxford.
- VAIL, D. (1948). *Amer. J. Ophthalm.*, **31**, 1.
- VOSSIUS, A. (1883). *v. Graefes Arch. Ophthalm.*, **29**, pt. 4, 119.
- WALSH, F. B. (1947). "Clinical Neuro-Ophthalmology", pp. 8-28. Williams and Wilkins Co., Baltimore.
- WILCZEK, M. (1947). *British Journal of Ophthalmology*, **31**, 551.
- WOLFF, E. (1939). *Trans. ophthalm. Soc., U.K.*, **59**, 157.
- (1940). *Ibid.*, **60**, 69.
- (1948). "The Anatomy of the Eye and Orbit", 3rd ed. Lewis, London.
- WOLFRING, K. (1872). *v. Graefes Arch. Ophthalm.*, **18**, 10.
- ZINN, J. G. (1755). "Descriptio anatomica oculi humani". Wriesberg, Göttingen.