

ANGIOID STREAKS AND PSEUDOXANTHOMA ELASTICUM*

BY

C. G. KEITH

Late Medical Officer i/c Ophthalmic Department, British Military Hospital, Hamburg

SCHOLZ (1941), reviewing the literature on angioid streaks and pseudoxanthoma elasticum, collected a total of 188 cases, only seventeen of which were reported from Great Britain. A further case is described in this article.

Angioid streaks were first described by Doyne (1889) and then by Plange (1891); Knapp (1892) gave them their present name. The fundus appearance in this disease was described by Verhoeff (1928) as follows:

A more or less broken peripapillary ring of pigment from which pigmented streaks extend out into the fundus. The appearance of the streaks varies from dark red to brown or even black. The edges of the streaks are serrated and along their course there may be reddish dots. They lie beneath the retinal vessels and above the choroidal ones. Usually there is a complete or incomplete greyish zone about the papilla. The entire fundus may have a mottled appearance or the degenerative changes may appear only in the periphery. Both eyes are involved.

However, since Verhoeff published this account, two cases of monocular angioid streaks have been described: one by Grönblad (1932) and one by Isayama (1940).

The most common presenting symptoms of patients with angioid streaks is diminution of vision. This is due to associated macular abnormalities which were present in 140 out of the 188 cases collected by Scholz (1941). These abnormalities may be haemorrhage, scarring, abnormal pigmentation, hole at the macula, exudate, or a specific type of retinitis such as disciform degeneration or retinitis circinata. Flame-shaped and blot-haemorrhage may occur in any part of the fundus. A peculiar type of haemorrhage caused by trauma described by Marchesani and Wirz (1931) comprises large tear-drop-like haemorrhages in the layer between the retina and choroid, rather similar to pre-retinal haemorrhages but at a deeper level. The diagnosis is revealed by examining the untraumatized eye. These haemorrhages are absorbed completely, but the authors suggest that they leave behind them white streaks in the retina similar to those which remain after a choroidal detachment. Other abnormalities of the retina may also be seen, such as pigment and hyaline bodies, especially drusen of the optic disc.

Pseudoxanthoma elasticum was first described by Balzer (1884), whose

* Received for publication April 11, 1956

two patients were later re-described by Chauffard (1889) and again by Darier (1896) who gave this condition its name. These same two patients were presented once more by Hallopeau and Laffitte (1903), who also noted that one of them had "une amblyopie—il ne peut plus lire. M. Antonelli a constaté l'existence d'un chorio-rétinite de la région centrale, intéressant la macule, avec atrophie secondaire de la papille optique". No further attention was paid to the association of the eye and skin condition until Grönblad (1929, 1932) published an account of the two diseases occurring together; Marchesani and Wirz (1931) described three new cases, reviewed the literature, and postulated the pathological basis of the syndrome.

The clinical picture of pseudoxanthoma elasticum is characterized by egg-yellow or light orange pinhead-sized papules, which may be discrete or confluent. The lesions, which may be as large as the palm of the hand, are linear, reticulated, or punctate, and occur on the sides of the neck, below the clavicle, in the axillary fold, the cubital fossa, the popliteal space, and the inguinal region, and sometimes on the chest, abdomen, and thigh. Lesions have also been reported as occurring in the buccal mucosa. The skin surrounding the lesion is usually livid and may even be telangiectatic, and characteristically there is loss of elasticity in the involved region (Ebert, 1943).

Case Report

A white, married, professional soldier aged 30 was admitted to the surgical ward on May 27, 1955, with acute back strain after heavy lifting. He had had two previous attacks. There was no sciatica present and a diagnosis of lumbago was made.

Investigations.—Erythrocyte sedimentation rate 27 mm./hr (Westergren). Total white blood count 5,600 per c.mm.; neutrophils 48 per cent., lymphocytes 50 per cent., basophils 2 per cent.

X rays of lumbar spine and sacro-iliac joints showed no abnormality.

The pain in the back responded to physiotherapy. The physician was then asked to see the patient because of the asymptomatic skin condition which had been present as long as the patient could remember.

Physical Examination.—Good colour and build. No finger clubbing. Palpable discrete, non-tender mobile glands in neck, axillae, and groins.

Respiratory System: Normal.

Cardiovascular System: Pulse 80, regular; blood pressure 160/90, Grade II split P₂.

Central Nervous System: Normal.

Abdomen: Liver palpable $\frac{1}{2}$ " below costal margin, not tender; tip of spleen palpable.

Skin: Complexion sallow, skin not greasy. A xanthomatous-like condition involved the skin of both axillae, the sides of the neck, chest, abdomen, groins, genitalia, popliteal fossae, and elbow flexures. The lesions were intradermal, yellow to orange, pinhead-sized papules lying in plaques. They were mainly of linear distribution in the skin flexures. The skin of all affected areas was lax, inelastic, and tending to lie in folds, especially in the axillae. There was a post-herpetic lesion over the sternum.

Investigations.—X rays of chest, skull, lumbar spine, and sacro-iliac joints showed no abnormality; M.S.U. normal.

Erythrocyte sedimentation rate: 6 mm./hr (Westergren). Total white blood count 7,800 per c.mm.; red blood cells 4,680,000 per c.mm.; Hb 100 per cent. (Haldane); neutrophils 47 per cent., lymphocytes 50 per cent., monocytes 3 per cent.

The patient was then referred to the ophthalmological department because of the peculiar appearance of the ocular fundi. He had worn glasses for years, and nothing abnormal had been mentioned previously. The notes of his previous examination 6 years before stated that the fundus was normal.

Family History.—His mother had had the right eye enucleated in 1945 (reason not known); the left eye had had a trephine and iridectomy. His father's sight was failing. Three sibs, aged 52, 35, and 29 were all well, with no skin lesions. Eight siblings (born before the patient) had died in the first 2 years of life and one born after the patient had died in infancy (causes not known).

Ophthalmological Examination

Visual Acuity: Right eye 6/36 - 1.75 D sph., +5 D cyl., axis 105° = 6/9

Left eye 6/36 +1 - 1.25 D sph., +4 D cyl., axis 67° = 6/9

Conjunctiva, cornea, anterior chamber, iris, lens, and vitreous all appeared normal. The pupils were equal, and reacted to light and accommodation briskly.

Visual Fields: Right peripheral fields showed general constriction, central fields normal.

Right Fundus: The disc was distorted by multiple drusen. Many angioid streaks radiating from circumpapillary ring to mid-equatorial region. Some hyaloid bodies were present near the ora serrata at 6 o'clock. A few patches of choroidal reactions were present. Scattered yellow pin-point spots were seen all over posterior pole. Macula normal.

Left Fundus: This showed a similar picture, except that the disc was surrounded by a halo of light-coloured tissue and the streaks arose from this (Figure). The multiple yellow spots and patches of choroidal reaction were more marked than in the right fundus. There was lightly scattered pigment at the macula, with one pin-head-sized patch in the paramacula.

The retinal vessels were normal in both fundi.

Diagnosis.—Angioid streaks and pseudoxanthoma elasticum.

Further Investigations:

Right Axillary Skin Biopsy: Elastic tissue of the corium markedly increased, the fibres being swollen, fragmented, and tending to occur in clumps. These changes were readily seen in routine haematoxylin and eosin sections and were confined to the deeper layers of the corium (Major Hardy: pathologist of the Royal Army Medical College).

Fasting Blood Sugar: 110 mg./100 ml.

Serum Bilirubin: Less than 0.1 mg./100 ml.

Blood Urea: 22 mg./100 ml.

Serum Alkaline Phosphatase: 8 King Armstrong units/100 mg.

Serum Acid Phosphatase: 12 King Armstrong units/100 ml.

Thymol Turbidity: 1 unit.

Thymol Flocculation: 0.

Wassermann Reaction and Kahn Test: Negative.

Serum Cholesterol: 178 mg./100 ml.

Serum Calcium, Potassium, and Chloride: Normal.

June, 1955: Total 7.2 g./100 ml. (Albumin 3.8 g./Globulin 3.4 g.) A/G 1.1:1.

September, 1955: Total 7.00 g./100 ml. (Albumin 4.5 g./Globulin 2.5 g.) A/G 1.8:1.

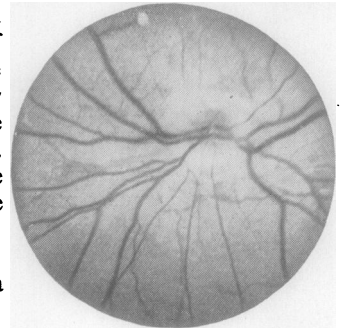


FIGURE.—Left fundus, showing circumpapillary greyish zone of tissue and angioid streaks of varying thickness arising from it.

Sternal Marrow Biopsy: Normal.

Electrocardiogram: Normal.

Chest Screening and Barium Swallow: Normal.

X-rays: Skull normal; thighs showed calcification of left femoral vessels.

The peripheral pulses in the feet were absent except in the right posterior tibial artery.

Discussion

Associations.—Scholz (1941) reviewed the literature on angioid streaks very thoroughly and collected 188 reported cases of the disease, 139 of which had been reported since Grönblad (1929, 1932) published his articles on the associations of this condition with pseudoxanthoma elasticum. Of these 139 cases of angioid streaks, 59 per cent. had pseudoxanthoma elasticum, 13 per cent. had no skin lesions, and in 18 per cent. the skin was not mentioned. Sandbacka-Holmström (1939) collected one hundred cases of pseudoxanthoma elasticum and found that 87 per cent. had angioid streaks.

Since Rowland (1933) first recorded a case of osteitis deformans (Paget's disease) occurring with angioid streaks, many more cases have been described. Scholz (1941) described 139 more recent cases of angioid streaks, of whom 9 per cent. had osteitis deformans.

Terry (1934), who studied 22 patients with osteitis deformans, found angioid streaks in three of them; Berliner (1933), who studied 29 patients with osteitis deformans, found one with angioid streaks; Scholz (1941), who examined fourteen, found one with angioid streaks. Thus, of a total of 65 patients with osteitis deformans, five (8 per cent.) had angioid streaks.

Scheie and Freeman (1946) described three patients with angioid streaks, two of whom had pseudoxanthoma elasticum and severe vascular disturbance of the lower limbs. X rays of the thighs of these two patients showed calcification of the femoral vessels.

Heredity.—Angioid streaks show a familial tendency; De Schweinitz (1896) described its occurrence in brothers, and seventeen more cases of its occurrence in two siblings have since been described.

Histology.—The picture in the skin is characterized by diffuse and circumscribed areas of swollen, broken, and fragmented elastic fibres in the sub-papillary layer and middle portions of the cutis (Finnerud and Nomland, 1937). Degenerated fibres occur in large coils which are surrounded by normal collagen fibres. Bodin (1900) described a giant cell which was either an elastoblast or an elastoclast, and similar cells were described and microphotographs published by Marchesani and Wirz (1931), who said that the cell was similar to a Langhans giant cell. These cells surround and seem to destroy the clumped elastic tissues in the corium. Marchesani and Wirz (1931) also described changes in the walls of the blood vessels in the affected parts of the skin. The elastica of the arterioles is deficient, the lumen is enlarged, and the walls thinned and even burst in places, resulting in haemor-

rhages into the tissues. Finnerud and Nomland (1937) demonstrated the presence of excessive quantities of calcium in the degenerated elastic tissues in the corium.

The histological picture in the eye is not so clearly established. Kofler (1917) first suggested that the appearance of the angioid streaks was due to splits in the lamina vitrea, and this theory has received much support.

Other suggestions that the streaks resulted from haemorrhage (Plange, 1891) or from a primary exudative process (Coppez and Danis, 1925) have now been discarded. The main barrier to the elucidation of the pathological changes in the eye has been the lack of *post-mortem* specimens. However, Boeck (1938) obtained the eyes, 48 hrs after death, from a patient who had pseudoxanthoma elasticum and angioid streaks. Staining with haematoxylin and eosin showed thickening of the lamina vitrea, which also stained deeply with elastic tissue stains. This layer showed many small defects and breaks and in other areas appeared split and fragmented. These changes were most evident near the papilla, whereas there was little change near the ora serrata. Serial sections of the eye showed that the breaks in the lamina vitrea corresponded to the angioid streaks seen *ante mortem*. The tunica elastica of the ciliary arteries and the arteries in the chorio-capillaris also showed degenerative changes. The elastica in the aorta showed thickening and disintegration. This patient had been observed to have enlargement of the aorta fluoroscopically before death.

Hagedoorn (1939a, b) also described the histological appearance of the eyes from a case of angioid streaks, and he too noted the degenerative changes in Bruch's membrane, particularly when stained with orcein. The degeneration was greatest in the sub-papillary and submacular areas. He could find no increase in the amount of calcium present in the elastica, but this may have been due to the preserving fluid dissolving the calcium out. He did find that the lamina vitrea gave a positive reaction for iron with Turnbull's blue reagent.

Verhoeff (1939) disputed the significance of these changes in Bruch's membrane and stated that similar staining was found in seventy eyes out of six hundred examined at random.

Of two hundred eyes examined histologically at Johns Hopkins University, 10 per cent. showed basophilic staining of the lamina vitrea, and in two cases there was fragmentation similar to that seen in the cases of Boeck and Hagedoorn. One of these had Paget's disease (Scholz, 1941).

Aetiology.—The natural history of the disease is quite unknown. The familial tendency may indicate a congenital weakness of elastic tissue. The disease manifests itself on the skin where it is most easily seen, and in the eye where it causes symptoms of visual impairment. On the skin it affects primarily those areas most rich in elastic tissue, that is, the skin over the flexor surfaces of the joints. The skin there must contract when the joint

is flexed so that it is not thrown up into folds which would impede full flexion. The elastic tissue here takes up the "slack" in the skin. The lamina vitrea is also very rich in elastic tissue. The arrangement of the elastic fibres is disturbed where the optic nerve passes back to the brain and it is around this site of disturbance that the circumpapillary ring occurs and the angioid streaks usually arise.

The underlying pathological process, a degeneration of the elastic tissue, is probably the same in all areas affected by the disease, that is, the skin, eye, aorta, ciliary and choroidal arteries, femoral vessels, and possibly the smaller arteries of the feet. The enlarged liver and spleen in the case presented here may have the same pathological cause. The high incidence of Paget's disease in patients with angioid streaks, and *vice-versa*, indicates some similar aetiological factor or common pathological process. The excess of calcium demonstrated in the skin lesion and in the femoral vessels is probably due to dystrophic calcification and not to any generalized disturbance of calcium phosphorus metabolism. The raised level of serum acid phosphatase in this case could not be repeated for verification.

The haemorrhages occurring so commonly in the eye can be compared with those occurring spontaneously in the skin as described by Marchesani and Wirz (1931).

The Grönblad-Strandberg syndrome is a degenerative disease affecting the elastic tissue of the skin, lamina vitrea of the eye, and the elastic laminae of the arteries. Further investigations may show that it occurs in other organs also. The visual prognosis is poor as the changes occurring in the macula destroy the central vision, but this may take years to develop.

Summary

A case of angioid streaks and pseudoxanthoma elasticum is described. The literature is briefly reviewed. A previously unquoted article by Marchesani and Wirz (1931), who describe a tear-drop-like haemorrhage characteristic of this disease, is reported. The giant cell occurring in the skin, only described previously by Bodin (1900), was also described by Marchesani and Wirz (1931).

REFERENCES

- BALZER, F. (1884). *Arch. Physiol. norm. path.*, 3 ser., 4, 65.
 BERLINER, M. L. (1933). *Arch. Ophthal.* (Chicago), 10, 709.
 BODIN, E. (1900). *Ann. Derm. Syph. (Paris)*, 4 ser., 1, 1073.
 BOECK, J. (1938). *Z. Augenheilk.*, 95, 1.
 CHAUFFARD, A. (1889). *Bull. Soc. méd. Hôp. Paris*, 3 ser., 6, 412.
 COPPEZ, H., and DANIS, M. (1925). *Bull. Soc. franç. Ophthal.*, 38, 560.
 DARIER, J. (1896). *Mh. prakt. Derm.*, 23, 609.
 DE SCHWEINITZ, G. E. (1896). *Trans. Amer. Ophthal. Soc.*, 7, 650.
 DOYNE, R. W. (1889). *Trans. ophthal. Soc. U.K.*, 9, 128.
 EBERT, R. H. (1943). *Arch. Derm. Syph. (Chicago)*, 48, 75.
 FINNERUD, C. W., and NOMLAND, R. (1937). *Ibid.*, 35, 653.
 GRÖNBLAD, E. (1929). *Acta ophthal. (Kbh.)*, 7, 329.
 ——— (1932). *Ibid.*, 10, Suppl. 1.

- HALLOPEAU and LAFFITTE (1903). *Ann. Derm. Syph. (Paris)*, 4 ser., 4, 595.
- HAGEDOORN, A. (1939a). *Arch. Ophthal. (Chicago)*, 21, 746.
- (1939b). *Ibid.*, 21, 935.
- ISAYAMA, H. (1940). *Acta Soc. ophthal. jap.*, 44, 134.
- KNAPP, H. (1892). *Arch. Ophthal. (N.Y.)*, 21, 289.
- KOFLER, A. (1917). *Arch. Augenheilk.*, 82, 134.
- MARCHESANI, O., and WIRZ, F. (1931). *Ibid.*, 104, 522.
- PLANGE, O. (1891). *Ibid.*, 23, 78.
- ROWLAND, W. D. (1933). *Amer. J. Ophthal.*, 16, 61.
- SANDBACKA-HOLMSTRÖM, I. (1939). *Acta derm.-venereol. (Stockh.)*, 20, 684.
- SCHEIE, H. G., and FREEMAN, N. E. (1946). *Arch. Ophthal. (Chicago)*, 35, 241.
- SCHOLZ, R. O. (1941). *Ibid.*, 26, 677.
- TERRY, T. L. (1934). *Trans. Amer. ophthal. Soc.*, 32, 555.
- VERHOEFF, F. H. (1928). *Trans. Sect. Ophthal. A.M.A.*, p. 243. Cited by Grönblad (1932).
- (1939). *Arch. Ophthal. (Chicago)*, 22, 313.