

Case reports

Displaced stress fracture of the femoral neck in an active amenorrhoeic adolescent

F S Haddad, S Bann, R A Hill, D H A Jones

Abstract

Female athletes in endurance sports are at risk of osteoporosis which predisposes them to femoral neck stress fractures. These require early diagnosis and treatment to avoid catastrophic consequences. (*Br J Sports Med* 1997;31:70-72)

Keywords: femoral neck; stress fracture; amenorrhoeic adolescent.

Stress fractures of the femoral neck are rare injuries in children¹⁻³ and are often not initially considered when assessing hip pain. Patients occasionally persevere with the causative activity increasing the risk of fracture displacement with its associated morbidity of delayed union, non-union, premature physeal closure, and avascular necrosis.^{4,5} Early diagnosis and appropriate treatment are vital to ensure a return to full function.

We present the case of a skeletally immature girl where an interplay between endurance running, amenorrhoea, and possible anorexia nervosa contributed to a stress fracture of the femoral neck. Difficulties in diagnosis and management are discussed and emphasised.

Case report

A 15 year old girl who was a keen runner suffered acute right hip and thigh pain whilst jogging. She had noted no previous pain in that region and recalled no trauma. She was seen and examined by her general practitioner, by a casualty officer, and by an osteopath over the next few days. No radiographs were taken, no firm diagnosis was reached, and she was treated with analgesics, physiotherapy, and manipulations. This did not eradicate her pain but enabled her to walk, albeit with a limp. She could not exercise or attend school.

Six weeks later, whilst swimming, she felt a crack in the right groin and was no longer able to bear weight on her right leg. She was taken back to the Accident and Emergency Department of her local hospital where radiographs revealed a displaced fracture of the neck of her right femur (fig 1). She underwent emergency surgery with decompression of the hip capsule and stabilisation of the fracture with a dynamic hip screw.

She continued to complain of pain, and serial radiographs unfortunately confirmed progressive loss of fixation (fig 2). At this stage, she was referred to our unit.

Further clinical questioning revealed a two year history of a vegan diet, gradual weight loss totalling 8 kg, and primary amenorrhoea. Endocrine work up was, however, unremarkable. Her injury did not appear related to any increase in her weekly running mileage. Review of her initial radiographs suggested an old compression stress fracture of the right femoral neck which had acutely displaced. The initial fixation was deemed unsatisfactory, and was revised to 6.5 mm cancellous screws with cancellous autograft (fig 3). This relieved most of her pain and allowed mobilisation of her hip.

Discussion

The incidence and natural history of stress fractures of the femoral neck in adults have long been recognised.⁶⁻¹⁰ Devas⁷ described two types of stress fracture of the femoral neck. The compression type, commoner in young patients, which appears on the inferior aspect of the femoral neck, is inherently stable and can usually be managed conservatively. The transverse or tension type, which appears as a lucency on the superior aspect of the femoral neck, is very unstable and usually requires internal fixation. Tension stress fractures of the

Department of
Orthopaedics,
Hospital for Sick
Children, Great
Ormond Street,
London WC1N 3JH,
United Kingdom

F S Haddad
S Bann
R A Hill
D H A Jones

Correspondence to:
F S Haddad, 46B Hanover
Gate Mansions, Park Road,
London NW1 4SN.

Accepted for publication
29 October 1996

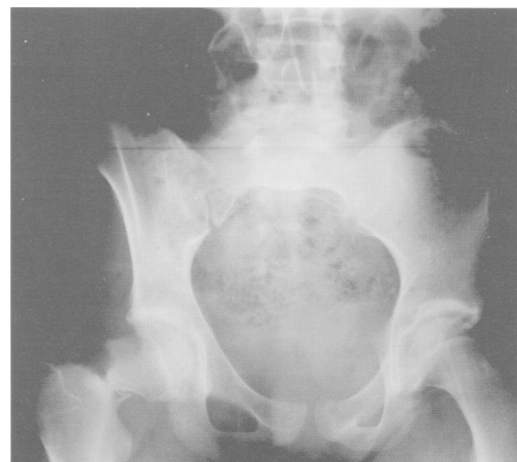

Figure 1 Anteroposterior radiograph of the pelvis showing a displaced compression type stress fracture of the right neck of femur.

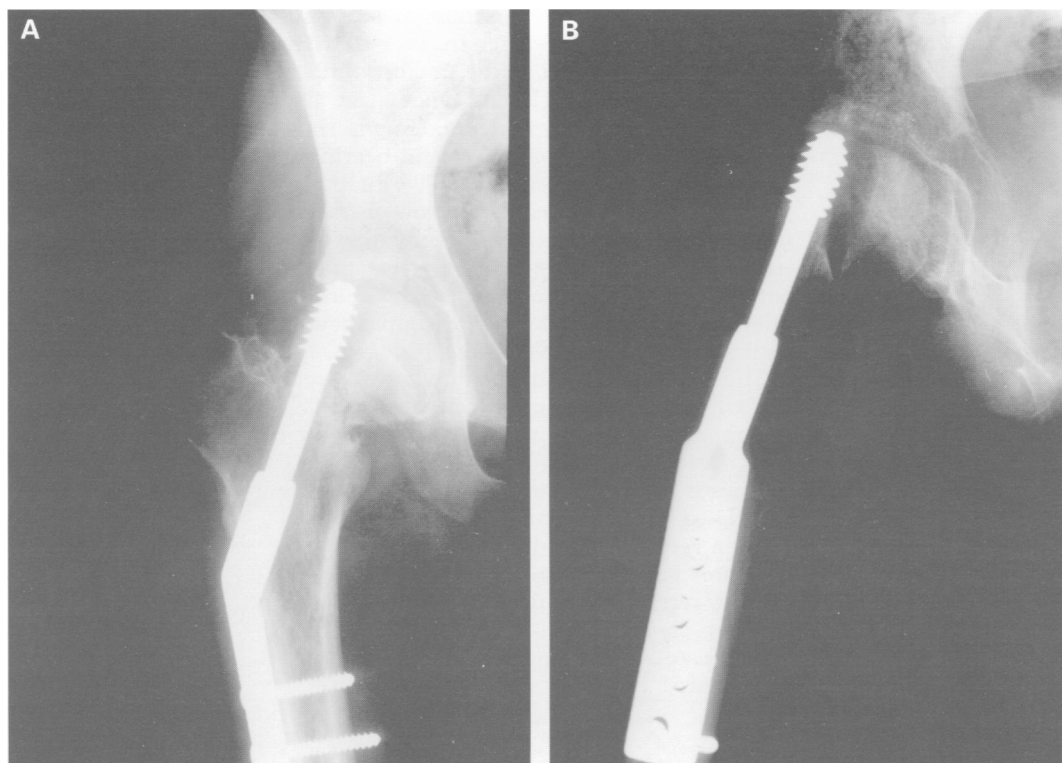


Figure 2 Anteroposterior (A) and lateral (B) radiographs showing failure of fixation with the dynamic hip screw cutting out anterosuperiorly.

femoral neck have not been reported in the skeletally immature.⁵ Fullerton and Snowdy¹¹ expanded on Devas' classification by separating displaced fractures into a different category and subclassifying them in an attempt to define prognosis at an early stage.

Careful history taking with particular reference to recent activities, nutritional status, and menstrual disorders is important as there are initially few clinical signs, and the early radiographic criteria of a stress fracture can be subtle. A high index of suspicion and careful follow up are therefore warranted when assessing a patient with unexplained hip pain. Early diagnosis and treatment are necessary,^{12,13} as displacement leads to significant morbidity and appears to be directly related to the development of avascular necrosis.⁴ Our patient's management would have been significantly easier had radiographs been taken at the first presentation.

In some endurance sports more than 50% of female athletes may be amenorrhoeic. This leads to decreased trabecular bone density and may predispose to stress fractures.¹⁴⁻¹⁷ Anorexia nervosa is also recognised as a cause of decreased bone density and stress fractures.^{18,19} Moreover subclinical eating disorders are present in many endurance athletes and should be addressed.¹⁶ Low calorific intake, excessive dietary fibre, frequent exercise, and delayed menarche probably all contributed to a reduced bone mass and the femoral neck stress fracture in our patient.

Plain film radiographic diagnosis can be difficult in the early stages.²⁰ Bone scans are most sensitive,³ although false negative results have been reported.^{21,22} The radiological differential diagnosis includes osteoid osteoma, chronic

sclerosing osteomyelitis, osteogenic sarcoma, Ewing's tumour, and metastases.²⁰ Follow up radiographs with evidence of healing are usually sufficient, however, to confirm the diagnosis of stress fracture.²³

Once the diagnosis of a femoral neck stress fracture is made, established clinical algorithms can be followed.^{5,11} Compression fractures can be managed with bed rest or

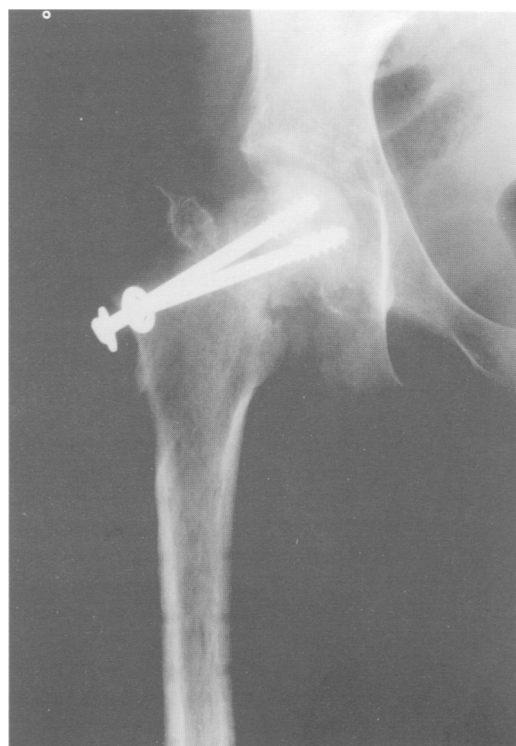

Figure 3 Revised fixation using cannulated screws and bone graft.

non-weight-bearing mobilisation. Cast immobilisation or fixation are necessary when compliance is poor, when the fracture widens, or when union is delayed. Once pain free movement is restored and radiographs show evidence of healing, partial weight-bearing is initiated, and activities gradually increased. Tension fractures necessitate a low threshold for surgical stabilisation. Displaced stress fractures of the femoral neck represent a surgical emergency and require urgent reduction and internal fixation which can be supplemented with vascularised bone graft.²⁴

Stress fractures of the femoral neck are a recognised cause of pain in athletes at all levels of competition and can also occur in children and adolescents. Early recognition of these injuries is important to prevent the morbidity associated with fracture displacement and allow a return to full function.¹³ Preventative measures have been shown to be of benefit in military recruits,^{25,26} and a similar approach at a primary care level is of importance so that appropriate referral and management can be instituted.

- 1 Wolfgang GL. Stress fracture of the femoral neck in a patient with open capital femoral epiphyses. *J Bone Joint Surg* 1977;59A:680-1.
- 2 Miller F, Wenger D. Femoral neck stress fracture in a hyperactive child. *J Bone Joint Surg* 1979;61A:435-7.
- 3 Meaney JEM, Carty H. Femoral stress fractures in children. *Skeletal Radiol* 1992;21:173-6.
- 4 Canale ST. Fractures of the hip in children and adolescents. *Orthop Clin North Am* 1990;21:341-52.
- 5 St Pierre P, Staheli LT, Smith JB, Green NE. Femoral neck stress fractures in children and adolescents. *J Pediatr Orthop* 1995;15:470-3.
- 6 Ernst J. Stress fracture of the neck of the femur. *J Trauma* 1964;4:71-83.
- 7 Devas MB. Stress fractures of the femoral neck. *J Bone Joint Surg* 1965;47B:728-38.
- 8 Bingham JAW. Stress fracture of the femoral neck. *Lancet* 1945;2:13-14.
- 9 Katsas DS. Stress fracture of the femoral neck in young adults. *J Bone Joint Surg* 1981;63B:33-7.
- 10 Milgrom C, Giladi M, Stein M, Kashtan H, Margules Y, Chisi R *et al*. Stress fractures in military recruits. *J Bone Joint Surg* 1985;67B:732-5.
- 11 Fullerton LR, Snowdy HA. Femoral neck stress fractures. *Am J Sports Med* 1988;16:365-7.
- 12 Dorne HL, Lander PH. Spontaneous stress fractures of the femoral neck. *AJR Am J Roentgenol* 1985;144:343-7.
- 13 Johansson C, Ekenman I, Tonqvist H. Stress fractures of the femoral neck in athletes: the consequence of a delay in diagnosis. *Am J Sports Med* 1990;18:524-8.
- 14 Wilson JH, Wolman RL. Osteoporosis and fracture complication in an amenorrhoeic athlete. *Br J Rheumatol* 1994;33:480-1.
- 15 Drinkwater BL, Nilson K, Chesnut CH, Bremner WJ, Shainholz S, Southworth MB. Bone mineral content of amenorrhoeic and eumenorrhoeic athletes. *N Engl J Med* 1984;311:277-81.
- 16 Wolman RL. Bone mineral density in elite female athletes. *Ann Rheum Dis* 1990;49:1013-16.
- 17 Leinberry CF, McShane RB, Stewart WG. A displaced subtrochanteric stress fracture in a young amenorrhoeic athlete. *Am J Sports Med* 1992;20:485-7.
- 18 LaBan MN, Wilkins JC, Sackeyfio AH, Taylor RS. Osteoporotic stress fractures in anorexia nervosa: etiology, diagnosis and review of four cases. *Arch Phys Med Rehabil* 1995;76:884-7.
- 19 Kaplan FS, Pertschuck MJ, Fallon M, Haddad J. Osteoporosis and hip fracture in a young woman with anorexia nervosa. *Clin Orthop* 1986;212:250-4.
- 20 Pavlov H. Roentgen examination of groin and hip pain in the athlete. *Clin Sports Med* 1987;6:829-43.
- 21 Keene JS, Lash EG. Negative bone scan in a femoral neck stress fracture. *Am J Sports Med* 1992;20:234-6.
- 22 Sterling JC, Webb RF, Myers MC, Calvo RD. False negative bone scan in a female runner. *Med Sci Sports Exerc* 1993;25:179-85.
- 23 Daffner RH, Pavlov H. Stress fractures: current concepts. *AJR Am J Roentgenol* 1992;159:245-52.
- 24 Mendez AA, Eyster RL. Displaced non union stress fracture of the femoral neck treated with internal fixation and bone graft. *Am J Sports Med* 1992;20:230-3.
- 25 Bargren JH, Tilson DH, Bridgeford OE. Prevention of displaced fatigue fractures of the femur. *J Bone Joint Surg* 1971;53A:1115-17.
- 26 Zahger D, Abramovitz A, Zeilovsky L, Israel O, Israel P. Stress fractures in female soldiers: an epidemiological investigation of an outbreak. *Mil Med* 1988;153:448-50.

Ring avulsion injuries and the basketball player

B R Pynn, T P Bartkiw, H M Clarke

Abstract

As basketball increases in worldwide popularity, more epidemiological data on injury rate and type will be documented. A serious ring avulsion injury (Urbanik Class I) is here reported in an adolescent incurred while attempting a slam dunk. The management of this injury is discussed as well as safety concerns for coaches and supervisory staff.

(*Br J Sports Med* 1997;31:72-74)

Keywords: basketball injury; ring avulsion; finger; safety.

In basketball, all players are required to perform a magnitude of skilled activities involving sudden and rapid changes in speed and direction.¹ A combination of unprotected exposure with unpredictable changes in force plays a large part in the well documented increasing incidence of injuries during basket-

ball play, at both the professional and recreational level.^{1,2} Ankles are the most injured joint of the body during basketball play, representing approximately 18-33% of all injuries.^{3,4} Finger injuries account for approximately 11-43% of all injuries, with contusions and sprains of the proximal interphalangeal and metacarpophalangeal joints representing 90% of all hand injuries invoked.^{1,3,4} Rarely reported are the unusual lacerations occurring from slam dunking the basketball, especially those requiring surgical intervention.⁵ No other reports of avulsion injuries related to basketball in a single digit could be found. A case is reported here of a ring avulsion injury incurred during slam dunking the basketball.

Case report

The patient, a 6 foot, 180 pound right handed 16 year old boy, had been playing basketball during high school gym class and attempted to slam dunk the basketball. As he was coming back down, he caught his ring in the netting of

Hospital For Sick
Children, Toronto,
Ontario, Canada
B R Pynn
T P Bartkiw
H M Clarke

Correspondence to:
Dr H M Clarke.

Accepted for publication
14 November 1996