

# Lesions of the Segmental and Lobar Hepatic Ducts

WILLIAM P. LONGMIRE, JR., M.D., RONALD K. TOMPKINS, M.D.

Despite reports to the contrary, unobstructed drainage of 50% of an otherwise normal liver through either the right or left uninfected hepatic duct is adequate to restore normal liver function, even if the obstructed lobe remains in place. An undrained liver lobe, if present, may require no further treatment. As long as it is completely obstructed and uninfected, it will undergo a progressive asymptomatic atrophy. Cholangitis invariably develops behind a partial lobar ductal obstruction, producing jaundice, pruritis, and fever. Unless unobstructed, uninfected biliary flow can be achieved through a segmental or lobar duct, it is better that the duct be completely obstructed and the affected liver parenchyma allowed to atrophy, provided there is normal biliary flow from the residual 50% of liver. This concept is important in the management of injured anomalous segmental or lobar hepatic duct and in the palliative treatment of bile duct carcinoma. Localized intrahepatic infections communicating with abnormal biliary ducts will require hepatic resection of the infected parenchyma and ducts for cure. The abnormality may be saccular dilatation of the intrahepatic ductal system with abscess formation or intrahepatic abscess associated with stenosis of the ductal system from trauma to the duct, to the duct and liver, or to retained intrahepatic stones. Diffusely situated intrahepatic abscesses secondary to ductal abnormalities can be treated with systemic antibiotics, local drainage of a dominant abscess, and efforts to improve biliary drainage.

IT HAS BEEN DEMONSTRATED in man that, after major resection of the liver, adequate hepatic function can be maintained by as small a residual segment of liver tissue as approximately one-fourth of the organ's normal volume.<sup>16,19,27</sup> The effects of obstruction of a segmental or lobar duct that drains an otherwise intact functioning human liver unit (segment or lobe), however, are not precisely known, and the limited pertinent reports in the literature are confusing and, at times, apparently contradictory.

Localized biliary obstruction, however, is but one of

---

Presented at the Annual Meeting of the American Surgical Association, Quebec City, Quebec, May 7-9, 1975.

Supported in part by the James G. Greims Trust Fund.

*From the Department of Surgery, UCLA School of Medicine, Los Angeles, California 90024*

---

the effects of a variety of clinical conditions that may involve either the intra- or the extrahepatic lobar or segmental hepatic ducts, producing obstruction, biliary infection, or external biliary fistula, either singly or in combination. The hepatic and systemic effects of these lesions and their management are the focus of this report.

## Anatomy

The functioning unit of the intrahepatic biliary system was first clearly presented by Hjortsjo,<sup>13</sup> who, in 1948, reported, on the basis of observations on corrosion casts, that the hepatic arteries, bile ducts, and branches of the portal vein had a segmental distribution within the liver. The studies of Healey and Schroy,<sup>12</sup> in 1953, also supported this concept and demonstrated that every major artery of the liver supplies a definite segment of hepatic parenchyma and that every bile duct drains a definite segmental area of the liver. Within the normal liver, other than the regular confluence of smaller ducts into larger ones, there is no anastomosis of bile ducts or collateral bile exit pathways to develop in the face of obstruction.

McArthur et al.<sup>21</sup> studied in detail the extraparenchymal hilar hepatic ducts proximal to their confluence to form the common hepatic duct, noting that a 3 cm section of left hepatic duct regularly is present outside of the liver parenchyma from the site where the duct is formed by the confluence of its two major branches until it joins the right hepatic duct. The extraparenchymal right hepatic duct was usually less than 1 cm in length.

The biliary system below the hepatic duct confluence, the portion of the ducts most often exposed to manipulation during the performance of cholecystectomy, the

second most common intra-abdominal surgical procedure in America, abounds with anatomical variations. As Cole<sup>5</sup> commented a number of years ago: "In no region of the body are anomalies so common as in the bile ducts and adjacent blood vessels. It is, therefore, impossible to present any pattern as the 'normal'; a composite of specimens least abnormal becomes the substitute for normal anatomy in this area." In a series of 200 dissections of the extrahepatic bile ducts, Flint<sup>7</sup> found only 69 to conform with the arrangement of vessels and ducts as given in textbooks of anatomy. The most common anomaly involving the hepatic ducts was that of aberrant or accessory right hepatic ducts encountered in 29 examples. In 9 cases, the aberrant hepatic duct ran from the right lobe into the right hepatic duct or into the proximal portion of the common hepatic duct where it was high enough in the hilus of the liver that injury during cholecystectomy was unlikely. The aberrant right hepatic duct entered the lower portion of the common hepatic duct or the junction of the cystic and common duct in 19 cases at a point where it might readily be injured during cholecystectomy unless the area were dissected meticulously. In one case the aberrant duct entered the cystic duct (Fig. 1).

Flint stated that the size of these aberrant ducts varied: "The smallest is only large enough to admit a good sized bristle. The largest is as big as the right hepatic duct. The most common is half way between these limits, that is to say, it is quite a considerable duct." Such aberrant hepatic ducts have generally been reported to occur in 10% to 18% of cases<sup>1,23,24</sup> and to have a diameter that approximates that of the cystic duct.<sup>1</sup>

A second anomaly of the hepatic ductal system of major concern to the surgeon is a low confluence of the left and right hepatic ducts, either with or without the cystic duct entering the right hepatic duct (Fig. 2). This arrangement was found in one-fourth of the major duct anomalies identified by Daseler et al.<sup>6</sup>

The unrecognized division of a small duct passing directly from the liver into the gallbladder has been listed for many years as one of the principal indications for the use of drains after cholecystectomy. Despite recent studies that have questioned the existence of such congenital cholecystohepatic ducts, small open ducts have been well documented in the bed of the gallbladder, passing directly into the liver parenchyma after cholecystectomy.<sup>14,26,29,34</sup> Goor and Ebert<sup>10</sup> reported the division during cholecystectomy with reanastomosis of an aberrant hepatic duct that ran from the right lobe into the common hepatic duct within the wall of the gallbladder. Thus, it seems that small segmental ducts do, on rare occasions, course from the liver parenchyma in intimate contact with the wall of the gallbladder into either the gallbladder itself or into the ductal system and that these ducts may

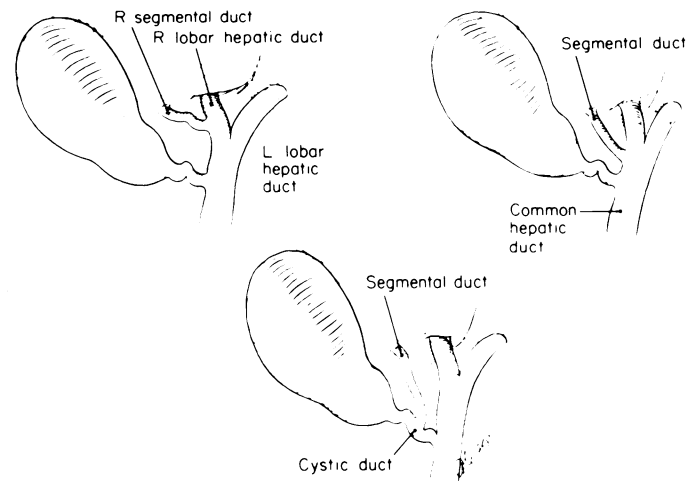


FIG. 1. Common anomalies of extrahepatic segmental and lobar ducts of surgical importance.

be severed during cholecystectomy (Fig. 3). It has been repeatedly expressed that free bile does not appear in the bed of the gallbladder to alert the surgeon that such a duct has been divided.

### Experimental Pathophysiology

Braasch et al.<sup>3</sup> interrupted from one to 5 of the 7 segmental hepatic ducts of the dog and performed a variety of hepatic tests. They found that the extent of deviation from normal was related to the fraction of the total bile outflow obstructed. Serum bilirubin was least affected. Of 21 animals studied, in only four did the serum bilirubin concentration rise above 1 mg/100 ml, and it was necessary to interrupt 3, 4, or 5 ducts in these animals. Serum glutamic oxaloacetic transaminase (SGOT), serum glutamic pyruvic transaminase (SGPT), and alkaline phosphatase concentrations showed the greatest abnormalities. These tests returned to normal in 2 to 3 months' time in most of the animals. Other abnormal hepatic tests gradually returned to normal as the

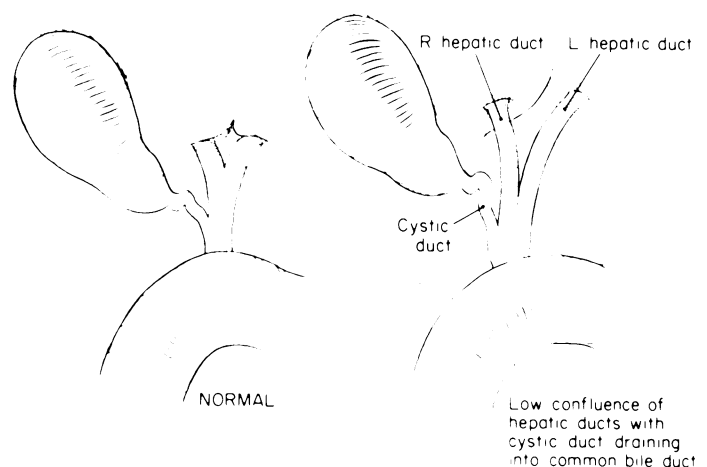


FIG. 2. Low confluence of hepatic ducts may lead to injury of right hepatic duct during cholecystectomy.

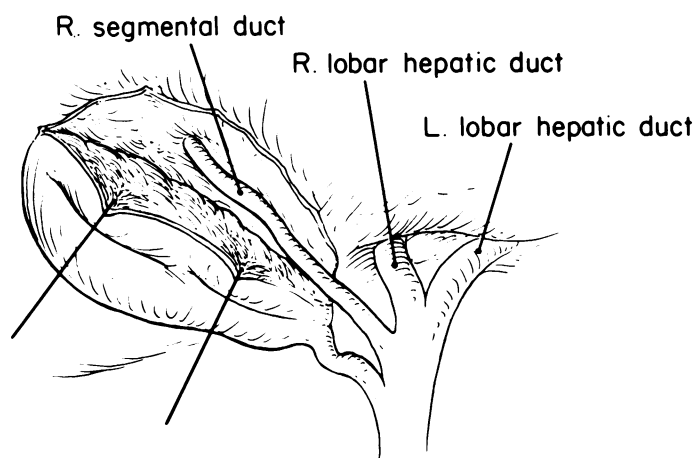


FIG. 3. Anomalous segmental duct in bed of gallbladder that may be injured during cholecystectomy.

obstructed liver parenchyma atrophied and the unobstructed liver underwent hyperplasia. Unobstructed lobes were found to double their weight after obstruction of approximately 40% to 60% of the biliary drainage system. In earlier studies,<sup>11,22</sup> which may have lacked sensitive laboratory test techniques, ligation of up to 80% of the biliary outflow system was found to result in increased urinary bile excretion but without a concomitant increase in serum bilirubin.

### Clinical Reports

Clinically, pruritis, the most distressing symptom of chronic uninfected biliary obstruction, is generally related to the degree of hyperbilirubinemia, but the extent of ductal obstruction necessary to produce a clinically significant hyperbilirubinemia in man has not been clearly defined. Likewise, factors other than obstruction have not been fully evaluated, either from the standpoint of their relationship to the degree of hyperbilirubinemia or with respect to their role in the production of pruritis and associated disabling clinical symptoms, including the eventual serious deterioration of hepatic function. Pruritis is generally thought to be caused by the irritation of cutaneous sensory nerves by retained bile salts, and its intensity has been related to the concentration of bile salts in the system. Sherlock<sup>30</sup> questioned this assumption and pointed out that current information merely indicates that itching is caused by some substance normally eliminated in the bile. That itching disappears when liver cells fail suggests that the substance is manufactured by the liver.

Stafford and Issacs<sup>32</sup> reported upon two elderly patients (70 and 75 years of age) with calculous obstruction of the left hepatic duct accompanied by mild jaundice, congestive heart failure, and, in the second case, cholangitis: (Case 1, serum bilirubin, 2.3 mg/100 ml, alkaline phosphatase, 18 units; Case 2, serum bilirubin, 2.3

mg/100 ml, alkaline phosphatase, 24.6 units). It was their conclusion that jaundice occurred because the functional reserve of the liver suffered a double impairment from blockage of the left hepatic duct and congestive heart failure. It is noteworthy that the jaundice in one patient cleared after digitalization, bed rest, and probable subsidence of the cholangitis before operative relief of the duct obstruction.

Cattell and Braasch,<sup>4</sup> in their report of difficult repairs of benign strictures of one or both hepatic ducts, commented that the symptomatology in patients in whom only one hepatic duct is obstructed is different from the classical picture of common duct obstruction in that the jaundice is less intense, pruritis is a prominent feature, and the urine is dark but the feces remain normal in color. They included in their series 11 instances in which the left hepatic duct alone could be located and anastomosed, either to the lower end of the duct or to the jejunum. Recognizing the uncertainties of such difficult reconstructions, it is important to note that, at the time of their report, three patients with only a functioning left hepatic duct were alive with satisfactory results more than 3 years following operation.

Braasch and Preble<sup>2</sup> later reported in abstract on 4 of their cases and an additional 3 cases from the literature of a specific syndrome associated with the obstruction of a single hepatic duct, without significant decompression by internal or external fistula and characterized by jaundice, dark urine, stools containing bile pigment, and unilateral enlargement of the obstructed lobe of the liver. They postulated that the obstructed lobe produces an altered bilirubin "which the unobstructed lobe secretes with notable inefficiency." They suggested that hepatic lobectomy might be useful in the treatment of unilateral obstruction from benign stricture. One year later, Mistilis and Schiff<sup>25</sup> reported such a jaundiced patient with malignant unilateral left hepatic duct obstruction in which the jaundice was only temporarily reduced by drainage of the right hepatic duct but relieved after removal of the obstructed left lobe. They commented: "Experience in this case confirms previous reports of the occurrence of jaundice in patients with unilateral hepatic duct obstruction. While regurgitation of bile from the obstructed lobe is the factor apparently responsible for the development of jaundice, the persistence of icterus in spite of adequate bile drainage from the unobstructed lobe and its disappearance following surgical removal of the affected lobe raises the question of whether the human liver is able to excrete conjugated bilirubin delivered to it."

Based on the observation of 4 patients with strictures of bile ducts of a segment or lobe, Braasch et al.<sup>3</sup> concluded that humans respond in a manner comparable to that observed in dogs, that is, elevation of serum bilirubin

TABLE 1. *Segmental or Hepatic Bile Duct Injury Without Infection*

Patient	Cause	Duct Injured	Treatment	Result	Remarks
E.K.	Cholecystectomy	Common hepatic	L. hepatico-jejunostomy	Well	R. hepatic duct not reconstructed
W.E.	Cholecystectomy	R. dorsal caudal	Ligated?	Well	Dorsal-caudal segment not seen on cholangiogram
A.A.	Cholecystectomy	Ventral-cranial segmental Common hepatic. Dorsal-caudal segmental	End-to-end anastomosis  Hepatico-jejunostomy Ligation	Well	External biliary fistula closed spontaneously

with major portions of the bile outflow obstructed, atrophy of obstructed lobes, and hypertrophy of unobstructed lobes. The inference is made that obstruction of a large segmental duct draining one-third of the liver substance or of either the right or left hepatic duct is sufficient to cause a significant elevation of the serum bilirubin. Their cases, however, were all quite complicated, and the long histories of repeated operations, infection and cholangitis, partial degrees of obstruction, and varying degrees of generalized depression of hepatocellular function make difficult evaluation of the sole effects of segmental or lobar duct obstruction.

George<sup>8</sup> reviewed the treatment of carcinoma of the bile ducts at the confluence of the right and left hepatic ducts and commented that "it is essential to relieve the obstruction to the right lobe of the liver, as relief of the left lobe only will not cause effective disappearance of jaundice." Such a statement, however, does not reflect the true anatomical equality of the parenchymal liver mass of the right and left lobes. Our experience demonstrates that drainage of the left hepatic duct alone will relieve jaundice (c.f. Case H.C., Section on Hepatic Duct Carcinoma).

From these somewhat conflicting reports of others, together with our own experience with isolated segmental or lobar hepatic duct obstruction, it is apparent that four factors are of paramount importance in the determination of the clinical course of a patient with such a condition: 1) degree of obstruction, i.e., complete, partial, slight; 2) extent or percentage of hepatic parenchyma with obstructed drainage; 3) presence or absence of infection in the ductal system; 4) condition of the unobstructed liver.

Fortunately, the surgeon is infrequently concerned with problems related to lobar hepatic ducts, but it is important to be acquainted with lesions that involve these structures and to have some knowledge of the basic principles to be used in their treatment.

### Classification of Lesions

Based on a review of more than 50 patients seen at the UCLA Hospital, segmental and lobar hepatic duct lesions have been classified into the following groups: 1) Segmental or hepatic bile duct injury without infection; 2) Segmental or hepatic bile duct injury with infection; 3) Congenital hepatic duct lesions; 4) Intrahepatic stones; 5) Hepatic duct carcinoma.

#### *Segmental or Hepatic Bile Duct Injury Without Infection*

If, during the course of cholecystectomy, a segmental duct or the right hepatic duct is injured, what can be the patient's anticipated course? Kune<sup>15</sup> cautions that "if the surgeon encounters more than two ducts issuing from the liver, on no account should he divide or ligate any of them, assuming it to be an accessory duct, because serious consequences will follow." Longo and Masumana<sup>20</sup> found aberrant hepatic ducts in 10% of their cases studied with cholangiograms. They concluded that aberrant bile ducts occur more frequently than is generally believed, that little harm may result should a small aberrant duct be injured during cholecystectomy, but that if a larger duct is injured and not detected and repaired, bile peritonitis will result.

Smith<sup>31</sup> recommends that small or filament-like accessory ducts should be dissected free, ligated, and divided, but sizable ducts (especially when they are approximately the size of the cystic duct) should be assiduously preserved.

Goor and Ebert<sup>10</sup> repaired end-to-end over a T-tube a 2 mm aberrant right segmental duct imbedded, in part, in the wall of the gallbladder that had been severed during cholecystectomy. The patient's postoperative course was uneventful. Bile drainage from the T-tube was 100 to 150 cc per day in the repaired duct, and a postoperative cholangiogram was said to have demonstrated a patent anastomosis in this duct that drained a major portion of the right hepatic lobe.

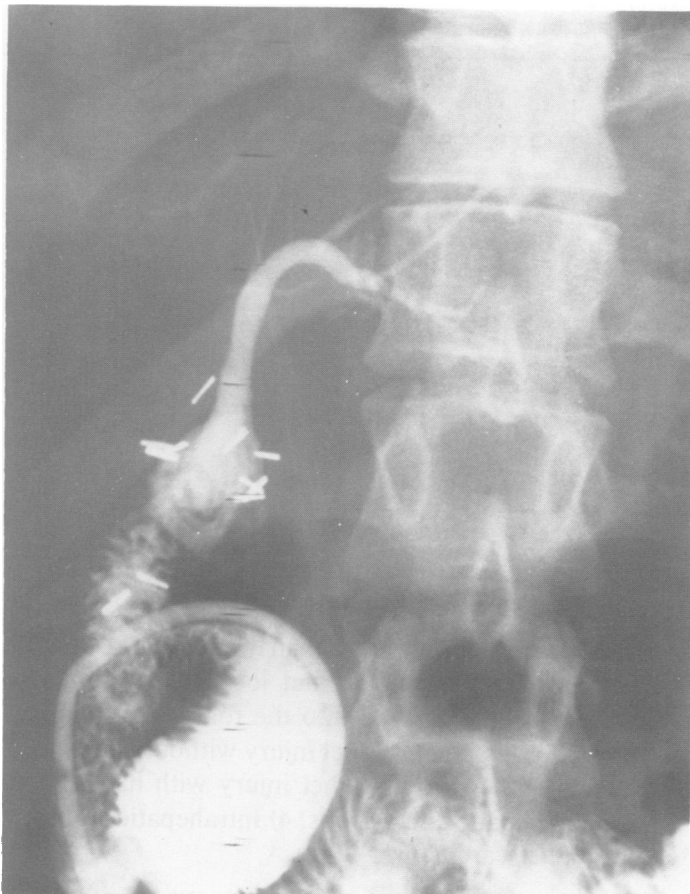

FIG. 4. Injection of dye into Roux-en-Y jejunal limb filling left hepatic duct system. There is no communication with right hepatic duct. Serum bilirubin returned to normal without further operation.

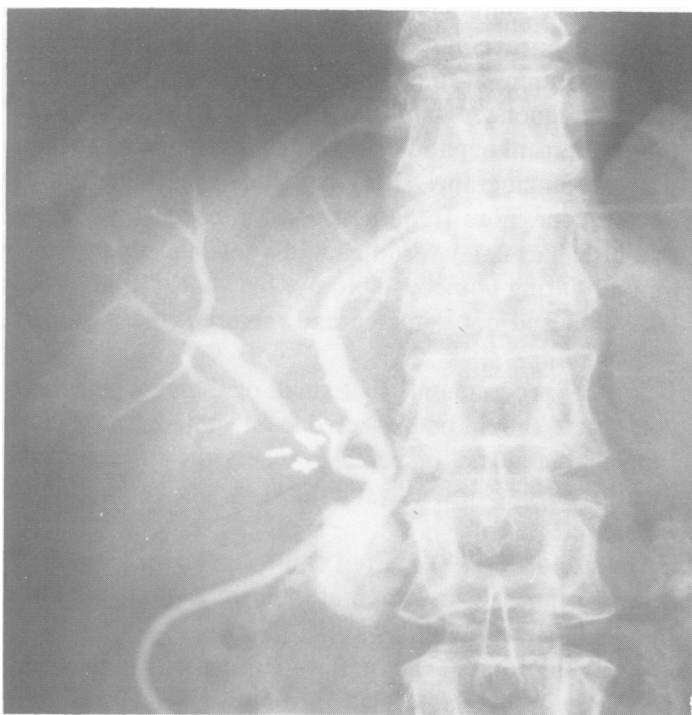

FIG. 5. Postoperative cholangiogram demonstrating T-tube in left hepatic duct and very low confluence of left and right hepatic ducts. Right hepatic duct (ventral-cranial segment) has been reanastomosed. Dorsal-caudal duct system not visualized.

A trying but eventually successful outcome was achieved by quite a different form of management reported by Pollock and Tabrisky<sup>28</sup> in an injury to a right anterior segmental duct. An unrecognized division of the duct during cholecystectomy led to a difficult postoperative course complicated by bile peritonitis that gradually cleared with drainage of the subhepatic space. Daily drainage of 800 cc from the severed right segmental duct during the first week steadily decreased to 250 cc per day by the fifth week and then ceased spontaneously without elevation of the bilirubin or other signs of biliary obstruction.

Three patients seen at the UCLA Hospital illustrate the manifestations of isolated injuries to a right segmental or lobar duct and the management of these lesions (Table 1).

**Case 1 (E.K.):** A 23-year-old woman had suffered right upper quadrant pain, jaundice, and fever 3 days after cholecystectomy performed on August 29, 1973. Two weeks later, a choledochojejunostomy Roux-en-Y was performed for obstruction of the common hepatic duct. The jaundice decreased, but the alkaline phosphatase continued to increase. A tube cholangiogram demonstrated good filling and drainage of the left hepatic duct but no visualization of the right hepatic ductal system (Fig. 4). On admission to the UCLA Hospital, her temperature was normal. There was no drainage from the right upper quadrant. The abdomen was soft, and there were active bowel sounds. Laboratory values were as follows: Prothrombin time was greater than 100%, hematocrit 29.3%, white blood cell count was 6500/mm<sup>3</sup>, total serum bilirubin 4.8 mg/100 ml, direct 4.2 mg/100 ml, SGOT 163 units, SGPT 245 units, protein 7.4 gm/100 ml, albumin 2.8 gm/100 ml, alkaline phosphatase 1,286 King-Armstrong (K-A) units. During a week of observation in the hospital, her condition remained stable, and results of hepatic function tests slowly improved. On October 30, 1973, 7 weeks after the left hepatic jejunostomy, the total serum bilirubin was 1.6 mg/100 ml and alkaline phosphatase was 574 K-A units. During the past year, she has led a normal life without further symptoms related to her biliary system.

**Comment:** Secondary reconstruction of the biliary system after cholecystectomy resulted in drainage of the left hepatic system only. As moderate jaundice readily receded and the patient was otherwise asymptomatic without evidence of infection, the decision was made to allow the right hepatic duct to remain obstructed in anticipation of atrophy of the right lobe and compensatory hypertrophy of left lobe.

**Case 2 (W.E.):** A 58-year-old woman had undergone a cholecystectomy on November 5, 1973, during which an anomalous right hepatic duct draining the cystic duct and joining the left hepatic duct at the level of the pancreas was divided. The right hepatic duct, which measured 3 mm in diameter, was repaired immediately in an end-to-end fashion. Postoperative cholangiograms (Fig. 5) through a T-tube placed in the long left hepatic duct demonstrated an area of constriction at the site of the anastomosis, with dye filling only the ventral-cranial segment of the right hepatic ductal system. Dye drained back slowly but adequately from this segment. The left ductal system was normal.

When seen at the UCLA Hospital on January 3, 1974, the patient had numerous minor complaints similar to those expressed before operation; however, she had maintained her weight, the stools were normal, and there was no history of jaundice, chills, or fever. *Proteus mirabilis* organisms were cultured from the bile. Laboratory values were as follows: Total protein, albumin, calcium, phosphorous, cholesterol, glucose, uric acid, creatinine, and lactic dehydrogenase (LDH) were within normal limits. The alkaline phosphatase was elevated to 128 units, the serum bilirubin to 1.7 mg/100 ml, and SGOT to 156 units.

Hematocrit was 39%, hemoglobin was 13.1 gm/100 ml, white blood cell count was 5900/mm<sup>3</sup> and urine was positive for bilirubin.

Despite the apparent defect in the right hepatic duct and the inability to demonstrate the dorsal-caudal segment of the right lobe on cholangiogram, it was elected to remove the T-tube and to observe her course. By January 20, 1974, the alkaline phosphatase had dropped to 41 units and the serum bilirubin to 0.3 mg/100 ml. She has remained well since that time.

*Comment:* Absence of the ducts of the right dorsal-caudal segment on the postoperative cholangiogram suggests that this duct had an anomalous, unrecognized course and that it was ligated and divided but not repaired. Although this patient had one segmental duct ligated and the lumen of another segmental duct compromised by a circumferential repair, minimal changes in hepatic function were demonstrated, and these had reverted to normal in less than 3 months. The anastomosis of a small bile duct, such as was done in this case, may well result in stricture, but if such occurs without infection, it will be without clinical symptoms. Therefore, the T-tube was removed promptly from the ductal system to prevent the exacerbation of the infection by a foreign body. Laboratory tests suggest that the anastomosis has functioned adequately to date.

**Case 3 (A.A.):** A 40-year-old woman had undergone cholecystectomy on January 7, 1971, at which time the common hepatic duct, which measured only 2-3 mm in diameter, was mistakenly identified as an accessory bile duct or a small blood vessel and divided. Upon proper recognition of the duct, it was reanastomosed over a small T-tube end-to-end to a diminutive (2 mm) common bile duct, one centimeter below the confluence of the left and right hepatic ducts. Due to a persistent extended drainage of large amounts of bile, acholic stools, and low grade fever, a second exploration was performed January 31, 1971, and a choledochojejunostomy was performed. Intermittent attacks of jaundice and cholangitis persisted until her admission to the UCLA Hospital on May 1, 1971. At reexploration 2 days later, the stenosed choledochojejunal anastomosis was resected, and the common hepatic duct was anastomosed to a Roux-en-Y limb fashioned out of the jejunal loop. Of interest, however, during the dissection was the identification of a 3 mm bile-containing duct opening into the right lobe of the liver dorsal to the hepatoduodenal ligament. X-ray studies made after the injection of dye into this duct demonstrated the ductal system of the dorsal-caudal segment of the right lobe (Fig. 6A). A cholangiogram made by injection of dye through a catheter in the common hepatic duct demonstrated the left hepatic duct and the ventral-cranial segment of the right lobe (Fig. 6B). Fearing that a separate anastomosis of this small duct to the jejunum might become stenotic and infected and as there was no evidence of infection in the segment at this time, the decision was made to ligate the duct and to allow the segment to atrophy.

External bile drainage of approximately 300 cc per day from the site of the ligated duct began 1 week after operation and continued for 3 weeks before ceasing spontaneously. The serum bilirubin which was 9 mg/100 ml before operation, rose to 14.4 mg/100 ml the day after operation, decreased to 5.0 mg/100 ml 2 weeks after operation, and returned to normal levels 3 weeks later. The SGOT, which was 78 units prior to operation, rose to a high of 130 units the day after operation and fell to 51 at the time of discharge from the hospital. The alkaline phosphatase, which was 22.5 K-A units prior to operation, fluctuated between 15 and 22, falling to 15.5 K-A units at the time of discharge. In the 3½ years since the duct anastomosis was revised and the external bile fistula closed spontaneously, the patient has been well.

*Comment:* The anomalous arrangement of the ducts with an unusually small extrahepatic ductal system and an aberrant segmental duct led to an inadvertent division of the common hepatic duct. The third repair with a choledochojejunostomy has functioned satisfactorily for 3½ years. A biliary fistula, which developed from the aberrant segmental duct despite a careful pursestring suture ligation, closed spontane-

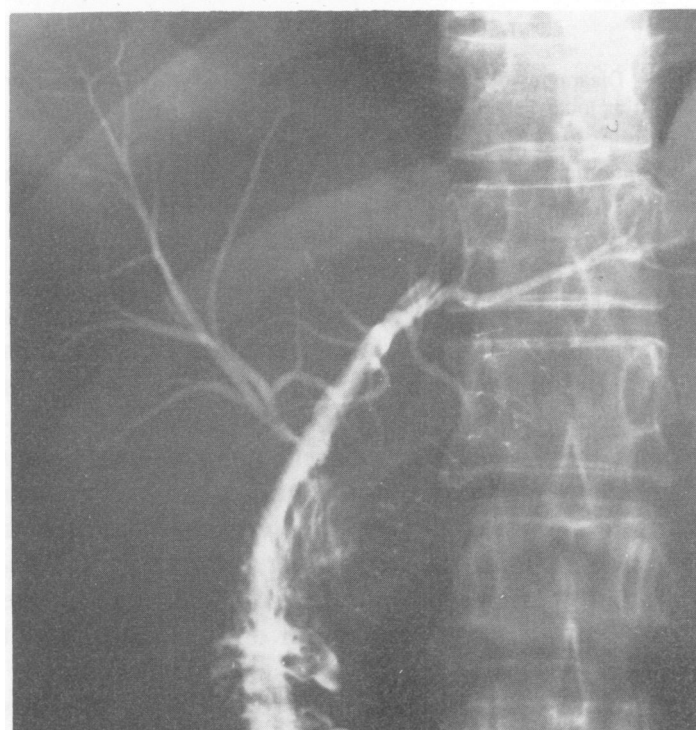
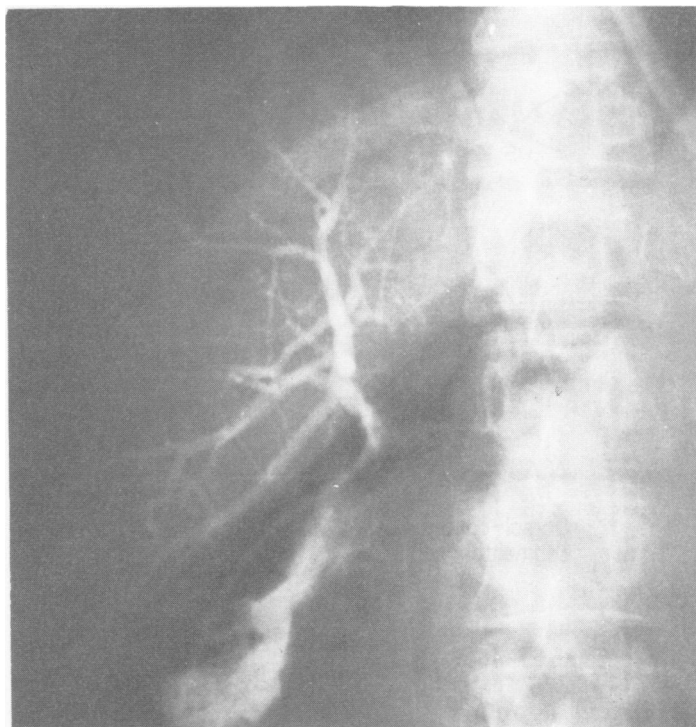


FIG. 6. (Patient A.A.) A, Dye injection at operation into right segmental duct visualized dorsal-caudal segment of right lobe. Duct was ligated. B, Dye injection via catheter after anastomosis of common hepatic duct to Roux-en-Y jejunal limb visualized left hepatic and right ventral-cranial segment duct systems.

ously, as expected, after draining approximately 300 cc per day for 5 weeks. Closure of the duct and subsequent atrophy of the segment was the course of management selected rather than reanastomosis. Adequate drainage should be provided when such ducts are ligated since necrosis of the end of the ligated duct with subsequent bile leakage is not uncommon. An anastomosis of this small duct to the jejunum might well have become stenotic, and had the ductal system become chronically infected behind the stenosis, resection of the liver

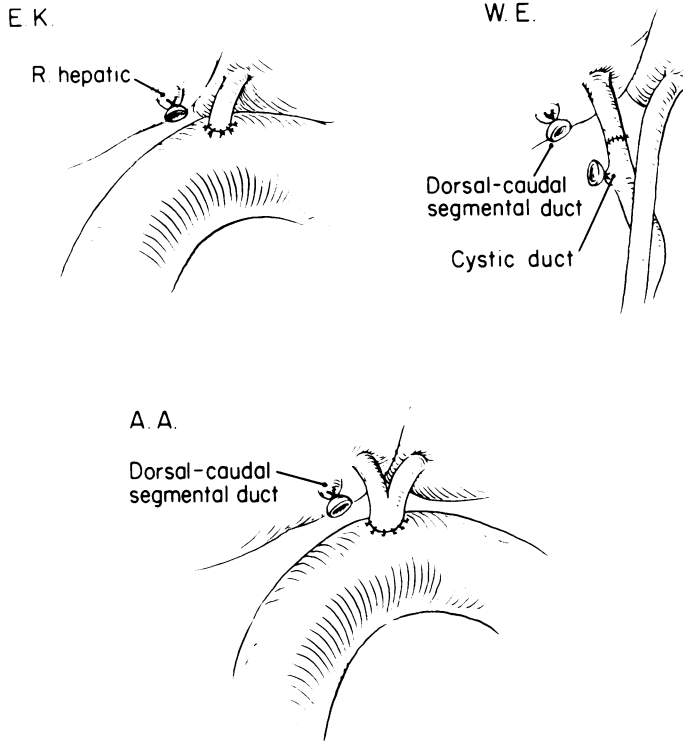


FIG. 7. Diagrammatic summary of three patients with injuries of segmental or lobar hepatic ducts.

segment might have been required to eradicate the intrahepatic infection.

### Discussion

#### *Segmental or hepatic bile duct injury without infection.*

In at least two patients (Fig. 7), a confusing anomalous arrangement of the extrahepatic ductal system with an aberrant right segmental hepatic duct led to inadvertent ductal injury. In both patients, a right dorsal-caudal segmental duct was ligated, with temporary external biliary fistula in one but with eventual healing and normal liver function in both. As there was no external drainage or infection, no further attempt was made to treat the moderate constriction at the site of end-to-end repair in the right ventral-cranial segmental duct of one patient (W.E.).

In the first patient (E.K.), normal liver function was regained, and she was clinically well 6 weeks after an hepaticojejunostomy which restored bile flow only from the left hepatic duct.

These cases demonstrate that complete obstruction of one-quarter to one-half of the biliary drainage system is quite well tolerated as long as there is no external bile fistula or cholangitis and as long as the drained hepatic parenchyma has essentially normal function. The initial and postoperative management of patients with segmental or lobar hepatic duct injury is outlined in Table 2.

#### *Segmental or Hepatic Bile Duct Injury With Infection*

Persistent partial stenosis of an injured segmental or

lobar hepatic duct, particularly if the duct has been anastomosed to the alimentary tract, invariably leads to bile stasis, sludging, infection, and bouts of clinical cholangitis with fever, pain, jaundice, and eventual reoperation. Dilatation and thickening of the wall of the duct may permit a more accurate reconstruction at the second operation than was possible at the first, and if adequate unobstructed biliary flow can be reestablished through the duct, the infection will be eliminated. On the other hand, if the cholangitic infection persists behind a partially obstructed duct, infected duct saccules and parenchymal abscesses develop, and an appropriate hepatic resection usually will be required to eradicate the infection.

High strictures that involve the confluence of the hepatic ducts require individual reconstruction of the left and right hepatic ducts. The right side has a particular proclivity to persistent stenosis because the right duct bifurcates within a short distance above the confluence into its smaller branches. Its very short extrahepatic course makes it technically difficult to create a satisfactory biliary-enteric anastomosis. Therefore, intrahepatic abscesses are most likely to occur in the right lobe in patients with long-standing obstruction and infection (Table 3).

**Case 1 (A.O.):** A 47-year-old woman gave a history of repeated bouts of biliary obstruction and cholangitis following a cholecystectomy in 1949. In January, 1966, a stone was said to have been removed from her common duct. An external biliary fistula and repeated subphrenic abscesses which developed postoperatively were demonstrated to communicate with the right intrahepatic biliary system. A stricture that involved the confluence of the hepatic ducts was treated in June, 1966, by anastomosis of the right and left hepatic ducts individually to a Roux-en Y jejunal limb. Two further right subphrenic abscesses occurred, one of which developed into a biliary bronchopleural fistula, and a right hepatectomy was performed on October 30, 1967. The left hepatic duct, which was fibrotic and narrowed, was reanastomosed to the jejunum; however, the patient died from hepatic failure shortly after the operation. The resected lobe contained a 6 x 4 x 4 cm abscess with other microscopic abscesses, centrilobular hepatic necrosis and atrophy, fibrosis, and regenerating liver tissue.

**Comment:** The long-standing obstruction and infection led to intrahepatic abscesses with rupture into the subphrenic space. Hepaticojejunostomy was ineffective in eradicating the infection. Ad-

TABLE 2. *Segmental or Hepatic Bile Duct Injury Without Infection*

Initial Management	
Ligate small segmental ducts <1 mm	
End-to-end repair of larger segmental and hepatic ducts >2 mm	
Drainage and antibiotics	
Management After Repair of Duct	
Good function	No further treatment
Asymptomatic stenosis	No further treatment
Stenosis with infection	Reoperation to establish adequate biliary-enteric drainage

TABLE 3. *Segmental or Hepatic Bile Duct Injury With Infection*

Patient	Cause	Duct Injured	Treatment	Result	Remarks
A.O.	Cholecystectomy secondary repair	R. and common hepatic	Partial R. hepatic lobectomy. L. hepaticojejunostomy	Died	Generalized intrahepatic biliary sclerosis
R.B.	Bullet wound	R. hepatic	R. hepatic lobectomy	Well	R. hepatic artery severed. Chronic draining abscess, R.
S.W.	Sclerosing solution in Echinococcus cyst	R. and common hepatic	Partial R. hepatic lobectomy. L. hepaticojejunostomy	Well	Persistent R. subphrenic biliary abscess

vanced biliary sclerosis and secondary cirrhosis led to hepatic failure after an exceedingly difficult right hepatic lobectomy. A successful lobectomy might have been possible had the diagnosis of the intrahepatic abscess been made some months earlier before the extensive perihepatic scarring and the biliary sclerosis developed.

Chronic intrahepatic abscesses that communicate with a damaged biliary system may arise in association with other types of trauma, as illustrated by the following cases.

**Case 2 (R.B.):** A 23-year-old army sergeant suffered a shrapnel wound June 20, 1973, that severed the right hepatic duct and artery and penetrated the right lobe of the liver. A right subphrenic abscess developed that communicated freely with the right intrahepatic biliary system and a biliary fistula from the hilus of the liver (Fig. 8). Recurrent abscesses, jaundice, biliary drainage, and repeated bleeding continued until a right hepatectomy and end-to-end anastomosis of the left hepatic duct to the common duct was performed on September 24, 1973. The patient recovered completely after a 2½-month hospitalization.

*Comment:* Despite repeated drainage of subphrenic and intrahepatic abscesses, the infection could not be controlled because of interference with bile drainage at the hilus. Removal of the infected right lobe and repair of the left ductal system eradicated the infection and biliary drainage and restored normal liver function.

**Case 3 (S.W.):** An 11-year-old girl had had a repeat evacuation of a right hepatic echinococcus cyst and injection of a sclerosing solution into the cavity when she was 6 years old. Apparently, the cyst cavity communicated with her right ductal system, for a stenosis of the right and common hepatic ducts developed. Infected bile repeatedly accumulated in the cyst cavity and in the right subphrenic space, requiring numerous drainage procedures. When she was 7½ years old, evacuation of an intrahepatic abscess and anastomosis of a Roux-en-Y jejunal limb to the opening of the bile fistula on the dome of the right lobe relieved the recurrent subphrenic abscesses; however, repeated bouts of cholangitis continued during the next 3½ years, leading to portal hypertension, splenomegaly, and esophageal varices. At the time of her last admission, the enlarged spleen was removed and an end-to-side splenorenal shunt performed. A part of the severely atrophied right lobe was removed, and a hepaticojejunostomy was performed between the Roux-en-Y limb and the markedly dilated left hepatic duct (Fig. 9). She has developed normally and has been well during the 4 years since the last operation.

*Comment:* A partially successful attempt was made to drain a blocked right biliary system and intrahepatic abscess into a peripherally placed Roux-en-Y limb. The portal hypertension could have been averted and the course of the prolonged repeated infections abbreviated

had the infected right lobe been more promptly removed and the partially obstructed left hepatic duct decompressed.

#### *Segmental or hepatic bile duct injury with infection*

In patients with chronic biliary obstruction, infection within the biliary system (cholangitis) will invariably develop above the point of stenosis, and adequate repair of the stenotic area will relieve the infection. However, if the obstruction is also associated with an intrahepatic abscess, resection of the appropriate liver lobe and repair of the remaining ductal system are usually necessary to control the infection.

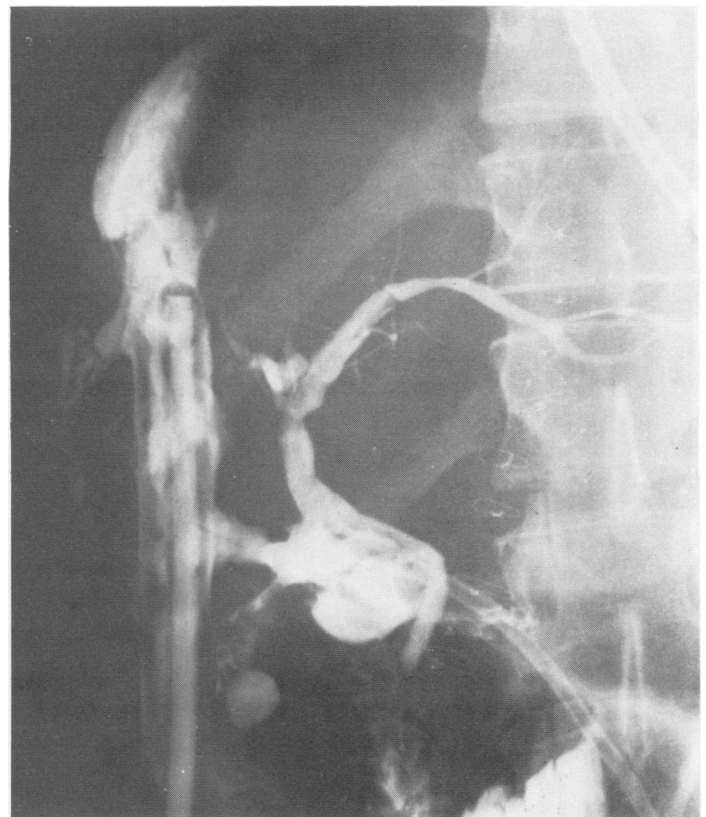

FIG. 8. Injection of dye through tube in left hepatic duct demonstrating leakage through disrupted right duct system into intrahepatic abscess in right lobe and right subphrenic space.



TABLE 4. *Congenital Ductual Lesions*

Patient	Duct Involved	Symptoms	Treatment	Result
R.M.	L. hepatic	Recurrent fever, jaundice, pain	Choledochojejunostomy. Drainage of cyst	Well
T.G.	L. hepatic	Recurrent fever, jaundice, pain	Hepaticojejunostomy	Well
C.H.	Diffuse cystic dilatations	Recurrent fever, jaundice, pain	Hepaticojejunostomy. Indwelling tube	Improved
L.B.	L. intrahepatic	Fever, jaundice	L. hepatectomy	Well
F.K.	R. intrahepatic	Fever	R. hepatectomy	Died
S.C.	Ventral-cranial segment R.	Fever, pain	R. hepatectomy	Well

### *Congenital Lesions*

A variety of congenital anomalies of the lumen of the normally arranged segmental or lobar ducts may occur. These include single isolated lesions, multiple anomalous conditions, and diffusely involved ductal systems. Idiopathic hepatic lobar or segmental atrophy<sup>33</sup> may be the result of congenital atresia of a lobar or segmental duct such as was seen in two of our patients. As incidental findings, the left lobe in one and the left lateral seg-

ment in another were atrophic. The congenital lesions that usually confront surgeons are related to some type of ductal dilatation with stasis of bile flow, precipitation of solid material, and infection. Clinically, such patients usually show signs of infection in the presence of jaundice so that the biliary system is immediately suspect. When the process is confined to a segment of the intrahepatic ductal system, jaundice is absent, and early localization of the source of a systemic infection may be difficult. The following six patient reports illustrate various types of congenital hepatic duct lesions (Table 4).

**Cases 1 and 2 (R.M. and T.G.):** These two patients, previously reported upon,<sup>17</sup> had isolated cystic dilatations of the left hepatic duct, a site in the ductal system that seems to have a predilection for such anomalies. Glenn and Moody<sup>9</sup> have described patients with similarly located cystic lesions. In both patients, soft pigment stones and sludge collected in the saccular dilatation, causing repeated bouts of jaundice and cholangitis. In one patient (T.G.), the cystic dilatation was located at the hilus outside of the liver, and adequate drainage of the cyst and relief of symptoms were obtained by anastomosis of the biliary cyst to a Roux-en-Y jejunal limb. In the second patient (R.M.), the cyst was intrahepatic, making treatment more complicated. The infection was finally controlled by placement of an indwelling catheter into the cyst for prolonged daily irrigations, and a Roux-en-Y jejunal limb was anastomosed end-to-end to the dilated common hepatic duct so that biliary debris could pass readily into the alimentary tract.

Multiple intrahepatic cystic dilatations of the biliary tract may be diffuse throughout the system or confined to an anatomical segment of the liver.

**Case 3 (C.H.):** An 18-year-old girl had biliary symptoms since a choledochal cyst was anastomosed to the duodenum when she was 1 year old. In association with the choledochal cyst, she had diffuse cystic dilatation throughout the intrahepatic ductal system (Caroli's disease) (Fig. 10). After 6 operations for repeated attacks of cholangitis, she now has a high hepaticojejunostomy. An external tube which passes into the dilated hepatic duct has been left in place for approximately 2 years to allow access to the ductal system for irrigation and instrumentation of the sludge and debris that form in the dilated ducts. She has been free of cholangitis during this period.

Because of the diffuse distribution of the cystic areas throughout both lobes of the liver, the treatment in such cases must be directed toward keeping the biliary system as free as possible of particulate matter by irrigations, leaving as large a communication as possible between the

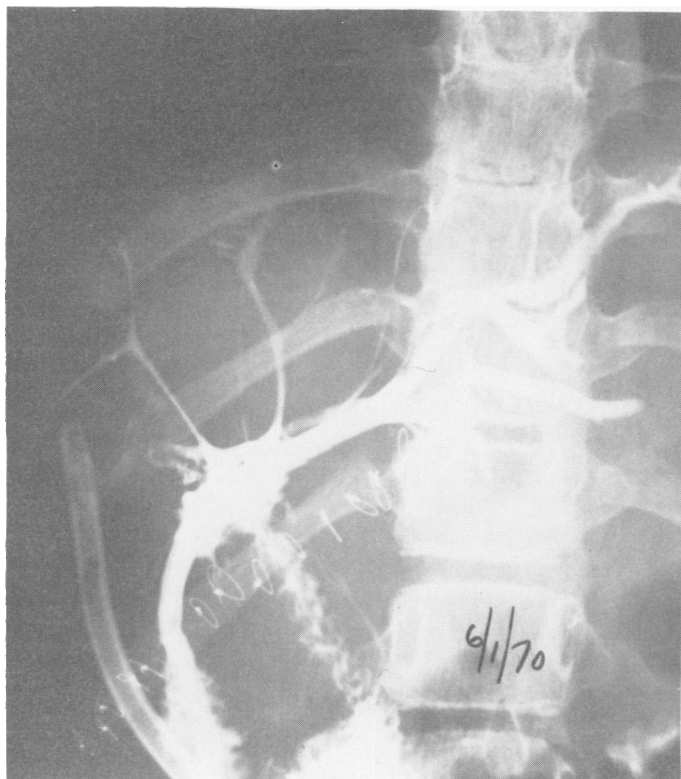


FIG. 9. Dye injected via tube through common hepatic jejunal anastomosis. Note enlargement of left duct system and marked atrophy of remaining portion of right intrahepatic ducts.

biliary and enteric tracts. In some patients with a history of frequent recurring episodes of cholangitis, a route of access should be provided to the biliary tree for periodic mechanical removal of stones and sludge.

Multiple cystic dilatations of the intrahepatic ducts were localized to resectable anatomical segments of the liver in the following three cases. The left lobe was affected in one patient, the right lobe in the second, and the right ventral-cranial segment in the third. It is remarkable that, although these malformations were congenital and had been present since birth, they did not become symptomatic until the patients were 46, 41, and 16 years of age.

**Case 4 (L.B.):** A 47-year-old woman with cystic malformations confined to the left lobe had had symptoms of increasingly severe attacks of cholangitis for 1½ years. During an acute febrile episode with gram negative sepsis, the patient underwent drainage of what was thought to be a large left hepatic abscess. Subsequent x-ray studies indicated that the abscess was a part of a markedly dilated left hepatic ductal system with numerous large cystic areas. With external drainage, the acute episode was relieved, but attacks of cholangitis persisted until the left lobe was resected. After recovery from an extensive wound infection, the patient remained well (Figs. 11a and b).

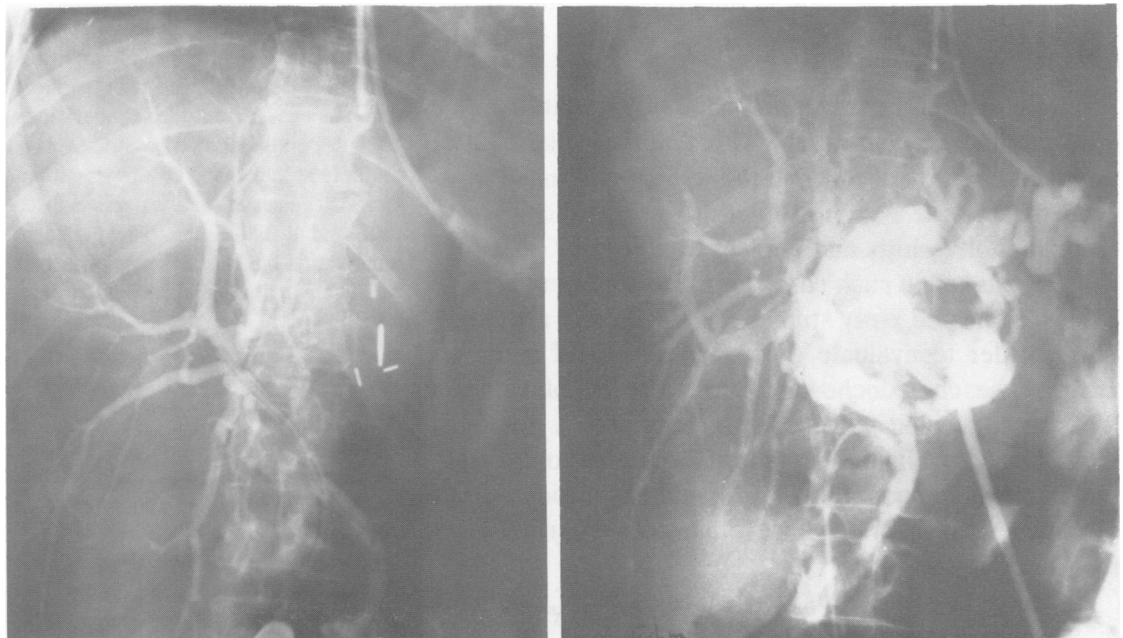
**Case 5 (R.K.):** A 51-year-old man, mentioned in a previous report,<sup>17</sup> had a 10-year history of recurrent cholangitis. He underwent a choledochojejunal anastomosis to control a continued biliary sepsis. When the operation proved to be totally ineffective, a right hepatectomy was performed, but the patient died of overwhelming sepsis. Three large cystic areas tightly packed with bilirubinate stones served as the nidus to perpetuate his cholangitis. Had these areas all been located and drained and the active acute infection allowed to subside prior to the hepatectomy, a successful outcome might have been achieved.

**Case 6 (S.C.):** A very puzzling diagnostic problem was presented by a 16-year-old boy who was admitted to the UCLA Hospital with a 10-day history of abdominal pain with chills and fever for 5 days. Attention was directed to his biliary system by increased tenderness in the right upper quadrant and a total serum bilirubin of 2.3 mg/100 ml. *Escherichia coli* bacteria were cultured in the blood. Findings on liver scan were normal. At operation, the gallbladder was distended and thick-walled, as was the common bile duct, but no stones were present. The bile was dark, but no particulate matter was seen. An operative cholangiogram, which visualized the intra- and extrahepatic biliary system, was interpreted as normal (Fig. 12a). The liver and spleen were enlarged, and the portal

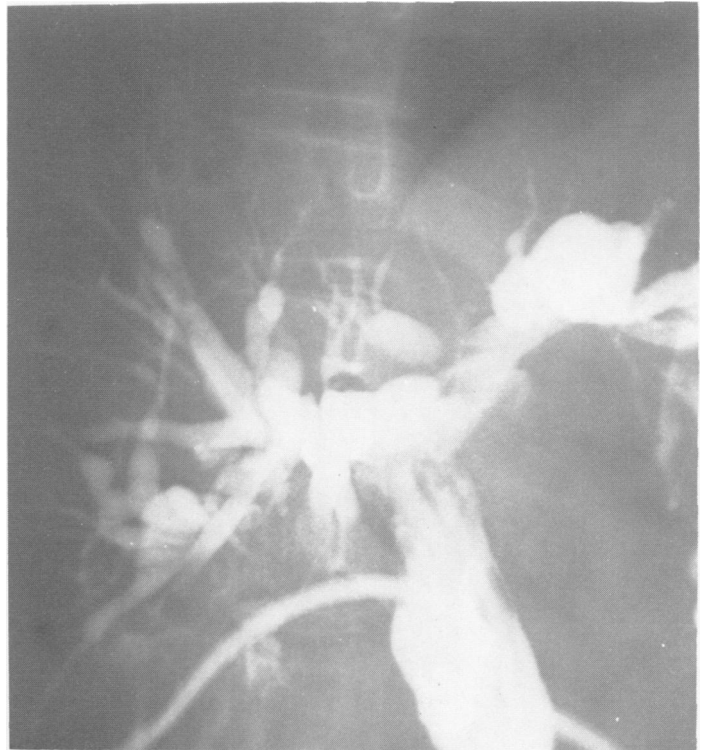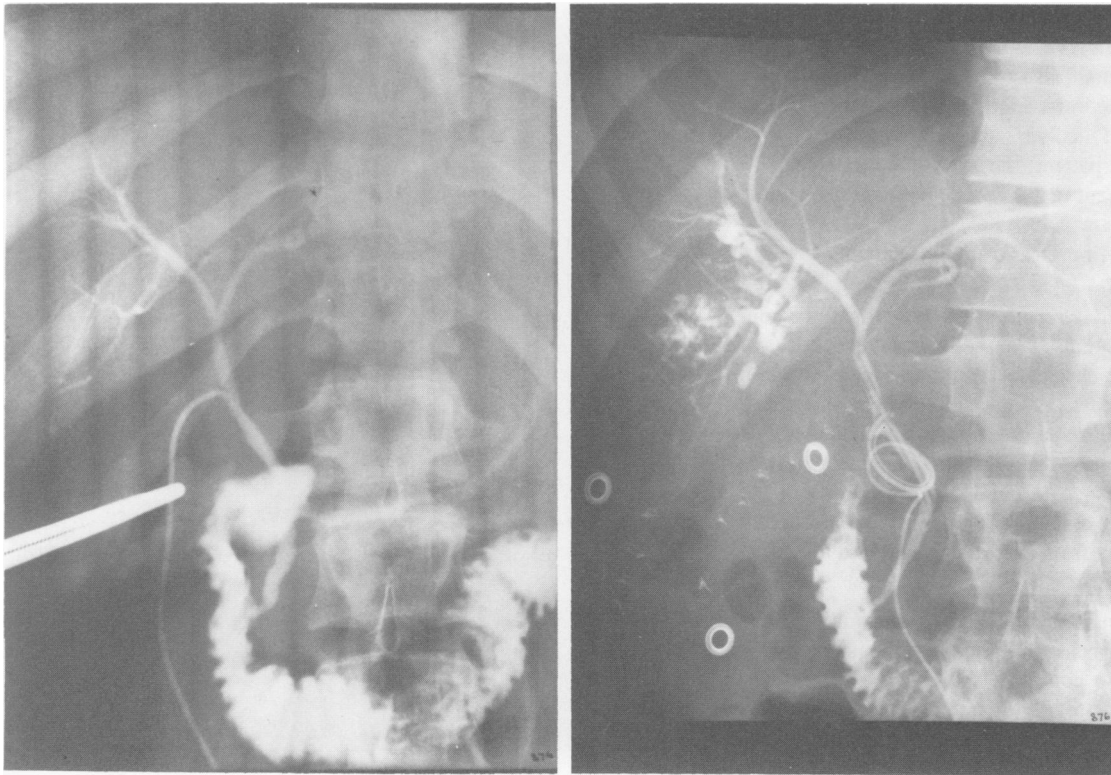


FIG. 10. Tube cholangiogram of patient with anastomosis of jejunum to markedly dilated hepatic duct after partial excision of congenital choledochal cyst. Multiple cystic dilatations of the entire intrahepatic biliary system are demonstrated.

pressure was 212 mm of saline. The gallbladder was removed and a T-tube placed in the common duct. Postoperatively, his febrile course continued unabated. The serum bilirubin rose to 3.8 mg/100 ml, alkaline phosphatase to 128 units, SGOT to 220 units, and SGPT to 154 units. A postoperative cholangiogram demonstrated multiple cystic collections of contrast agent in the dorsal-caudal segment of the right hepatic biliary system (Fig. 12b). A partial right hepatectomy removed a segment of liver containing multiple *Escherichia coli* abscesses in the biliary tree. Since the postoperative period, he has been well for 1½ years.



FIGS. 11A and B (left), Demonstration of marked saccular dilatation of left intrahepatic system. Right intrahepatic ducts are normal. (right) Normal right intrahepatic ducts after resection of left lobe.



FIGS. 12A and B. (left), Operative cholangiogram interpreted as normal. Note that dorsal-caudal segment of right lobe is not visualized. (right) Post-operative cholangiogram demonstrated multiple infected cystic areas in dorsal-caudal segment of right lobe.

### Congenital lesions

Single localized cystic dilatations in the major hepatic ducts can be drained into the alimentary tract. When infection and cholangitis supervene in the patient with multiple diffusely situated intrahepatic cystic dilatations, surgical treatment is not curative, but palliation may be achieved by hepaticojejunostomy, with or without an indwelling catheter. Localized infected cystic dilatations of the intrahepatic ducts may be resected by segmental or lobar hepatectomy. When acute sepsis is present, antibiotic therapy and biliary drainage or drainage of a dominant intrahepatic abscess should be instituted before definitive hepatic resection is undertaken (Table 5).

### Intrahepatic Stones

Intrahepatic stones occur in one of two conditions. The most common is the patient with a diffuse dilatation of the ductal system secondary to the long continued presence of multiple common duct stones associated with chronic cholecystitis and cholelithiasis. Great care should be taken in such cases to insure the removal of all stones. Repeated x-ray studies of good quality are essential in order to evaluate the completeness of stone removal. The choledochoscope may also be of value in locating concealed stones. In patients with a markedly dilated, thick-walled common duct, the creation of a lateral choledochoduodenostomy should be considered as a prophylactic measure against retained or recurrent common duct stones.

Intrahepatic stones that serve as a nidus of continued infection and repeated attacks of cholangitis that cannot

be removed by the usual methods with scoops, forceps, Fogarty catheters, wire baskets, or the aid of the choledochoscope may require hepatic resection. On the other hand, the mere presence of an intrahepatic stone unassociated with any clinical symptoms of biliary tract disease is not necessarily an indication for remedial surgical procedures, but such patients should be maintained under observation. The initial treatment to be used for the irremovable symptomatic intrahepatic stone, however, is a choledochenteric anastomosis. If such proves to be ineffective in relieving the symptoms, hepatic resection must be considered, as illustrated by the following cases (Table 6).

**Case 1 (S.B.):** A 43-year-old woman had suffered with intermittent epigastric and right upper quadrant pain for 25 years. A cholecystectomy in 1945 had relieved her symptoms for 7 years. Recurrent common duct stones were removed at operations in 1953, 1955, and 1963. T-tube cholangiograms showed a stricture of the left intrahepatic duct with multiple stones distal to the stenotic area. In October, 1963, the left lateral segment of the liver was excised, including the stenotic hepatic duct and distal stones. The patient has had subsequent attacks of pancreatitis but no further biliary tract difficulty.

*Comment:* It seems quite likely that the post-stenotic infection and

TABLE 5. Congenital Hepatic and Intrahepatic Ductal Lesions With Infection

Condition	Treatment
Single lesion involving major hepatic duct	Cyst-jejunal anastomosis
Multiple intrahepatic cysts	
Diffuse	Hepaticojejunostomy
Localized	Hepatic resection

TABLE 6. *Intrahepatic Stones*

Patient	Duct	Disease	Symptoms	Treatment	Result
S.B.	L. intra-hepatic	Congenital	Cholangitis	L. lateral segmental resection	Well
A.B.	L. intra-hepatic	Retained stone	None	Attempted extraction	Well?

debris in the left hepatic duct were passed into the common duct, producing attacks of cholangitis and right upper quadrant pain. The marked deformity made an intraductal approach to the stones impossible. Hepatic resection was the only way whereby the stones and the infected duct could be removed.

**Case 2 (A.B.):** This 58-year-old woman illustrates, in contrast, the possible innocuous nature of an intrahepatic stone. The patient became jaundiced and febrile in December, 1972, and a chronically inflamed gallbladder with stones was removed on January 4, 1973. Multiple stones were removed from a grossly dilated extra- and intrahepatic ductal system. A postoperative T-tube cholangiogram demonstrated a 1½ cm retained stone in one of the major left intrahepatic biliary ducts (Fig. 13). The system was otherwise negative. Attempts to remove the stone by manipulation via the T-tube tract were unsuccessful.

*Comment:* As the patient is entirely asymptomatic with normal liver function tests, she has been treated conservatively since that time. If such a patient becomes symptomatic, operative removal of the stone would be attempted with the aid of the choledochoscope, and a direct approach to the left hepatic duct would be performed in conjunction with choledochoduodenostomy. If this were unsuccessful and attacks of cholangitis persisted without other explanation, hepatic resection would be considered.

### *Intrahepatic stones*

At the initial operation in cases of primary (congenital) or secondary (acquired) dilatation of the ductal system with multiple calculi, it is important that every effort be made to extract all stones from the intra- and extrahepatic systems with all of the usual techniques. Carefully performed post-exploratory operative cholangiograms should demonstrate the major intrahepatic segmental ducts. Choledochenteric anastomosis should always be performed when the duct dilatation is primary and seriously considered for the patient with long-standing multiple calculous disease with marked secondary duct thickening and dilatation. Hepatic resection may be required for the irremovable intrahepatic stone with distal infection. Some stones of this type are remarkably well tolerated and generally require treatment only when they become symptomatic.

### *Hepatic Duct Carcinoma*

In a previous study of carcinoma of the extrahepatic biliary tract, we found the confluence of the hepatic ducts at the hilus of the liver to be involved in 34 of 63 cases.<sup>18</sup> Resection of the tumor with duct enteric anastomosis was possible in only four patients. Major hepatic resection combined with excision of the tumor was used in two additional patients. A T-tube was inserted into the com-

mon duct and through the site of tumor obstruction in 13 patients, and in three others, an enteric anastomosis to the hepatic ducts above the obstruction was used as a palliative procedure. Palliation was considered good in 5, fair in 7, and poor in 4 patients. When a tube was inserted through an area of malignant obstruction or through a duct enteric anastomosis into the intrahepatic system, it usually passed into either the right or left hepatic system. The extent of biliary drainage from the opposite lobe varied from complete drainage to complete obstruction. With either extreme, the result seemed to be better than with partial drainage, particularly if infection were present. The following four cases are illustrative (Table 7).

**Case 1 (L.D.):** A 65-year-old man was admitted to the UCLA Hospital with signs of increasing renal dysfunction 2½ weeks after cholecystectomy and insertion of a small T-tube through a stenotic area in the common bile duct. Jaundice, pruritis, and weakness had been present for 3 months preoperatively. After operation, his serum bilirubin fell from 21 to 7.5 mg/100 ml where it remained. The serum creatinine rose to 4.0 mg/100 ml. A T-tube cholangiogram demonstrated the tube to be in the right hepatic duct with marked dilatation of the entire right intrahepatic ductal system above a site of complete obstruction at the confluence of the hepatic ducts (Fig. 14). At reoperation, a Roux-en-Y jejunal limb was anastomosed to the site of confluence of the left and right hepatic ducts above the tumor obstruction as a palliative bypass.

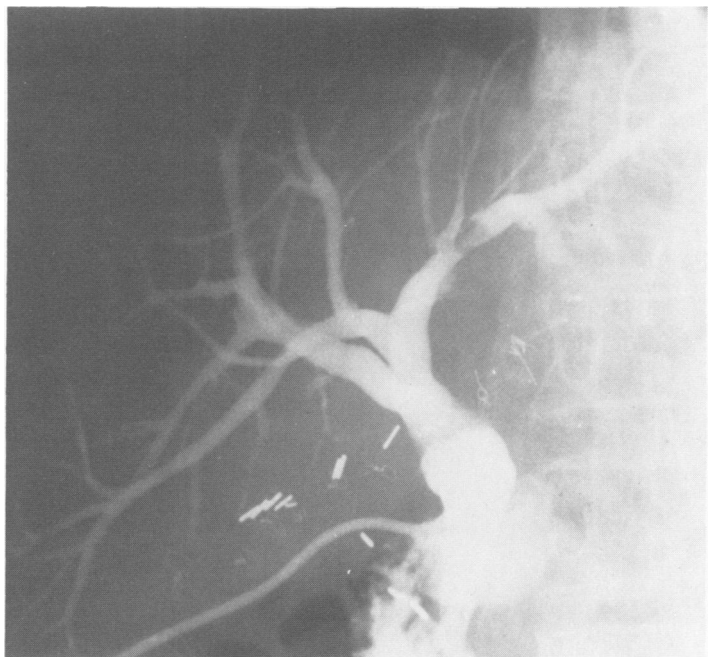


FIG. 13. Cholangiogram demonstrating an intrahepatic stone in the main branch of the left hepatic duct. The patient has been asymptomatic for more than 2 years.

TABLE 7. *Hepatic Duct Carcinoma*

Patient	Location Tumor	Intrahepatic System Drained	Procedure	Result
L.D.	Confluence hepatic ducts	1st operation R., partial L. 2nd operation R. and L.	T-tube through tumor Hepaticojejunostomy	Bilirubin ↓ 7.5  Bilirubin normal. Lived 11 mo
C.F.	Confluence hepatic ducts	L.	L. hepatico-duodenostomy	Bilirubin, alkaline phosphatase normal, 2½ mo. after operation until death at 1 yr
H.C.	Confluence hepatic ducts. Extension into L. hepatic duct.	R.	T-tube through tumor into R. hepatic duct	Bilirubin normal, alkaline phosphatase elevated, 3 mo after operation
E.Z.	Confluence hepatic ducts	R. ventral-cranial segment-partial?	T-tube through tumor	Bilirubin ↓ 6-7 4 mo

The serum bilirubin returned to normal 4 weeks after operation and remained so until shortly before he died 11 months after operation.

*Comment:* Although there was some communication of the left and right intrahepatic ductal systems, as demonstrated on cholangiogram, the decompression of the system was not adequate through the T-tube limb in the right duct to decrease the ductal dilatation or to lower the serum bilirubin below 7.5 mg/100 ml. Adequate drainage of both lobes via a hepaticojejunostomy above the tumor returned the serum bilirubin to normal.

**Case 2 (C.F.):** A 54-year-old man had a T-tube inserted into the common duct below a point of obstruction after about a month of jaundice and abdominal discomfort. On the basis that the scarred common duct blockage might be sclerosing cholangitis, he was treated with

Prednisone over the ensuing 2 months with some apparent temporary relief of his symptoms. At reoperation, a carcinoma at the confluence of the hepatic ducts extending into the right lobe was identified, and the left hepatic duct was anastomosed to the duodenum (Fig. 15). Over the next 2½ weeks prior to discharge from the hospital, the serum bilirubin fell from 25.3 mg/100 ml to 5.1 mg/100 ml and alkaline phosphatase from 86.4 to 25.3 k-A units. Two weeks later, the stool and urine were of normal color.

The alkaline phosphatase and serum bilirubin were normal 2½ months after operation and remained so until the patient died of bleeding associated with tumor erosion of the gastric wall 1 year after operation.

*Comment:* This patient's course demonstrates that free drainage of one normal hepatic lobe (the left in this case) despite complete obstruction of the ductal system of the other lobe is adequate to bring about a normal serum bilirubin and alkaline phosphatase within 2 months after the relief of complete biliary obstruction.

**Case 3 (H.C.):** In this 46-year-old woman, operation in February, 1974, disclosed an obstruction of the bile ducts at the confluence of the hepatic ducts with marked dilatation of the intrahepatic ductal system above this level. After dilatation of the obstruction and insertion of a T-tube, there was drainage of bile for approximately 1 month, after which drainage ceased and the tube was removed. The jaundice increased, and she lost 20 pounds before her admission to UCLA and the second exploration on July 24, 1974. Carcinoma of the confluence of the bile ducts was found with extension of the tumor up the left hepatic duct. The lumen of the obstructed duct was dilated, and a T-tube was inserted through the obstruction into the right hepatic duct (Fig. 16). Three months after operation, the serum bilirubin was 1.2 mg/100 ml, and the serum alkaline phosphatase was 475 K-A units. Six months after operation, the patient had returned to work. The serum bilirubin was 0.9 mg/100 ml, the alkaline phosphatase 406 units, and the SGOT 137 units. X-ray studies demonstrated good filling and emptying of the right hepatic ductal system. The left system was completely obstructed.

*Comment:* In this case, there is free drainage of the right hepatic ductal system with complete uninfected obstruction of the left hepatic duct. Serum bilirubin levels came down to normal in 3 months and have remained so. The alkaline phosphatase is still elevated. The patient is symptomatically well.

**Case 4 (E.Z.):** A 40-year-old man was admitted to the hospital on August 26, 1974, with a 2-month history of upper abdominal pain and deepening jaundice. At operation on September 9, 1974, a T-tube was placed through a fibrotic obstruction of the common hepatic duct up into the right hepatic ductal system. His serum bilirubin, which was

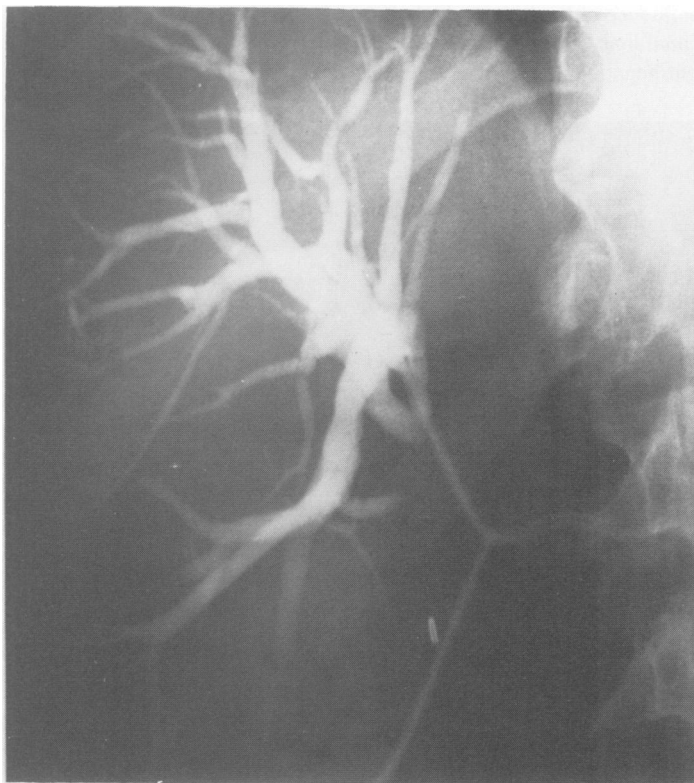


FIG. 14. Small T-tube placed through an obstructing carcinoma at the confluence of the hepatic ducts into the dilated right hepatic system was too small to provide adequate drainage.

21.5 mg/100 ml at the time of operation, dropped to 10.8 mg/100 ml, and the alkaline phosphatase fell from 117 units to 73 units (normal 15-45) at the time of discharge 11 days after operation. Postoperative T-tube cholangiograms showed the proximal limb of the T-tube to extend well out into a tertiary segment of the right ductal system with filling of about one-half of the ducts in the ventral-cranial segment. There was no evidence of drainage about the catheter or of filling of the ducts in the left lobe or the dorsal-caudal segment of the right lobe. During the ensuing 4 months since operation, the bilirubin has ranged from 6 to 7 mg/100 ml, the alkaline phosphatase about 390 K-A units, and there has been one episode of intermittent low-grade fever of 100 F. *Pseudomonas* and another gram negative rod were grown in cultures of the bile. Despite the icterus, the patient has felt well, maintained his weight, and remained asymptomatic. A repeat T-tube cholangiogram on November 27, 1974, showed a decrease in the size of the ducts in the portion of the system that had been drained (Fig. 17). Again, only a portion of the ductal system of the ventral-cranial segment was demonstrated. No ducts were seen in the left lobe or in the dorsal-caudal segment of the right lobe.

*Comment:* The operative findings and cholangiographic studies would indicate that the present T-tube is probably draining less than one-quarter of the hepatic mass, and cultures demonstrate the presence of infection. If the patient should survive a sufficient period of time, it is possible that adequate hyperplasia would occur in the drained area to restore normal liver function. At present, the persistent serum bilirubin of 6 to 7 mg/100 ml indicates that that portion of the biliary system being drained is insufficient to excrete an adequate amount of bilirubin and to maintain a normal serum bilirubin level.

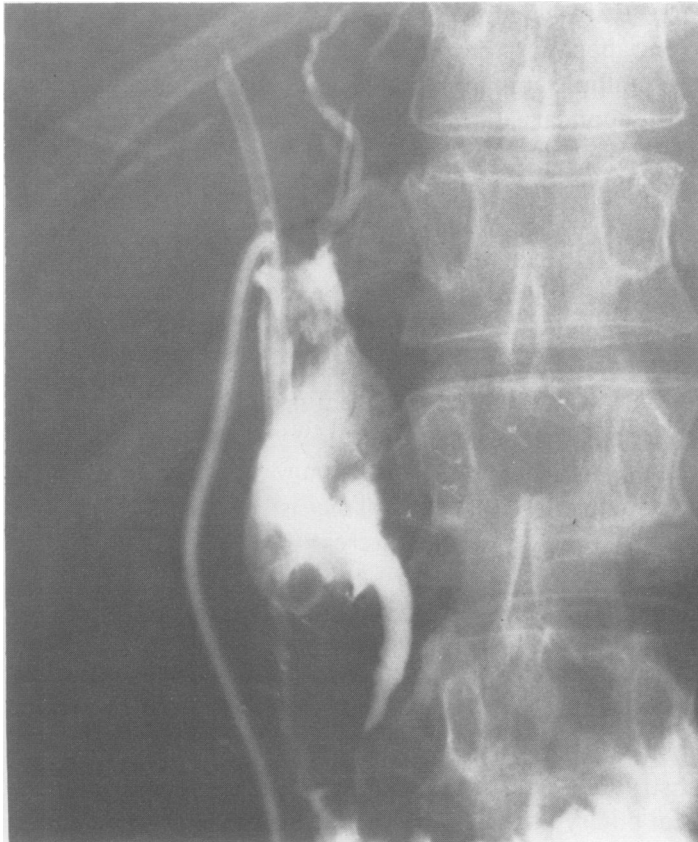

FIG. 15. Attempted passage of T-tube through the obstructing carcinoma of the right hepatic duct; the duodenum has been anastomosed to the left hepatic duct. Dye injected via the T-tube demonstrating that tube does not pass above the tumor and that the right duct is completely obstructed. The dye, however, passes down the common duct into the duodenum and refluxes through the hepaticoduodenostomy into the left hepatic duct.

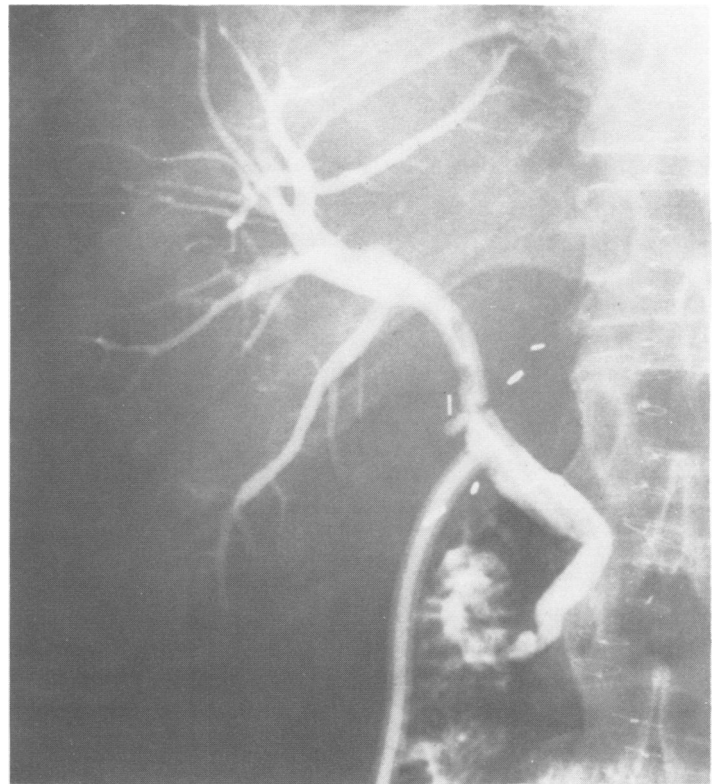


FIG. 16. Dye injection demonstrating T-tube passing through an obstructing carcinoma providing adequate bile drainage via the right hepatic duct system. Left hepatic duct completely obstructed.

### *Hepatic duct carcinoma*

These four cases demonstrate certain results that may be expected and certain principles believed to be important when lobar and segmental ducts are drained in treatment of carcinoma of the biliary tract. In the first case (L.D.), normal liver function was restored with drainage of both the right and left ducts after a small T-tube into the right system and restricted drainage of the left hepatic ducts had been only partially effective. Case 2 (C.F.) regained normal serum bilirubin and alkaline phosphatase levels with drainage of the left hepatic duct only. Case 3 (H.C.) responded in a similar fashion with drainage limited to the right ductal system. And, finally, in the fourth case (E.Z.), a partial drainage of the ventral-cranial segment of the right lobe has resulted in symptomatic improvement but has not provided sufficient biliary drainage to lower the bilirubin or to bring the alkaline phosphatase to normal.

### **Conclusion**

The various conditions discussed above, when they involve the segmental or lobar hepatic ducts, have a remarkably limited number of effects on the biliary system. Basically, they produce one of four responses singly or in combination: 1) Obstruction to the flow of bile; 2) precipitation of particulate matter and formation of

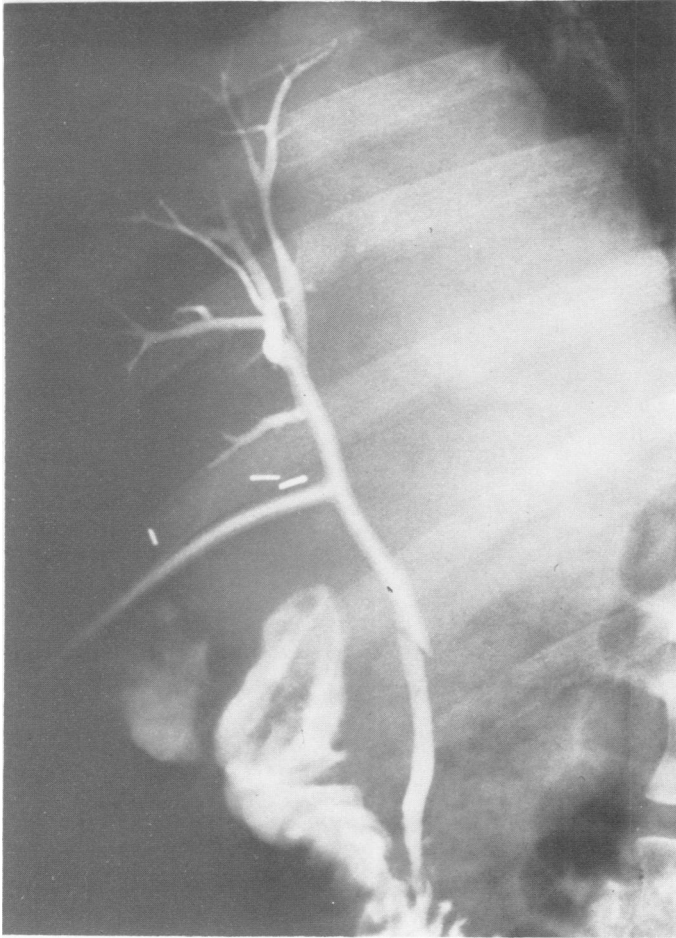


FIG. 17. T-tube cholangiogram indicating partial drainage of ventral-cranial segment of right lobe. Moderate elevation of serum bilirubin persists. Otherwise the patient is asymptomatic.

stones; 3) development of infection; or 4) creation of an external biliary fistula.

Obstruction and infection have important secondary effects on the liver parenchyma: complete biliary obstruction, resulting in hepatic atrophy; and partial obstruction, particularly when associated with infection, causing hepatocyte destruction, periportal scarring, and ductal sclerosis.

In certain rare cases, if the infection escapes beyond the liver via the lymphatic or hepatic veins, the systemic effects of infection, i.e., gram-negative sepsis, become a part of the clinical picture. Partial obstruction, although it may, at times, be produced by stones, will of itself ultimately lead to the formation of stones and the development of infection.

Bland obstruction of the biliary system without infection is remarkably well tolerated. Despite previous reports to the contrary, evidence seems clear that unobstructed biliary drainage of 50% of the liver parenchyma through either the right or left hepatic ducts is adequate to restore normal liver function, even if the

obstructed lobe remains in situ. It is probably necessary, however, that the hepatocellular function of the drained lobe be normal and the ductal system uninfected. The presence of undrained liver tissue is probably of no significance as long as it is completely obstructed and uninfected. A partially obstructed lobe or segment, particularly when associated with infection, will, on the other hand, lead to hyperbilirubinemia with the clinical signs of jaundice, pruritis, and sepsis. The exact mechanism whereby partial obstruction produces such symptoms is not understood.

These concepts have important connotations in the management of segmental or lobar duct lesions, for unless there is a good chance that an unobstructed, uninfected biliary flow can be achieved through such a duct, it is better that it be completely obstructed and its drainage area allowed to atrophy.

An intrahepatic abscess, in communication with an obstructed or abnormal biliary tract, will generally require resection of the involved liver and repair of the abnormal bile duct should the lesion of the bile duct be situated in a portion of the biliary system that drains both normal and abnormal portions of the liver.

Symptoms resulting from diffuse intrahepatic duct abnormalities may be ameliorated, at least in part, by a large extra-hepatic duct-enteric anastomosis.

Intrahepatic stones are seen in: 1) patients who have had multiple common duct stones for long periods of time with secondary dilatation of the ductal system or 2) those with congenital anomalies of the ductal system (usually saccular or diffuse dilatation) and secondary stone formation.

After removal of intrahepatic stones using all available techniques, including endoscopy, a choledochoenterostomy should be performed if there is a question of retained or recurrent stones or if the ductal dilatation is the primary condition and stone formation secondary. Intrahepatic stones are usually asymptomatic until they pass down into the main biliary channel to produce biliary obstruction and cholangitis. Passage of the stone through the choledochoenterostomy will, of course, prevent this sequence of events. Impacted intrahepatic stones with distal infection may require hepatic resection.

Unimpeded drainage of either the right or the left hepatic ductal system via a large T-tube through the point of obstruction or by duct-enteric anastomosis above the obstruction can provide satisfactory palliation of malignant biliary obstruction due to carcinoma of the bile duct when the tumor cannot be excised.

Finally, it should be emphasized once again that frequent anomalies of the extrahepatic ducts play an important role in provoking injury of the biliary apparatus during cholecystectomy. Knowledge of the common

anomalies, their recognition and management, is essential for the surgeon.

### Addendum

Since completion of this manuscript, we have treated another patient with an unrecognized right dorsal caudal segmental duct injury sustained during cholecystectomy. Recovery was complicated due to inadequate drainage of intraperitoneal bile, but the biliary fistula eventually closed spontaneously. Postoperative x-ray films obtained by the injection of radiopaque solution through the biliary fistula suggested that the divided duct opened into the bed of the gallbladder.

J.S., a 37-year-old man, underwent cholecystectomy for cholelithiasis on August 20, 1974. Three weeks after an uncomplicated operation and an initial uneventful postoperative course, the right upper quadrant was reexplored because of pain. A massive subhepatic and subphrenic accumulation of bile was drained. Bile seemed to be coming out of the bed of the gallbladder. Thereafter, approximately 400 cc of bile was drained per day, but he continued to have normal-colored stools. On October 18, 1974, the following test results were obtained: Prothrombin time 100%, serum creatinine 1.1 mg/100 ml, total protein 9.2 gm/100 ml, albumin 4.65 gm/100 ml, cholesterol 151 mg/100 ml, glucose 103 mg/100 ml, total bilirubin 0.7 mg/100 ml, alkaline phosphatase 265 units, SGPT 150 units, SGOT 89 units, white blood cell count 8,300/cu mm, hematocrit 38.8%, hemoglobin 12.6 gm/100 ml. X-ray findings were as follows: A sinogram demonstrated a "pocket" of dye in the region of the gallbladder fossa; the dye then filled a part of the intrahepatic ductal system in the region of the right dorsal caudal segment. No dye was seen to enter the extrahepatic biliary tract. Cleocin was given for 4 days following one episode of temperature elevation to 100.6 F on October 12, 1974. This febrile episode was associated with reduced biliary drainage from the fistula. At the time of the patient's admission to the UCLA Hospital on October 30, 1974, slight tenderness was present over the right costal margin. Biliary drainage had stopped. His temperature was 99 F, white blood cell 9,100/cu mm, total serum bilirubin 0.6 mg/100 ml, SGOT 183 units, and alkaline phosphatase 296 units. Stool and urine were normal in color. Attempted injection of the sinus tract did not disclose any communication with the biliary tree. Continued observation was recommended, and in the ensuing months, the patient has remained well without biliary drainage, chills, fever, or jaundice.

### References

1. Beaver, M. G.: Variations in the Extrahepatic Biliary Tract. *Arch. Surg.*, 19:321, 1929.
2. Braasch, J. W. and Preble, H. E.: Unilateral Hepatic Duct Obstruction. *Gastroenterology*, 42:743, 1962.
3. Braasch, J. W., Whitcomb, F. F., Jr., Watkins, E., Jr., et al.: Segmental Obstruction of the Bile Duct. *Surg. Gynecol. Obstet.*, 134:915, 1972.
4. Cattell, R. B. and Braasch, J. W.: Repair of Benign Strictures of the Bile Duct Involving Both or Single Hepatic Ducts. *Surg. Gynecol. Obstet.*, 110:55, 1960.
5. Cole, W. H.: Congenital Anomalies of the Bile Ducts and Adjacent Blood Vessels. *Surg. Gynecol. Obstet.*, 87:111, 1948.
6. Daseler, E. H., Anson, B. J., Hambley, W. C. and Reimann, A. F.: The Cystic Artery and Constituents of the Hepatic Pedicle. *Surg. Gynecol. Obstet.*, 85:47, 1947.
7. Flint, E. R.: Abnormalities of the Right Hepatic, Cystic and Gastroduodenal Arteries and of the Bile Ducts. *Br. J. Surg.*, 10:509, 1922.

8. George, P.: Disorders of the Extrahepatic Bile Ducts. *Clin. Gastroenterology*, 2:127, 1973.
9. Glenn, F. and Moody, F. G.: Intrahepatic Calculi. *Ann. Surg.*, 153:711, 1961.
10. Goor, D. A. and Ebert, P. A.: Anomalies of the Biliary Tree. *Arch. Surg.*, 104:302, 1972.
11. Gutman, A. B., Hagg, B. M. and Olson, K. B.: Increased Serum Phosphatase Activity Without Hyperbilirubinemia after Ligation of Hepatic Ducts in Dogs. *Proc. Soc. Exp. Biol. Med.*, 44:613, 1940.
12. Healey, J. E., Jr. and Schroy, P. C.: Anatomy of the Biliary Ducts within the Human Liver. *Arch. Surg.*, 66:599, 1953.
13. Hjortsjo, C. H.: The Topography of the Intrahepatic Ductal System. *Acta Anat.*, 11:599, 1951.
14. Jackson, J. B., and Kelly, T. R.: Cholecystohepatic Ducts: Case Report. *Ann. Surg.*, 159:581, 1964.
15. Kune, G. A.: The Influence of Structure and Function in the Surgery of the Biliary Tract. *Ann. Royal Coll. Surg. Engl.*, 47:78, 1970.
16. Lin, T. Y.: Results in 107 Hepatic Lobectomies with a Preliminary Report on the Use of a Clamp to Reduce Blood Loss. *Ann. Surg.*, 177:413, 1973.
17. Longmire, W. P., Jr., Mandiola, S. A. and Gordon, E.: Congenital Cystic Disease of the Liver and Biliary System. *Ann. Surg.*, 174:711, 1971.
18. Longmire, W. P., Jr., McArthur, M. S., Bastounis, E. A. and Hiatt, J.: Carcinoma of the Extrahepatic Biliary Tract. *Ann. Surg.*, 178:333, 1973.
19. Longmire, W. P., Jr., Trout, H., III, Greenfield, J. and Tompkins, R. K.: Elective Hepatic Surgery. *Ann. Surg.*, 179:712, 1974.
20. Longo, O. F. and Masumana, L. A.: Canaux biliaires segmentaires aberrants et cholangeographie. *Lyon Chir.*, 65:499, 1969.
21. McArthur, M. S., Hiatt, J. and Bastounis, E.: The Surgical Anatomy of the Porta Hepatis. *J. Surg. Res.*, 17:111, 1974.
22. McMaster, P. D. and Rous, P.: Biliary Obstruction Required to Produce Jaundice. *J. Exp. Med.*, 33:731, 1921.
23. Mentzer, S. H.: Anomalous Bile Ducts in Man. *JAMA*, 93:1273, 1929.
24. Michels, N. A.: The Hepatic, Cystic, and Retroduodenal Arteries and Their Relation to the Biliary Ducts. *Ann. Surg.*, 133:503, 1951.
25. Mistilis, S. and Schiff, L.: A Case of Jaundice due to Unilateral Hepatic Duct Obstruction with Relief After Hepatic Lobectomy. *Gut*, 4:13, 1963.
26. Neuhoef, H. and Bloomfield, S.: The Surgical Significance of an Anomalous Cholecystohepatic Duct. *Ann. Surg.*, 122:260, 1945.
27. Ong, G. B. and Leong, C. H.: Surgical Treatment of Primary Liver Cancer. *J. Royal Coll. Surg. Edinb.*, 14:42, 1969.
28. Pollock, E. L. and Tabrisky, J.: The Aberrant Divisional Bile Duct: A Surgical Hazard. *Surgery*, 73:234, 1973.
29. Rabinovitch, J., Rabinovitch, P. and Zisk, H. J.: Rare Anomalies of the Extrahepatic Ducts. *Ann. Surg.*, 144:93, 1956.
30. Sherlock, S.: Diseases of the Liver. Philadelphia, F. A. Davis Co., 1966; pp. 398.
31. Smith, R.: Surgery of the Gall Bladder and Bile Ducts. London, Butterworth & Co., 1964.
32. Stafford, E. S. and Issacs, J. P.: Stone in the Left Hepatic Duct Causing Jaundice. *Ann. Surg.*, 147:812, 1958.
33. Tsuzuki, T., Hoshino, Y., Uchiyama, T., et al.: Compensatory Hypertrophy of the Lateral Quadrant of the Left Hepatic Lobe Due to Atrophy of the Rest of the Liver, Appearing as a Mass in the Left Upper Quadrant of the Abdomen. *Ann. Surg.*, 177:406, 1973.
34. Williams, C. and Williams, A. M.: Abnormalities of the Bile Ducts. *Ann. Surg.*, 141:498, 1955.

### DISCUSSION

DR. FRANK G. MOODY (Salt Lake City, Utah): Drs. Longmire and Tompkins have presented with clarity approaches to problems which occur at or above the bifurcation of bile ducts. The principles they have

enumerated are not far different from the ones we use for problems in the lower biliary tree, that is removal of debris and the establishment of free egress of bile especially when it's infected.

When you read the manuscript as I have, you'll try to second guess them on the cases that they present, but I assure you that you won't