

Hematuria and Rectal Bleeding in the Child with Klippel and Trenaunay Syndrome

M. SERVELLE*, R. BASTIN, J. LOYGUE, A. MONTAGNANI, F. BACOUR, J. SOULIE, J. B. ANDRIEUX

From the Hopital Saint-Michel, Paris, France

We have operated upon 588 patients with Klippel and Trenaunay syndrome. The underlying factor is a congenital malformation of the deep veins: agenesis, atresia or compression by fibrovascular bands of the popliteal, femoral or iliac veins. Of these 588 patients, 6 children between 15 months and 4 years of age had severe rectal bleeding and hematuria. One of these children died from massive bleeding of the rectum with septicemia. Another boy was saved by rectal resection and the last one by subtotal cystectomy. The important venogram shows an absence of the anterior venous pathway (superficial femoral vein) compensated by the abnormal development of 2 venous groups, the vein of the sciatic nerve and large veins along the external aspect of the inferior limb. These 2 venous groups penetrate into the pelvis by the sciatic and gluteal notches and terminate in the internal iliac vein which becomes enormous and has a very high flow. This overflow hinders drainage of the venous collateral from the rectum, the bladder and the vagina. The retro adductor vein, prolonged by the deep femoral vein, represents an anastomosis between the sciatic nerve vein and the common femoral vein. The surgeon must try to widen this pathway.

IN 1900, Klippel and Trenaunay described a syndrome under the name of osteo-hypertrophic varicose nevus characterized by: 1) a nevus on the abnormal limb; 2) varicosities on that same limb; 3) hypertrophy of all tissues, particularly of the bones of that same limb. In June, 1945 we demonstrated that this syndrome was caused by a malformation of the deep veins of the affected limb. During the 30 years that followed, we examined and operated upon 588 patients with Klippel and Trenaunay syndrome. This wide experience has shown that the underlying factor responsible for this disease may be agenesis, atresia or external compression of the deep veins by abnormal muscles, fibrous or fibrovascular bands.

Of these 588 patients treated surgically for Klippel and Trenaunay syndrome, 6 children had severe rectal bleeding. In one case, rectal hemorrhage had been preceded by severe hematuria at the age of two and in another, again at the age of two, by vaginal and vulvar hemorrhages. The experience gained from venograms and from surgery on the veins in these 6 patients has led to better understanding of the mechanism of these hemorrhages. They are complications related to certain localization of the syndrome of Klippel and Trenaunay. The aim of our surgical treatment should be to restore the venous return from the inferior limb to the normal anterior venous pathway formed by the common femoral and external iliac veins. This technique has given good results in 4 of the 6 patients operated upon. However in certain cases, this correction has been insufficient or impossible. Hemorrhagic complications in these children have led to the death of one patient, necessitated removal of the rectum in a 5-year-old boy (Prof. Loygue) and to subtotal cystectomy in another two-year-old child (Prof. Montagnani). It thus seems interesting to study the hemorrhagic complications of the Klippel and Trenaunay syndrome as an entity since they may have a common physiopathology.

Case Reports

Klippel and Trenaunay Syndrome, Death from Rectal Bleeding

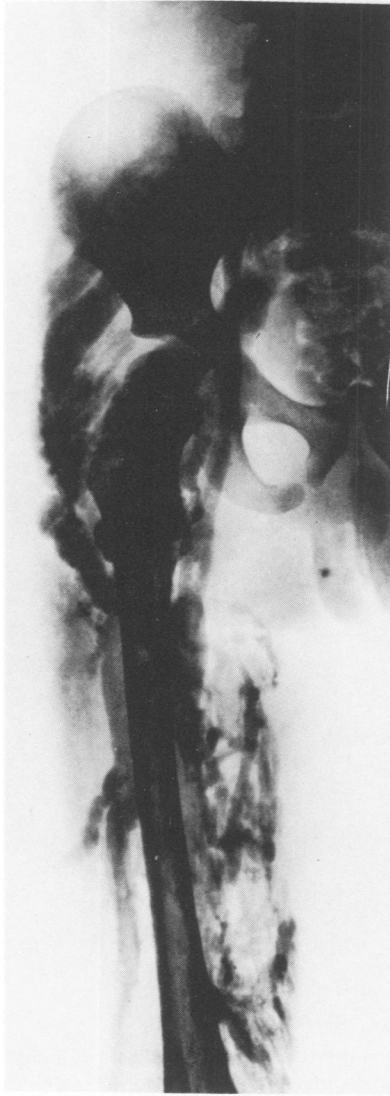Case 1. C.M., a 3-year-old boy, was referred in 1951 for a syndrome of Klippel and Trenaunay of the left inferior limb: superficial angioma, edema and increased length of the limb (1.4 cm).

From the moment the child was able to stand, large *hemorrhoids* appeared and there was bright red hemorrhage from the rectum.

Submitted for publication

* Hopital Saint-Michel, 33, Rue Olivier-De-Serres (XVe), Paris, France.

FIG. 1. Patient C.M., Case 1. Venogram, September 1951: the superficial femoral is not visualized. Large (1 cm diameter) sciatic nerve vein. Large collateral on the external aspect of the knee and thigh. At the superior extremity of the femur, the sciatic vein divides into three branches: the internal, injects the external iliac via the deep femoral vein; the mid-branch (13 mm in diameter) penetrates into the pelvis by the sciatic notch and leads to the internal iliac; the external branch receives the large vein from the external aspect of the thigh and then divides in two large gluteal veins measuring 1 cm in diameter which penetrate into the pelvis by the gluteal canal and also drain into hypogastric vein.



September 1951: Venogram of this inferior limb: the popliteal drains into a large sciatic nerve vein. Absence of the superficial femoral vein. The deep femoral vein injects the common femoral vein which leads to a 5 mm external iliac vein. The large veins on the external aspect of the thigh drain into the enormous sciatic nerve vein which, at the height of the great trochanter, divides into two veins: one (1 cm in diameter) enters the pelvis through the sciatic notch and terminates in the hypogastric vein; the other (the gluteal vein) drains also into the large hypogastric vein (diameter = 14 mm)

October 1951: Exploration of the popliteal fossa: the popliteal vein is compressed by two fibrotic strands which are cut. Just below the compression originates a large sciatic nerve vein.

November 10, 1951: There was excessive rectal bleeding: R.C. = 1,900,000. Professor Turpyn suggested a treatment of iron and liver extracts.

February 1952: Rectal bleeding continued. R.C.: 4,500,000.

March 1952: Exploration of the superficial femoral vein: this vein was found to be atretic on most of its length. The deep femoral vein was large and compressed by an arterial collateral which was cut.

The operation was terminated with the resection of large hemorrhoids.

March 1956: Second venogram: 8 cm of the superficial femoral vein (3 mm in diameter) was opacified. Venous stasis was less marked. The two principal collateral circuits remain the sciatic nerve vein and the veins on the external aspect of the thigh. There was displacement of the left ureter and of the left horn of the bladder towards the midline.

July 1956: Since the hemorrhoidectomy in 1952, rectal bleeding has persisted but is less abundant. In January 1960 the hemorrhoidal bleeding increased. R.C. 2,750,000. The child was transfused.

May 1962: Development of sciatica on the side of surgery: bed rest for two months. Rectal hemorrhages necessitate two transfusions.

Early 1963: Hemorrhage was much more abundant: the child, now 15, has received multiple transfusions. On September 1963 we ligated the sciatic nerve vein. The venogram showed a decrease in the filling of the internal iliac vein. During the next 3 months, the hemorrhage was less severe. However they recurred, necessitating multiple transfusions.

April 1964: Rectal hemorrhages persist. R. C. = 3,150,000. Following anal dilatation, multiple hemorrhoids were sutured in the anal canal. The day after surgery, in spite of antibiotics, his fever was elevated to 38.5 C. Two days later the temperature increases to 40 C. On May 9, his temperature returned to normal but rectal bleeding persisted.

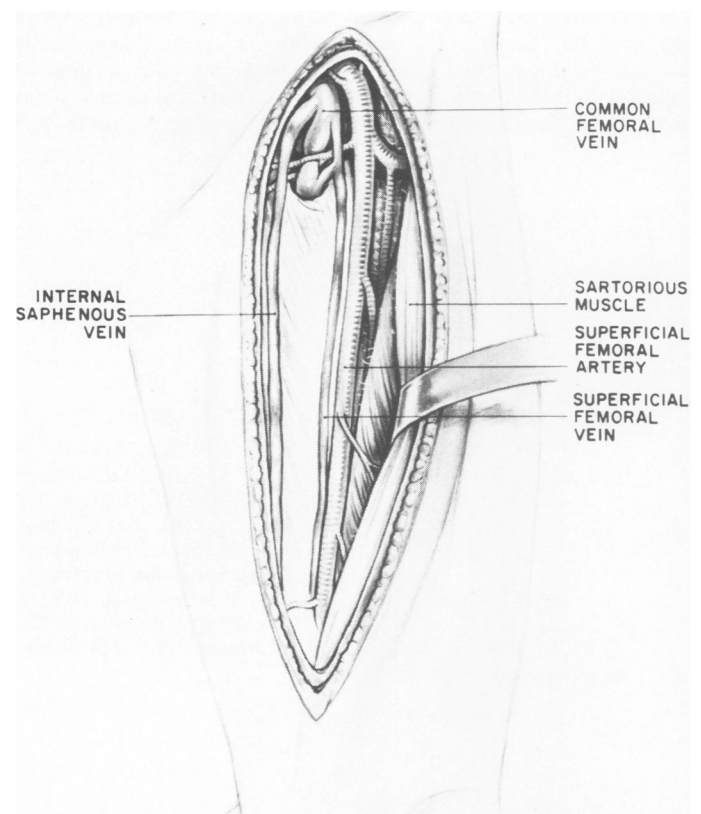


FIG. 2. Patient C.M., Case 1. Drawing from surgical findings: atresia of the entire superficial femoral vein. The large deep femoral vein is compressed by an arterial collateral.

May 15, 1964: In spite of antibiotics the patient's fever rose to 41.5 C, with severe chills. The patient was referred to Prof. Bastin: hemoculture showed staphylococcus sensitive to Kanamycin. On May 20, intensive intravenous antibiotherapy was instituted: the temperature dropped to normal within two days.

May 26, 1964: Massive rectal bleeding necessitating 2,500 ml of blood within 12 hours. The patient was referred to a gastrointestinal service: electrocoagulation was done by rectoscopy. May 29: the patient's temperature rose to 40 C.

June 9, 1964: The patient returned to Prof. Bastin's service: rectal bleeding had not recurred since electrocoagulation but the patient's temperature remained at 40 C. Hemoculture showed staphylococcus. Kanamycine was replaced by Flabelline. Three days later the patient's temperature dropped to 38.4 C.

June 19, 1964: The patient's general state was poor. He was jaundiced and had severe psychological disorders. The patient died on June 20, 1964.

Agenesis of the Popliteal Vein Compensated by a Sciatic Nerve Vein: Rectal Hemorrhages

Case 2. M.P., a 3½-year-old girl, was referred in 1953 for Klippel and Trenaunay Syndrome of the leg. A few weeks prior to her referral, this girl presented rectal hemorrhage severe enough to contemplate removal of the rectum.

Examination: The left leg was enlarged and 1 cm longer than the right. There was extensive superficial angioma on the external aspect of the leg and the thigh.

October 10, 1953: Venogram of the left inferior limb. The popliteal vein was not injected. A large vein (8 mm in diameter) directed upwards along the external aspect of the leg and the knee. Above the knee this large vein is divided into two main channels: one ascends on the external aspect of the thigh: the other is directed internally, crosses the posterior edge of the femur and ascends along the path of the superficial femoral vein. A large sciatic nerve vein

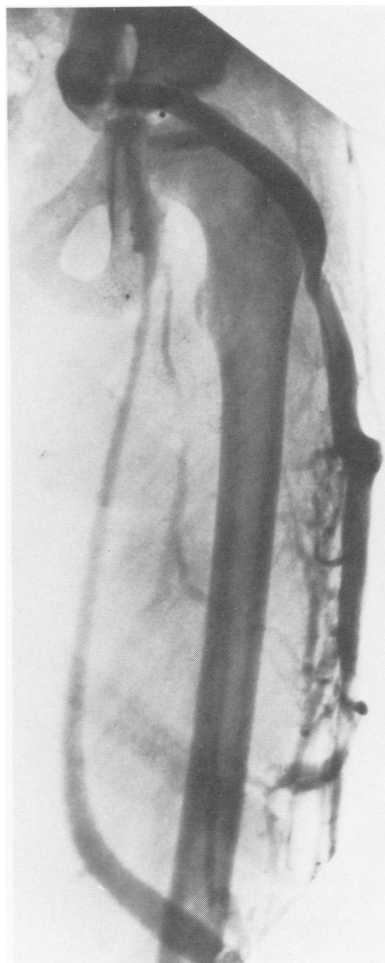


FIG. 4. Patient M.P., Case 2. Venogram of the thigh: small superficial femoral vein visible on a very short distance. Large internal saphenous vein. Huge collateral at the external aspect of the thigh penetrating into the pelvis by the sciatic notch and emptying into a large internal iliac vein (18 mm in diameter).

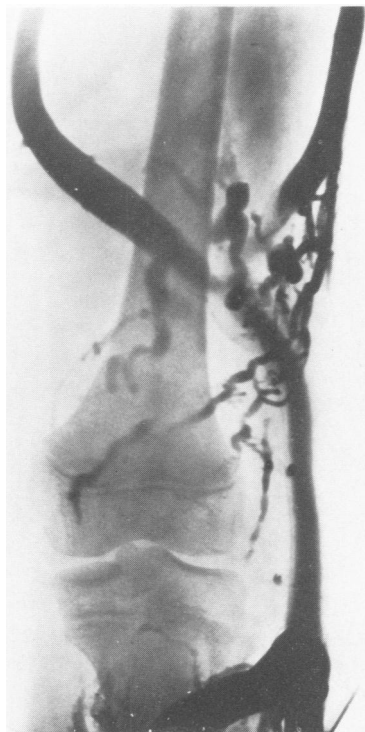

FIG. 3. Patient M.P., Case 2. Popliteal venogram: no injection of the popliteal vein. The internal saphenous vein is dilated (15 mm). A large external oblique vein fills a large vein on the external aspect of the thigh.

follows the posterior edge of femur. At the level of the great trochanter, the large venous vessel (1 cm diameter) on the external aspect of the thigh passes upwards and medially behind the femoral head where it divides: one branch entering the pelvis through the sciatic notch, the other through the gluteal vessel canal. These two large veins drain into a very large hypogastric vein (18 mm in diameter). The venous flow from the common femoral to the external iliac was very light.

April 1, 1954: Exploration of the left popliteal fossa: multiple varicosities on the sciatic nerve which is accompanied on its internal side by a large vein (4 mm in diameter). The popliteal artery is without satellite vein. It is however wrapped in a sheath of multiple lymphatic vessels. *Diagnosis:* agenesis of the popliteal vein compensated by a large sciatic nerve vein and a large collateral on the external aspect of the thigh.

October 31, 1960: Second venogram, the distribution is the same as that observed prior to surgery with a very large internal iliac vein (2 cm in diameter). In 1968 the calf and the foot remain greatly enlarged.

August and September 1971: multiple accesses of lymphangitis with high fever recurring upon cessation of antibiotherapy. This girl is now married and has three children. After each pregnancy she has had lymphangitis. We performed total superficial lymphangiectomy in October 1971 and January 1972.

October 1975: over the past three years this patient has not had rectal bleeding. The lymphangiectomy has given excellent results.

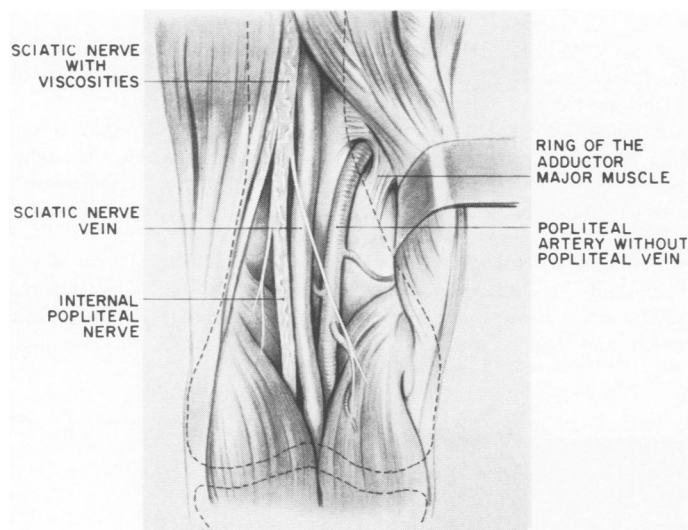


FIG. 5. Patient M.P. Drawing from surgical findings: agenesis of the popliteal vein.

Syndrome of Klippel and Trenaunay Necessitating Resection of the Rectum

Case 3. B.D., a 27-month-old boy, was referred to us in April 1966 for a Klippel and Trenaunay Syndrome of the right leg complicated by rectal bleeding since the age of 15 months. May 15, 1966, the hemorrhages were so abundant that the child had to be admitted in Toulouse Hospital. At birth, there were two angiomas on the external aspect of the thigh. At 8 months of age, edema of the inferior limb began and varicosities appeared on the leg. The child began to walk at 12 months and rectal bleeding began 3 months later. The presence of hemorrhoids was noted at the age of two.

April 2, 1966: the right inferior limb is edematous (thigh = +1.5 cm, calf = +2.5 cm) and longer (1.5 cm) than the left.

June 20, 1966: 1) Venogram of the right inferior limb: malformation of the popliteal vein; very large internal saphenous and gluteal veins terminate in a large internal iliac. 2) Exploration of the popliteal fossa: large external saphenous vein; one cm below the ring of the adductor there is a definite musculo fibrotic band compressing the popliteal vein. The band was then cut. 3) Exploration of the superficial femoral vein showed a very small vein. Three centimeters below the common femoral vein, it was pierced by an arterial collateral which was cut in order to free the internal part of the divided superficial femoral vein. The common femoral and deep femoral veins were large. By disinsertion of the great adductor muscle, the deep femoral vein was freed its entire length.

November 14, 1966: 1) Second venogram: the superficial femoral vein was well visualized in its inferior half. 2) Rectal venogram: multiple rectal varicosities were visualized.

October 25, 1967: Rectal hemorrhages persisted. R.C. = 3,300,000. Ligation of multiple hemorrhoidal groups on the inferior region of the rectal ampulla.

October 10, 1968: The child was readmitted on an emergency basis following rectal hemorrhage. R.C. = 1,700,000. We advised Prof. Loygue to proceed with resection of the rectum, which was carried out on November 21, 1969.

July 3, 1972: Following resection of the rectum, there has been no rectal bleeding. *Venogram:* the sciatic nerve vein has shrunk a great deal: the internal iliac is much smaller; the lateral rectal veins are absent.

October 20, 1975: Since rectal resection in 1969 there has been no rectal bleeding.

Klippel and Trenaunay Syndrome Complicated with Rectal Bleeding

Case 4. C.G., a 17-month-old girl, was referred on October 20, 1967 for Klippel and Trenaunay Syndrome of the left leg complicated by rectal bleeding. There was edema of the left leg and buttock since birth: also present were varicosities of the calf and ankle and superficial angioma at the knee. The left leg has been longer than the right since she was one year old. Rectal bleeding began in October 1967 and lasted 8 days. A venogram of the left leg was done on December 21, 1967: large external saphenous vein (4 mm in diameter) continued into the thigh by a large sciatic nerve vein from the external aspect of the knee and sent out a collateral ascending on the external aspect of the thigh through which it visualized the gluteal veins and the sciatic nerve vein, both entering the pelvis to terminate in the hypogastric vein. The superficial femoral vein is not injected. On the second film, the inferior half of the sciatic

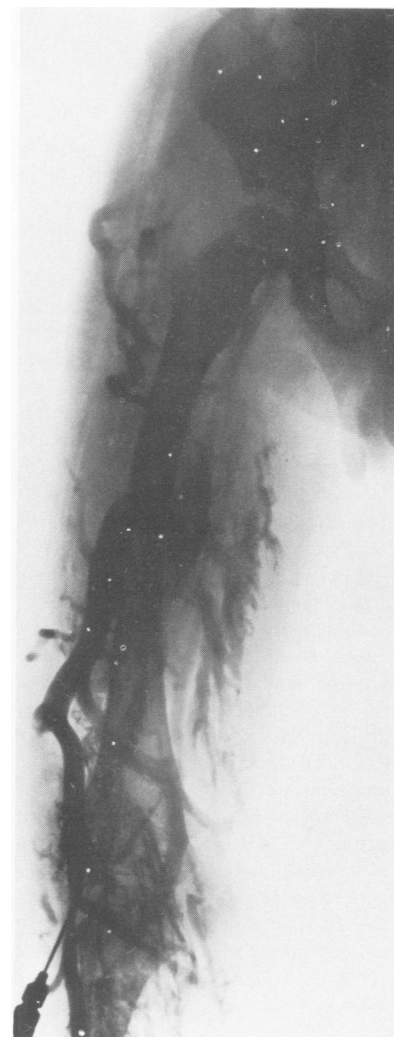

FIG. 6. Case 3. Venogram, June 20, 1966: malformations of the popliteal and superficial femoral veins compensated by a sciatic nerve vein and a gluteal vein draining into the internal iliac.

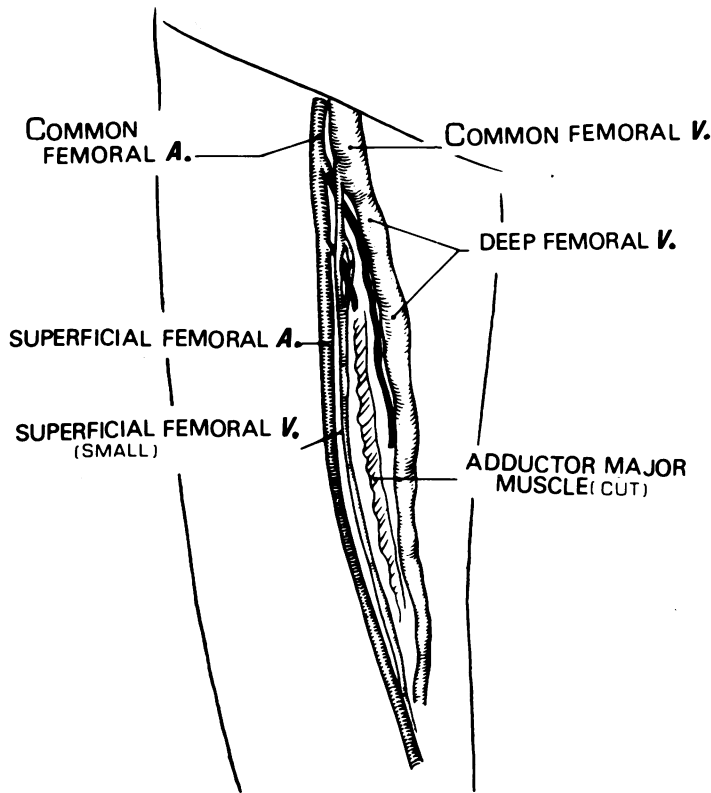


FIG. 7. Case 3. Drawing from surgical findings: atresia of the superficial femoral vein. Huge common and deep femoral veins.

nerve vein drained into a large vein on the external aspect of the thigh which itself drains into the gluteal veins and the sciatic nerve vein. Internal to the femur, 3 cm above the gluteal fold, appear horizontal veins that inject the anal area.

Conclusion: The superficial femoral vein is never visualized. The venous blood of the inferior limb drains into the pelvis: 1) Anteriorly by the deep, common femoral and external iliac veins. 2) Posteriorly by the sciatic nerve vein and the gluteal veins which drain into the internal iliac. 3) Part of the venous return is to the inferior hemorrhoidal veins.

Surgery: December 21, 1967 1) Visualization of the superficial femoral vein. The vein measures $\frac{1}{2}$ mm in diameter. It is freed on its entire length. By freeing of the great adductor, the deep femoral is completely isolated; it is large and continues inferiorly into a large retroadductor vein. The common femoral vein is of good calibre. 2) Exploration of the popliteal fossa: the popliteal vein is enormous (3.5 cm in diameter). The sciatic nerve vein is anterior to the nerve itself; it is freed upwards where it joins the retro-adductor vein which has been freed from above. The large external saphenous drains into the sciatic nerve vein.

December 27, 1967: Rectal venogram: good injection of the venous system of the rectal ampulla. Fine veins of the mucosa are visualized. There is a marked venous stasis.

October 31, 1968: 2nd rectal venogram: injection of all the veins of the rectal ampulla and of the inferior mesenteric vein. The veins of the buttock on the affected side are injected in a retrograde fashion.

October 1975: 8 years following operation, the patient has had only short episodes of rectal bleeding in July and August 1975.

Syndrome of Klippel and Trenaunay Complicated by Rectal and Vulvar Bleeding.

Case 5. M-C.J., a 7½-year-old girl, was referred in February 1964 for Klippel and Trenaunay Syndrome of the right leg. Since the age of 2, this girl has had vulvar and rectal bleeding.

Examination: superficial angioma covering the external aspect of the leg, the thigh, the labia majora and the buttock on the right. Numerous hemorrhages have occurred from this angioma. Varicosities around and under this angioma. Edema (calf = 2.5 cm). The right inferior limb is longer than the left (+2 cm).

February 3, 1964: Venogram, the superficial femoral vein is not visualized. A large popliteal vein extends upwards by a large sciatic nerve vein which penetrates into the pelvis by the sciatic notch and injects a large internal iliac vein. On the last film,

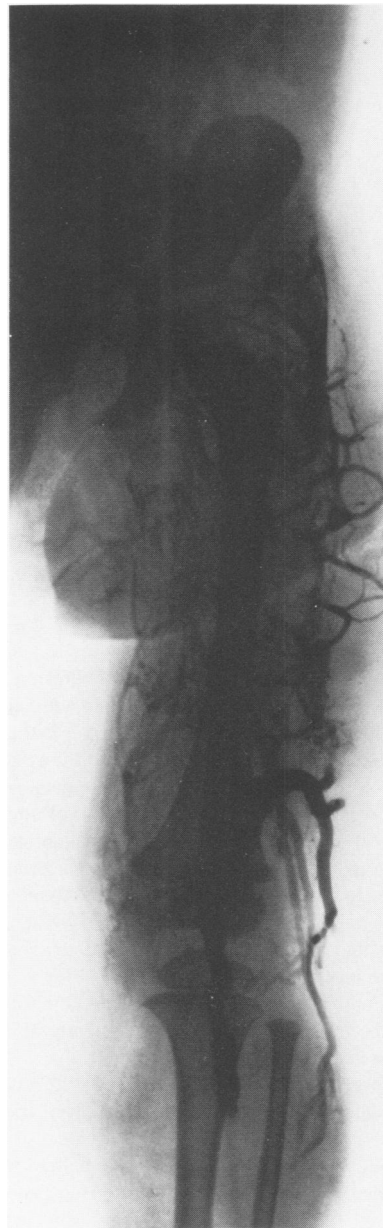

FIG. 8. Case 4. Venogram: Large external saphenous vein extending up to the thigh by a huge sciatic nerve vein. Huge vein at the external aspect of the thigh draining into the sciatic and gluteal veins before emptying into the hypogastric vein.

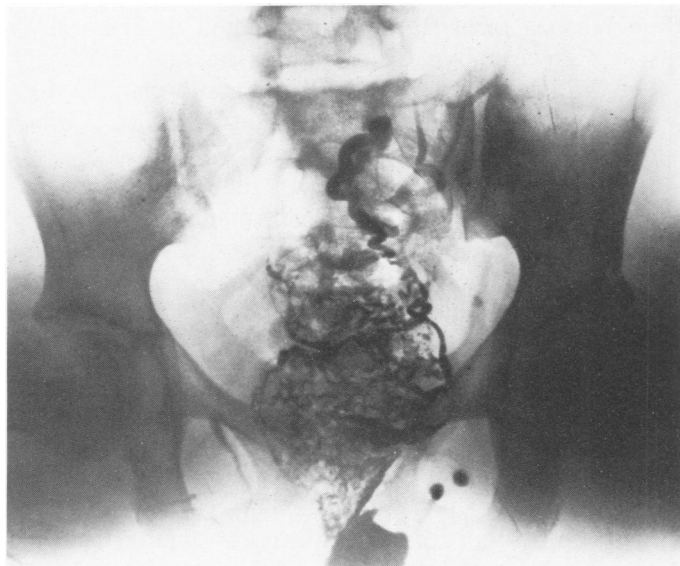

FIG. 9. Case 4. Rectal venogram: opacification of the entire venous system of the rectal ampulla.

multiple veins at the external aspect of the greater trochanter and in the gluteal region are visualized. The obturator vein is also injected.

February 3, 1964: 1) Visualization of the superficial vein shows that it is only 1 to 2 mm in diameter. The common femoral vein is of a good calibre. The deep femoral vein measures 4 mm in diameter. It is followed by disinsertion of the great adductor muscle on the posterior aspect of the thigh.

December 21, 1967: Second venogram: The inferior two-thirds of the popliteal vein is small in diameter. The superficial femoral vein is always not injected.

June 6, 1968: Exploration of the popliteal fossa: The external saphenous vein does not drain into the popliteal vein but ascends on the posterior aspect of the thigh: however at the level of the knee joint, the popliteal give off a small venous collateral, remnant of the arch of the short saphenous. The popliteal vein is small and is wrapped in a fibrotic sheath which is progressively slit. At the level of the knee joint, this popliteal vein divides into two branches: 1) the sciatic nerve vein, 2) a small popliteal vein wrapped in multiple fibrotic stands. Slitting of these bands freed the vein.

June 1968: Rectal bleeding has stopped but vaginal bleeding persists. Vaginal venogram unsuccessful. A rectal venogram showed numerous small veins of the rectal ampulla, draining in a large superior hemorrhoidal vein.

June 29, 1970: The rectal and vaginal hemorrhages have not recurred. Fourth venogram: marked decrease of venous stasis. The deep femoral and external iliac veins are small (4 mm). The internal iliac vein measures 22 mm in diameter.

September 9, 1974. The vulvar and rectal hemorrhages have disappeared. The right labia majora is very distended by varicosities. Venogram of the vulva shows that the varicosities are linked to the left thigh through numerous veins; the long vaginal veins are injected.

Klippel and Trenaunay Syndrome Complicated by Hematuria and Rectal Bleeding

Case 6. S.F., a 4-year-old boy, was referred from Italy on January 21, 1974 for a superficial angioma of the left leg and thigh, a 2 cm increase in length of the right leg and hypertrophy of the

anterior half of both feet. At 20 months of age there was hemorrhage of the angioma which was treated by electroagulation and sclerosing injections. Thirteen months later there was massive hematuria. Cystoscopy showed most of the bladder to be covered by angioma. A subtotal cystectomy (Prof. Montagnani) in 1972 gave a very good result, but a few weeks later rectal bleeding appeared followed by higher fever which responded well to antibiotics.

Examination (January 21, 1974) typical syndrome of Klippel and Trenaunay of the right inferior limb with gigantism of the feet.

January 22, 1974: 1) Venogram; the deep veins of the calf, the popliteal and superficial femoral veins are not injected. The main venous drainage of this inferior limb is through a large vein ascending on the external aspect of the leg, knee and thigh. At the level of the great trochanter this large vein (16 mm in diameter) curves internally and ascends slightly to enter the pelvis through the sciatic notch and injects the internal iliac vein (1 cm in diameter).

2) Exploration of the popliteal fossa; Anterior to the sciatic nerve is a large sciatic nerve vein (1 cm in diameter). No popliteal vein along the upper two-thirds of the popliteal artery.

January 31, 1974: 1) Inspection of the superficial femoral vessels; There is an agenesia of the superficial femoral vein on its entire length. The deep femoral vein is very small as is the common femoral. There is no internal saphenous vein. 2) Amputation of the malformed

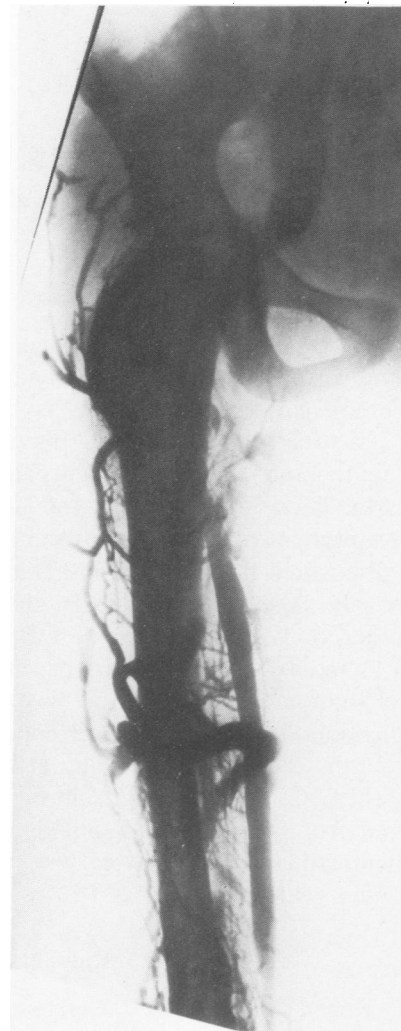

FIG. 10. Case 5. Venogram, December 21, 1967: the thigh is markedly rotated outward: the superficial femoral is not injected. Very large popliteal vein leading to a large sciatic vein ending in a large internal iliac vein. Important venous dilations on the external aspect of the thigh.

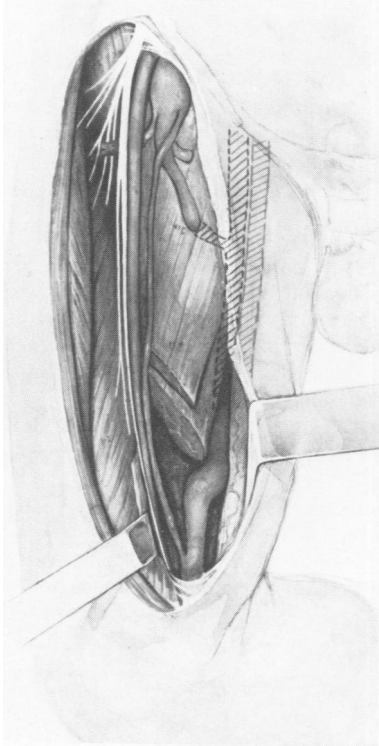


FIG. 11. Case 5. Drawing from surgical findings: atretic superficial femoral vein. Large sciatic nerve vein linked to the deep femoral by an anastomosis. The common femoral is markedly enlarged.

toes along with resection of the soft tissues of the anterior feet and of the soles.

In September 1975: Since surgery there has been no hematuria and no rectal bleeding. This boy can walk with normal shoes.

Comments

The 6 children with hemorrhagic complications all had a syndrome of Klippel and Trenaunay in its typical and complete form: one limb was larger and longer, with varicosities and superficial angioma. Noteworthy is the fact that out of our 588 patients with congenital anomalies of the deep veins operated upon during the past 30 years, a superficial angioma was present in 37% of the cases and varicosities in 36%. The other symptoms were present in all. Also noteworthy is the early appearance of rectal or vesical bleeding. In three observations (Cases 1, 3 and 4), rectal hemorrhages appeared at the age of 15 or 16 months. Patient M.P. has bled only once from the angioma at 20 months, had hematuria at 2 years and 9 months then rectal bleeding at the age of 4 years. Patient C.G. had bleeding from the rectum, from the vulva and from the angioma, noted at the age of two. The hemorrhagic complications were seen between 15 months and 4 years of age.

Frequency

Rectal bleeding is the most frequent. It has been noted in 6 observations. Hematuria, vulvar and vaginal hemorrhages are much more scarce (one of 6).

Hemorrhages from the angioma, noted in 3 of our 6 cases, are caused by venous stasis associated with fragility of the skin over this cutaneous malformation: they thus have an etiology totally different than that of other hemorrhagic complications.

In regards to the frequency of all hemorrhages occurring in our 588 cases with malformations of the deep veins, it is presently difficult to give precise statistics. We have chosen the 6 observations which were exceptionally severe and representative. Parents of these children did not inform us about the rectal bleeding. They believed it to be caused by hemorrhoids not related to the malformation of the limb for which they sought consultation. We have just seen a young girl of 10 who was operated upon for Klippel and Trenaunay Syndrome: the parents had never told us about the presence of hemorrhoids. Only upon our specific questioning did they say their daughter had had rectal bleeding since the age of 2 or 3 years. They related this bleeding to constipation. Another patient was operated upon for Klippel and Trenaunay Syndrome at the age of 22, after having had two children. She had agenesis of the superficial femoral vein. Each pregnancy had brought on hemorrhoids which bled for many months. The last pregnancy had been terminated by cesarian section during which transection of a large supra-pubic vein was followed by varicosities of the labia majora.

We are reexamining our older patients so as to answer this question of frequency of hemorrhages.

Rectal bleeding or hematuria occurring in a patient with Klippel and Trenaunay Syndrome is serious indeed: one patient died from massive bleeding of the rectum

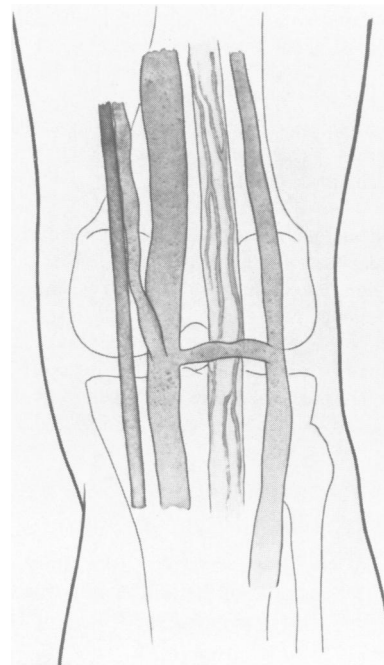


FIG. 12. Case 5. Drawing from surgical findings of the popliteal region: large external saphenous vein, external to the sciatic nerve; on the inside, the sciatic nerve vein is very dilated. The popliteal vein follows the artery in its upper two thirds: it is small.

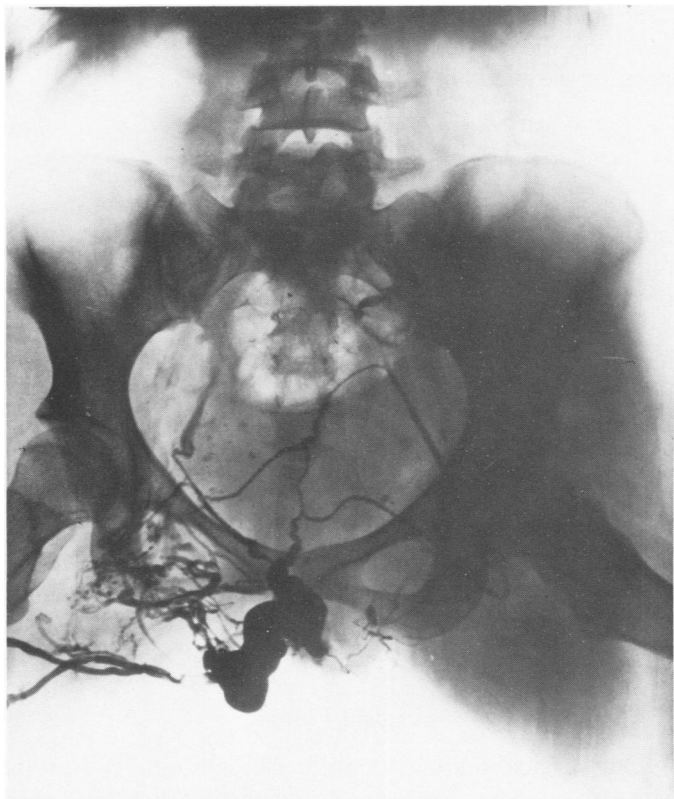


FIG. 13. Case 5. Vulvar venogram: high varicosity on the right labia majora linked to the right thigh by numerous collateral veins. The long vaginal veins are also opacified.

with secondary septicemia: another patient (Case 3) was saved by rectal amputation and the last (Case 6) by subtotal cystectomy.

Sex is not an important factor in the occurrence of these complications: there are 3 girls and 3 boys in our group.

Importance of the Venogram

The data collected from the venogram are particularly interesting; they are quite similar in our 6 cases. In 5 of the 6, the superficial femoral vein is not visualized and in two of these, Cases 1 and 6, the popliteal vein is not seen. Only in Case 3 do we see abnormal, irregular filling of the popliteal and superficial femoral veins instead of the usual absence of these veins. Moreover, the deep and the common femorals and the external iliac are injected in 3 cases out of 6 only. Cases 1 and 4 have normal opacification of these three veins but Case 5 has a very small deep femoral leading to a small common femoral. The internal saphenous vein is present in all except the last case (Case 6).

In all our cases, we thus have, on venogram of the thigh, absence of the anterior venous pathway through the superficial femoral vein. The compensation pathways are made up of the internal saphenous vein and by the

abnormal development of two venous groups: 1) The vein of the sciatic nerve (embryological remnant) large, constant in our 6 children; 2) Large veins along the external aspect of the inferior limb. At the higher part of the thigh these two collateral venous groups merge into a single trunk which is directed internally and posterior to the neck of the femur; it divides once again to penetrate into the pelvis through sciatic and gluteal notches, and terminates in a very large internal iliac vein of 14 to 22 mm in diameter. In two

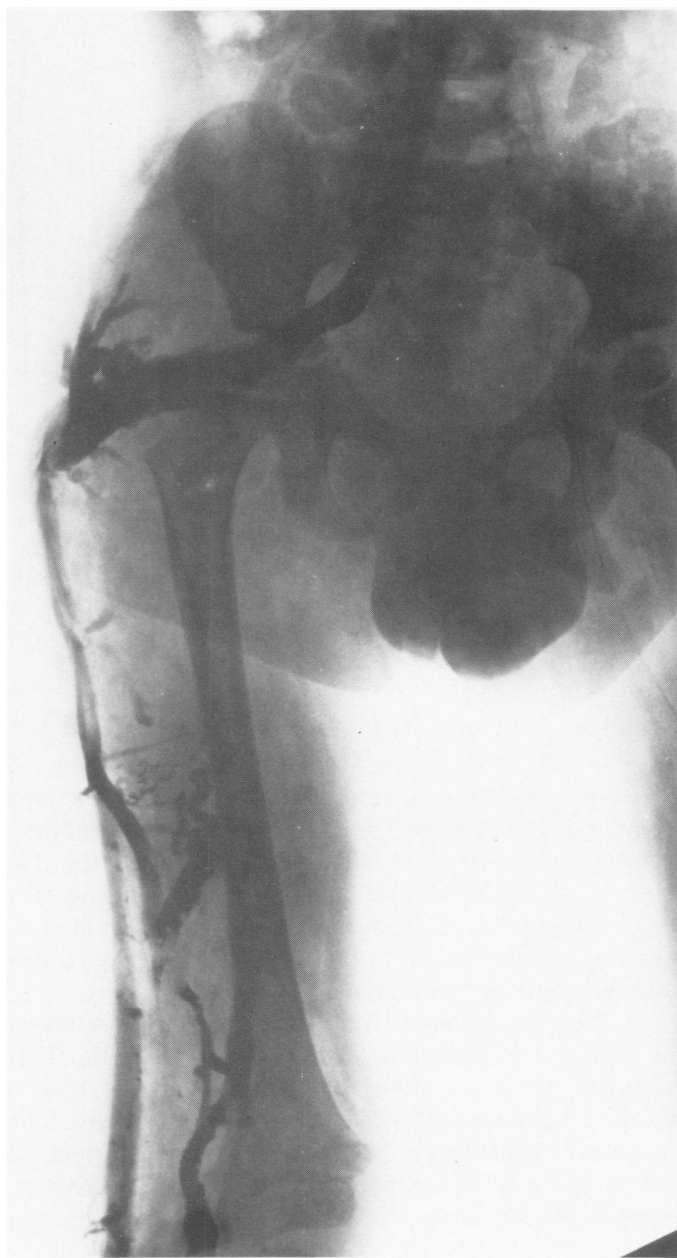

FIG. 14. Case 6. Venogram, January 22, 1974: large veins on the external aspect of the leg and important sciatic nerve vein fusing together behind the great trochanter in a unique trunk which penetrates into the pelvis by the sciatic notch and drains into the internal iliac vein.

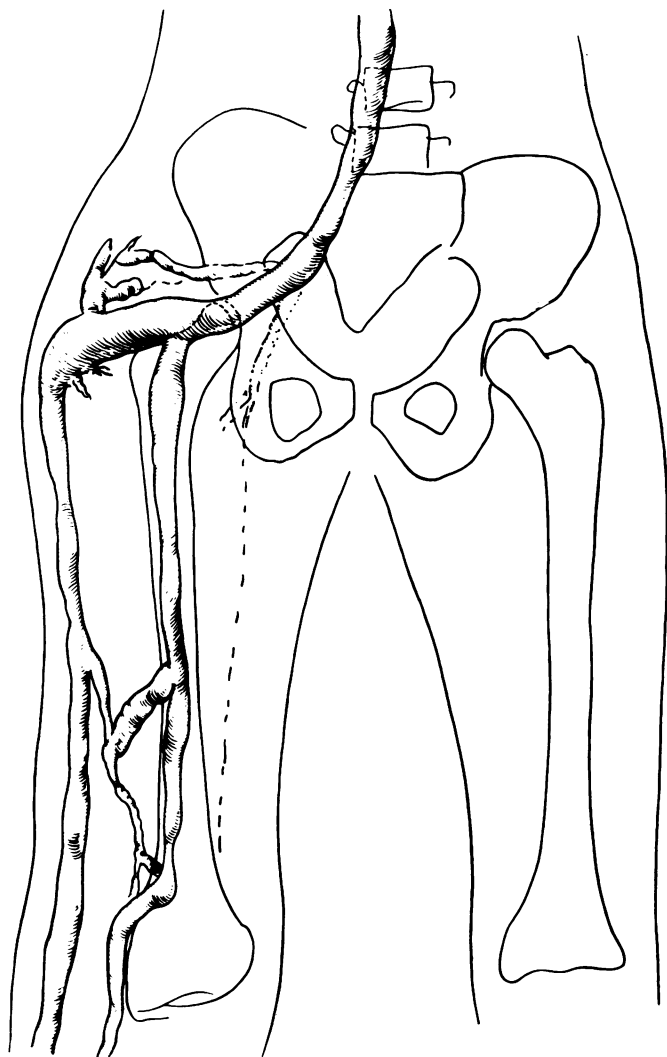


FIG. 15. Case 6. Sketch of the preceding venogram.

observations, there is retrograde injection from these veins into the perianal veins (Case 4) and the obturator vein (Case 5). In two children a vein follows the iliac crest to drain directly in the inferior vena cava. The retroadductor vein leads to the deep femoral vein creating an anastomosis between the sciatic nerve vein and the common femoral vein.

In 2 of our 6 cases, the venogram done elsewhere, prior to our examination, had been read as normal. In another, an arteriogram was interpreted as showing arteriovenous shunts in the thigh, the calf and the foot: however radiologically and surgically in this child we found agenesis of the popliteal and superficial femoral veins. On the other hand, on the urograms and the barium enemas of this young boy, done in Italy at the age of 12 and 20 months, note was judiciously taken of the enlargement of the retrovesical and retrorectal spaces by distension of soft tissues caused by the considerable development of varicosities. As far back as

1956, in our first case, we had described such a displacement of the pelvic segment of the ureter and of the horn of the bladder on the pathological side.

Rectal and Vulvar Venograms

Since 1966, in order to better understand the mechanism of rectal hemorrhages we have developed a technique for rectal venograms: the dye is injected into a hemorrhoidal vein and serial radiograms are obtained. In simple hemorrhoids just a few of the rectal veins are visualized and the superior hemorrhoidal veins are immediately opacified. In the syndrome of Klippel and Trenaunay with rectal hemorrhages, one can see highly developed venous plexus surrounding the rectal ampulla and venous stasis followed on the radiography; however the hemorrhoidal veins are not much dilated.

On several occasions we have followed the same technique and have injected varicosities of the vulva: these veins are also dilated and show evidence of venous stasis.

Surgical Findings

Our surgical findings confirm the data obtained on the venograms. The most important lesions affect the superficial femoral vein: it is totally absent in Case 6 and atretic in four cases (1, 3, 4 and 5). The popliteal vein is absent in two cases only (2 and 6); it is small in Case 5 and twice have we found it to be compressed by fibrotic bands (Cases 1 and 3); the popliteal has been

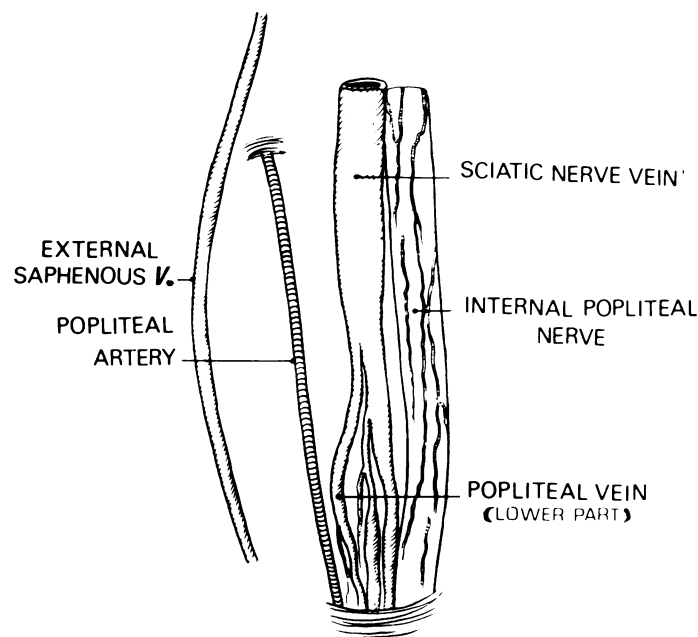


FIG. 16. Case 6. Drawing from surgical findings at the popliteal fossa: agenesis of the popliteal vein. Large sciatic nerve vein. Small varicosities in the sciatic nerve. The external saphenous ascends directly on the posterior aspect of the thigh.

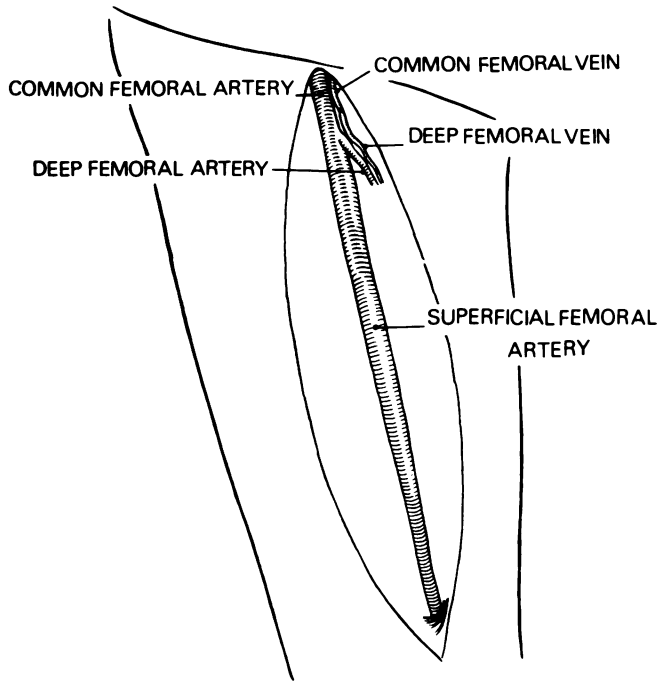


FIG. 17. Case 6. Drawing from surgical findings at the thigh: agenesis of the superficial femoral vein; atresia of the common and deep femoral veins.

found to be much dilated below an atretic superficial femoral vein in Case 4.

Each time we have operated upon a superficial femoral vein we have examined the common and the deep femoral veins: four times have we found this latter vein to be compressed in its retro-adductor segment; once it was atretic. As for the common femoral vein, it was normal in 4 and atretic in one case.

In summary, we have found an agenesis of the popliteal and superficial femoral veins once, an agenesis of the popliteal vein alone once, and in 4 children out of the 6 there was an atresia of the superficial femoral vein. Thus the underlying pathological factor resides in severe malformation of the deep veins of the thigh and knee.

Physiopathology

The physiopathology of these rectal, vesical or vaginal hemorrhages complicating a syndrome of Klippel and Trenaunay, can be explained from our venographic and surgical findings. In the 6 children the normal anterior venous pathway, consisting of the popliteal, superficial and common femorals leading to the external iliac, was interrupted at the popliteal level once (Case 2) and 5 times at the level of the superficial femoral vein. Because of this obstruction venous return borrows beside the internal saphenous vein, two other pathways of substitution: the sciatic nerve vein and large veins

of the external aspect of the limb. These two veins merge together behind the great trochanter into a single trunk which curves internally and then once again divides before penetrating into the pelvis by the sciatic and gluteal notches to flow into the internal iliac vein: because of this high flow this vein becomes enormous. According to Rouvière this vein in the adult normally measures 8 to 10 mm in diameter. In our 6 children, the diameter of the vein varied from 12 to 20 mm. Moreover this vein is without valves. The overflow in the internal iliac hinders drainage of the venous collaterals from the rectum, the bladder and the vagina. These collaterals will thus distend in a retrograde fashion up to their origin, creating large hemorrhoidal, peri and intra vesical and vaginal veins. The hemorrhoidal varices will rupture into the rectum causing external bleeding as seen in the 6 children. These venous ruptures in highly septic cavities will often be complicated by septicemia followed by death as we have seen in our first case, explaining the high fever in two patients and causing the death of our first patient.

In the same fashion veins of the bladder become involved: their rupture causes hematuria.

As the high vaginal veins also drain into the internal iliac, obstruction to the venous return has identical repercussions: varicose veins that rupture and cause vaginal hemorrhages.

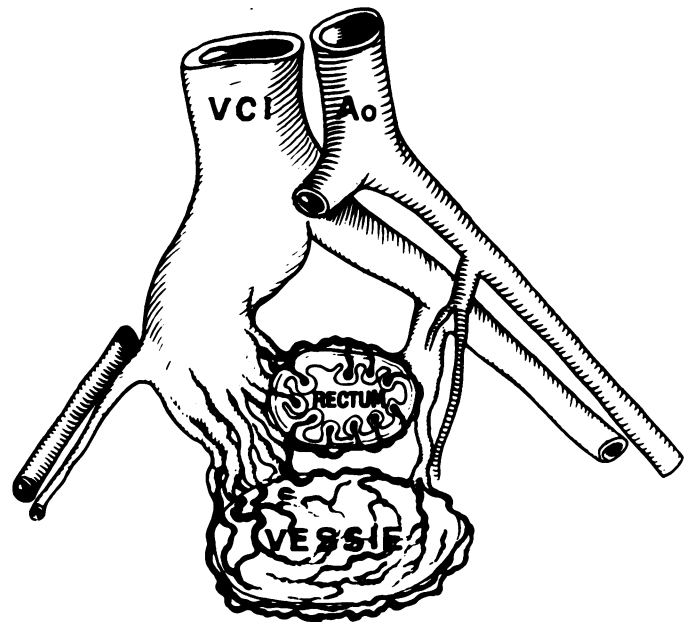


FIG. 18. Sketch outlining the physiopathology of rectal bleeding and hematuria in the syndrome of Klippel and Trenaunay. Because of the drainage of most of the blood from the inferior limb into the internal iliac vein, this vessel becomes considerably dilated. The collaterals in the pelvis (rectal and vesical veins), because of overloading of the hypogastric system, cannot drain normally. They thus become dilated as do their branches of origin, the hemorrhoidal and bladder wall veins. The rupture of these latter veins leads either to rectal bleeding or to hematuria.

The vulvar hemorrhages have another origin. When the femoral and external iliac veins drain poorly either because of congenital malformations or of thrombosis, not only do large varicosities appear in the suprapubic area but some also develop on the labia majora to allow drainage from the affected limb to the normal limb. Case 5 presented a considerable dilatation of the veins of the labia majora on the affected side. These varicose dilatations are troublesome and can lead to hemorrhages, complications which would necessitate resection of the labia majora. It is this process of shunting of blood from the affected limb to the normal limb through the genital veins that we have observed in Case 3 who developed an enormous varicocele on the affected side.

The absence of valves in the internal iliac vein most likely explains the clinical observation that most hemorrhages appear only after the child has begun to walk.

In this physiopathological discussion, we must outline the importance of the deep and common femoral vein. In our series of 588 syndromes of Klippel and Trenaunay treated surgically, we have noted 7 instances of agenesis, 102 of atresia and 85 of various malformations of the superficial femoral vein alone. Moreover we have 137 patients with associated malformations of the superficial femoral and of the popliteal veins. We have operated upon 331 malformations of the superficial femoral vein. When we dissect a small superficial femoral vein we often find a large deep femoral vein leading to a distended common femoral vein. Since 1960, we have freed this deep femoral vein on its entire length by disinsertion of the adductor major muscle. In so doing we have found, posterior to this muscle, a retro-adductor vein which is a prolongation of the deep femoral vein and which is often compressed by muscular bands or by arterial collaterals. As these obstructive bands are cut the deep femoral and the retro-adductor veins dilate allowing for a freer flow to the common femoral. We have also noted that this retro-adductor vein and its prolongation, the deep femoral vein, have numerous anastomoses with the abnormal and distended sciatic nerve vein so often present in Klippel and Trenaunay syndrome. In our cases the malformation of the anterior venous pathway (superficial femoral) brings on the development of the posterior venous pathway (sciatic nerve vein and large vein on the external aspect of the limb). The deep femoral vein and its prolongation, the retro-adductor vein, are collaterals which help return of a part of the posterior venous pathway blood

to the common femoral vein and to the external iliac vein. If surgically we can broaden this anastomosis we will relieve the internal iliac vein and thus establish a prophylaxis of rectal or vaginal bleeding. In children presenting a syndrome of Klippel and Trenaunay complicated by rectal or vesical bleeding, one must: 1) free the superficial femoral or popliteal-femoral malformation, and 2) complete this disengagement by freeing of the deep femoral and the retro-adductor veins by disinsertion of the adductor major. In Cases 2, 4 and 5, this technique was beneficial: the rectal bleeding ceased. In Case 6 there was an association of agenesis of the femoral, popliteal and internal saphenous with atresia of the deep and common femorals. The child had to undergo cystectomy following which rectal bleeding occurred. The last complication was controlled by liberating the small deep femoral vein.

Management of Persistent Hemorrhage after Surgical Freeing of the Veins

Our first patient twice underwent hemorrhoidectomy. These veins are so numerous and important that it is difficult to expect good results from such operations. However in the young child it can be tried in association with injections of these veins under rectoscopy. If the hemorrhage persists, the prognosis is poor as seen in our first case. In our third case, recurrence of severe rectal hemorrhages has led Prof. Loygue to perform an amputation of the rectum which stopped the bleeding. In the same manner Prof. Montagnani saved his patient (Case 6) after vesical hemorrhage, by doing a subtotal cystectomy when the patient was 33 months old.

Conclusion

Rectal bleeding and hematuria appearing in children with Klippel and Trenaunay syndrome are caused by overload of the internal iliac vein which drains the greater part of the venous return from the inferior limb. Venogram localized the venous malformation which should be explored surgically and corrected. Freeing up of the deep femoral and the retro-adductor veins allows for more flow to the common femoral and to the external iliac vein from the posterior venous pathway thus relieving the hypogastric vein. Should these vascular interventions fail one must turn to resection of the rectum for rectal bleeding and to subtotal cystectomy for massive hematuria in these children.