

# Facts and Fallacies of Common Bile Duct Obstruction by Pancreatic Pseudocysts

ANDREW L. WARSHAW, M.D., DAVID W. RATTNER, M.D.

Although it is commonly accepted that pancreatic pseudocysts can cause obstruction of the common bile duct, few documented examples of this phenomenon exist. Most cases of obstructive jaundice associated with pseudocysts appear to be due to fibrotic stricture of the intrapancreatic portion of the common bile duct, rather than to pressure on the duct by the pseudocyst. We report three additional cases, in two of which fibrosis and not the pseudocyst caused the biliary obstruction. This experience illustrates the imperative to perform intraoperative cholangiography after drainage of the pseudocyst and the necessity of a biliary-enteric bypass if bile duct obstruction has not been relieved by simple decompression of the pseudocyst.

ACCEPTED SURGICAL LORE holds that pancreatic pseudocysts may compress and obstruct the common bile duct. In fact we have found reports of only 18 such cases,<sup>1-6,12</sup> and most of those are either poorly documented or misleading. The vast majority of pseudocysts occur in patients with chronic pancreatitis, who therefore have other causes of intrapancreatic common duct obstruction, most prominently fibrotic stricture. In reporting three new cases of extrahepatic biliary obstruction associated with pancreatic pseudocysts, the purpose of this paper is to demonstrate the danger of assuming that decompression of the pseudocyst will relieve the biliary obstruction and to outline a strategy to assess the need for concomitant bilioenteric bypass.

## Case Reports

**Case 1.** A 49-year-old reformed alcoholic male was admitted for evaluation of chronic epigastric and back pain associated with known chronic pancreatitis. There was a tender palpable mass in the epigastrium to the right of midline. The serum amylase was twice the upper limit of normal and the serum alkaline phosphatase was three times higher than the limit of normal. The serum bilirubin was 1.6 mg/dl. Abdominal roentgenograms showed calcification in the pancreatic area. Ultrasonography showed a cystic mass in the head of the pancreas and dilatation of the extrahepatic bile ducts. Endoscopic retrograde cholangiopancreatography (ERCP) showed the pancreatic pseudocyst and demonstrated a long, smooth tapered stricture of the bile duct apparently curving around the pseudocyst and compressed by it (Fig. 1).

Reprint requests: Andrew L. Warshaw, M.D., Massachusetts General Hospital, Boston, Massachusetts 02114.

Submitted for publication: December 19, 1979.

*From the Surgical Services of the Massachusetts General Hospital and the Department of Surgery, Harvard Medical School, Boston, Massachusetts*

At operation the pseudocyst was drained into a Roux-en-Y loop of jejunum. The gallbladder, which had been tensely distended, seemed to empty partially. The immediate postoperative recovery was uneventful, but the serum alkaline phosphatase remained elevated.

Six weeks after discharge, the patient was readmitted with fever, leukocytosis, tender hepatomegaly and ascites. The serum bilirubin was 6 mg/dl, and the serum alkaline phosphatase was six times the upper limit of normal. At operation no trace of the pseudocyst remained. Intraoperative cholangiography showed complete obstruction to the passage of contrast material through the intrapancreatic portion of the common duct. A cholecystojejunostomy was performed. He remains well five years later.

**Case 2.** A 55-year-old man with known chronic calcific pancreatitis due to alcoholism was admitted for treatment of intractable abdominal pain. A tender mass was palpable in the epigastrium. The serum amylase was slightly increased. The serum alkaline phosphatase was 90 international units (normal < 40). The serum bilirubin was 2.8 mg/dl. Ultrasonography showed a cystic mass in the head of the pancreas, dilated proximal bile ducts, and a dilated pancreatic duct. Endoscopic retrograde cholangiopancreatography confirmed these findings and demonstrated the point of biliary obstruction to be a smooth, tapered, compressed portion of the common duct, conforming to the outline of the pseudocyst (Fig. 2).

After the cholangiopancreatography, he developed spiking fevers and was operated on urgently. The pseudocyst, situated in the head of the pancreas adjacent to the duodenum, was drained by a cystoduodenostomy distal to the ampulla. Intraoperative cholangiography performed after decompression of the pseudocyst, showed persistence of an intrapancreatic stricture (Fig. 3). Accordingly, a choledochoduodenal anastomosis was created. The dilated pancreatic duct was drained by a long lateral pancreaticojejunostomy (Roux-en-Y).

Postoperatively the serum amylase, alkaline phosphatase, and bilirubin concentrations returned to normal levels. An upper gastrointestinal series performed ten days after the operation showed that the tight stricture of the intrapancreatic portion of the bile duct remained unchanged (Fig. 4). He remains well six months later.

**Case 3.** A 29-year-old woman entered the hospital because of abdominal pain and vomiting. She previously had been admitted because of episodes of relapsing pancreatitis. The serum amylase was minimally elevated, but the alkaline phosphatase was 89 international units and the 5'-nucleotidase was 26 units (normal < 2.5 units). The serum bilirubin was 2.0 mg/dl. An upper gastrointestinal series suggested a mass widening the duodenal loop and impinging

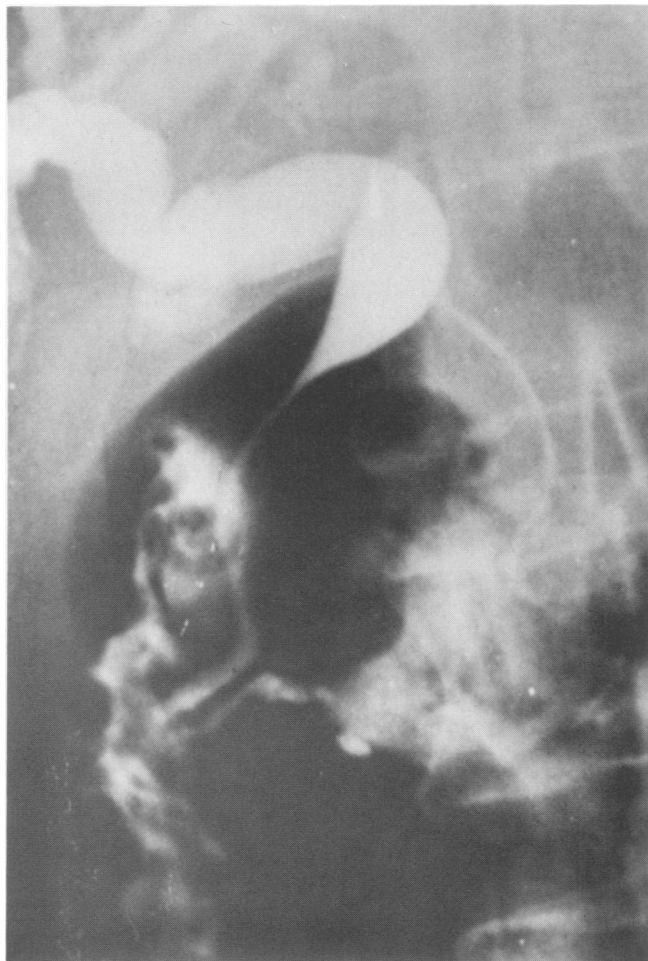

FIG. 1. Long, smooth narrowing of the common duct, curving around the pseudocyst in the head of the pancreas. The appearance falsely suggests compression by the pseudocyst (Case 1).

upon the lumen. A CT scan showed a large, cystic mass in the head of the pancreas (Fig. 5). ERCP showed the cyst adjacent to and deforming the intrapancreatic portion of the common bile duct (Fig. 6). Her surgical treatment consisted of a cyst-duodenostomy only. Postoperatively the serum alkaline phosphatase, 5'-nucleotidase and bilirubin returned to normal. She was readmitted seven months later for evaluation of transiently increased serum alkaline phosphatase and abdominal pain. Percutaneous transhepatic cholangiography at that time showed free flow of contrast material through the common duct into the duodenum (Fig. 7). There was no residual stenosis of the bile duct.

### Discussion

Jaundice occurs in 15–25% of patients hospitalized with pancreatitis.<sup>1,13</sup> The potential contributing causes comprise both hepatocellular dysfunction and mechanical factors including choledocholithiasis, constriction of the intrapancreatic portion of the common bile duct by pancreatic edema, fibrotic stricture of the intrapancreatic bile duct, or compression of the bile

duct by an adjacent pancreatic pseudocyst. It has been our experience that the last in this list of possibilities, biliary compression by a pseudocyst, is unlikely to be the sole cause of obstruction.

Sidel and colleagues<sup>10</sup> suggested four criteria for proving that jaundice is caused by a pancreatic pseudocyst: 1) presence of biliary obstruction; 2) demonstration at operation that the common duct is compressed by the pseudocyst; 3) relief of biliary obstruction by drainage of the pseudocyst; 4) complete disappearance of jaundice in the postoperative period. These criteria have been met infrequently in 18 previously reported cases of purported biliary obstruction by pseudocysts. Of 58 patients with pseudocysts reported by Waugh and Lynn,<sup>12</sup> five were jaundiced because of "pressure on the common duct . . . usually due to a cyst, but occasionally caused by associated pancreatitis." Bradley and Salam reported three cases of obstructive jaundice associated with a pseudocyst of the pancreas, but the obstruction in two of these was by fibrosis either

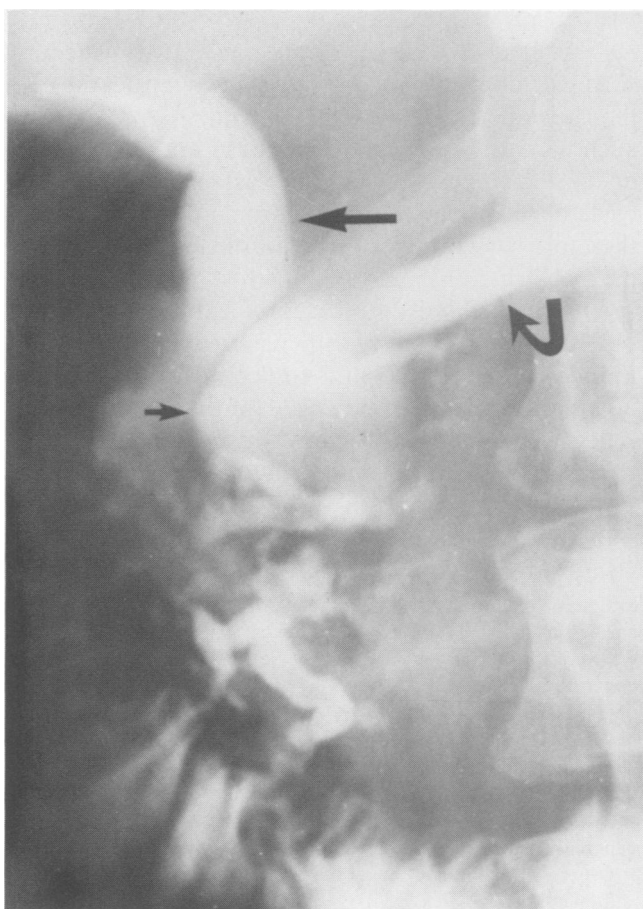


FIG. 2. Endoscopic cholangiopancreatogram showing a pseudocyst (short arrow) apparently compressing and obstructing the common bile duct (long arrow). The pancreatic duct is widened also (curved arrow) (Case 2).

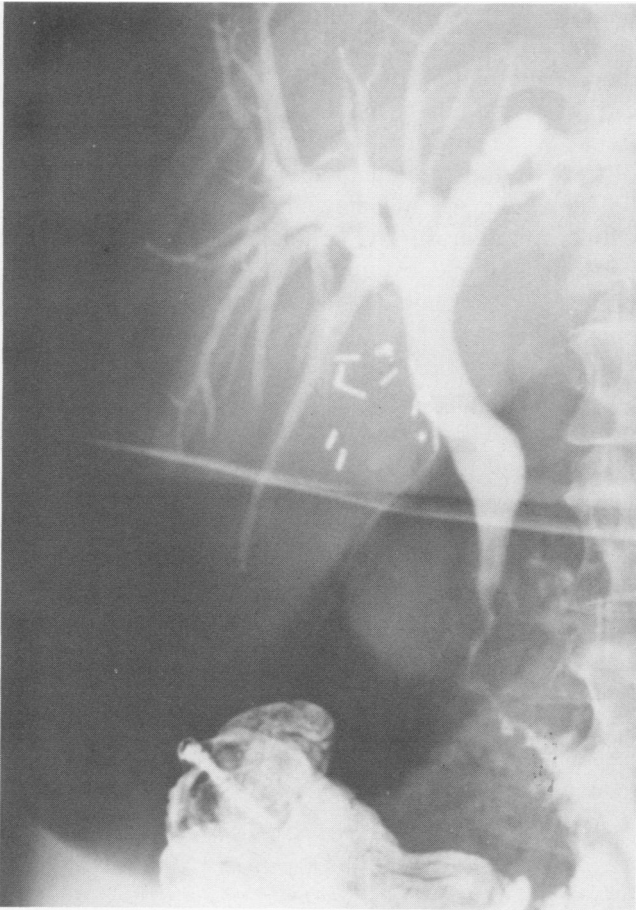


FIG. 3. Intraoperative cholangiogram showing persistence of the common bile duct stricture after internal drainage of the pseudocyst (Case 2).

at the ampulla or along the distal bile duct.<sup>1</sup> Gonzalez, et al.<sup>5</sup> presented five cases, but in only one of the five was jaundice relieved solely by drainage of the pseudocyst. Of the other four, the two who were treated by pseudocyst drainage alone remained jaundiced while the two who had a concomitant bilioenteric anastomosis recovered. Similarly the case reported by Falko, et al.<sup>4</sup> also had a choledochoduodenostomy at the time of pseudocyst drainage, and one of the two cases reported by McCollum, et al.<sup>6</sup> remained jaundiced after drainage of the pseudocyst. Two other single cases appear to have been successfully resolved by internal drainage of the pseudocyst alone.<sup>2,3</sup>

Our own experience is congruent with that outlined above and emphasizes the dangers in failing to relieve the obstruction of the biliary tree. Although the narrowed area of the bile duct apparently conformed to the configuration of the pseudocyst in the head of the pancreas, decompression and drainage of the pseudocyst failed to increase the lumen of the biliary channel in two of the three cases. In one of these the persisting

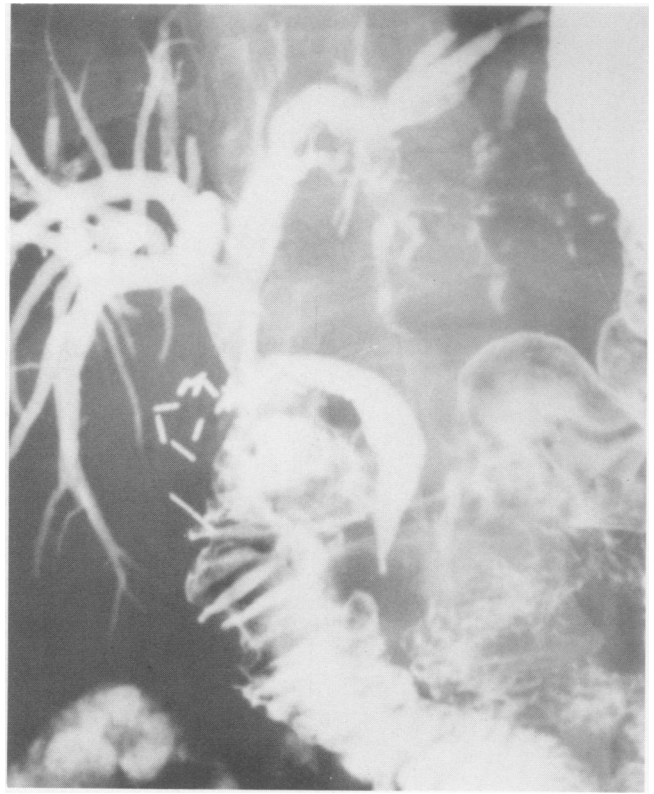

FIG. 4. Upper gastrointestinal series 10 days after pseudocystoduodenostomy and choledochoduodenostomy shows persistence of the stricture of the intrapancreatic portion of the common bile duct (Case 2).

obstruction was not appreciated until the patient returned with acute cholangitis and miliary liver abscesses six weeks later. In the other, intraoperative cholangiography after internal drainage of the pseudocyst demonstrated persistence of the intrapancreatic biliary obstruction and thereby indicated the need for a choledochoduodenostomy. Radiographs taken ten days later

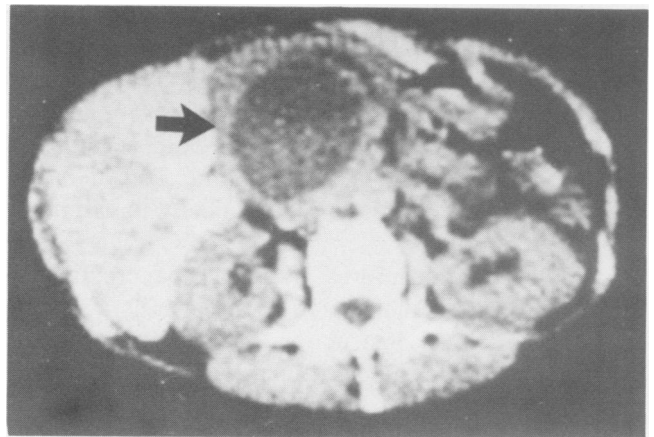


FIG. 5. CT scan showing a large pseudocyst in the head of the pancreas (arrow) (Case 3).

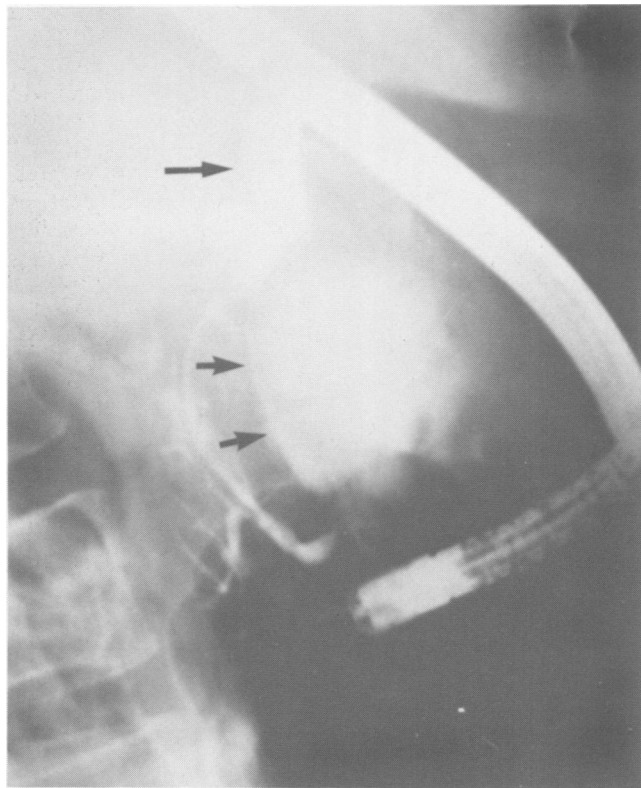


FIG. 6. Cholangiopancreatogram showing the relationship of the pancreatic pseudocyst (short arrows) to the partially obstructed common bile duct (long arrow) (Case 3).

again confirmed the presence of the permanent stricture. In only one of the three cases did pseudocyst drainage suffice as treatment for the biliary obstruction.

Most pancreatic pseudocysts occur in patients with chronic rather than acute pancreatitis, and all reported instances of common duct obstruction associated with pseudocysts have been in patients with chronic pancreatitis. Distal common duct stenosis due to fibrosis in the head of the pancreas occurs frequently in chronic pancreatitis<sup>13</sup> and may cause persistent obstructive jaundice<sup>11</sup> or intermittent jaundice at times of inflammation and edema.<sup>7,9,11</sup> In one series of 38 patients with chronic pancreatitis investigated by cholangiography, there was a long intrapancreatic stricture of the common bile duct in 11 patients.<sup>9</sup> Ten of the 11 patients had cholestasis during clinically apparent relapses of pancreatitis.

Common duct strictures in chronic pancreatitis require treatment if the degree of stenosis is sufficient to cause functional obstruction. The earliest and most reliable index of significant functional obstruction appears to be elevation of the serum alkaline phosphatase.<sup>8,11</sup> Although Sarles and Sahel state that these lesions are relatively infrequent in chronic pancreatitis and tend to minimize their importance,<sup>7</sup> our own ex-

perience has shown that untreated common duct stenosis in chronic pancreatitis can lead to persistent jaundice, acute and chronic cholangitis, secondary biliary cirrhosis, and biliary fistulas after choledochostomy.<sup>11</sup> Because the strictures are too long to be opened adequately by transduodenal sphincteroplasty, they must be bypassed.<sup>7,8,11</sup> We have had equal success using cholecystojejunostomy, choledochojejunostomy, or choledochoduodenostomy,<sup>11</sup> but others have expressed preference for choledochoduodenostomy,<sup>1</sup> or choledochojejunostomy.<sup>8</sup>

We suggest that obstruction of the common bile duct solely by a pancreatic pseudocyst is a rare event indeed, and that extrahepatic biliary obstruction in the presence of a pancreatic pseudocyst is more often caused by something other than the pseudocyst, most notably the irreversible fibrosis. We caution against relying on drainage of the pseudocyst to cure the biliary obstruction, and recommend intraoperative cholangiography after drainage of the pseudocyst. If

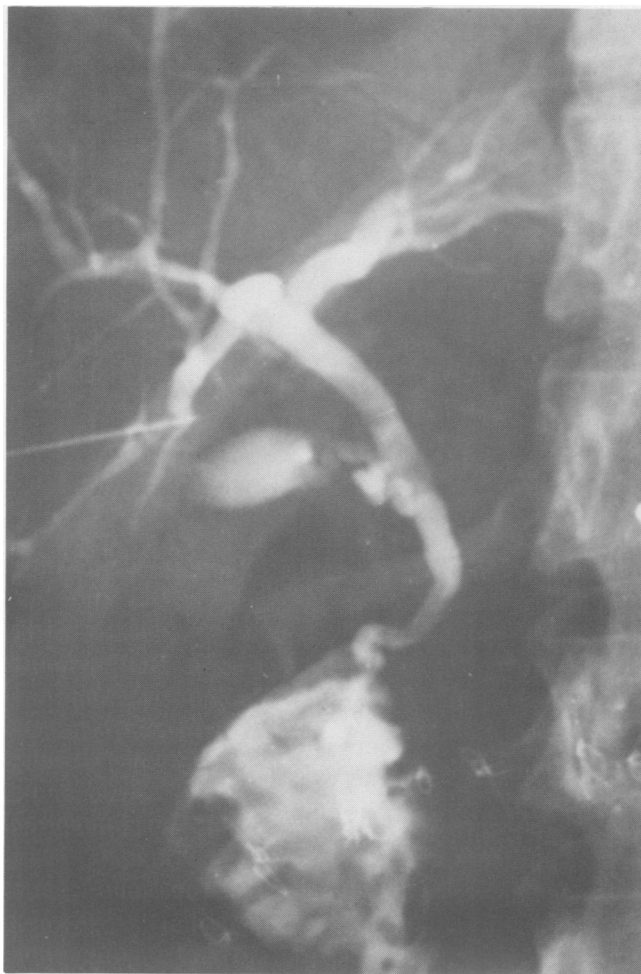

FIG. 7. Percutaneous transhepatic cholangiogram showing resolution of bile duct obstruction after pseudocystoduodenostomy (Case 3).

the intraoperative study does not prove unequivocal relief of biliary obstruction, a complementary bili-enteric bypass must be constructed. This course of action will also detect intraoperative injury to the bile duct consequent on cystduodenostomy<sup>5</sup> and will allow for compensatory biliary reconstruction.

### References

1. Bradley EL, Salam AA. Hyperbilirubinemia in inflammatory pancreatic disease: natural history and management. *Ann Surg* 1978; 188:626.
2. Chawla SK, Chawla K, Sossi AJ, LoPresti PA. Uncommon presentation of pancreatic pseudocyst. *Am J Gastroenterol* 1977; 68:154.
3. Christensen NM, Demling R, Mathewson C. Unusual manifestations of pancreatic pseudocysts and their surgical management. *Am J Surg* 1975; 130:199.
4. Falko JM, Mekhjian HS, Thomas FB. Silent pancreatic pseudocyst: an unusual cause of extrahepatic biliary obstruction. *Am J Dig Dis* 1975; 20:583.
5. Gonzalez LL, Jaffe MS, Wiot JF, Altemeier WA. Pancreatic pseudocyst: a cause of obstructive jaundice. *Ann Surg* 1965; 161:569.
6. McCollum WB, Jordan PH. Obstructive jaundice in patients with pancreatitis without associated biliary tract disease. *Ann Surg* 1975; 182:116.
7. Sarles H, Sahel J. Cholestasis and lesions of the biliary tract in chronic pancreatitis. *Gut* 1978; 19:851.
8. Schulte WJ, LaPorta AJ, Condon RF, et al. Chronic pancreatitis: a cause of biliary stricture. *Surgery* 1977; 82:303.
9. Scott J, Summerfield JA, Elias E, et al. Chronic pancreatitis: a cause of cholestasis. *Gut* 1977; 18:196.
10. Sidel VW, Wilson RE, Shipp JC. Pseudocyst formation in chronic pancreatitis: a cause of obstructive jaundice. *Arch Surg* 1958; 77:933.
11. Warshaw AL, Schapiro RH, Ferrucci JT, Jr, Galdabini JJ. Persistent obstructive jaundice, cholangitis, and biliary cirrhosis due to common bile duct stenosis in chronic pancreatitis. *Gastroenterology* 1976; 70:562.
12. Waugh JM, Lynn TE. Clinical and surgical aspects of pancreatic pseudocyst. *Arch Surg* 1958; 77:47.
13. Weinstein BR, Korn RJ, Zimmerman HJ. Obstructive jaundice as a complication of pancreatitis. *Ann Int Med* 1963; 58:245.