

Emergency Abdominal Wall Reconstruction with Polypropylene Mesh

Short-term Benefits Versus Long-term Complications

C. RANDLE VOYLES, M.D., J. DAVID RICHARDSON, M.D., KIRBY I. BLAND, M.D., GORDON R. TOBIN, M.D., LEWIS M. FLINT, M.D., HIRAM C. POLK, JR., M.D.

The acute replacement of full-thickness abdominal wall has been facilitated by polypropylene mesh (Marlex®) (PPM), allowing debridement of nonviable tissue and restoration of abdominal wall integrity without tension. However, no substantial long-term follow-up has been reported on the definitive wound coverage after the use of PPM in open wounds. Since 1976, we have placed PPM in 31 patients; 25 for infectious complication, three for massive bowel distension preventing abdominal closure, and three for shotgun wounds with extensive tissue loss. In 29 of 31 patients, the mesh was placed in heavily contaminated wounds; extensive fasciitis was present in 23 patients and 21 had intra-abdominal abscesses. Following mesh placement, 23 reoperations were required for continuing complications. No patients eviscerated, despite these multiple procedures. Polypropylene mesh was highly effective in restoring abdominal wall continuity. Despite advantages when PPM was used, significant long-term problems developed. Seven patients died from their primary illness in the postoperative period. Nine wounds were closed by granulation and subsequent split-thickness skin grafts. All nine developed mesh extrusion and/or enteric fistulae. Nine wounds healed by secondary intention, six developed enteric fistulae or continuing mesh extrusion. Full-thickness flap coverage after granulation provided the best means of wound closure. Polypropylene mesh had significant early advantages for providing abdominal wall integrity even in the presence of severe infection. However, long-term problems were common when wounds were closed to skin grafts or secondary intention. If the mesh cannot be completely removed, strong consideration should be given to myocutaneous flaps for coverage after the primary illness has resolved.

ABDOMINAL WALL LOSS after traumatic injury or necrotizing infection represents a most difficult problem for the patient and the surgeon. Primary closure under tension promotes wound ischemia that predisposes to dehiscence and evisceration and carries

From the Department of Surgery, University of Louisville School of Medicine, Louisville, Kentucky

an unsatisfactory mortality rate.⁶ Complex reconstructive efforts with undermining of tissues and rotation of flaps may induce invasive infection. The alternative of open wound management with delayed skin grafting over exposed bowel has merit but carries a high risk of early enteric fistula, and results in large abdominal wall hernias.⁸ Polypropylene mesh (Marlex®), originally developed to reinforce inguinal and incisional hernias,^{11,12} was used during the Vietnam War to replace abdominal wall loss after trauma.¹⁰ Subsequent reports on civilian wounds, primarily from Stone and colleagues,⁶ have been favorable, though largely anecdotal and with incomplete follow-up.¹⁻⁹

A retrospective analysis of our experience with polypropylene mesh was undertaken to evaluate the biologic properties of polypropylene mesh in the presence of overt infection, to assess the adequacy of immediate abdominal wall integrity, and to determine the best method of ultimate cutaneous coverage.

Materials and Methods

Polypropylene mesh (PPM) was used to replace the abdominal wall in 31 patients from 1976 to 1980. Twenty-five patients had necrotizing fascial infections, often with severe intra-abdominal infections, three patients had shotgun wounds with extensive abdominal wall loss, and three patients had massive bowel distension preventing closure. Patients with elective abdominal wall resection or with elective incisional hernia repair were excluded. Twenty-three men and eight women, ranging in age from 20 to 65 years (mean: 42 years), were treated. The initial operative procedure

Reprint requests: J. David Richardson, M.D., Department of Surgery, University of Louisville School of Medicine, 530 South Jackson Street, Louisville, Kentucky 40202.

Submitted for publication: February 20, 1981.

was elective in five patients (who subsequently developed infectious complications) and performed as an emergency in 26 patients; 12 of those patients sustained penetrating or blunt trauma and 14 patients had peritonitis and/or bowel obstruction. Prosthetic mesh was used most often in patients requiring reoperation. Mesh was placed in only six patients at the initial procedure, in 14 patients at the second, and in 11 patients at the third or later operation.

A single layer of PPM was secured in a subfascial plane with polypropylene suture. Initially, we used interrupted sutures, but in our later experience, we often used a running suture along each lateral aspect of the wound. Wounds with severe fasciitis were generally closed with interrupted sutures with the knots tied above the fascia. Omentum was placed under the mesh when possible. If drainage of the peritoneal cavity was indicated, it was performed by using the most direct approach, whether this was through the mesh or by a separate drain tract adjacent to or remote from the prosthetic material. Wounds were dressed regularly and kept moist with an antiseptic solution or saline, and abdominal binders were rarely used. Techniques used to complete the reconstruction with cutaneous coverage will be discussed in detail below. All patients were followed until death or to the point of complete wound stabilization.

Results

In 29 of 31 patients, the mesh was placed in a heavily contaminated field; extensive fasciitis prohibited primary wound closure in 23 patients, and intra-abdominal abscesses were present in 21 patients. Seven patients died (23%), six of uncontrolled infection. None of these deaths were attributable to the placement of mesh or a complication arising from its use. In the 24 survivors, 23 re-explorations were conducted after mesh placement. In the management of intra-abdominal complications the mesh allowed access to the abdominal cavity, even in the patient with multiple operative procedures. Additionally, it allowed drainage of purulent material between the interstices of the mesh in many patients. In no instance did the mesh appear to promote local infection and no patient eviscerated. Reoperation was not required for fasciitis alone, and no early enteric fistula developed in patients whose bowel was covered with PPM.

The preferred method of delayed wound management was to remove the mesh and perform satisfactory fascial closure. When this was not possible, we allowed the wound to granulate (either partially or completely covering the mesh). In our initial experience, we then performed a split-thickness skin graft over the granulated bed, if it appeared too large for closure by second-

ary intention. Table 1 shows the results with various methods of delayed wound closure. Six patients had the mesh removed and the fascia directly closed; two wound hernias occurred in this group. Both were subsequently successfully repaired without the use of prosthetic material.

Table 1 also indicates our results with closure by secondary intention and split-thickness grafting. There was one death directly attributable to the development of an intestinal fistula that required reoperation. In the group of patients with smaller defects that epithelialized, there was one colcutaneous fistula, and five patients continued to extrude mesh. Split-thickness grafting over the mesh eventually failed in all nine patients in whom it was used. All extruded the mesh within two months, and three developed fistulae. Four of the 15 patients in these groups developed abdominal hernias.

Because of our unfavorable experiences with skin grafting and epithelialization, we began to use full-thickness skin coverage over the mesh in patients in whom the PPM was necessary for continued abdominal wall continuity. In three patients, full-thickness flaps were mobilized to cover the granulating mesh. Although one small incisional hernia developed, it was secondarily repaired, and no patient developed mesh extrusion. The quality of the healed wound has been far superior to that obtained with the other two methods.

Case Reports

Case 1. A 56-year-old man sustained an abdominal gunshot wound, with severe contamination eventuating in generalized peritonitis, necrotizing fasciitis, and wound dehiscence that required the placement of PPM. Following multiple reoperations, his intra-abdominal sepsis was eventually controlled, and the mesh was covered with healthy granulation tissue that penetrated the entire mesh. Because removal of the mesh and a direct fascial closure was thought to be impossible, a split-thickness skin graft was applied. The graft healed promptly and completely and the patient's abdominal wall strength remained intact.

About six weeks after the skin grafting, the mesh began to penetrate the graft. Three months later the mesh was extruded in various areas and there was purulent drainage around the skin graft-mesh interface. Despite vigorous local care, this patient's condition worsened, requiring frequent visits to a physician. As the mesh became visible above the surface, a decision was made to trim the foreign body to skin level and, hopefully, promote healing. An attempt to accomplish this objective resulted in an enterotomy and a nonhealing small bowel fistula. Eventually, complete removal of the mesh was required and the fistula was resected and a primary small bowel anastomosis was performed. However, in removing the mesh, a large colotomy was made that necessitated a colostomy. Intra-abdominal sepsis and pneumonia developed and the patient died after a protracted hospital course.

Comment

This man was our only late death, as well as the only one directly related to the method of restoring

TABLE 1. Late Wound-related Morbidity

Closure Technique	Mesh Retention	No. of Patients	Late Mortality	Hernia	Enteric Fistula	Mesh Extrusion
Primary	removed	6	—	2	—	—
Granulation-epithelialization	retained	6	—	1	1	5
Split-thickness graft	retained	9	1	3	3	9
Full-thickness flap	retained	3	—	1	—	—

abdominal wall continuity. It illustrates the uniform ultimate failure we have had with split-thickness skin grafting even though the granulation tissue appeared to be of excellent quality and most skin grafts demonstrated initial complete survival.

Case 2. A 46-year-old man sustained shotgun wounds to the lower abdomen and groin that resulted in large perforations of the dome of the bladder, extensive luminal and mesenteric injury to the jejunum, a transection of the left common femoral artery, and a 12 cm full-thickness defect in the lower abdominal wall. After resuscitation, he underwent cystorrhaphy with placement of a suprapubic cystostomy, small bowel resection with primary anastomosis, and repair of the femoral artery wound. After the soft tissue defect had been completely debrided, there was inadequate tissue for primary closure, necessitating the use of PPM for reconstruction of the abdominal wall. The suprapubic tube was placed through a small hole in the mesh. The wound was dressed frequently but appeared to have superficial infection for the first seven days postinjury. In four weeks, the bladder had healed, the cystostomy tube had been removed, and the wound was granulating well over the mesh (Fig. 1). Because of our previous poor results with split-thickness skin graft coverage, we rotated a musculocutaneous flap based on the lateral circumflex femoral artery (Fig. 2). The wound healed primarily following flap closure and the patient has had no problems with extrusion or hernia for a follow-up period of over one year (Fig. 3).

Comment

This case demonstrated several important advantages of PPM. It was used in a heavily contaminated wound with multiple bowel and bladder perforations. The wound had early infection but it responded to local wound care with good granulation allowing a full-thickness skin coverage. The ability to bring drainage catheters through the mesh was a significant advantage. The use of full-thickness tissue, rather than split-thickness grafts, resulted in none of the sequelae seen in the latter method of skin closure.

Discussion

Adequate resection is the mainstay of therapy for tissue-destructive traumatic injury or necrotizing infection of the abdominal wall. With prosthetic materials available all questionably viable tissue may be debrided and abdominal wall integrity restored without tension. Favorable characteristics of PPM as the prosthetic material of choice include durability, pliability, and high-tensile strength, but, most importantly, host

tolerance in the presence of infection. Usher¹² has demonstrated that with adequate drainage, granulation will permeate the mesh and clear bacteria even with gross purulence, allowing the mesh to remain intact rather than being removed. It has been our observation that chronic infection develops only when there is a mesh-epithelium interface.

Our preferred technique for placement of the mesh was varied during the series. A single layer of mesh is placed in a subfascial plane and secured by either interrupted or running monofilament polypropylene sutures. In infected tissue where a tenuous closure is more likely, we generally use interrupted mattress sutures with the knots tied above the fascia.

Twenty-three of our patients have required reoperation; in the majority, the underlying bowel could be separated from the mesh although an occasional enterotomy occurred. In the occasional patients in which the sutures were exposed to the bowel, dense adhesions often resulted.

With the placement of PPM, abdominal wall integrity was immediately restored. Unraveling of the mesh did

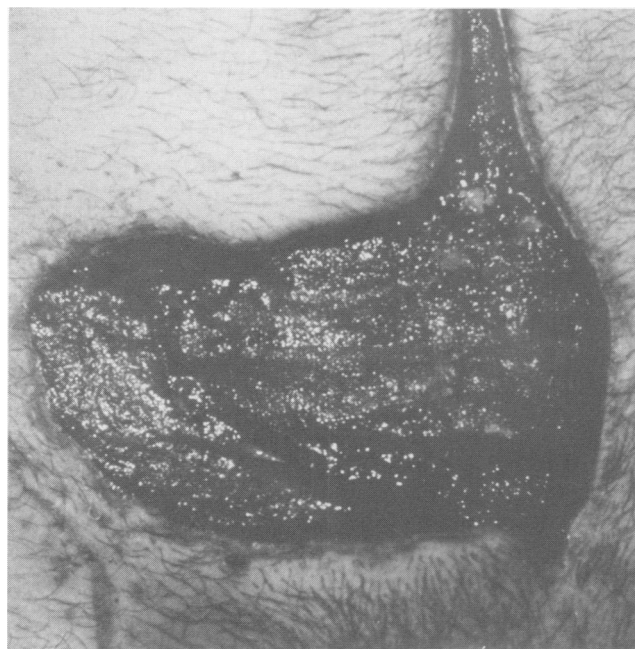


FIG. 1. One month postinjury the catheter had been removed and the wound was healing well over the mesh.

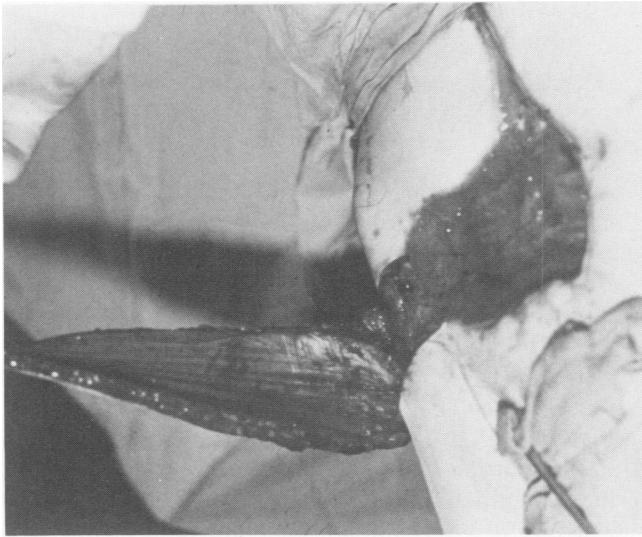


FIG. 2. A musculotaneous flap based on the lateral circumflex branch of the superficial femoral artery was used to cover the soft tissue defect.

not occur and no patient eviscerated. The mechanical stabilization of the abdominal wall allowed for greater patient mobility and enhanced pulmonary care. Dressing changes were not hazardous, with the mesh being well-tolerated by adjacent bowel. Within 12 hours of placement of the mesh, the peritoneal cavity is usually sealed in fibrin deposits.¹ When purulent drainage persisted in a wound several days after mesh placement, it prevented granulation tissue coverage and suggested an underlying abscess was present. If an abscess was suspected, the mesh was incised and digital exploration was undertaken. If an abscess was detected, drains were placed through the mesh if necessary, to provide the most dependable means of drainage. If their general condition warranted, patients were frequently placed on rotating beds to provide the most dependable means of drainage. Once the drainage cleared, the mesh edges were readily reapproximated with PPM suture.

Timing in completing the reconstructive effort with cutaneous coverage was dictated by the patient's clinical course. After all infection cleared, a period of at least 10–14 days was required for granulation tissue to permeate the mesh.^{1,5,6,10} In six patients, we removed the mesh early in the postoperative period and closed the fascia directly. However, in many patients, the size and location of the defect prohibits conventional closure. In such cases, previous authors recommend full-thickness flap coverage for small wounds but split-thickness skin grafts for larger wounds.⁵ However, the initial six reports with mesh coverage by split-thickness skin show breakdown due to mesh extrusion in at least seven of 17 patients.^{1,2,4,6,7,10} In the reports by Stone⁶ and Boyd,¹ three of five and four of eight pa-

tients, respectively, had extrusion of the mesh through the split-thickness skin graft. All other reports of successes have been isolated case reports.^{2,4,7,10} Our complete follow-up showed graft breakdown and mesh extrusion to occur uniformly within three months.

The cause for mesh extrusion appears to be related to two factors: 1) physical properties of the mesh itself, which tends to cause a "crinkling" or rolling up of the graft as it contracts with healing, and 2) a potentially poor blood supply when covered with skin grafts.

If graft extrusion does occur, it is essential that the physician treat it with respect since trimming away the mesh resulted in our only death. Mesh that appears at the wound edge as a result of wound contracture should be trimmed with great care to avoid the bowel. The mesh that is extruded by a crinkling, and directly overlies bowel cannot be safely trimmed because of the risk of intestinal fistulae.

While mesh extrusion has been previously documented after coverage by split-thickness skin,^{1,6} it occurs uncommonly with the use of mesh in elective hernia repair.¹¹ The well-perfused cushion of overlying skin and subcutaneous tissue in elective hernia repair appears less vulnerable to erosion than the split-thickness skin with "filtered" blood supply through the mesh. Based on our dismal long-term results with the use of split-thickness skin grafts, we do not recommend that they be used over mesh. Although our experience with full-thickness coverage is small, it has been uniformly successful. Full-thickness, well-perfused tissue mobilized from either adjacent abdominal wall or from flaps from the thigh or dorsal surface,

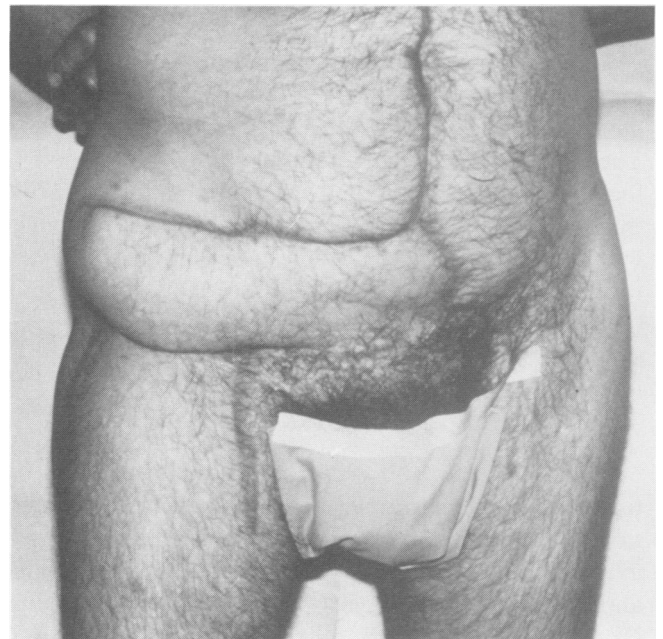

FIG. 3. The patient had good wound healing without infection, herniation or mesh extrusion.

provided uniquely secure coverage in all the patients so treated; it is our current preferred method when the mesh cannot be removed and the fascia closed primarily. Stone⁶ recently presented his complete experience with the use of synthetic mesh and found similar problems to ours with Marlex but had fewer problems with Prolene[®] mesh.

Thus, the use of polypropylene mesh in our large series of patients has presented the typical clinical dilemma of striking early success, which could not be achieved by other available means, versus long-term complications that are uniformly nuisances and occasionally, life-threatening. Hopefully, this study, which provides the only long-term follow-up of patients treated by these techniques, and our recommendations about eventual wound coverage will aid the surgeon in the management of these most difficult patients.

References

1. Boyd WC. Use of Marlex mesh in acute loss of the abdominal wall due to infection. *Surg Gynecol Obstet* 1977; 144:251.
2. Eng K, Casson P, Berman IR, Slattery LR. Clostridial myonecrosis of the abdominal wall: resection and prosthetic replacement. *Am J Surg* 1973; 125:367.
3. Gilsdorf RB, Shea MM. Repair of massive septic abdominal wall defects with Marlex mesh. *Am J Surg* 1975; 130:634.
4. Karakousis CP, Elias EG, Douglass HO. Abdominal wall replacement with plastic mesh in ablative cancer surgery. *Surgery* 1975; 78:453.
5. Markgraf WH. Abdominal wall dehiscence. *Arch Surg* 1972; 105:728.
6. Mathes SJ, Stone HH. Acute traumatic losses of abdominal wall substance. *J Trauma* 1975; 15:386.
7. McNally JB, Price WR, Wood M. Gas gangrene of the anterior abdominal wall. *Am J Surg* 1968; 116:779.
8. Mladick RA, Pickrell KL, Royer JR. Skin graft reconstruction of a massive full-thickness abdominal wall defect. *Plast Reconstr Surg* 1969; 43:587.
9. Pokorny WJ, Thal AP. A method of primary closure of large contaminated abdominal wall defects. *J Trauma* 1973; 13:542.
10. Schmidt HJ, Grinnan GLB. Use of Marlex mesh in infected abdominal war wounds. *Am J Surg* 1967; 113:825.
11. Usher FC. Hernia repair with Marlex mesh. *Arch Surg* 1962; 84:73.
12. Usher FC, Ochsner J, Tuttle LLD. Use of Marlex mesh in the repair of incisional hernias. *Am Surg* 1958; 24:969.