

Aspirin and Dipyridamole Decrease Intimal Hyperplasia in Experimental Vein Grafts

R. L. MCCANN, P-O. HAGEN, J. C. A. FUCHS

Release from platelets of a factor mitogenic for smooth muscle cells is a postulated mechanism for the pathogenesis of vascular intimal hyperplasia. In this study the effect of antiplatelet therapy was evaluated. Aspirin (165 mg twice daily) and dipyridamole (25 mg twice daily) were administered to six rhesus monkeys and six were given placebo only. Bilateral vein bypass grafts were placed in the iliac arteries. In addition, to evaluate the relative contribution of adventitial dissection and intimal injury, on one side the carotid artery and femoral vein were stripped of adventitia and on the other side the intima of these vessels were injured by the single passage of an inflated balloon tipped catheter. Animals were killed after 16 weeks. In grafts relative luminal area was determined by a photographic gravimetric method at three standard locations. Femoral veins and carotid arteries were classified as histologically normal or as exhibiting hyperplasia. All vessels with adventitial stripping were normal. All vessels with intimal injury in the placebo group except one exhibited intimal hyperplasia compared to the drug treated group in which over half were normal. Relative intimal area was significantly less in grafts from drug treated animals at all three locations and luminal area greater in two. These data suggest that vascular intimal hyperplasia can be reduced by treatment with antiplatelet agents.

INTIMAL HYPERPLASIA occurs in all autogenous vein grafts existing in the arterial system for more than a few weeks.^{2,7,16} In most patients the process appears to become static after several months and does not compromise graft function.^{8,16} In some grafts however the process is extensive and Imperato¹³ and Szilagyi²⁵ have reported on its clinical significance in peripheral bypass grafts. In up to 40% of patients undergoing a second coronary artery revascularization, the indication for operation is occlusive intimal hyperplasia of the original grafts.^{3,26}

The pathogenesis of intimal hyperplasia remains poorly understood. Carrel suggested that thickening of the vein graft wall represented an adaptation to arterial pressure, a view that has been widely ac-

*From the Department of Surgery
Duke University Medical Center
Durham, North Carolina*

cepted.⁵ However, arterial tissue, presumably already so adapted, is equally or even more subject to this process.^{9,17} Kennedy et al.¹⁵ and Bond et al.⁴ have emphasized the role of turbulence and Karayannacos et al.¹⁴ and Brody et al.⁵ the possible role of graft wall ischemia in the pathogenesis of intimal hyperplasia. Recently Fonkalsrud¹⁰ has focussed on the injury to the endothelium which is inherent in the transplantation procedure. Loss of this cell layer exposes the subendothelium to the circulating blood with resultant adhesion of blood cells to this new surface. Platelets contain a factor which is mitogenic for vascular smooth muscle cells and which is released upon contact with collagen.¹² These considerations have led several groups to investigate the effect of antiplatelet therapy on experimental intimal hyperplasia in arteries¹¹ and vein grafts.^{6,19} Brody et al.⁶ using a dog femoral artery bypass model were unable to demonstrate any benefit from dipyridamole alone. However, the degree of intimal thickening in the control grafts was quite small. Additionally the antithrombotic properties of dipyridamole alone are limited. Aspirin and dipyridamole act on platelets through different mechanisms²¹ and are synergistic. The present study was designed to examine the effect of continuous treatment with aspirin and dipyridamole on vascular intimal hyperplasia in a peripheral bypass model in nonhuman primates.

Materials and Methods

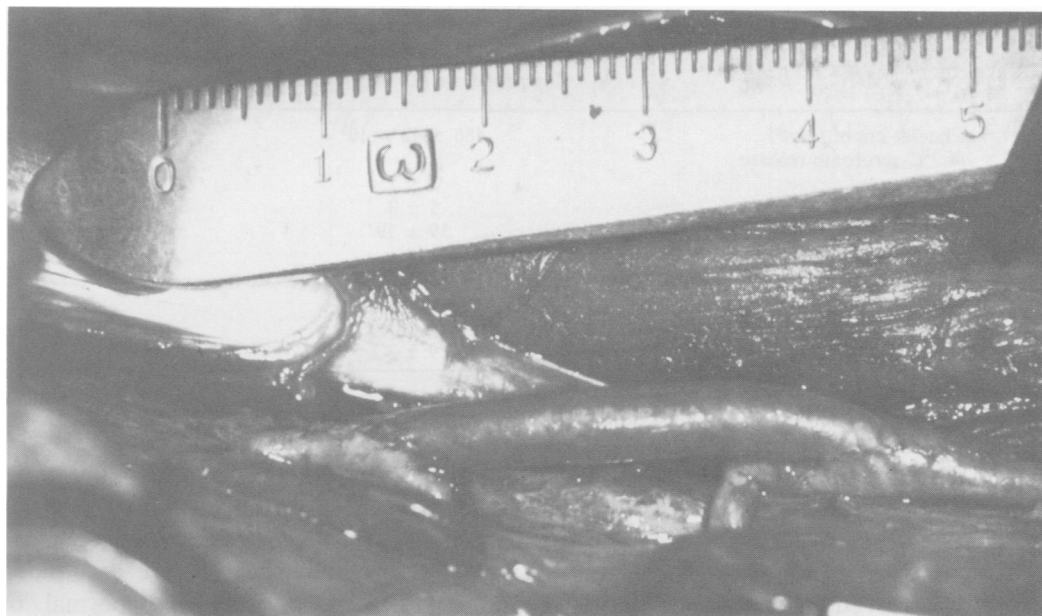
Twelve male rhesus monkeys weighing 4–6 kg at the start of the experiment were used. Aspirin (USP, 325 mg) and dipyridamole (Persantin®, 25 mg) tablets were purchased. One half aspirin tablet and one dipyridamole tablet were powdered in a mortar, mixed with baby food and given twice a day to half of the

Reprint requests: P-O. Hagen, Atherosclerosis Research Laboratory, Department of Surgery, Duke University Medical Center, Durham, North Carolina 27710.

Supported by U.S.P.H.S. Grants HL-15448 and HL-17369.

Submitted for publication: July 19, 1979.

FIG. 1. Photograph of vein bypass graft. Proximal artery is to the left.



animals. The other half of the animals received baby-food only. These preparations were given prior to regular twice daily feedings of Purina Monkey Chow® (#5038). Treatment was begun three weeks prior to operations and this time was used to perform platelet function studies.

Platelet counts and bleeding times were done by standard methods. Platelet survival time was measured by a modification of the method of Aster and Jandl.¹ Platelet rich plasma was obtained by repeated low-speed centrifugation of a 50 ml blood sample. One to two $\times 10^{10}$ platelets were obtained and labelled with 300 μCi ⁵¹Chromium, washed three times with buffer and reinjected along with the packed red cells from the original sample. Duplicate 0.5 ml blood samples were drawn at eight time points and the regression of counts per minute (CPM) on time extrapolated to zero. Platelet survival time was determined preoperatively and one week postoperatively.

Release of bound ¹⁴C-serotonin by platelet rich plasma in response to collagen was performed by the method of Zucker and Peterson.²⁷ Platelet rich plasma was incubated with ¹⁴C-serotonin (Amersham) and 0.5 ml aliquots challenged with collagen (acid soluble, Calbiochem) at a final concentration of 50, 100 and 200 $\mu\text{g}/\text{ml}$. After four minutes of shaking the mixture was centrifuged and released serotonin determined in the supernatant. Serum salicylate levels were determined by the clinical chemistry laboratory on samples drawn one hour after drug administration.

Each animal was operated on twice exactly one week apart. During each operation a jugular vein bypass graft was placed into an iliac artery. The artery was

completely prepared prior to harvest of the vein. Extreme gentleness was used in dissecting the vein and clamps were never applied to it. After carefully beveling each end of the vein 500 units of heparin were administered and an appropriate length of artery controlled with Dietrich clamps. Two end-to-side anastomoses were constructed within the controlled segment of artery so that when the segment of artery between the anastomoses was doubly ligated and divided retraction of the ends would produce as straight a graft as possible and minimal turbulence (Fig. 1).

In an attempt to further clarify the pathogenesis of vascular intimal hyperplasia each animal also was subjected to procedures on each carotid artery and femoral vein. Simultaneous with graft insertion, the carotid artery and femoral vein on one side were carefully stripped of all adventitia to interrupt any external source of blood supply to the vessel wall. On the opposite side these vessels were approached in as limited a manner as required for the insertion of a balloon tipped catheter (5F for artery and 6F for vein). These were inserted for a distance of 6 cm, inflated to the recommended volume and pulled back to injure the intima while leaving the adventitia intact. Which side underwent which procedure as well as the order of drug and control animals operated upon was determined from random numbers.

The animals were killed 16 weeks after their second operation. The left ventricle was cannulated and the right atrial appendage amputated. Blood volume was washed out by perfusion with buffered saline from a height of 130 cm until the right atrial return was clear.

TABLE 1. Platelet Function Tests

	ASA (165 mg p.o.b.i.d.) Dipyridamole (25 mg p.o.b.i.d.)	Baby Food Only	P
Platelet count (mm ³)	486 ± 42 × 10 ³	414 ± 126 × 10 ³	NS
% ¹⁴ C-serotonin release			
50 μg/ml	3 ± 2	12 ± 12	0.05
100 μg/ml	5 ± 3	36 ± 19	0.004
200 μg/ml	59 ± 19	81 ± 6	0.02
Platelet survival time (days)			
preoperative	6.82 ± 0.54	7.17 ± 0.55	NS
postoperative	6.49 ± 0.79	7.21 ± 1.09	NS
Bleeding time (minutes)	4.9 ± 1.3	2.3 ± 0.41	0.05
Salicylate level (mg/100 ml)	6.9 ± 2.2	—	

Data are mean ± 1 standard deviation.

At this time the perfusate was changed to 10% buffered formalin also from 130 cm. After five minutes of *in situ* perfusion the right atrial appendage was clamped which slowed but did not stop the rate of perfusion. After 30 minutes the vessels were dissected, removed and cannulated distant from the site of interest. The opposite end was ligated and fixation at venous or arterial pressure continued for an additional four hours. After removing periadventitial tissue the vessels were sectioned (5μ) perpendicular to blood flow and stained with the Verhoff von Gieson and Gomori trichrome stains. In the grafts, sections were taken 5 mm distal to the heel of the proximal anastomosis, in the center, and 5 mm proximal to the heel of the distal anastomosis. Relative luminal, intimal and medial areas were determined by a photographic gravimetric method. Each doughnut shaped section was photographed at 3× magnification (Medical Nikkor® 200 mm lens) and prints (Kodak polycontrast rapid RC® paper) were made at constant magnification. These were coded and examined by a blinded observer who cut out the area of the lumen, the intima and the media and these portions of the photographic paper were weighed. Reference was made to the original glass slide at higher power

magnification when necessary. Since the grafts were of variable size relative luminal, intimal and medial areas were calculated as a percentage of the total. Intimal changes in femoral veins and carotid arteries were much less severe and these vessels were classified as histologically normal or as exhibiting intimal hyperplasia.

Results

Results of platelet function tests are listed in Table 1. Whole blood platelet counts were similar in the two groups. Release of ¹⁴C-serotonin was significantly less at all three levels of collagen stimulus in platelet rich plasma from drug treated animals. No significant differences in platelet survival time were noted either between the two groups or within each group comparing the preoperative and postoperative determinations. It must be kept in mind that the absolute area of endothelial disruption by the operative procedures was small compared to the total endothelialized surface in the animals, and this fairly crude technique might not be sensitive enough to detect relatively small alterations in platelet luminal surface interactions. Bleeding time was significantly prolonged in drug treated animals. Salicylate levels were variable and examined at only one point in time. These simply confirmed that ingested drug was being absorbed.

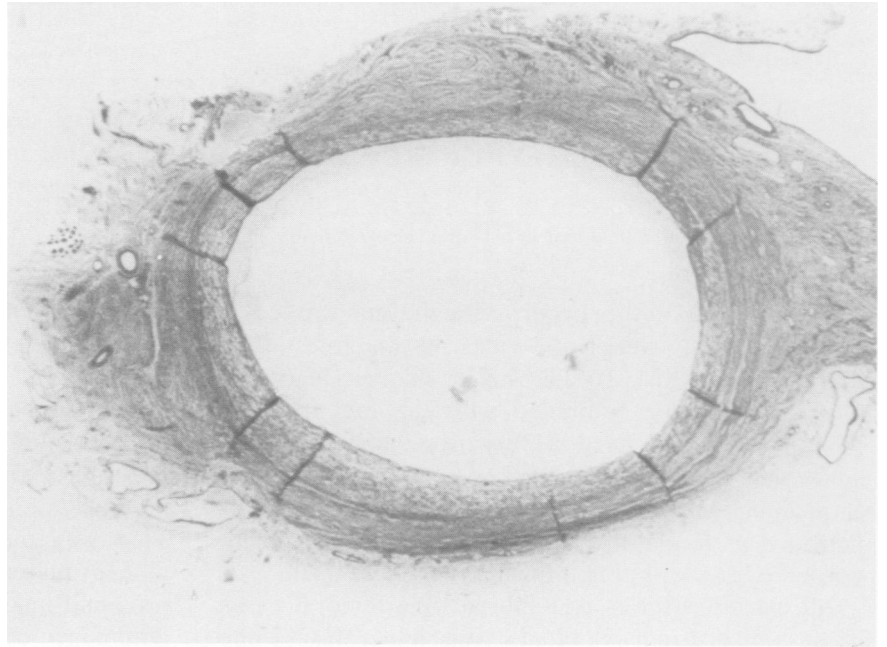
Technical difficulties precluded graft insertion on two occasions both in the same control animal. On one side the vein was unusually small and on the other an inadvertent intimal tear occurred in the iliac artery. All inserted grafts were patent at the time of sacrifice. Relative luminal, intimal and medial areas are shown in Table 2. Intimal hyperplasia was more exuberant near the anastomoses in grafts from both groups. At all three sampled locations intimal area was significantly less in grafts from drug treated animals (Figs. 2a and b). Reciprocally luminal area was significantly greater in the midportion and near the distal anastomo-

TABLE 2. Relative Cross Sectional Area in Vein Bypass Grafts

	Lumen	Intima	Media
Proximal			
ASA + dipyridamole	46 ± 20	26 ± 17	28 ± 11
control	39 ± 12	41 ± 12	20 ± 6
p	NS	0.02	0.05
Middle			
ASA + dipyridamole	70 ± 12	19 ± 11	10 ± 5
control	49 ± 15	45 ± 14	7 ± 3
p	0.001	0.001	0.05
Distal			
ASA + dipyridamole	64 ± 12	20 ± 12	16 ± 6
control	37 ± 10	51 ± 11	11 ± 3
p	0.001	0.001	0.03

ASA + Dipyridamole = aspirin and dipyridamole treated animals. Data are mean ± 1 standard deviation.

FIG. 2a. Cross section from the distal area of a graft from a drug treated animal with median degree of intimal thickening. Verhoff von Gieson, Gomori stains, original magnification 3 \times .



sis. Near the proximal anastomosis, medial hypertrophy compensated for reduction in intimal area and the mean 7% increase in luminal area from drug treated animals was not statistically significant.

All vessels that had been stripped of adventitia were patent and histologically normal except for external scarring (Table 3). The intima in these vessels re-

mained thin with no more than one or occasionally two cell nuclei beyond the internal elastic lamina. Five of the 24 vessels that had had passage of an inflated balloon tipped catheter could not be evaluated due to thrombosis. In two this was because of inadequate flow after repair of the venotomy site but in the others thrombosis was unrelated to obvious technical errors.

FIG. 2b. Cross section from the distal area of a graft from a control animal with median degree of intimal thickening. Verhoff von Gieson, Gomori stain, original magnification 3 \times .

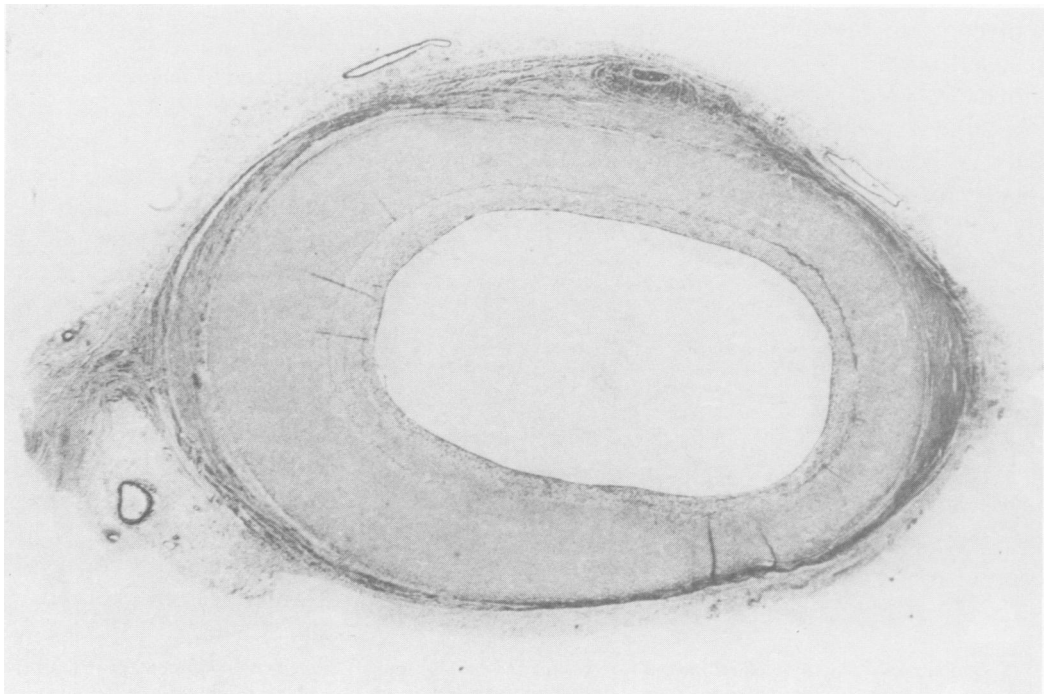


TABLE 3. Incidence of Intimal Hyperplasia in Carotid Arteries and Femoral Veins

	ASA + Di-pyridamole		Control	
	CA	FV	CA	FV
Adventitial stripping	0/6	0/6	0/6	0/6
Balloon passage	3/5	1/4	5/5	4/5

Number exhibiting intimal hyperplasia/number examined.

The thickness of the hyperplastic intima was comparable in both arteries and veins but much less than that in grafts (Fig. 3). The much smaller degree of intimal thickening combined with the fact that the veins even when fixed as described above remain somewhat flexible which makes sectioning into uniform doughnut shaped sections technically very difficult led us to classify these vessels as histologically normal or as exhibiting intimal hyperplasia.

All carotid arteries and four of five femoral veins in the control group exhibited intimal hyperplasia while only one of four femoral veins and three of five carotid arteries did so (Table 3). These observations are of course too few to draw valid statistical conclusions regarding the effect of the drugs. It is important however to note that intimal hyperplasia can be produced in venous tissue which subsequently exists under con-

ditions of venous hemodynamics quite easily and consistently by injury to the intima.

Discussion

Arterial pressure and hemodynamics, turbulence, endothelial injury and vessel wall ischemia have all been postulated to play a role in the pathogenesis of vascular intimal hyperplasia. Our data lend support to the hypothesis that intimal injury and interaction between subendothelium and circulating blood elements are important. These theories are not mutually exclusive however. It is conceivable that with arterial pressure and flow and the resultant streaming more formed elements are exposed to the luminal wall. It is also tempting to postulate that turbulence might affect the rate of re-endothelialization and might also continuously deposit and dislodge small platelet thrombi. That we could not demonstrate a statistically significant increase in luminal area in sections near the proximal anastomosis may have been due to a predominance of these factors at that site. On the other hand our data suggest that vessel wall ischemia at least as produced by adventitial stripping is not a significant factor in the pathogenesis of intimal thickening.

The immediate clinical implications of these conclusions remain to be determined. Intimal hyperplasia resulting in graft failure is a relatively rare occurrence,

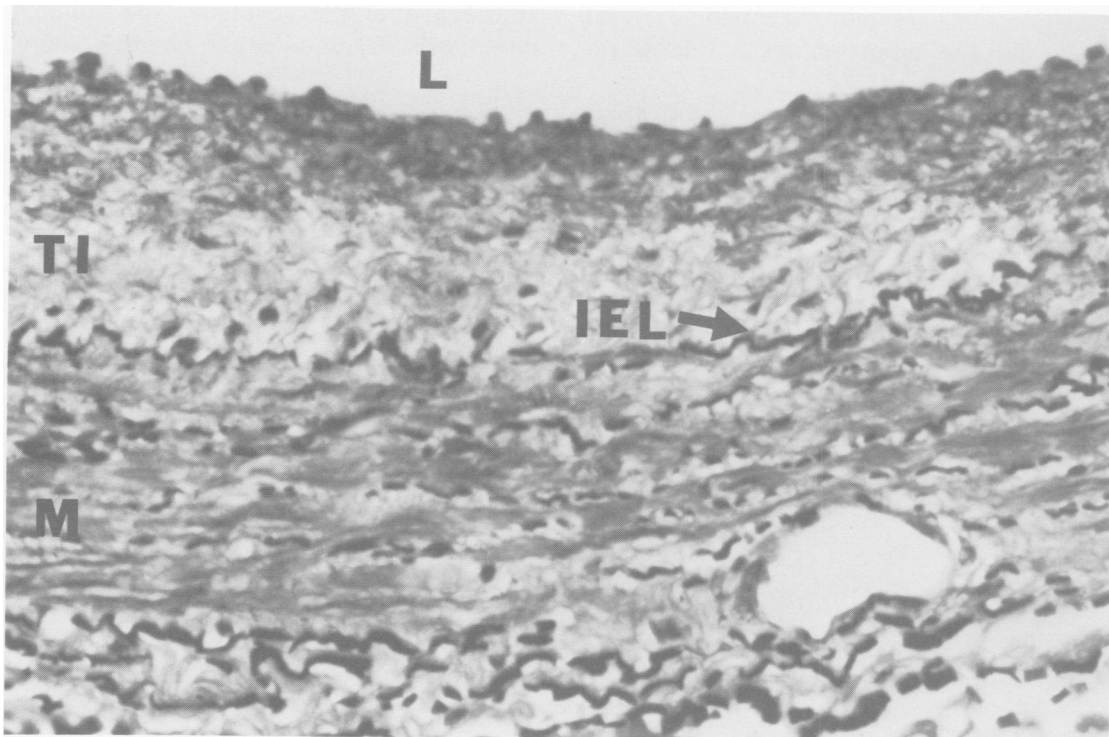


FIG. 3. Femoral vein 16 weeks after passage of inflated balloon tipped catheter. L = lumen, TI = thickened intima, IEL = internal elastic lamina, M = media. Note thickened intima on the luminal side of internal elastic lamina. Original magnification 100 \times .

particularly considering that antiplatelet therapy in surgical patients is not without some risk.^{20,23} However, the increasing reports of atherosclerosis in vein grafts^{3,26} coupled with the experimental evidence that vein graft intimal hyperplastic tissue may be even more susceptible to atheromatous degeneration than native arterial tissue^{18,22,24} underscores the need for a better understanding of these processes. Indeed Vouhe and Grondin²⁶ have described atheromatous changes in vein grafts removed from patients which are not localized lesions but rather are distributed throughout the intimal hyperplastic region of the entire graft. These authors further predict that atheromatous change may ultimately prove to be the single most important factor in late graft failure.

Although the issue of clinical use of antiplatelet drugs remains unsettled it should be noted that we have postulated that the interaction between platelets and blood vessel walls is important in the genesis of intimal hyperplasia. Gentle handling of the vein without stretching or distention or prolonged storage in unphysiologic environments with particular care for the fragile endothelium are precepts that carry no risk and may be of significant benefit.

References

1. Aster RH, Jandl JH. Platelet sequestration in man. I. Methods. *J Clin Invest* 1964; 43:843-855.
2. Barboriak JJ, Pintar K, VanHorn DL, et al. Pathologic findings in the aortocoronary vein grafts. *Atherosclerosis* 1978; 29:69-80.
3. Barboriak JJ, Batayias GE, Pintar K, Kornis ME. Pathological changes in surgically removed aortocoronary vein grafts. *Ann Thorac Surg* 1976; 21:524-527.
4. Bond MG, Hostetler JR, Karayannacos, PE, et al. Intimal changes in arteriovenous bypass grafts. Effects of varying the angle of implantation at the proximal anastomosis and of producing stenosis in the distal runoff artery. *J Thorac Cardiovasc Surg* 1976; 71:907-916.
5. Brody WR, Kosek JC, Angell WW. Changes in vein grafts following aortocoronary bypass induced by pressure and ischemia. *J Thorac Cardiovasc Surg* 1972; 64:847-854.
6. Brody WR, Brown JW, Reitz BA, et al. Effects of dipyridamole and methylprednisolone on intimal thickening in vein grafts. *J Thorac Cardiovasc Surg* 1977; 73:602-604.
7. Bulkley BH, Hutchins GM. Accelerated "atherosclerosis." A morphologic study of 97 saphenous vein coronary artery bypass grafts. *Circulation* 1977; 55:163-169.
8. Campeau L, Lesperance J, Corbara F, et al. Aortocoronary saphenous vein bypass graft changes 5 to 7 years after surgery. *Circulation* 1978; 58:Suppl. II, 170-175.
9. Curtis J, Stoney W, Alford W, et al. Intimal hyperplasia. A cause of radial artery aortocoronary bypass graft failure. *Ann Thorac Surg* 1975; 20:628-635.
10. Fonkalsrud E, Sanchez M, Zerubavel R. Morphological evaluation of canine autogenous vein grafts in the arterial circulation. *Surgery* 1978; 84:253-264.
11. Harker L, Ross R, Glomset J. The role of endothelial cell injury and platelet response in atherogenesis. *Thromb Haemostas* 1978; 39:312-321.
12. Ichnatowycz IO, Cazenave JP, Mustard JF, Moore S. Effect of indomethacin, sulfapyrazone and dipyridamole on the release of the platelet-derived growth factor. *Thrombosis Res* 1979; 14:311-321.
13. Imperato AM, Bracco A, Kim GE, Zeff R. Intimal and neointimal fibrous proliferation causing failure of arterial reconstructions. *Surgery* 1972; 72:1007-1017.
14. Karayannacos PE, Hostetler JR, Bond MG, et al. Late failure in vein grafts: mediating factors in subendothelial fibromuscular hyperplasia. *Ann Surg* 1978; 187:183-188.
15. Kennedy JH, Wieting DW, Hwang NH, et al. Hydraulic and morphologic study of fibrous intimal hyperplasia in autogenous saphenous vein bypass grafts. *J Thorac Cardiovasc Surg* 1974; 67:805-813.
16. Lawrie GM, Lie JT, Morris GC, Beazley HL. Vein graft patency and intimal proliferation after aortocoronary bypass: early and long-term angiopathologic correlations. *Am J Cardiol* 1976; 38:856-862.
17. McCann RL, Larson RM, Mitchener JS, et al. Intimal thickening and hyperlipidemia in experimental primate vascular autografts. *Ann Surg* 1979; 189:62-67.
18. McCann RL, Larson RM, Mitchener JS, et al. Late results of vascular autografts, histological and biochemical studies. Unpublished Manuscript.
19. Metke MP, Lie JT, Fuster V, et al. Reduction of intimal thickening in canine coronary artery bypass vein grafts with dipyridamole and aspirin. *Am J Cardiol (Abstract)* 1978; 41:411.
20. Michelson EL, Morganroth J, Torosian M, MacVaugh H. Relation of preoperative use of aspirin to increased mediastinal blood loss after coronary artery bypass graft surgery. *J Thorac Cardiovasc Surg* 1978; 76:694-697.
21. Moncada S, Korbust R. Dipyridamole and other phosphodiesterase inhibitors act as antithrombotic agents by potentiating endogenous prostacyclin. *Lancet* 1978; 1:1286-1289.
22. Rossiter SJ, Brody WR, Kosek JC, et al. Internal mammary artery versus autogenous vein for coronary artery bypass graft. *Circulation* 1974; 50:1236-1243.
23. Salzman EW, Harris WH, DeSanctis RW. Reduction in venous thromboembolism by agents affecting platelet function. *N Engl J Med* 1971; 284:1287-1292.
24. Scott HW, Morgan CV, Bolasny BL, et al. Experimental atherosclerosis in autogenous venous grafts. *Arch Surg* 1970; 101:677-682.
25. Szilagyi DE, Elliott JP, Hageman JH, et al. Biological fate of autogenous vein implants as arterial substitutes. *Ann Surg* 1973; 178:232-246.
26. Vouhe P, Grondin CM. Reoperation for coronary graft failure: clinical and angiographic results in 43 patients. *Ann Thorac Surg* 1979; 27:328-334.
27. Zucker MB, Peterson J. Effect of acetylsalicylic acid, other nonsteroidal anti-inflammatory agents, and dipyridamole on human blood platelets. *J Lab Clin Med* 1970; 76:66-75.