

**THE OCCURRENCE,  
STRUCTURE AND INNERVATION OF SLOW AND TWITCH  
MUSCLE FIBRES IN THE TENSOR TYMPANI AND  
STAPEDIUS OF THE CAT**

BY V. S. V. FERNAND\* AND A. HESS†

*From the Department of Physiology, University of Utah  
College of Medicine, Salt Lake City, Utah, U.S.A.*

(Received 26 August 1968)

SUMMARY

1. The muscle fibres of the tensor tympani and stapedius of the cat have been examined in the light microscope in teased preparations after cholinesterase staining and in the electron microscope.

2. In both muscles, two kinds of fibre have been found: those with an individual end-plate and those with multiple nerve terminals.

3. The stapedius fibres with an end-plate have fibrils regularly separated from each other by sarcoplasmic reticulum, a straight Z line, transverse tubular T system elements regularly occurring at the junction of A and I bands, an M line, an extensive sole plate area, and numerous post-junctional sarcolemmal infoldings under the nerve terminal. This type of muscle fibre in the tensor tympani has all of these features except that the fibrils are not well separated from each other, T system elements are absent in some sarcomeres, and a typical M line is absent.

4. Compared to the individually innervated fibres, the fibres with multiple endings have fibrils poorly separated from each other by sarcoplasmic reticulum, a jagged Z line, very few T system elements, a less extensive sole plate area, and essentially no folds under the nerve terminal. These fibres in both muscles have M lines.

5. Muscle fibres have thus been found in both the tensor tympani and stapedius of the cat which conform in their innervation, the structure of their motor nerve endings, and their internal structure to many of the morphological characteristics which are exhibited by slow muscle fibres elsewhere.

\* Present address: Department of Physiology, University of Ibadan, Ibadan, Nigeria.

† Present address: Department of Anatomy, Rutgers Medical School, New Brunswick, N.J., U.S.A.

## INTRODUCTION

Slow muscle fibres, which upon stimulation usually do not exhibit propagated action potentials and do not twitch, have been found physiologically in frogs (Kuffler & Vaughan Williams 1953) and chickens (Ginsborg, 1960). Such muscle fibres have morphological characteristics which differentiate them from ordinary twitch fibres (Hess 1960, 1961*a*; Page, 1965). In mammals, the only fibres thus far known to possess the morphological features typical of slow fibres occur in the extraocular muscles (Hess, 1961*b*, 1962; Dietert, 1965; Pilar & Hess, 1966; Mayr, Stockinger & Zenker, 1966). These muscle fibres in the extraocular muscles of cats have been shown to be slow fibres by physiological methods also (Hess & Pilar, 1963).

More recently, Erulkar, Shelanski, Whitsel & Ogle (1964) have presented evidence indicating that slow muscle fibres are present in the tensor tympani of the cat. Muscle fibres of both middle ear muscles in the cat have been studied in the present investigation to define further their structure and innervation in an attempt to determine if muscle fibres are present which have morphological characteristics conforming to those of slow muscle fibres previously described.

## METHODS

The tensor tympani and stapedius muscles of the cat have been studied. For electron microscopy, the muscles were removed from anaesthetized live animals, stretched and pinned on a cork board, and fixed in phosphate buffered glutaraldehyde (later treated with osmium tetroxide) or phosphate buffered osmium tetroxide. Pieces of muscle were dehydrated, embedded in Maraglas, and thin sections on formvar-coated copper grids were examined in an electron microscope. For the cholinesterase method, the muscles were fixed in 10% glyoxal treated with calcium carbonate, teased, incubated in acetylthiocholine iodide or butyrylthiocholine iodide, placed in ammonium sulphide solution, then teased further and mounted in glycerol.

## RESULTS

Essentially, the same results were found in muscle fibres from both the tensor tympani and stapedius; any differences will be mentioned below.

*Nerve endings.* The teased muscle fibres of the cholinesterase-stained preparations reveal two kinds of motor nerve ending (Pl. 1*A*). One is the typical motor end-plate (Pl. 1*B*). The end-plate endings occur in a relatively narrow band of innervation along the proximal third of the muscle. This compact ending stains darkly and appears to bulge from the muscle fibre. The end-plate endings of the stapedius muscle fibres (Pl. 1*F*) are larger and more conspicuous than those of the fibres in the tensor tympani. The muscle fibres of both muscles are very short (about 600 $\mu$ ); those with an end-plate have only one nerve ending on them. Sometimes, an accessory

end-plate is seen near the larger end-plate (Pl. 1 *D*). Other cholinesterase-stained areas are quite different in appearance and are attributed to stained musculo-tendinous origins and insertions of the muscle fibres.

The other type of ending is very different in appearance. It is seen as an elongated nerve terminal and is located away from the narrow band of motor end-plates (Pl. 1 *A*). This ending is seen as a series of small dots or lines running along the muscle fibres (Pl. 1 *C*, *E*, *G*). There are several of these endings on each muscle fibre, and there can also be more than one area of the muscle fibre where groups of these endings occur. These endings are thus multiple in nature. They do not necessarily appear like a bunch of grapes, but, nevertheless, are equivalent or analogous to the 'en grappe' terminals seen on muscle fibres elsewhere. Both the stapedius (Pl. 1 *G*) and tensor tympani (Pl. 1 *C*, *E*) have muscle fibres innervated in this manner. The fibres appear to be fewer in number in the stapedius than in the tensor tympani.

Both types of ending are revealed after incubation in acetyl- or butyrylthiocholine iodide; hence, both types of ending contain true and pseudocholinesterase. Both types of ending usually appear darker after acetylthiocholine iodide incubation than after incubation in butyrylthiocholine iodide; hence, there is more true cholinesterase than pseudocholinesterase around them. This is true of neuromuscular junctions elsewhere (Hess, 1962).

In electron micrographs, the end-plate endings (Pl. 2 *A*, Pl. 3 *A*) are seen as several units apposed to the muscle fibre, but separated from it by basement membrane material. All the units of the nerve terminal are covered by terminal Schwann cell. The nerve endings contain mitochondria and synaptic vesicles of relatively uniform size. The sole plate of the muscle fibre under the end-plate is extremely well developed, and there are large areas without muscle filaments. These areas contain large accumulations of ribosomes, some mitochondria and the Golgi apparatus. The post-junctional sarcolemmal infoldings are also well developed (Pl. 2 *A*, Pl. 3 *A*). They occur very regularly and extend quite deeply into the sole plate area.

The multiple 'en grappe' endings appear quite differently in the electron microscope (Pl. 2 *B*, Pl. 3 *B*). They are similar to end plates in that they are separated from the muscle fibre by basement membrane material, are covered by Schwann cell, and contain mitochondria and synaptic vesicles. However, the sole plate sarcoplasm, while large in amount and containing organelles similar to those described above, is not nearly as extensive as that seen under end-plate endings. Also, extensive post-junctional sarcolemmal infoldings are absent and the sarcolemma has only one or two short invaginations under the nerve terminal (Pl. 2 *B*,

Pl. 3*B*). It is this last histological characteristic which enables the differentiation of multiple 'en grappe' terminals from end-plate endings to be made easily in the electron microscope.

*Muscle fibres.* The stapedius muscle fibres with an end-plate (Pl. 4*A*) have fibrils well separated from each other by sarcoplasmic reticulum and a straight Z line across the width of the fibril. The transverse tubular T system is also well developed in these fibres and occurs regularly at the junction of the A and I bands (Pl. 4*A*). An M line is present.

The muscle fibres in the tensor tympani with an end-plate (Pl. 5*A*) are somewhat different from those of the stapedius. The fibrils are not as well separated from each other or regular in size. The Z line runs straight across the width of the fibril. The T system occurs at the junction of A and I bands, but apparently can be absent in some sarcomeres. A typical M line is not present. The thickening of the thick filaments in the middle of the A band occurs over a long length and hence the M line appears lighter, longer, and not as dark or obvious as usual. However, on one occasion, a muscle fibre with an end-plate in the tensor tympani was found with a typical M line.

The muscle fibres in both stapedius and tensor tympani with multiple terminals (Pl. 4*B*, Pl. 5*B*) are very different in appearance from those with an end-plate. The fibrils are irregular in size and relatively poorly separated from each other. The Z line running across the width of each fibril tends to be zig-zag or jagged. The T system is only poorly developed, does not occur regularly, and only a few aberrant elements can be seen frequently running longitudinally, rather than transversely, in the muscle fibre (Pl. 4*B*, Pl. 5*B*). These muscle fibres with multiple endings in both tensor tympani and stapedius have an M line (Pl. 4*B*, Pl. 5*B*).

#### DISCUSSION

In their internal structure, all vertebrate twitch muscle fibres thus far described have regular fibrils well separated from each other by large amounts of sarcoplasmic reticulum, a straight Z line in the fibril, and a regularly occurring T system, usually located at the level of the A-I junction (at the Z line in the frog). The twitch fibres of the stapedius also exhibit these features, while those of the tensor tympani vary slightly in that the fibrils are not well separated from each other and the T system apparently can be absent in some sarcomeres.

All vertebrate slow fibres are known to have irregular fibrils poorly separated by relatively scanty amounts of sarcoplasmic reticulum, a zig-zag or jagged Z line across the width of each fibril, and only aberrant T system elements not regularly disposed and sometimes running longi-

tudinally. The slow muscle fibres of the tensor tympani and stapedius also have these characteristics.

The significance of the presence or absence of the M line remains obscure. Most twitch fibres have an M line. The twitch fibres of the stapedius have a typical M line; those of the tensor tympani do not. The presence of an M line in slow fibres is inconstant. The slow fibres of the frog (Page, 1965), snake (Hess, 1965, 1967) and those of the extraocular muscles of the monkey (Mayr *et al.* 1966) do not have an M line. On the other hand, the slow fibres of the chicken and those of the extraocular muscles of the cat possess an M line (Hess, 1967). The slow fibres of the tensor tympani and stapedius also have an M line.

Twitch fibres are individually innervated, as are those of the tensor tympani and stapedius. Slow fibres have multiple nerve terminals, as do those of the tensor tympani and stapedius. Most twitch nerve terminals have well developed post-junctional sarcolemmal infoldings under them, although the sarcolemmal folds under the nerve terminal of the twitch fibres of the chicken posterior latissimus dorsi and the cat extraocular muscle fibres are not all conspicuous (Hess, 1967). The post-junctional sarcolemmal infoldings under the nerve endings of the twitch fibres of the tensor tympani and stapedius are prominent and extensive, thus conforming in this feature to most twitch fibres elsewhere. Slow fibres have virtually no folds under their nerve terminals; neither do the slow fibres of the tensor tympani and stapedius.

Muscle fibres have thus been found in both the tensor tympani and stapedius of the cat which conform in their innervation, the structure of their motor nerve endings, and their internal structure to many of the morphological characteristics which are exhibited by slow muscle fibres elsewhere. The middle ear muscles thus join the extraocular muscles as the only places where slow muscle fibres have thus far been found in mammals.

Although Blevins (1963, 1964) has presented excellent studies of the general anatomy of the tensor tympani and stapedius of the cat, he concluded (1963) that there are no distinctive morphological features that can account for a dual fibre system. In general, we can confirm the result of Erulkar *et al.* (1964) that slow muscle fibres are present in the tensor tympani of the cat. However, Erulkar *et al.* (1964) believe that slow fibres are not present in the stapedius. We also cannot confirm the description of Erulkar *et al.* (1964) that the T system is regularly present in both types of muscle fibre and occurs at the A-I junction in slow fibres and at the Z line in twitch fibres. Moreover, Erulkar *et al.* (1964) state that twitch fibres in the tensor tympani of the cat have M lines, while slow fibres do not. Our results, based on descriptions of the internal structure of the muscle fibre after identification of its nerve terminal in the electron microscope,

are exactly opposite. Smooth muscle fibres, which Erulkar *et al.* (1964) have described in the tensor tympani, have not been noticed in the present investigation.

The histograms of nerve fibre size and number presented by Blevins (1963, 1964) for both the tensor tympani and stapedius of the cat with many nerve fibres under  $8\mu$  indicate that there is an ample number of small motor nerve fibres available for innervation of the slow muscle fibres in these muscles. Also, since spindles are absent or rare in the tensor tympani and stapedius and small motor nerves in mammals usually serve to innervate intrafusal fibres, it is reasonable to infer that all the small motor nerve fibres in the nerves to the tensor tympani and stapedius serve to form multiple 'en grappe' terminals on the slow extrafusal fibres in these muscles.

Previously, several investigators have presented physiological and pharmacological evidence suggesting the existence of a dual fibre system in the intrinsic muscles of the ear of mammals (see Wersäll, 1958). Further physiological proof is needed to demonstrate definitely that the morphologically slow muscle fibres described in the present study are indeed physiologically slow. Since, in almost all situations in which slow fibres have been found, correlation exists between the morphological attributes of a muscle fibre and its physiological reaction to a nerve stimulus, it is indicated strongly that the muscle fibres, herein described as slow by morphological methods, will indeed be slow in physiological experiments. The reasons why slow muscle fibres are present in the muscles of the middle ear and what function they are performing there also await further experimental analysis.

This investigation was supported by U.S. Public Health Service Research Grants NB-05752 and NB-07662. V. S. V. Fernand was a Rockefeller Foundation Visiting Fellow from the University of Ibadan, Nigeria. A. Hess was in receipt of Research Career Development Award NB-22,494 from the Institute of Neurological Diseases and Blindness. Many thanks are due to Miss P. Cossey and Mr L. Bradshaw for their capable technical assistance.

#### REFERENCES

- BLEVINS, C. E. (1963). Innervation of the tensor tympani muscle of the cat. *Am. J. Anat.* **113**, 287-301.
- BLEVINS, C. E. (1964). Studies on the innervation of the stapedius muscle of the cat. *Anat. Rec.* **149**, 157-172.
- DIETERT, S. E. (1965). The demonstration of different types of muscle fibres in human extraocular muscle by electron microscopy and cholinesterase staining. *Investve Ophth.* **4**, 51-63.
- ERULKAR, S. D., SHELANSKI, M. L., WHITSEL, B. L. & OGLE, P. (1964). Studies of muscle fibers of the tensor tympani of the cat. *Anat. Rec.* **149**, 279-298.
- GINSBORG, B. L. (1960). Spontaneous activity in muscle fibres of the chick. *J. Physiol.* **150**, 707-717.
- HESS, A. (1960). The structure of extrafusal muscle fibers in the frog and their innervation studied by the cholinesterase technique. *Am. J. Anat.* **107**, 129-152.

- HESS, A. (1961*a*). Structural differences of fast and slow extrafusal muscle fibres and their nerve endings in chickens. *J. Physiol.* **157**, 221-231.
- HESS, A. (1961*b*). The structure of slow and fast extrafusal muscle fibers in the extraocular muscles and their nerve endings in guinea pigs. *J. cell. comp. Physiol.* **58**, 63-80.
- HESS, A. (1962). Further morphological observations of 'en plaque' and 'en grappe' nerve endings on mammalian extrafusal muscle fibers with the cholinesterase technique. *Revue can. Biol.* **21**, 241-248.
- HESS, A. (1965). The sarcoplasmic reticulum, the T system, and the motor terminals of slow and twitch muscle fibers in the garter snake. *J. cell Biol.* **26**, 467-476.
- HESS, A. (1967). The structure of vertebrate slow and twitch muscle fibers. *Investve Opth.* **6**, 217-228.
- HESS, A. & PILAR, G. (1963). Slow fibres in the extraocular muscles of the cat. *J. Physiol.* **169**, 780-798.
- KUFFLER, S. W. & VAUGHAN WILLIAMS, E. M. (1953). Small-nerve junctional potentials. The distribution of small motor nerves to frog skeletal muscle, and the membrane characteristics of the fibres they innervate. *J. Physiol.* **121**, 289-317.
- MAYR, R., STOCKINGER, L. & ZENKER, W. (1966). Elektronenmikroskopische Untersuchungen an unterschiedlich innervierten Muskelfasern der äusseren Augenmuskulatur des Rhesusaffen. *Z. Zellforsch. mikrosk. Anat.* **75**, 434-452.
- PAGE, S. G. (1965). A comparison of the fine structures of frog slow and twitch muscle fibres. *J. cell Biol.* **26**, 477-497.
- PILAR, G. & HESS, A. (1966). Differences in internal structure and nerve terminals of the slow and twitch muscle fibers in the cat superior oblique. *Anat. Rec.* **154**, 243-252.
- WERSÄLL, R. (1958). The tympanic muscles and their reflexes. *Acta oto-lar. suppl.* **139**, 1-112.

## EXPLANATION OF PLATES

## PLATE 1

Teased cat muscle fibres, cholinesterase stain. *A*, scale 100  $\mu$ ; *B-G*, scale 25  $\mu$ . *A-E*, tensor tympani; *F, G*, stapedius.

*A*. Multiple 'en grappe' endings are at the top left, end-plates are at the bottom right. *B*. End-plates. *C*. Multiple 'en grappe' endings. *D*. End-plates. Accessory end-plate on the right. *E*. Multiple 'en grappe' endings. *F*. End-plate. *G*. Multiple 'en grappe' endings.

## PLATE 2

Electron micrographs of cat tensor tympani. Scale 0.5  $\mu$ .

*A*. Nerve terminal with many post-junctional folds on a twitch fibre.

*B*. Nerve terminal with virtually no post-junctional folds on a slow fibre.

## PLATE 3

Electron micrographs of cat stapedius. Scale 1  $\mu$ .

*A*. Nerve terminal with many post-junctional folds on a twitch fibre.

*B*. Nerve terminal with virtually no post-junctional folds on a slow fibre.

## PLATE 4

Electron micrographs of cat stapedius. Scale 0.5  $\mu$ .

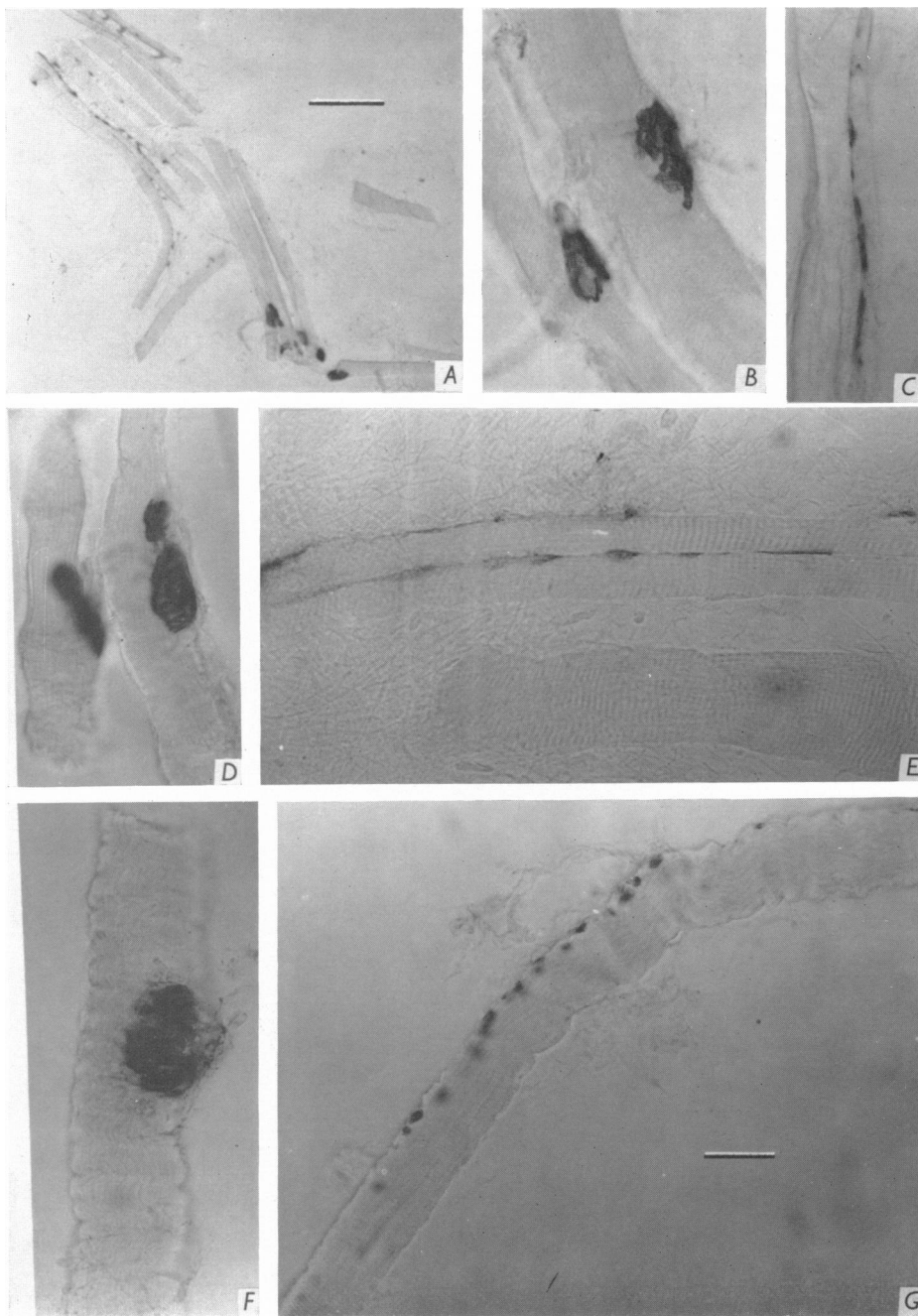
*A*. Twitch fibre. Fibrils well separated from each other, Z line straight, T system elements (arrows) regularly occurring, M line present (M). *B*. Slow fibre. Fibrils relatively poorly separated from each other, Z line jagged, T system elements not regularly occurring (only aberrant ones occur), M line present (M).

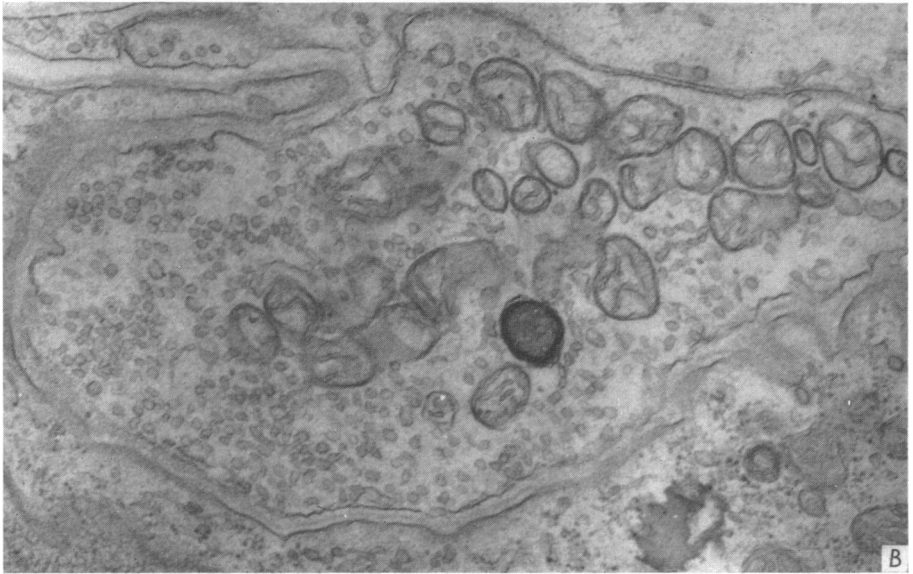
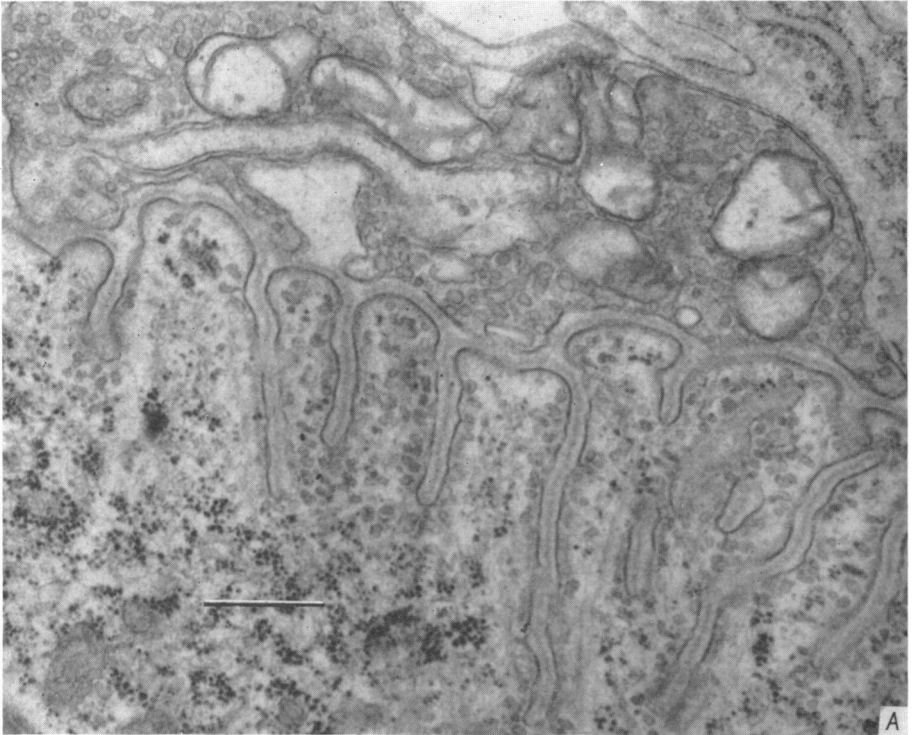
## PLATE 5

Electron micrographs of cat tensor tympani. Scale 0.5  $\mu$ .

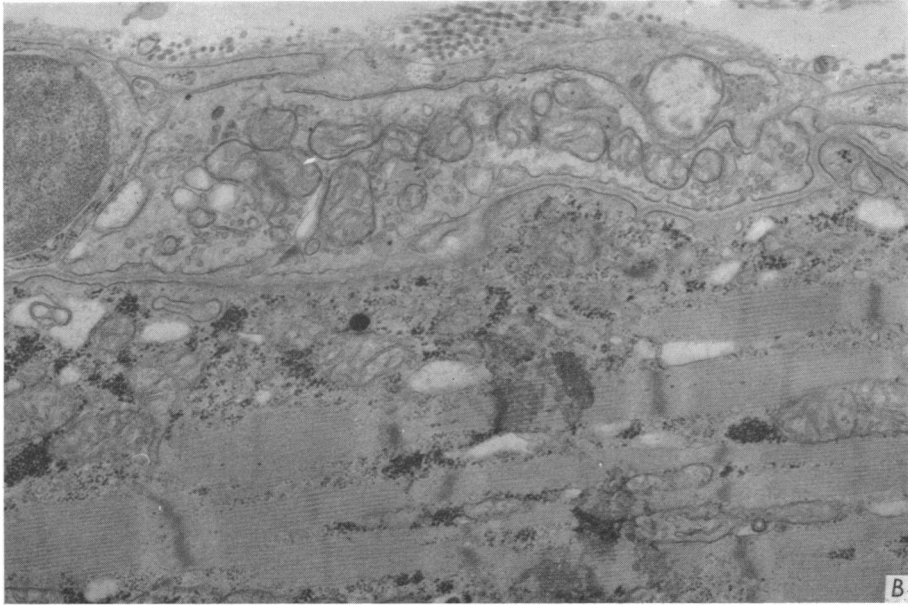
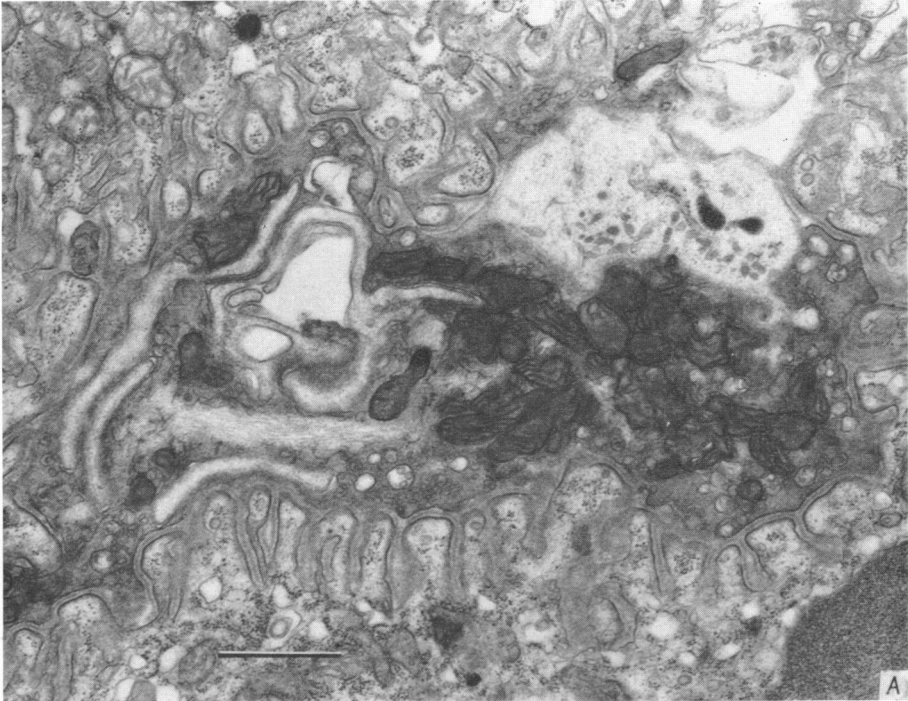
*A*. Twitch fibre. Fibrils not well separated from each other, Z line straight, T system elements (arrows) frequent but apparently absent in some sarcomeres, typical M line absent. *B*. Slow fibre. Fibrils poorly separated from each other, Z line jagged, T system elements not regularly occurring (only aberrant ones occur), M line present (M).







V. S. V. FERNAND AND A. HESS



V. S. V. FERNAND AND A. HESS

