

**PRESERVED VAGAL
VISCEROMOTOR FUNCTION FOLLOWING DESTRUCTION OF
THE DORSAL MOTOR NUCLEUS**

BY **FREDERICK W. L. KERR**

*From the Sections of Neurological Surgery and Neuroanatomy,
Mayo Graduate School of Medicine, Rochester, Minnesota, U.S.A.*

(Received 17 February 1969)

SUMMARY

1. The dorsal motor nucleus of the vagus was destroyed in cats and after survival periods greater than 10 days, the response of the heart, bronchioles, oesophagus and duodenum to electrical stimulation of the cervical vagi was investigated. The responses obtained from the vagus ipsilateral to the destroyed dorsal motor nucleus were compared to those obtained from the contralateral vagus and with normal controls. No significant differences were demonstrable.

2. The responses obtained from stimulation of the cervical vagus following chronic intracranial rhizotomy of the IXth, Xth and XIth nerves were also examined. Visceromotor responses were abolished in three experiments and atypical responses were obtained in two experiments.

3. It is concluded that the dorsal motor nucleus does not supply the vagal fibres which produce contraction of the smooth muscle of the bronchioles, oesophagus and duodenum, and that it is not the source of the cardio-inhibitory fibres

4. A simple method of destroying a longitudinal column of neurones is described.

INTRODUCTION

The dorsal motor nucleus of the vagus (D.M.N. hereafter) is generally believed to provide motor fibres to the smooth muscle of the bronchi and gut, as well as supplying the fibres mediating cardio-inhibitory effects (Marinesco, 1897; Molhant, 1910; Getz & Sirnes, 1949; Mitchell & Warwick, 1955 and many others).

Knowledge of the central connexions of the vagus developed slowly, and until the end of the last century the dorsal nucleus was regarded by most investigators as a vagal sensory relay area. Marinesco (1897), however, concluded from his studies on retrograde chromatolysis in the medulla

resulting from vagotomy, that the dorsal nucleus had motor functions and on cytological grounds he stated that it supplied innervation to the smooth muscle of the viscera; he therefore proposed that it should be called the '*noyau musculo-lisse*'.

The following year van Gehuchten (1898) was able to impregnate the axons of D.M.N. neurones with the Golgi technique and showed that they emerged with the vagal rootlets. This was confirmed by Cajal (1909) who also used the Golgi method; he showed that the axons travelled without giving collaterals in the medulla and stated that an occasional axon from the D.M.N. crossed to the opposite side, but he was unable to determine the subsequent course of these latter fibres. Kohnstamm & Wolfstein (1906) further consolidated the concept of the efferent nature of this nucleus by destroying it and demonstrating the efferent bundles of fibres by the Marchi technique.

While the efferent nature of the nucleus was thus clearly established, the conclusion that this nucleus innervated smooth muscle and supplied cardiodecelerator fibres was based on the distribution of the vagus in the periphery and on the cytological similarity of D.M.N. neurones to other neurones known to be autonomic in function (Marinesco, 1897).

The majority of authors have accepted this point of view. Miller & Bowman (1916) using electrical stimulation of the floor of the fourth ventricle concluded that the D.M.N. was a cardio-inhibitory centre. Laughton (1929) with a similar technique stated that it had a gastro-motor function and Kuru & Sugihara (1955) presented evidence that the D.M.N. and its vicinity produced gastric and jejunal contractions.

Bell & Lawn (1955), on the other hand, were impressed by the fact that when the tip of their stimulating electrode was in the D.M.N., contraction of the rumen in sheep was rarely evoked. They postulated that the parameters of stimulation were inadequate for the neurone somata, though effective for the axons, or that the number of gastric motor neurones is extremely small and thus they might be less accessible to the stimulus than in the bundles of intraaxial radicles. Calaresu & Pearce (1965*a, b*), studied cardio-inhibitory effects by inducing reflex bradycardia and, finding few neurones in the D.M.N. that they could correlate with the cardiodeceleration, concluded that cardio-inhibitory neurones in the D.M.N. must be widely dispersed or possibly located in some other area.

On anatomical grounds the classical concepts of D.M.N. function have been challenged on occasion. Kosaka & Yagita (1908) and Kosaka (1909) stated that the cardio-inhibitory neurones were located in the ambiguous nucleus, Hudovernig (1908) believed that the esophageal, gastric and bronchomotor neurones were located in the ambiguous nucleus and recently Szabo & Dussardier (1964) have suggested that the distal third of the

oesophagus is represented by neurones in the rostral pole of that nucleus.

These reports which query or doubt the localization of one or other of the visceromotor functions in the D.M.N. are a minority, however, and the evidence adduced has often been indirect (as in studies of retrograde chromatolysis) or conflicting, as in studies of electrical stimulation of the medullary nuclei (Miller & Bowman, 1916; Laughton, 1929; Bell & Lawn, 1955).

Because of these conflicting data a series of investigations has been carried out in this laboratory over the past several years in an effort to clarify some of the problems by employing a multidisciplinary approach.

METHODS

General plan. To test the function of the D.M.N., this nucleus was destroyed unilaterally and after survival periods adequate for all the axons arising in the D.M.N. to have degenerated, the visceromotor effects which could be elicited from stimulation of the distal end of the cut cervical vagus were investigated. The effects of chronic intracranial rhizotomy on cervical vagal visceromotor activity were also studied, since they had direct bearing on the interpretation of the experiments on the D.M.N.

Forty adult cats weighing between 4 and 9 lb. were used; of these thirty-five were used for the D.M.N. study and five for the rhizotomy study.

Using pentobarbital given intravenously, a posterior fossa craniectomy was done, the floor of the fourth ventricle was exposed for a distance of 5-6 mm anterior to the obex by careful retraction of the vermis, opening of the tela choroidea and retraction of the choroid plexus. Approximately 5 mm of the medulla below the obex was also exposed.

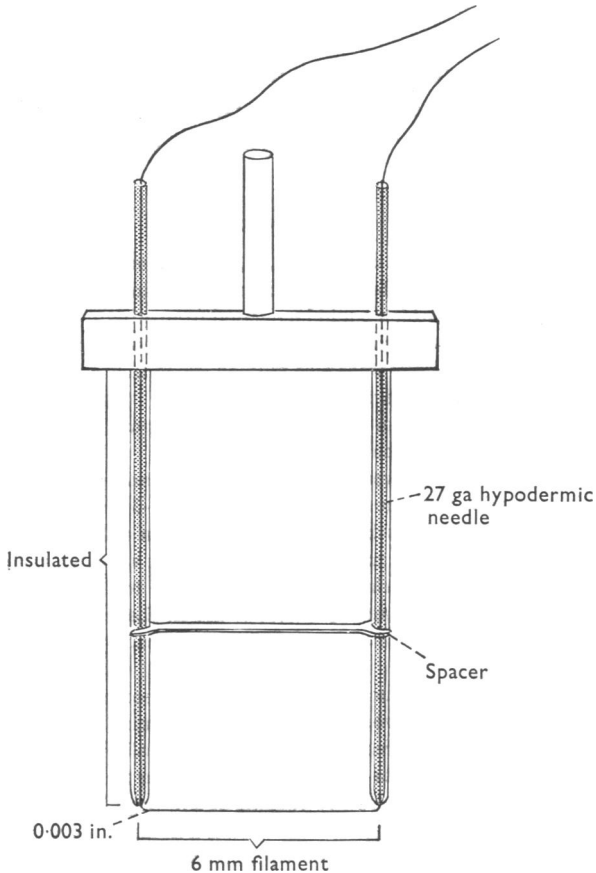
The D.M.N. extends from approximately 4.5 mm rostral to 2 mm caudal to the obex: from a deep paramedian position caudally where it lies at the level of the central canal it diverges gradually from the mid line and is superficially located in the floor of the fourth ventricle.

Initial attempts to destroy this nucleus using the usual needle electrode showed us that total destruction could not be achieved with any regularity and that this was an extremely time consuming procedure. For this reason the simple electrically heated filament illustrated in Text-fig. 1 was designed. It consists of an 0.003 in. diameter tungsten wire filament which is maintained taut between the ends of two lengths of 27-gauge hypodermic tubing within which the filament is crimped. The hypodermic tubing was insulated with plastic up to the point where the filament emerged from the tips. However, because of the temperatures reached, glass is now used for insulation; this is simpler and more effective and is best done by sweating a glass capillary tube onto the needles. The location of the D.M.N. was determined by measurement in serial sections from our collection and, using the obex and the mid line as a landmark, the filament was laid on the floor of the fourth ventricle with its rostral tip 4.5 mm from the obex and 2.0 mm lateral to the mid line, the caudal end being at the level of the obex 1.0 mm from the mid line; filament lengths varied from 3 to 6 mm and the length of tissue destroyed was measured with calipers. From the obex caudally the heated filament was used to cut down to the level of the D.M.N. which lies on a plane with the dorsal aspect of the central canal 1.0 mm from the mid line. The filament was heated by a brief electric current regulated from a Variac by an assistant; the current passed through an isolation transformer.

The wound was closed in layers excepting the dura which was left open, and prophylactic

penicillin (100,000 u.) was given intramuscularly. To try to reduce oedema resulting from the thermal coagulative lesion, 0.25 mg Decadron (Dexamethasone) was given intramuscularly just before the operation. Post-operatively 5% glucose in normal saline was given subcutaneously twice daily when required.

Rhizotomies. In five cats the IXth, Xth and XIth nerves were sectioned intracranially. This was readily accomplished by performing a left suboccipital craniectomy and if the resection of bone is carried well down and part of the atlanto-occipital joint is removed,



Text-fig. 1. Electrically heated tungsten filament used for making longitudinal lesions in the medulla.

excellent exposure of these roots is obtained. All the nerve fibres entering the jugular foramen were transected and the area was carefully examined using a nerve hook to be certain that no residual filaments had remained between the brain stem and the foramen. The incision was closed in layers leaving the dura open and the post-operative course was uneventful.

Test of vagal function. After survival periods of 10 or more days following the above described procedure, the animals were anaesthetized with pentobarbital given intravenously. Because of the well known depressor effect of barbiturates on autonomic responses a dose just sufficient to abolish the corneal reflex and reflex responses to pain was given; this was supplemented when necessary with ether during the abdominal phase of prepara-

tion. In this manner visceromotor responses of excellent amplitude were obtained and no discomfort was manifested by the animals.

Blood pressure and heart rate were monitored by a polyethylene catheter introduced into the abdominal aorta via the femoral artery. A catheter was introduced into the inferior vena cava and through it a slow infusion of normal saline was maintained; supplements of pentobarbital were given via this catheter when required. A tracheostomy was performed and a Y tube was secured tightly in the trachea; one arm of the Y tube was connected to a Harvard respiratory pump and the stroke volume was adjusted so that the visceral pleura just reached the parietal pleura as seen through bilateral thoracotomies which were done to eliminate any influence of the chest wall on the respiratory pressure tracing. The stroke volume was usually 75–100 ml. and the rate ranged from 8 to 12 per minute. The exhaust from the Harvard pump was allowed to bubble through approximately 1–2 cm water. The other arm of the tracheostomy Y tube was connected to a Statham air pressure strain gauge. Small water-filled balloons mounted on polyethylene catheters were introduced into the second portion of the duodenum and into the oesophagus via the mouth; the introduction of the balloon into the duodenum was done by gentle manipulation through a mid line laparotomy, since it is usually not otherwise possible to introduce a catheter into the duodenum of the cat. The correct location of both balloons was readily established by palpation.

All recording cannulae were connected to Statham strain gauges and the latter via pre-amplifiers to a Minneapolis Honeywell 1508 visicorder. Both vagi were then exposed in the neck, care being taken to avoid handling the nerve trunk directly during the process of separating it from the cervical sympathetic trunk, and the latter was resected. Both cervical vagi were transected in the upper part of their course before stimulation of either vagus was begun, to eliminate afferent effects, and stimuli were delivered to the distal ends of the nerve using bipolar silver electrodes.

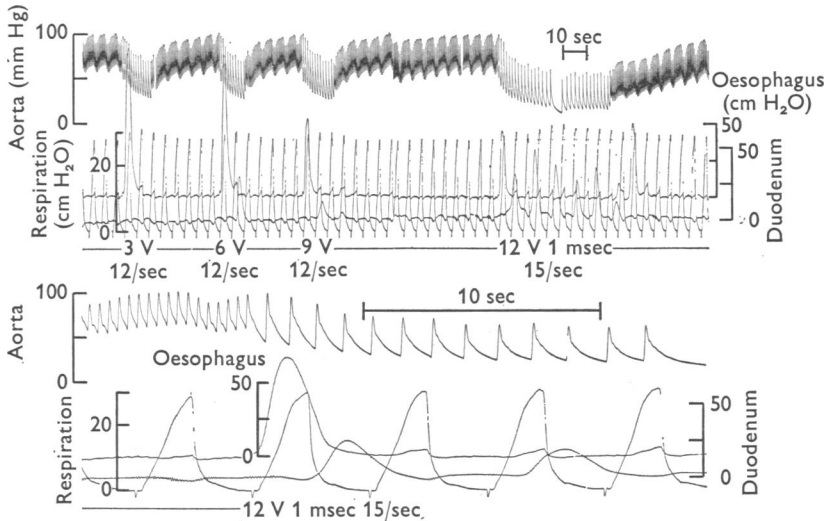
Using a Grass Model IV stimulator, 1 msec square wave pulses were delivered at frequencies of 6–20/sec and potentials of 0.5–20 V in trains lasting 10 sec each and separated from each other by intervals of 20 sec. In this manner it was hoped that the probability would be reduced of overlooking a response because of an inadequate stimulus. Long trains of stimuli lasting up to 2 min were occasionally used. The vagus contralateral to the side on which the D.M.N. had been destroyed was used as a control for that experiment and cats which had not had any prior procedures served as additional controls.

At the end of each procedure the location of each recording catheter tip was verified and recorded, specimens of the peripheral vagus nerve on each side at symmetrical and multiple levels were removed for electronmicroscopic study (to be reported) and the brain was perfused via the aorta with normal saline followed by 10% aqueous formalin. Serial frozen sections of the medulla were cut in the transverse plane at 20 μ thickness. Every 8th, 9th and 10th section was mounted and stained by the Luxol fast blue, the basic fuchsin and the Nauta technique respectively. Thus an accurate determination of the degree of destruction of the nucleus was obtained in every instance. In those experiments in which a portion of the nucleus was spared due to an inadequate lesion, the length of this preserved portion was simply determined by multiplying the number of sections in which neurones remained by the thickness of the sections.

RESULTS

Normal controls. The visceromotor responses obtained from stimulation of the distal end of the transected cervical vagus of the cat under light barbiturate anaesthesia in the present experiments are illustrated in Text-fig. 2. In the upper tracing the responses to progressive increases in the stimulus parameters are shown; bradycardia, contraction of the distal

oesophagus and rise in the resistance of the airway are evident. It may be noted that the amplitude of oesophageal response was commonly inversely proportional to stimulus intensity. In some experiments, however, the amplitude of this response increased with increases in stimulus intensity until the maximum response was reached. Duodenal responses were relatively unpredictable, and, as in this experiment, did not appear to be related in any quantitative manner to the stimulus parameters. With



Text-fig. 2. Visceromotor responses obtained from stimulation of distal end of the cervical vagus; both cervical vagi transected. Records from above downward in this and subsequent illustrations: aortic blood pressure, oesophageal pressure 1 cm above the cardia, pressure in the second portion of the duodenum and airway pressure (inflation corresponds to upstroke of the trace). A fine line has been drawn through the peaks of the resting respiratory pressure tracing to permit easier evaluation of the response to stimulation. The interrupted line at the foot of the record shows onset and end of stimuli.

more prolonged stimulation, however, a clear-cut train of duodenal contractions could usually be obtained, as in this example. Both the oesophageal and the cardiac responses were of short latency (1 sec or less) and the rise in respiratory pressure similarly had a brief latency. Duodenal responses had variable latencies from 2 or 3 sec up to 30 or 45 sec in some instances. Long trains of stimulation were used in those experiments in which no duodenal responses had been obtained, in an effort to initiate such activity. It was frequently observed that once the duodenum was activated in this manner, it became much more responsive to stimulation thereafter. Threshold for cardiac, oesophageal and respiratory responses was commonly 3V. 1 msec 6/sec while duodenal response threshold was slightly higher (6V. 1 msec 6/sec).

In the lower tracing run at ten times the speed of the preceding one, (Text-fig. 2) the shape of the respiratory pressure curve is shown. There is an increase in the rate of rise in the latter part of the ascending phase of this curve before peak pressure is reached, which is compatible with bronchiolar constriction. This point is noted since it might be objected that the increases in peak respiratory pressures were due to changes in lung compliance secondary to the bradycardia evoked by the same stimulus. Additional evidence against this latter possibility is that clear-cut rises in respiratory pressure curves have been observed in other experiments in which the cardiac component had been eliminated (F. W. L. Kerr and N. Hendler, unpublished). Thus the respiratory pressure rise appears to be a primary vagal effect on the lung and not secondary to bradycardia.

Responses following chronic rhizotomy. Five experiments were done in which the rootlets of the vagus together with those of the spinal accessory and the glossopharyngeal nerves were transected intracranially and after survival periods of 4 days to 2 weeks, testing of vagal visceromotor activity was carried out. No cardiac or duodenal responses were evoked in any of these experiments.

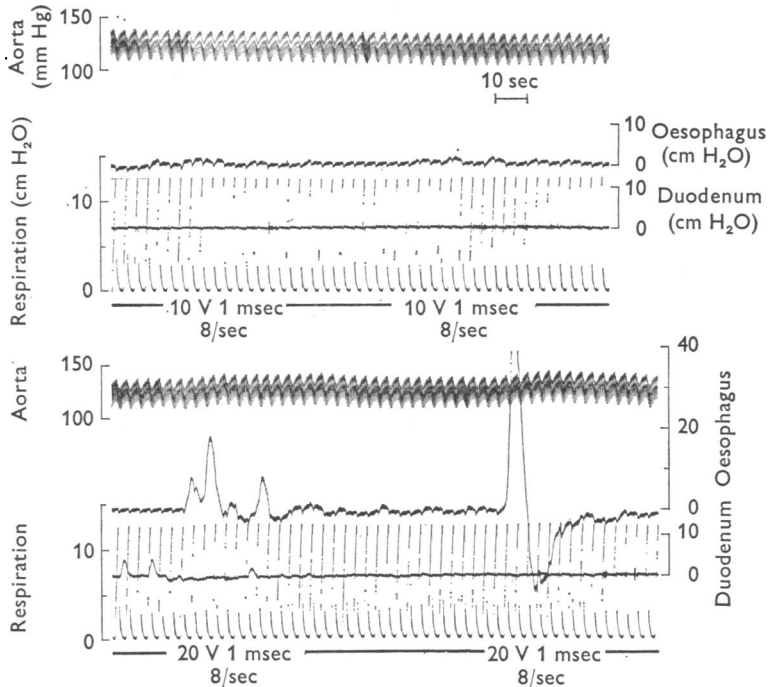
However, in two experiments, one at 9 days and one at 14 days post-operatively, high threshold atypical, long latency oesophageal responses were elicited.

In the 14-day experiment (Text-fig. 3) stimulation of the cervical vagus on the side of the rhizotomy evoked no responses at the usual stimulus intensities (upper tracing); with higher voltages (lower tracing) an irregular oesophageal response occurred with a latency of 6 sec, compared to the normal latency of 1 sec or less, and a rise of questionable significance in respiratory pressure was seen. When the same stimulus was repeated, the oesophageal response had a latency of 7 sec but had a wave form much more comparable to the normal response; a negligible rise in respiratory pressure occurred. On repeating the stimulation an atypical response was again obtained; with further stimulation the response could no longer be elicited.

Responses following chronic destruction of the D.M.N. Of the thirty-five experiments in which total destruction of the D.M.N. was attempted there were four experiments in which this objective was met. In four additional experiments in which subtotal destruction was obtained the residuum of the nucleus consisted of a few neurones at the caudal end in one experiment, a few neurones at the rostral end in another, in both of which the neurones were damaged and questionably viable, while in the other two instances of subtotal destruction 0.5 mm and just under 1.0 mm of the rostral end of the nucleus were spared.

In seven of these experiments the visceral responses obtained from the

distal end of the cut cervical vagus ipsilateral to the destroyed D.M.N. were compared with those obtained in identical manner from the contralateral vagus. In the eighth experiment (Expt. 32 in Table 1) the contralateral vagus had been chronically transected in the neck and the responses were compared with those of normal controls and with the controls of the other seven successful experiments.

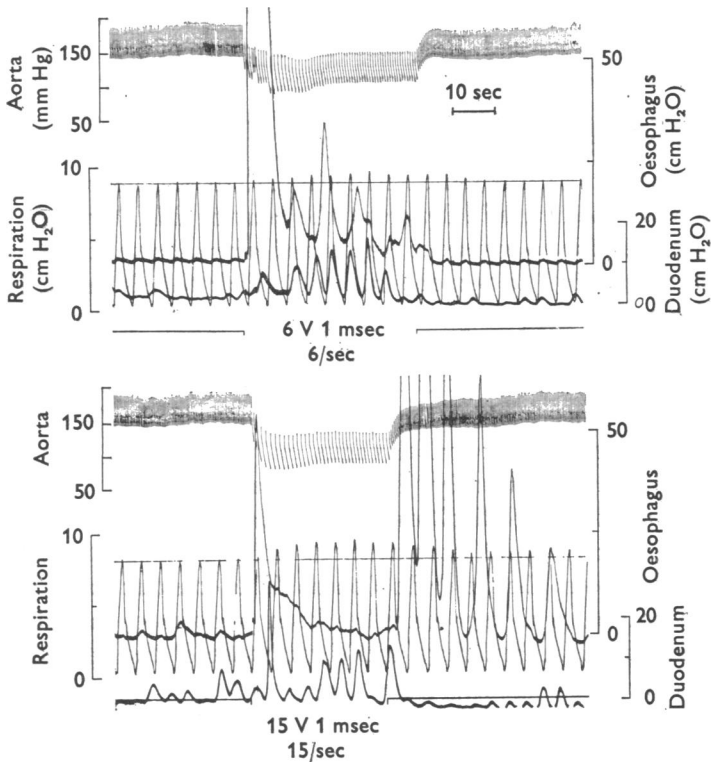


Text-fig. 3. Responses to stimulation of distal end of cut cervical vagus, 14 days after intracranial rhizotomy of nerves IX, X and XI. At the usual stimulus intensities only a trace of oesophageal response was seen (upper record). At higher intensities very atypical oesophageal responses were elicited and a trace of bronchiolar response occurred.

An example of the responses obtained from stimulation of the vagus ipsilateral to the totally destroyed D.M.N. is shown in Text-fig. 4. From above downward the tracings show the vagal cardioinhibitory effect with the associated fall in blood pressure, a short latency intense contraction of the oesophageal smooth muscle with a rapid fall followed by a series of smaller contractions terminating shortly after the end of stimulation; the next trace shows an incrementing series of duodenal contractions of moderate amplitude, and the respiratory trace shows a gradual increment in pressure during stimulation. With a stronger stimulus some of these

responses are seen to be enhanced; thus the oesophageal 'off' response and the bronchiolar response are markedly increased, whereas the oesophageal 'on' response is decreased.

Transverse sections of the medulla in this experiment are shown in



Text-fig. 4. Ten days following destruction of the ipsilateral dorsal motor nucleus, stimulation of the distal end of the vagus (both cervical vagi transected) elicited marked bradycardia, pronounced oesophageal contraction, rise in pulmonary resistance to inflation and a moderate increase in duodenal motility. The oesophageal 'on' response was of greater amplitude with lower stimulus intensities whereas the 'off' response in this instance was absent at low stimulus intensity but unusually large and repetitive at higher intensity. The respiratory and cardiac responses increased with increasing stimulus. The finer traces in this record have been retouched.

Plates 1 and 2. Four levels from the rostral pole to the caudal end of the nucleus are illustrated; the normal D.M.N. is included for comparison. It is clear that the nucleus is destroyed and examination at higher power confirmed this, there being no residual normal neurones; at the rostral tip of the nucleus a few damaged neurones were observed.

The results obtained in the other experiments were similar and have

been summarized in Table 1 which includes only those experiments in which a successful lesion was made. Tabular representation of some of these responses is simple, as in the case of cardiac or respiratory changes, and these are expressed as a percentage decrease or increase of the resting rate and pressure respectively. In the case of oesophageal and duodenal responses, a grading system has been used based on the maximum amplitude of responses obtained. Responses in the range of 5–20 cm water were graded as weak (+), average responses from 20 to 50 cm water (++) and intense responses were those in excess of 50 cm water (+++). Responses of less than 5 cm water are graded 0 and when the responses from a viscus were not recorded, this is indicated by a bar. In two instances a normal response was obtained initially from the control side, but this fatigued and disappeared for no apparent reason and when the vagus ipsilateral to the lesion was tested no response was obtained; this is marked with an asterisk. One respiratory response appeared to be positive but irregularities in the amplitude of the resting tracing which could not be corrected made evaluation uncertain; this is noted by an interrogation mark.

In the experiment in which the D.M.N. on one side had been destroyed 93 days earlier and the cervical vagus on the opposite side had been transected 43 days previously (Expt. 32, Table 1) it is noted that this animal had shown no difficulties with feeding, had maintained a satisfactory weight and at post mortem examination there was no evidence of dilatation of the oesophagus or duodenum. This contrasts with animals in which bilateral cervical vagotomy has been performed, in which paresis of the oesophageal musculature and disturbance of the sphincteric tone at the cardia results in involuntary regurgitation of gastric contents in addition to problems of aspiration pneumonitis secondary to denervation of the fauces and larynx. Such vagotomized animals present great difficulties in maintenance.

DISCUSSION

The most satisfactory base line against which the results of destruction of the D.M.N. can be judged is the result of total visceromotor denervation. This is readily achieved in the case of the vagus by performing an intracranial rhizotomy. While it might be possible to do a selective motor rhizotomy based on the report of Du Bois & Foley (1936) according to which the ventral row of vagal rootlets are motor and the dorsal ones sensory, the presence of some admixture of motor fibres with the dorsal rootlets would invalidate the experiment. Total rhizotomy, however, is a satisfactory procedure to test efferent denervation, since interruption of the central processes of neurones in the superior and inferior vagal ganglia

TABLE 1. Comparison of visceromotor responses obtained from stimulation of the transected cervical vagi in eight cats in which the D.M.N. had been destroyed unilaterally; in one animal, chronic contralateral cervical vagotomy had also been done. Cardio-inhibitory effects are represented as % drop in heart rate, bronchiolar effect as % increase in respiratory airway pressure. Oesophageal and duodenal responses are graded as described in the text. — not recorded. * response disappeared on control side; further description in text

Expt. no.	Lesion	Vagal function										Histological study of D.M.N.
		Normal side					Operated side					
Survival days	Heart (%)	Oesoph.	Duod.	Resp. (%)	Heart (%)	Oesoph.	Duod.	Resp. (%)	Oesoph.	Duod.	Resp. (%)	
1	Left D.M.N.	44	81	++	—	19	70	++	++	—	9	Subtotal destruction. A few neurones at caudal end spared
17	Right D.M.N.	14	67	++	+++	8	61	++	++	++	?	Total destruction
18	Right D.M.N.	13	63	+++	+++	10	63	*	+++	+++	5.6	Total destruction
21b	Left D.M.N.	11	0	+++	0	0	0	+++	+++	0	0	Subtotal destruction. Rostral 0.5 mm of nucleus spared
22	Left D.M.N.	14	75	+++	+++	3.7	76	+++	+++	+	4.7	Subtotal destruction. Rostral 1 mm of nucleus spared
29	Right D.M.N.	10	63	+++	+++	6	69	+++	+++	+	10	Subtotal destruction; a few neurones at the rostral end of nucleus spared
30	Right D.M.N.	10	55	+++	0	4	63	++	++	0	3.6	Total destruction plus subtotal destruction contralateral caudal half of D.M.N.
32	Left D.M.N.	93	Chronic right vagotomy before recording	43 days	68	+++	+++	+++	+++	+++	20	Total destruction. Twelve neurones of doubtful viability at rostral end

should not have any appreciable effect on the peripheral processes of these cells. The basis for investigating the vagus in this manner is that some controversy has existed regarding the possibility of visceromotor neurones in the vagal ganglia. Heinbecker & O'Leary (1933) first suggested that such might be the case since they found that after intracranial rhizotomy of the vagus, cardiac response to stimulation of the peripheral vagus was abolished, whereas duodenal and respiratory responses were preserved. Daly & Evans (1953) and Agostoni, Chinnock, Daly & Murray (1957) on the other hand stated that all vagal visceromotor responses were abolished by this procedure. The latter group noted, however, that in twenty-nine instances of vagal rhizotomy, bradycardia was obtained in one case and bronchial constriction in another; they could find no explanation for this unless incomplete rhizotomy might have been responsible in one experiment and concluded that all visceromotor vagal neurones have their somata in the medulla.

The rhizotomy experiments described here were of value in discarding the possibility of erroneous interpretation of vagal responses following destruction of the D.M.N. Since in three of five rhizotomy experiments no responses were obtained at periods of 4-9 or more days post-operatively, and in the two instances in which responses were obtained, these were high threshold, long latency oesophageal responses, no possibility of misinterpretation exists, since the responses obtained in the cases of destruction of the D.M.N. were typical in all respects. There is little to be gained from speculation regarding the mechanism of the atypical responses noted, since no data or reasonable explanation is available for them.

Destruction of the D.M.N. Because a degree of variability of visceromotor responses is common even in normal controls and because total destruction of the D.M.N. with satisfactory survival is not readily achieved, a considerable number of experiments had to be carried out. Molhant (1910) had tried to destroy the D.M.N. using acid and then study visceromotor functions but was unable to produce satisfactory lesions.

Initial attempts in the present study were unsuccessful. The first approach used was to introduce a metal micro-electrode into the nucleus and attempt to fire the neurones antidromically from the cervical vagus; once responses had been obtained it was planned to destroy the nucleus which had been precisely localized in this manner by running a direct current through the recording electrode.

To our surprise (B. Higgs & F. W. L. Kerr, unpublished) we were never able to fire D.M.N. neurones antidromically. Urabe & Tsubokawa (1960) have reported similar results. Furthermore, destruction of the nucleus is a lengthy procedure and it is difficult or impossible to obtain a continuous lesion which destroys all neurones in a column of cells in this manner.

The simple electrically heated tungsten filament (Text-fig. 1) resolved the problem for the purposes of this study.

As a result eight experiments with destruction ranging from total in four to subtotal in four instances, form the basis of the conclusions on function of the D.M.N.

The summarized results in Table 1 indicate that visceral responses of normal amplitude were obtained from all the systems examined. Threshold, latency, amplitude and repeatability of responses were entirely comparable when the vagus ipsilateral and contralateral to the destroyed D.M.N. was tested. The degeneration period allowed was well in excess of the time required for failure of conduction in vagal axons separated from their somata (Cragg, 1965).

The experiments in which subtotal destruction was accomplished are included because they provide additional support on the one hand, and because on the other hand we (F. W. L. Kerr & N. Hendler, unpublished) have evidence showing that with partial survival of vagal efferents visceromotor responses are markedly depressed.

Source of the vagal visceromotor fibres. These experiments having indicated that the D.M.N. does not supply motor fibres to involuntary muscle, the question of the location of those visceromotor neurones is naturally raised; this point has been touched on earlier herein and current evidence, based on the work from our laboratory already referred to (Kerr, 1967) and the observations of Gunn, Sevelius, Puiggari & Myers (1968), on cardio-inhibitory neurones, indicates that they lie in the area between the ambiguous nucleus and the ventromedial aspect of the trigeminal spinal nucleus.

This lateral location of the visceromotor column would be in accord with the location of the salivatory centres at a higher level. Szentagothai (1952) suggested that the nucleus for vagally innervated smooth muscle, specifically for the oesophagus, corresponded to Jacobsohn's nucleus retrofacialis. This nucleus lies between the rostral pole of the ambiguous nucleus and the caudal pole of the facial nucleus and is generally accepted to correspond to the inferior salivatory nucleus.

This restricted location cannot, however, be accepted for the visceromotor nucleus; thus, our observations on stimulation of the medulla with micro-electrodes indicate that the column of visceromotor cells is co-extensive with the ambiguous nucleus, though located laterally to it. This is in excellent accord with the anatomical conclusion reached long ago by Kosaka & Yagita (1908) regarding location of cardiodecelerator neurones.

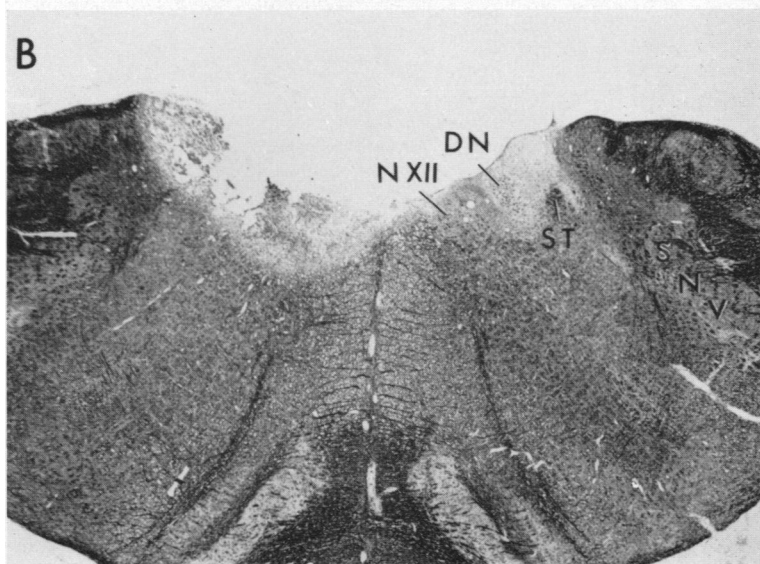

The function of the D.M.N. Since the D.M.N. does not provide innervation for smooth or cardiac muscle, the question of its true function can be considered. There is, as noted, no question that it provides motor fibres


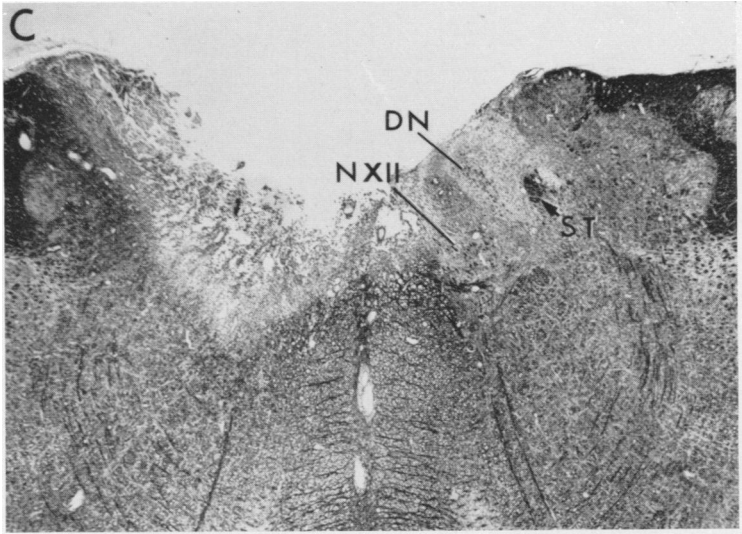
to the vagus and that these reach the abdominal branches of the nerve. It seems reasonable to infer that it may provide secretomotor fibres as suggested earlier (Kerr, 1967), and the possibility of such control over secretion or metabolic functions of any of the viscera which receive vagal efferents should be considered.

This study was supported in part by Grant NB 5995 from the National Institutes of Health, U.S.P.H.S. I am grateful to Dr David E. Donald for critical comments, to Dr Ward S. Fowler and Dr Frederic H. Helmholz for helpful suggestions. Mr Patrick Bowron's assistance in the experiments and Mrs Lucille Hayes assistance with the histological work are gratefully acknowledged.

REFERENCES

- AGOSTONI, E., CHINNOCK, J. E., DALY, M. DE B. & MURRAY, J. G. (1957). Functional and histological studies of the vagus nerve and its branches to the heart, lungs and abdominal viscera. *J. Physiol.* **135**, 182-205.
- BELL, F. R. & LAWN, A. M. (1955). Localization of regions in the medulla oblongata of sheep associated with rumination. *J. Physiol.* **128**, 577-592.
- CAJAL, S. R. (1909). *Histologie du Système Nerveux de l'Homme et des Vertébrés*, vol. 1. p. 743. Cons. Sup. Inv. Cient. Madrid (Reprint 1952).
- CALARESU, F. R. & PEARCE, J. W. (1965*a*). Electrical activity of efferent vagal fibres and dorsal nucleus of the vagus during reflex bradycardia in the cat. *J. Physiol.* **176**, 228-240.
- CALARESU, F. R. & PEARCE, J. W. (1965*b*). Effects on the heart rate of electrical stimulation of medullary vagal structures in the cat. *J. Physiol.* **176**, 241-251.
- CRAGG, B. G. (1965). Failure of conduction and of synaptic transmission in degenerating mammalian C fibres. *J. Physiol.* **179**, 95-112.
- DALY, M. DE B. & EVANS, D. H. L. (1953). Functional and histologic changes in the vagus nerve of the cat after degenerative section at various levels. *J. Physiol.* **120**, 579-595.
- DU BOIS, F. S. & FOLEY, J. O. (1936). Experimental studies on the vagus and spinal accessory nerves. *Anat. Rec.* **64**, 285-307.
- GETZ, B. & SIRNES, T. (1949). The localization within the dorsal motor vagal nucleus. *J. comp. Neurol.* **90**, 95-110.
- GUNN, C. G., SEVELIUS, G., PUIGGARI, M. J. & MYERS, F. R. (1968). Vagal cardiomotor mechanisms in the hindbrain of the dog and cat. *Am. J. Physiol.* **214**, 258-262.
- HEINBECKER, P. & O'LEARY, J. L. (1933). The mammalian vagus nerve—a functional and histological study. *Am. J. Physiol.* **106**, 623-646.
- HUDOVERNIG, C. (1908). Beiträge zur mikroskopischen Anatomie und zur Lokalisationslehre einiger Gehirnnervenkerne (Nervus Hypoglossus, Vagus und Facialis). *J. psychol. Neurol.* **11**, 26-48.
- KERR, F. W. L. (1967). Function of the dorsal motor nucleus of the vagus. *Science, N.Y.* **157**, 451-452.
- KOHNSTAMM, O. & WOLFSTEIN, J. (1906). Versuch einer physiologischen Anatomie der Vagusursprünge und des Kopfsympathicus. *J. psychol. Neurol., Lpz.* **8**, 177-203.
- KOSAKA, K. (1909). Über die Vaguskerne des Hundes. *Neurol. Zentbl.* **28**, 406-410.
- KOSAKA, K. & YAGITA, K. (1908). Über den Ursprung des Herzvagus. *Neurol. Zentbl.* **27**, 209-210.
- KURU, M. & SUGIHARA, S. (1955). Contributions to the knowledge of bulbar autonomic centres. II. Relationship of the vagal nuclei to the gastro-jejunal motility. *Jap. J. Physiol.* **5**, 21-26.
- LAUGHTON, N. B. (1929). The effects on the stomach of stimulation of the dorsal vagal nuclei. *Am. J. Physiol.* **89**, 18-23.
- MARINESCO, M. G. (1897). Les noyaux musculo-striés et musculo-lisses du pneumogastrique. *C. r. Séanc. Soc. Biol.* **49**, 168-169.
- MILLER, F. R. & BOWMAN, J. T. (1916). The cardio-inhibitory center. *Am. J. Physiol.* **39**, 149-153.





- MITCHELL, G. A. G. & WARWICK, R. (1955). The dorsal vagal nucleus. *Acta anat.* **25**, 371-395.
- MOLHANT, M. (1910). Les connexions anatomiques et la valeur fonctionnelle du noyau dorsal du vague. *Névraxe* **11**, 137-244.
- SZABO, T. & DUSSARDIER, M. (1964). Les noyaux d'origine du nerf vague chez le mouton. *Z. Zellforsch. mikrosk. Anat.* **63**, 247-276.
- SZENTAGOTHAI, J. (1952). The general visceral efferent column of the brain stem. *Acta morph. hung.* **2**, 313-328.
- URABE, M. & TSUBOKAWA, T. (1960). Distribution of activating neurons in medulla oblongata by stimulation of the vagus nerve. *Neurol. med. chir.* **2**, 147-161.
- VAN GEHUCHTEN, A. (1898). Recherches sur l'origine réelle des nerfs crâniens. III Le nerf glossopharyngien et le nerf vague. *J. Neurol., Brux.* **3**, 493-510.

EXPLANATION OF PLATES

PLATE 1

Transverse sections of the medulla from the cat in which the responses shown in Text-fig. 4 were obtained. The lesion has destroyed the dorsal motor nucleus from its most rostral level *A* and continues to be complete in serial sections through *B*.

PLATE 2

Continuation of the lesion illustrated in Plate 1. Destruction of the dorsal motor nucleus is total as far as its termination in *D*. The contralateral dorsal nucleus is preserved throughout. Key to symbols:

DN	Dorsal motor nucleus of vagus	ST	Solitary tract
Ce	Central canal	N XII	Hypoglossal nucleus
SNV	Spinal nucleus of trigeminal nerve		