

# Twenty-four- and 48-hour Canine Liver Preservation by Simple Hypothermia with Prostacyclin

MORITO MONDEN, M.D., JOSEPH G. FORTNER, M.D.

Canine livers were preserved by simple hypothermic storage using modified Sacks' solution and prostacyclin. Orthotopic liver transplantation was then carried out. Five of six and three of five livers preserved for 24 and 48 hours, respectively, were able to sustain life for more than five days.

ONE OF THE MAJOR limitations of liver preservation is the liver's extreme sensitivity to hypoxia. For the past 20 years, two basic preservation techniques have been employed in experimental and clinical transplantation: hypothermia storage<sup>1-6</sup> and hypothermic pulsatile perfusion.<sup>7-12</sup> The latter has been reported to be a superior method when preserving the liver for more than a few hours; however, the complexity of the method and inconsistent results have restricted its general use. From the clinical point of view, hypothermia storage has been the preferable method for the two- to four-hour ischemic periods commonly necessary for liver transplantation in man. Some progress in clinical liver storage has been reported.<sup>13</sup> The arterial ischemic time was as long as 5 hours, 37 minutes in one donor liver that was flown from Buffalo, New York to Memorial Hospital in New York City for a heterotopic transplant.

Experimentally, some improvements in preservation for 8-12 hours have been seen using a high potassium and magnesium solution, plasma protein fraction or hyperosmolar solution with glucose and cortisone.<sup>3,5</sup> Attempts to perform orthotopic liver transplantation using a liver that has been preserved for more than 24 hours have failed.

This report concerns the use of a heretofore unreported method for liver preservation that has a high success rate after both 24- and 48-hour storage. The method is simple storage at refrigerator temperatures in a hyperosmolar, modified Sacks' solution containing prostacyclin (prostaglandin I<sub>2</sub>). The viability of the preserved liver was assessed by orthotopic liver transplantation.

---

Reprint requests: Morito Monden, M.D., The Second Department of Surgery, Osaka University Medical School, Fukushima-ku, Osaka 553, Japan.

Submitted for publication: September 10, 1981.

*From the General Motors Surgical Research Laboratory,  
Memorial Sloan-Kettering Cancer Center,  
New York, New York*

---

## Materials and Methods

Mongrel dogs of either sex, weighing 7.0 to 27.0 kg were used. Anesthesia was induced with intravenous thiopental sodium (10-15 mg/kg) followed by nitrous oxide and a minimum of halothane. During surgery, donor dogs received an infusion of about 1,000 ml of Ringer's lactate solution. After the donor liver was freed except for vascular attachments, its portal vein was flushed with cold Ringer's lactate solution (1,000 ml) at a hydrostatic pressure of 100 cm. Two thousand milliliters of test solution were then infused through the portal vein and celiac axis over a 30- to 45-minute period. During this period, the liver was removed and transferred to a sterile basin. The basin containing the liver and 1,000 ml of the infusion fluid were placed in a sterile plastic bag and stored, surrounded by ice, in a standard refrigerator (38 F).

There were four experimental groups: I. Liver perfusate was Ringer's lactate solution supplemented with glucose 1.0 g, methylprednisolone 250 mg, and cephalozin 500 mg per liter. The liver was refrigerated for 24 hours. II. Modified Sacks' solution II<sup>14</sup> containing KH<sub>2</sub>PO<sub>4</sub> 0.74 g, NaHCO<sub>3</sub> 1.2 g, K<sub>2</sub>HPO<sub>4</sub> 9.5 g, KHCO<sub>3</sub> 0.6 g, and mannitol 37.5 g per liter of distilled water. This solution was sterilized by ultrafiltration and refrigerated until needed. On the day of usage, the following substances were added to each liter: 1 M MgCl<sub>2</sub> solution 8 ml, methylprednisolone 250 mg, and cephalozin 500 mg. The ionic composition was Na 14, K 121, Mg 16, Cl 16, and PO<sub>4</sub> 115 mEq. The final pH was 7.75-7.80, and the osmolarity was 420 osmoles (measured). This solution was designated as M-solution. Liver refrigeration was for 24 hours. III. 100 µg of prostacyclin dissolved in 0.05 M Tris solution was added just prior to perfusion to each liter of modified Sacks' solution as described for Group II. The prostacyclin

solution was used immediately after preparation or stored at  $-20\text{ C}$  for use in less than seven days. The liver was refrigerated for 24 hours. IV. Perfusate was the same as for Group III, but the liver was stored for 48 hours.

Immediately prior to transplantation, the stored livers were rinsed through the portal vein and celiac axis with 2,000 ml of cold Ringer's lactate solution that contained  $\text{NaHCO}_3$  (10 mM) and prostacyclin (100  $\mu\text{g/L}$ ) for experimental Groups III and IV. Prostacyclin was not added to the perfusate in Groups I and II. At the end of preservation, a small biopsy was taken from the preserved liver for light and electron microscopic examination.

Following the rinse, the liver was transplanted orthotopically using a recently described technique.<sup>15</sup> Immune suppression was with azathioprine (4 mg/kg/day), starting on the day before transplantation, and methylprednisolone (3 mg/kg/day), beginning on the day of transplantation. The methylprednisolone dosage was tapered to 0.5 mg/kg/day by the fifth day. Azathioprine dosage was adjusted according to peripheral blood counts. Blood samples were collected for biochemical determinations every day in the first week and every other day in the following weeks.

### Results

The results are summarized in Table 1. Five of six dogs in Group I died within 24 hours of transplantation

from uncontrolled bleeding. The bleeding usually began 15 to 20 minutes following portal revascularization. One dog survived for six days dying of liver failure. Jaundice and hypoglycemia were present.

Two of five recipients in Group II survived beyond 24 hours. Of these two, one died from unknown causes on the fifth day, and the other died of peritonitis caused by biliary complications on the 25th day. Two of the remaining three dogs regained consciousness. However, all three died within 24 hours following transplantation with severe bleeding.

Six of six recipients in Group III survived more than 48 hours. Five of them survived more than five days, with the sixth dying from arterial thrombosis on the third day. In Group IV, three of five recipients lived more than five days. Two died on the sixth day, with one showing an arterial thrombosis, and the other having peritonitis of unknown origin. The third dog died from rejection on the eighteenth day. Of the remaining two, one died from massive bleeding two hours after transplantation, and the other died of liver failure 24 hours following transplantation.

Figure 1 shows the changes in SGOT that were observed following liver transplantation. Initial values obtained on the day following transplantation were very high (mean  $2089 \pm 773$ ), with Group I, II, and IV more elevated than Group III. The high values, especially in Group III, quickly dropped and were  $116 \pm 95$  IU by the fifth post-transplant day. The latter is essentially

TABLE 1. Results of Liver Preservation

Experimental Group	Dog No.	Changes in Liver Weight	Survivals	Cause of Death
I 24-hr preservation with Ringer's lactate solution	387	+ 13.5%	6 days	Massive necrosis of the liver
	780	+ 8.4%	12 hrs	Bleeding
	682	+ 25.0%	12 hrs	Bleeding
	207	+ 3.9%	8 hrs	Bleeding
	407	+ 1.7%	6 hrs	Bleeding
	021	+ 9.6%	6 hrs	Bleeding
II 24-hr preservation with M-solution	872	+ 2.0%	25 days	Peritonitis
	757	- 3.2%	5 days	Unknown
	782	nd*	12 hrs	Bleeding
	854	+ 4.9%	12 hrs	Bleeding
	639	+ 8.1%	5 hrs	Bleeding
III 24-hr preservation with M-solution and $\text{PGI}_2$	P-1	nd	40 days	Malnutrition
	677	+ 1.5%	20 days	Infection (evisceration)
	445	+ 1.1%	17 days	Perforation of gastric ulcer
	620	- 1.4%	11 days	Perforation of gastric ulcer
	058	- 0.6%	6 days	Perforation of gastric ulcer
	101	nd	3 days	Arterial thrombosis
IV 48-hr preservation with M-solution and $\text{PGI}_2$	P-2	nd	18 days	Rejection
	559	+ 8.5%	6 days	Arterial thrombosis
	358	+ 21.6%	6 days	Peritonitis
	603	+ 15.6%	24 hrs	Liver failure
	425	+ 6.8%	2 hrs	Bleeding

\* nd = not done.

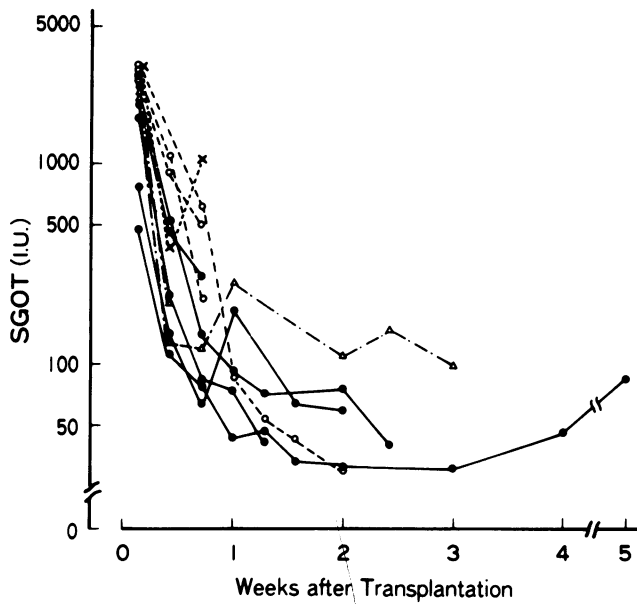


FIG. 1. Changes in SGOT level following orthotopic transplantation of preserved livers. The livers were preserved for 24 hours in a Ringer's lactate solution ( $\times \cdots \times$ ), in a modified Sacks' solution alone ( $\Delta \cdots \Delta$ ), in the modified Sacks' solution with prostacyclin ( $\bullet \cdots \bullet$ ), and in the modified Sacks' solution with prostacyclin for 48 hours ( $\circ \cdots \circ$ ).

that observed for fresh liver transplants in this laboratory. In a representative series using fresh donor livers, the SGOT level on the first and fifth days after orthotopic transplantation averaged at  $433 \pm 498$  and

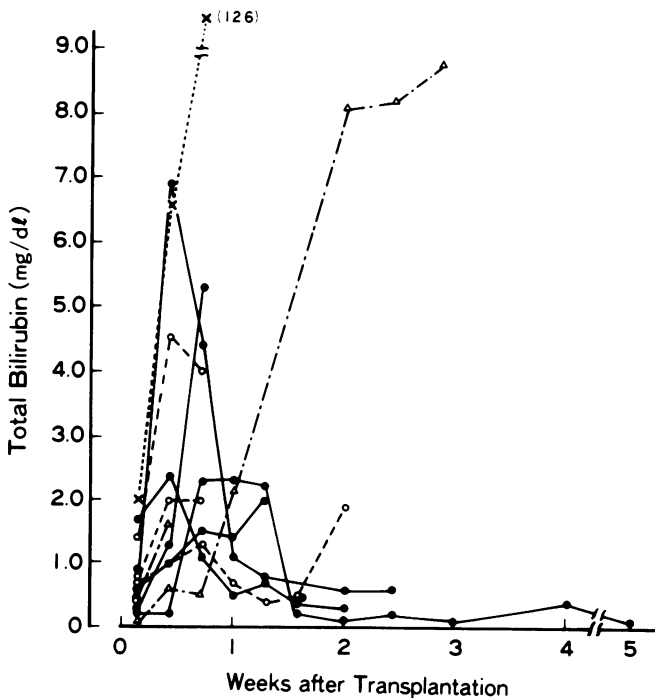


FIG. 2. Changes in serum total bilirubin level following orthotopic transplantation of preserved livers. Symbols are same as in Figure 1.

$105 \pm 64$  IU, respectively. Changes in total bilirubin levels following transplantation are shown in Figure 2. It is clearly evident that liver function was especially well preserved in Group III.

Changes in liver weight during preservation were measured. In Group I, the liver's weight increased by  $10.4 \pm 7.6\%$ , and in Groups II and III, the liver increased in weight  $3.0 \pm 4.6\%$  and  $1.5 \pm 1.2\%$ , respectively. Forty-eight-hour storage resulted in a weight increase of  $13.1 \pm 5.9\%$ .

Light micrographs of biopsies taken from the preserved livers at the end of preservation are shown in Figure 3. The anatomical structure is severely altered in Group I, and the plasma membrane is indistinct for the most part (Fig. 3a). On the other hand, the plasma membrane in Group III livers is well preserved, although each cell appears slightly swollen and the sinusoid is minimally dilated (Fig. 3c). The histologic appearance of the liver in Group II animals was intermediate between that of Groups I and III (Fig. 3b). Electron microscopy of the liver in animals of Group III reveals a nearly normal organelle; the plasma membrane, bile capillary, mitochondria, lysosome, rough endoplasmic reticulum and nucleus are well preserved (Fig. 4). The histologic appearance of a liver biopsy taken from a transplanted liver in Group III on the sixth post-transplant day is almost normal (Fig. 3d).

## Discussion

Canine livers were transplanted successfully after a minimum storage of 24 hours in a modified Sacks' solution containing protacyclin. Storage was at refrigerator temperature (38 F). Four of six recipients survived more than ten days. The other two died of causes unrelated to preservation; one dying of a perforated gastric ulcer on the sixth day and the other of an arterial thrombosis on the third day. Even preservation of the liver for 48 hours had a high success rate since three of five animals survived transplantation more than five days.

Weight gain by the liver that had been stored for 24 hours was minimal. At 48 hours, however, significant gains were seen (Table 1). Some liver damage was sustained even at 24 hours storage in that the SGOT was elevated to a greater extent than seen when fresh livers are transplanted and in the hypoalbuminemia, which was present. Fortunately, bilirubin and alkaline phosphatase levels were not affected. The morphologic appearance of the liver preserved for 24 hours in M-solution with prostacyclin was minimally altered.

The mechanism by which prostacyclin in M-solution successfully preserved the canine liver is not understood fully. Sacks' solution is widely used for kidney hypothermia preservation.<sup>14</sup> It was modified in the study re-

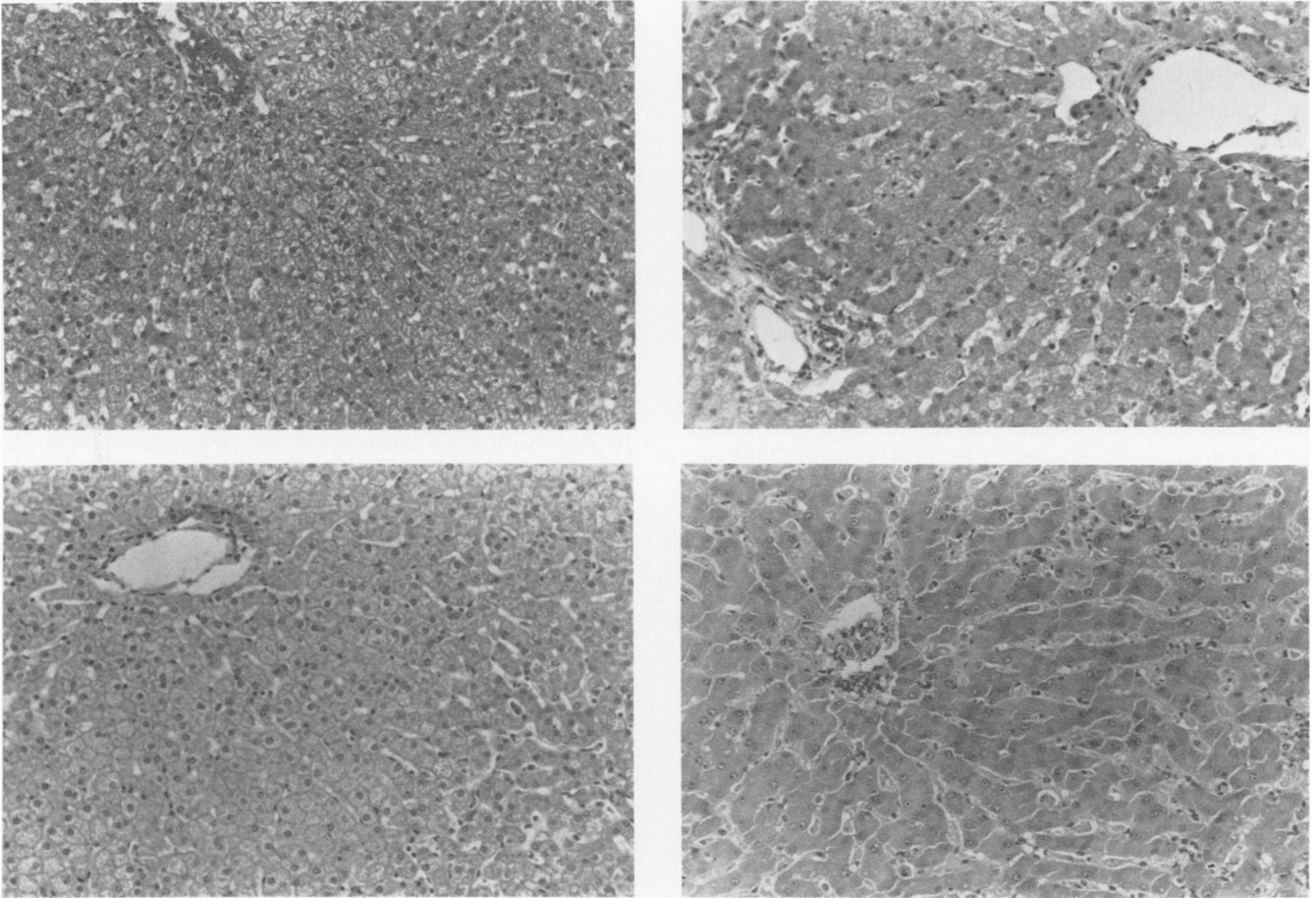


FIG. 3. Biopsies taken at the end of a 24-hour preservation and taken six days following transplantation of 24-hour preserved liver in a modified Sacks' solution combined with prostacyclin (D, *bottom right*). The livers were preserved for 24 hours in a Ringer's lactate solution (A, *top left*), in a modified Sacks' solution (B, *top right*) and in the modified Sacks' solution with prostacyclin (C, *bottom left*) (hemoxylin-eosin stain, original magnification  $\times 200$ ).

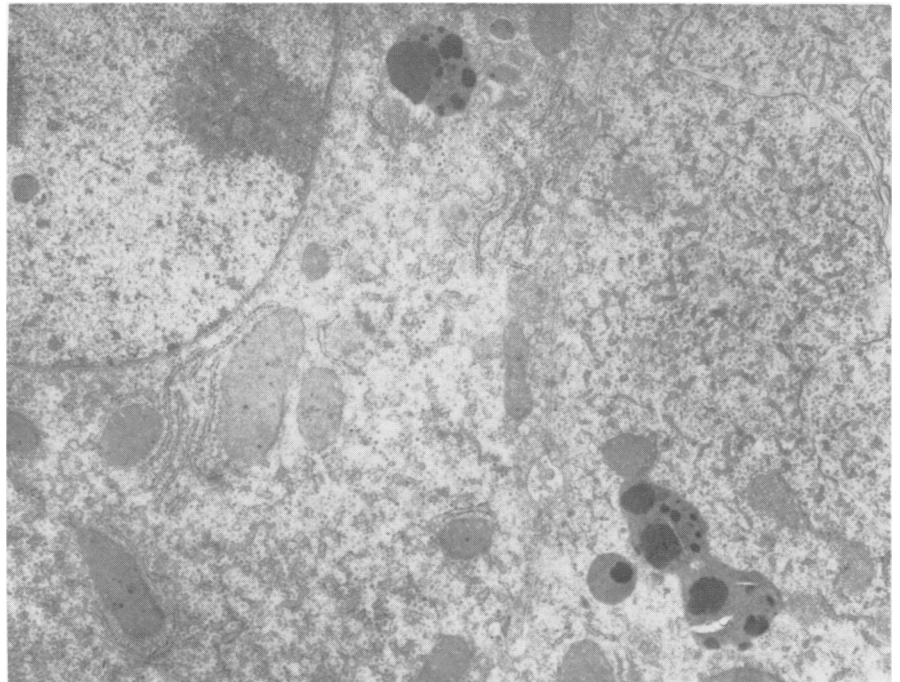


FIG. 4. Electron micrograph of the canine liver at the end of 24-hour preservation in a modified Sacks' solution with prostacyclin ( $\times 6000$ ).

ported here so as to have an alkaline pH in order to prevent hydrolysis of the prostacyclin. This compound is hydrolyzed rapidly to an inactive form—6 keto prostaglandin F<sub>1α</sub> at pH 7.4, 37 C.<sup>16</sup> Use of an alkaline solution is contrary to that recommended by Calne and others for liver preservation.<sup>4,17</sup>

Prostacyclin (PGI<sub>2</sub>), the major product of arachidonic acid metabolism synthesized by vascular endothelial cells, was recently discovered.<sup>18</sup> It is known to be a potent inhibitor of platelet aggregation and a vasodilator.<sup>19,20</sup> In addition, prostacyclin has been found to be a stabilizer of lysosomal membranes.<sup>20</sup> Recently, it has been reported that the lysosomal and cytoplasmic membrane integrity of hepatocytes during hypoxic liver perfusion was well preserved by prostacyclin. This cytoprotective effect is unrelated to its vasodilation and inhibition of platelet aggregation.<sup>21</sup>

In conclusion, successful preservation of the canine liver for 24 hours in six of six animals and for 48 hours in three of five animals has been achieved using prostacyclin in a modified Sacks' solution at refrigerator temperature. This may obviate the existing severe limitations on donor liver exchange and transportation capabilities. In addition, limited function of some grafted liver due to poor preservation, even short-term, may be obviated also in the future.

#### Acknowledgment

We are grateful to Dr. John Pike, The Upjohn Company, Kalamazoo, for the generous supply of prostacyclin.

#### References

- Schalm SW, Terpstra JL, Drayer B, et al. A simple method for short-term preservation of a liver homograft. *Transplantation* 1969; 8:877-881.
- Abouna GM, Koo CG, Howanitz LF, Anacarami KA. Successful orthotopic liver transplantation after preservation by simple hypothermia. *Transplant Proc* 1971; 3:650-653.
- Spilg H, Uys CJ, Hickman R, et al. Successful liver transplantation after storage for 6-8 hours using a simple hypothermia immersion technique. *Transplantation* 1971; 11:457-460.
- Wall, WJ, Calne RY, Herbertson BM, et al. Simple hypothermia preservation for transporting human livers long distances for transplantation. Report of 12 Cases. *Transplantation* 1977; 23:210-216.
- Benichou J, Halgrimson C, Weil R, et al. Canine and human liver preservation for 6 to 18 hours by cold infusion. *Transplantation* 1977; 24:407-411.
- Toledo-Pereyra L, Chee M, Lillehei R, Condie R. Liver preservation by cold storage with hyperosmolar solutions for twenty-four hours. *Cryobiology* 1979; 5:43-49.
- Slapak M, Wigmore RA, MacLean LD. Twenty-four hour liver preservation by the use of continuous pulsatile perfusion and hyperbaric oxygen. *Transplantation* 1967; 5:1154-1158.
- Brettscheider L, Daloz P, Huguet C, et al. The use of combined preservation technique for extended storage of orthotopic liver homografts. *Surg Gynecol Obstet* 1968; 126:263-274.
- Calne R, Dunn D, Herbertson B, et al. Liver preservation by simple passage hypothermic "squirt" perfusion. *Br Med J* 1972; 4:142-144.
- Petrie C, Woods J. Successful 24 hour preservation of the canine liver. *Arch Surg* 1973; 107:461-464.
- Toledo-Pereyra L, Simmons R, Najarian J. Factors determining successful liver preservation for transplantation. *Ann Surg* 1975; 181:289-298.
- Toledo-Pereyra L. Successful orthotopic liver transplantation after preservation by simple hypothermia. *Transplantation* 1979; 27:291-293.
- Fortner JG, Kim DK, Shiu MH, et al. Heterotopic (auxiliary) liver transplantation in man. *Transplant Proc* 1977; 9:217-221.
- Sacks S, Petritsch P, Kaufman J. Canine kidney preservation using a new perfusate. *Lancet* 1973; i:1024-1028.
- Monden M, Barters RH, Fortner JG. A simple method of orthotopic liver transplantation in dogs. *Ann Surg*, 1982; 195:110-113.
- Johnson RA, Morton DR, Kinner JH, Gorman RR, et al. The chemical structure of prostaglandin X (prostacyclin). *Prostaglandins* 1976; 12:915-928.
- Turner MD, Alican F. Successful 20 hour storage of the canine liver by continuous hypothermic perfusion. *Cryobiology* 1970; 6:293-301.
- Moncada S, Gryglewski R, Bunting S, Vane JR. An enzyme isolated from arteries transforms prostaglandin endoperoxides to an unstable substance that inhibits platelet aggregation. *Nature* 1976; 263:663-665.
- Dusting GJ, Moncada S, Vane JR. Prostacyclin (PGX) is the endogenous metabolite responsible for relaxation of coronary arteries induced by arachidonic acid. *Prostaglandins* 1977; 12:3-15.
- Lefer AM, Ogletree ML, Smith JB, et al. Prostacyclin: a potentially valuable agent for preserving myocardial tissue in acute myocardial ischemia. *Science* 1978; 200:52-54.
- Araki H, Lefer AM. Cytoprotective actions of prostacyclin during hypoxia in the isolated perfused cat liver. *Am J Physiol* 1980; 238:H176-H181.