

A Comparison of the He Ne Laser and Ultrasound Doppler Systems in the Determination of Viability of Ischemic Canine Intestine

R. H. ROTERING, JR., J. A. DIXON, G. A. HOLLOWAY, JR.,* D. W. McCLOSKEY

One of the most challenging intraoperative dilemmas continues to be determination of viability of ischemic bowel. Many techniques and devices are available to help the surgeon, probably the most useful of which is the ultrasound Doppler. A more recently developed system, the laser Doppler, has a flexible optical fiber and fine tip probe that can be approximated onto or endoscopically passed into the gastrointestinal tract. This study was undertaken to experimentally compare the He Ne laser and ultrasound Doppler systems in predicting viability of ischemic canine intestine. Twenty ischemic bowel zones were created in dogs by division of the mesenteric blood supply. Determination of the last site of antimesenteric serosal perfusion was then marked with each Doppler. Additionally, the fine tip probe was endoscopically passed across the ischemic zone and mucosal perfusion determined. Thus, each zone was marked three times, each indicating the anticipated site of necrosis by each method. The animals were killed 24 hours later and the tissues studied histologically. The results demonstrated that both the serosally applied and endoscopically placed laser Doppler were closer to predicting the point of total transmural necrosis. The possible clinical advantage of this device in prevention of short gut syndromes is readily apparent. The additional asset of a flexible optical fiber that can be endoscopically or laparoscopically passed make it an even more attractive modality. The findings of this study attested to the superior sensitivity, ease of use, and objectivity of the laser Doppler when compared with the ultrasound system.

ONE OF THE MOST challenging intraoperative dilemmas that continue to perplex surgeons is determination of viability of ischemic bowel. The lack of reliability of clinical indicators has motivated researchers to produce a number of techniques and devices to attempt to ease and objectify these difficult decisions. Among proposed methods have been radionuclide labeled microspheres, fluorescein injection, and Doppler ultrasonography. Despite advantages of each, drawbacks have been great enough to stimulate additional investigation.

Probably the most useful technique developed to date

*From the Department of Surgery, Division of Endoscopic and Laser Surgery, and Department of Pathology, University of Utah College of Medicine, Salt Lake City, Utah and *Center for Bioengineering, University of Washington, Seattle, Washington*

is the ultrasound Doppler. General availability and demonstrated accuracy have made it a standard.¹ Limitations of this method include: lack of ability to measure microvascular perfusion, the need for significant experience with the device before making critical decisions, and the gel required for contact. These and other drawbacks leave room for improvement.

A more recently developed system,² the laser Doppler, has a flexible optical fiber and fine tip probe that can be easily passed endoscopically and applied to the mucosa of the GI tract without interposing a gel. An objective numerical readout is displayed, and a uniform depth of measurement is obtained without large vessel interference.

This study was undertaken to experimentally compare the He Ne laser and ultrasound Doppler systems in predicting viability of ischemic canine intestine.

Materials and Methods

Instrumentation

Both laser and ultrasound devices employ the Doppler principle. The basic concept utilized is that the frequency of transmitted light or sound is shifted when reflected from a moving object. This Doppler shift is directly proportional to the velocity at which the object is moving. In the case of the laser Doppler, light is used to monitor the quantity and speed of red blood cells in the microcirculation.

The laser Doppler used to measure gastrointestinal perfusion is a commercially available device (Medpacific, Seattle, WA) based on a prototype fabricated by Holloway and Watkins.^{4,6} The self-contained, readily

Reprint requests: John A. Dixon, M.D., 50 No. Medical Drive, Salt Lake City, Utah 84132.

Submitted for publication: March 31, 1982.

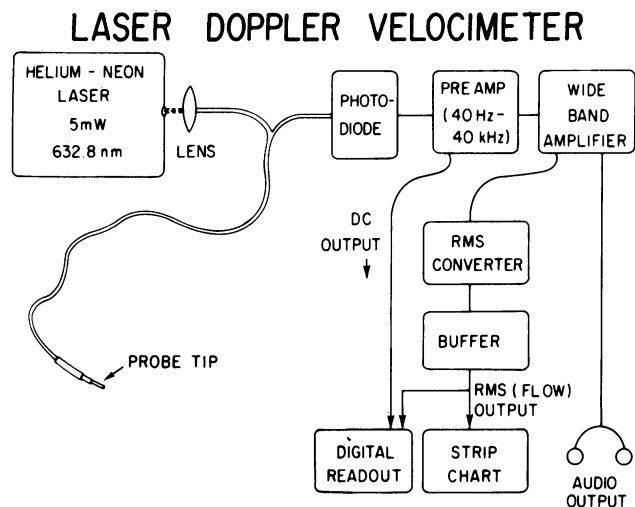


FIG. 1. Block diagram of laser Doppler velocimeter. Redrawn from Watkins and Holloway, *IEEE Trans. Bio-Med. Eng.* BME 1978; 25:28-33.

portable unit weighs approximately 35 lbs. Three basic components constitute the system: laser, fiber-optics, and signal processing. This is represented diagrammatically in Figure 1. The laser contained in the unit is a 5 mW helium-neon laser that generates monochromatic light of 632.8 nm wave length. The laser light is coupled into a fiber optic system containing two optical fibers. The first fiber serves as the transmission fiber; the second, separated by 1 mm from the first, is the receiving fiber. The fiberoptic wave guide system is approximately 5 meters in length and has a probe 2 mm in diameter and 3 cm in length, attached to its end. The light passes through the transmission fiber and exits via this probe which is approximated to the tissue surface being studied. No coupling medium is needed between the probe tip and tissue. In the tissue, the light is reflected from both the nonmoving surface tissue (a constant) and is not Doppler shifted, and from moving red blood cells which produce the Doppler shift. Both of these com-

ponents are transmitted back to the photodiode by the receiving fiber. The Doppler shifted signal which is proportional to red blood cell velocity is extracted. Further amplification and processing display the value of the shift on a digital meter, strip chart recorder, and audibly (Fig. 1). The depth of penetration in tissue of the low-power laser light is well controlled with studies reporting the penetration between 0.6 and 1.5 mm, depending on the tissue.^{2,3,5} On the average, 1 mm³ of tissue is monitored which assures the identity of the signal as arising from the microvasculature. Limited depth of penetration is a marked advantage of using light as a medium since it avoids the background transmission influence of major vessels.

The ultrasound Doppler used for the study was a Parks Electronics model 806. The pencil probe chosen was a 9 MHz attachment.

Experimental Models

Five healthy, adult mongrel dogs, average weight 28 kg, were used as experimental models. General anesthesia was achieved with IV Surital and a sterile midline laparotomy performed. A total of ten ischemic loops measuring 20 cm each in length were created in the dogs by dividing the entire mesentery of the loop adjacent to the bowel wall and suture-ligating the collateral mesenteric vascular arcade at the mesenteric margin of the bowel wall. This technique yielded ten ischemic loops, each having a proximal and distal ischemic zone for study, or a total of 20 ischemic zones. This is diagrammed in Figure 2.

Fifteen minutes after devascularization, each of the twenty ischemic zones was studied. The ultrasound Doppler with attached pencil probe was used to determine by audible signal the last site of antimesenteric serosal arterial perfusion. Sterile contact gel was used to improve conduction. This site of last audible arterial sound was marked by suture with color 1.

Immediately following determination of the last site of perfusion with the ultrasound Doppler, the probe of the laser Doppler was applied to the antimesenteric border in similar fashion. This handheld probe was gently approximated to the tissue so as not to disturb or compromise the microvascular perfusion. The last site of perfusion, as indicated by digital readout was recorded with suture color 2.

Following this, an enterotomy was performed remote from the ischemic zone. The operating channel of a T91-S ACMI endoscope was used to introduce the probe of the laser across the ischemic zone. Antimesenteric mucosal perfusion was evaluated in this intraluminal manner. The last site of mucosal perfusion as determined by the laser Doppler was marked externally with suture

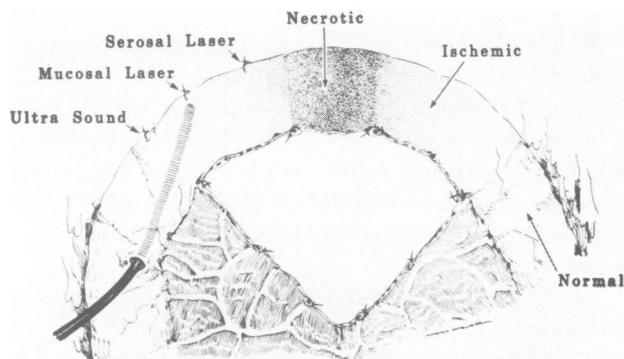


FIG. 2. Model of canine intestinal loop. Note suture marking technique for last indicated perfusion. Endoscopic laser Doppler device is shown.

TABLE 1. Average Distance From Doppler Loss of Signal To Point of Any Partial Necrosis*

N = 20		
Ultrasound	Mucosal Laser	Serosal Laser
0.6 cm ± 0.5	-3.7 cm ± 2.7	-5.2 cm ± 2.8

* A negative value means the marker was within the final zone of partial necrosis. Distances recorded moving from perfused toward necrotic zone.

color 3. Thus, each ischemic zone was marked with three different colored sutures, each indicating the anticipated site of necrosis as projected by each method.

All animals underwent re-exploration and were sacrificed 24 hours after the initial studies. The ischemic loops were resected and fixed in formalin. Two cm longitudinal sections through the ischemic zones were made, stained with H & E and examined by a pathologist unaware of the suture marking code.

Results

The results of the histologically confirmed prediction of ischemia are seen in Tables 1 and 2. The average distances to the point of first partial necrosis were ultrasound 0.6 cm, endoscopic laser Doppler -3.7 cm and serosal laser Doppler -5.2 cm. The average distances to the point of total necrosis were 5.0, 1.9, and 0.4 cm, respectively.

There was a variable length in the ischemic zones ranging from 2 to 12 cm before complete transmural necrosis could actually be confirmed. Thus, the wide standard deviations in Tables 1 and 2 represent variability in blood supply to ischemic loops rather than in instrument sensitivity since the sites of loss of perfusion were readily reproducible. The typical pattern of loss of perfusion signals progressing from perfused to ischemic areas was first ultrasound, then mucosal, followed by serosal laser Doppler. The reasons for this became apparent on histologic examination. Tissue sensitivity to ischemia was evidenced first by loss of mucosa, followed next by muscularis and then serosa. However, irregular "spotty" patterns were noted often such as islands of normal muscularis appearing distal to areas of necrotic muscularis, and findings as curious as normal mucosa overlying necrotic muscularis (Fig. 3).

It was found that the laser Doppler was technically much easier to use for several reasons. First of all, since no contact gel was required, results could be obtained in a more rapid manner without the mess of gel in the operative field. Once tissue contact was made with the laser probe the device provided an instantaneous and continuous perfusion value on both the digital display and strip chart as well as an audible signal. This again

TABLE 2. Average Distance From Doppler Loss of Signal To Point of Total Necrosis

N = 20		
Ultrasound	Mucosal Laser	Serosal Laser
5.0 cm ± 2.6	1.9 cm ± 1.5	0.4 cm ± 1.4

was time saving and additionally removed the ambiguity and observer error in interpreting audible ultrasound Doppler signals. In this study, as in others utilizing ultrasound, there were observer disagreements as to when ultrasonic Doppler signals were actually present or absent and hence the level at which to mark the bowel.

The laser Doppler was also found to be a more sensitive instrument. It was not possible to consistently pick up ultrasound Doppler signals on the antimesenteric borders of normal bowel, whereas the laser Doppler always did. The ultrasound Doppler was consistent in recording on the mesenteric side of normal bowel where the vessels are larger in size. It was found at times that with the ultrasound Doppler positioned on the antimesenteric serosal surface, there was transluminal recording of arterial signals from the mesenteric side. The laser Doppler routinely picked up perfusion signals in partially ischemic areas when the ultrasound Doppler did not. Viable skip areas were also correctly identified with the laser Doppler with perfusion signals once again being recorded further into the ischemic zone after initially disappearing. This did not occur with the ultrasound device.

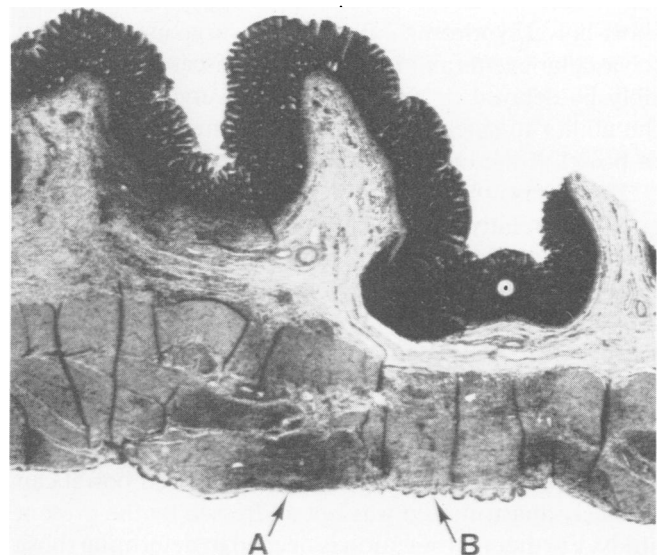


FIG. 3. Longitudinal section of ischemic zone in canine intestine, fixed in formalin and stained with H & E. A indicates Hematoxylin stained necrotic muscularis. B indicates Eosin stained normal muscularis. Note irregular spotty pattern of muscle necrosis and normal mucosa overlying necrotic muscularis.

The probe of the laser Doppler was easier to use because it was less sensitive to positional orientation relative to the bowel. When handheld or endoscopically placed, it was not difficult to achieve tissue contact with the laser probe.

Discussion

From the results in these comparative studies, it appears that a histologically predictable process occurs across a necrotic zone following an ischemic event. The first tissue to necrose is usually the mucosa, followed in turn by the muscularis mucosa, muscularis externa, and serosa. This sequence is predicted by the progressive loss of perfusion moving toward an ischemic zone, recorded by ultrasound Doppler, followed by mucosally applied laser Doppler, and, finally, serosally applied laser Doppler. The ultrasound Doppler appears to lack the sensitivity to detect perfusion at sites of partial mural necrosis. The serosally applied laser Doppler was closest to predicting the final site of total transmural necrosis, being an average of 0.4 cm from the site.

Since the length of bowel that will undergo partial ischemia yet survive is widely variable, the potential clinical advantage of the laser Doppler is readily apparent. In critical situations some of this bowel might be saved. The authors' studies as well as those of Cooperman et al.¹ revealed the last audible ultrasound Doppler signal to be well within normally perfused bowel. With that system, an experimental correction factor would then need to be introduced to predict where partial and full thickness necrosis will appear, since this is beyond the sensitivity of the ultrasound Doppler system. The short-bowel syndrome, known to all surgeons secondary to vascular events and inflammatory diseases, could possibly be delayed or prevented if the surgeon possessed the ability to safely retain just a few more centimeters of bowel at the operating table.

The ultrasound Doppler system has been found to be good but relatively insensitive. With the digitally displayed values for perfusion afforded by the laser Doppler, further research is needed to determine which values are representative not only of normal bowel but also of various degrees of partially ischemic bowel. Again, centimeters of bowel might be saved in critical situations when perfusion values become known that might allow the anastomosis to be safely performed within regions of compromise. Whether such compromised bowel can be safely anastomosed was not addressed by the present study. Further investigation is needed to determine those values of perfusion that are essential for safe resection and anastomosis of ischemic bowel. It would be easy to do repeated laser Doppler recordings during and im-

mediately following anastomosis in areas of questionable perfusion to determine the possible adverse effects of suturing or stapling procedures. Early work with the laser Doppler system would suggest that this is certainly within the realm of instrument sensitivity.

Researchers and clinicians alike are in need of more ideal methods for assessing mural gastrointestinal perfusion. Disadvantages of present techniques include invasiveness, difficult procedures, complex apparatus, and lack of sensitivity and reliance upon subjective end points. Preliminary studies indicate the laser Doppler is sensitive, accurate, noninvasive, and safe and easy to use in research applications.^{4,7} The additional asset of a flexible optical fiber and fine tip probe that can be endoscopically passed make it an even more attractive modality. The findings of this study attested to the superior sensitivity, ease of use, and objectivity of the laser Doppler when compared with the ultrasound system.

The diagnostic potential of laparoscopic and endoscopic applications is also exciting. Further work with the instrument should provide valuable information as to which perfusion values correlate not only with tissue ischemia and necrosis but certain enteric vascular diseases as well. Earlier work in the laboratory has convinced the authors of the value of the laser Doppler in research applications on the gastrointestinal tract.⁷ It is now felt that the modality merits careful clinical evaluation.

Acknowledgments

The authors greatly acknowledge the generosity of Medpacific, Seattle, for their loan of the laser Doppler for this study. Thanks also to Mr. Barry Bagley and Mr. Carter Wilsey from the Utah Biomedical Test Lab for their expert technical assistance. Finally, we thank Mrs. Jean Florence for her manuscript preparation and ongoing support.

References

1. Cooperman M, Pace WG, Martin EW Jr, et al. Determination of viability of ischemic intestine by Doppler ultrasound. *Surgery* 1978; 83(6):705-710.
2. Stern MD, Lappe DL, Bowen PD, et al. Continuous measurement of tissue blood flow by laser Doppler spectroscopy. *Am J Physiol* 1977; 232:H 441-448.
3. Stern MD, Bowen PD, Parma R, et al. Measurement of renal cortical and medullary blood flow by laser Doppler spectroscopy in the rat. *Am J Physiol* 1979; 236:F 8087.
4. Holloway GA Jr, Watkins DW. Laser Doppler measurement of cutaneous blood flow. *J Invest Dermatol* 1977; 69:306-309.
5. Nilsson GE, Tenland T, Oberg PA. Evaluation of a laser Doppler flowmeter for measurement of tissue blood flow. *IEEE* 1982; BME 27 (10):597-604.
6. Watkins DW, Holloway GA Jr. An instrument to measure cutaneous blood flow using the Doppler shift of laser light. *IEEE Trans Bio-Med Eng BME* 1978; 25:28-33.
7. Rotering RH, Larsen KR, Dixon JA, Moody FG. The measurement of canine gastric mucosal blood flow with a laser Doppler velocimeter (Abstr). *The Physiologist* 1981; 24:15.