

# Lobular Carcinoma—An Indication for Elective Biopsy of the Second Breast

WILLIAM L. DONEGAN,\* M.D.,  
CARLOS M. PEREZ-MESA,\*\* M.D.

From the Department of Surgery,  
Ellis Fischel State Cancer Hospital,  
Columbia, Missouri

THE EVIDENCE that mammary cancer is a more curable disease if it is diagnosed in an asymptomatic or pre-clinical stage provides an impetus for implementing effective methods of early detection. In addition to other means of detection, elective, random or "blind" biopsy of the apparently normal breast is finding a place in the early diagnosis of mammary cancer in populations known to be at high risk for the disease.

Elective biopsy promises to be particularly useful for the diagnosis of second primary lesions in women with known cancer in one breast. The incidence of clinical cancers in the remaining breast of women treated for one mammary cancer is known to be high, approximately five times the incidence of first cancers in the general female population, and these second cancers claim the lives of a significant number of patients. Clinical studies have identified categories of patients who are especially prone to develop second mammary cancers. Prominent among them are women who are less than 50 years of age, who have a strong family history of breast cancer and whose first cancer is multifocal, comedo or lobular carcinoma.<sup>1,30</sup>

Among the most likely for contralateral involvement, are women with lobular carcinoma.<sup>24,36</sup> This lesion, which arises in the lobules and terminal ducts of the breast,

has been recognized as a pathologic entity since 1941 when the *in situ* form was described separately by Muir<sup>26</sup> and by Foote and Stewart,<sup>10</sup> and it is now estimated to comprise from 0.6% to 10.2% of primary malignant breast neoplasms.<sup>34,39</sup> Although *in situ* lobular carcinoma is often multifocal and frequently in both breasts, it does not produce signs or symptoms. Its importance lies in its ability to become invasive or to metastasize. The risk of developing invasive carcinoma in a breast containing lobular carcinoma *in situ* is cumulative reaching 35% after 20 years.<sup>24</sup>

In 1969 the policy was adopted at Ellis Fischel State Cancer Hospital and the Cancer Research Center (EFSCCH-CRC) of routinely performing a diagnostic biopsy of the opposite breast if lobular carcinoma was found in one, a practice recommended initially by Newman<sup>27</sup> in 1962 and one which is finding an increasing number of adherents.<sup>2,8,37,39</sup> The present report relates the institutional experience with lobular carcinoma to date and the results of using it as an indication for elective biopsy of the second breast.

## Materials and Methods

Approximately 110 new patients with mammary cancer in all stages are referred yearly to EFSCCH-CRC for examination and treatment, and since 1940 more than 3,000 instances of mammary cancer have been seen. When the present study began the files were reviewed to identify all women with a diagnosis of lobular carcinoma.

Microscopic slides were reviewed (CPM) to confirm

Submitted for publication August 25, 1971.

\* Surgeon and Associate Scientist, Ellis Fischel State Cancer Hospital and Cancer Research Center, and Associate Professor of Surgery, University of Missouri School of Medicine.

\*\* Chief Pathologist and Senior Scientist, Ellis Fischel State Cancer Hospital and Cancer Research Center, and Associate Professor of Clinical Pathology, University of Missouri School of Medicine.

Reprint requests to: William L. Donegan, M.D., Ellis Fischel State Cancer Hospital, Columbia, Missouri 65201.

This investigation was supported by Public Health Service Research Grant No. CA-08023-04 from the National Cancer Institute.

the diagnosis in all cases. The features of lobular carcinoma *in situ* (LIS) are characteristic (Fig. 1). An abrupt alteration in lobular cytology is ordinarily present.

The size of the lobule is increased and its ducts are filled by cells larger than normal but generally of uniform size. The eosinophilic, opaque cytoplasm of the neoplastic cells is frequently vacuolated, surrounding a nucleus which exhibits rare mitotic activity. The evolution of lobular carcinoma sometimes can be clearly demonstrated by areas in which there is incomplete obliteration of the lobule by the proliferating cells. The transition from lobular carcinoma *in situ* to invasive cancer is generally represented by the peculiar tendency of the invading cells to be arranged in linear formations which have been described as "Indian files" (Figs. 2 and 3).<sup>17</sup>

Patients with a confirmed diagnosis of lobular carcinoma who were still living were recalled for biopsy of the second breast. This request was not made of those who had developed recurrence of the first cancer or who had already developed and been treated for a second mammary cancer. In addition, new patients who had lobular carcinomas had biopsies of the opposite breast

either simultaneously with the initial treatment or shortly thereafter.

Prior to biopsy the breast was carefully examined by inspection and palpation and in some cases a modified single view mammogram was obtained. A cosmetic para-areolar incision was used and with some undermining, a sample of mammary parenchyma was removed from any suspicious area. If no suspicious areas had been identified, samples were taken electively from the upper outer quadrant as well as from the quadrant which corresponded to the location of the cancer in the first breast, two areas frequently involved by second cancers. Elective biopsy seems a more proper term than "blind" or "random" since the procedure was not performed blindly and a deliberate choice of site was made. Only a modest amount of tissue was removed, and the incision was closed cosmetically, usually without drains and with no effort to close the deep tissues. This technic provided adequate exposure and produced a practically invisible scar. Frozen sections were requested only if the tissues were grossly suspicious of cancer; otherwise permanent sections were awaited.

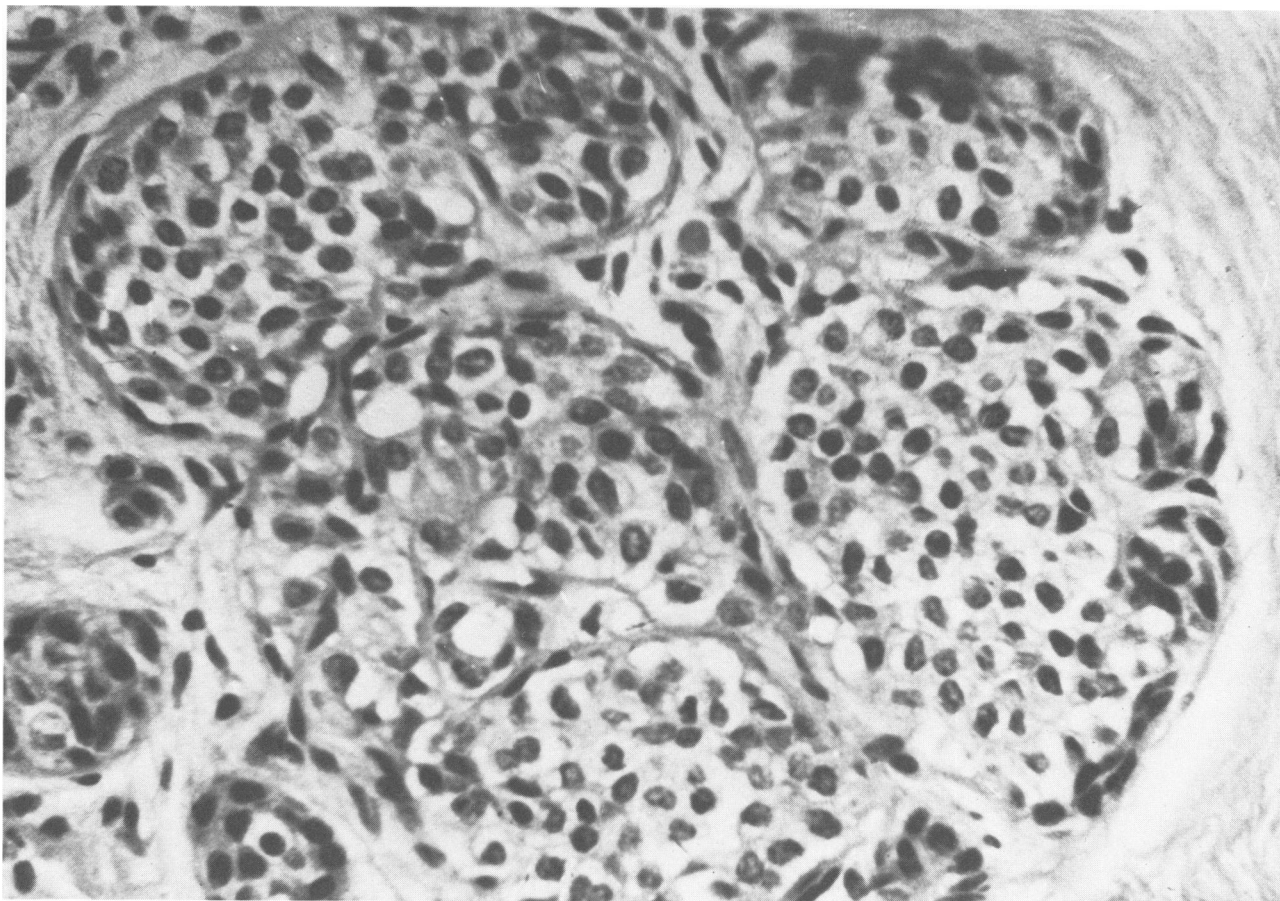


FIG. 1. Lobular carcinoma *in situ*: Notice the filling of the ducts of the lobules by generally uniform cells with foamy cytoplasm. (H & E  $\times 250$ )

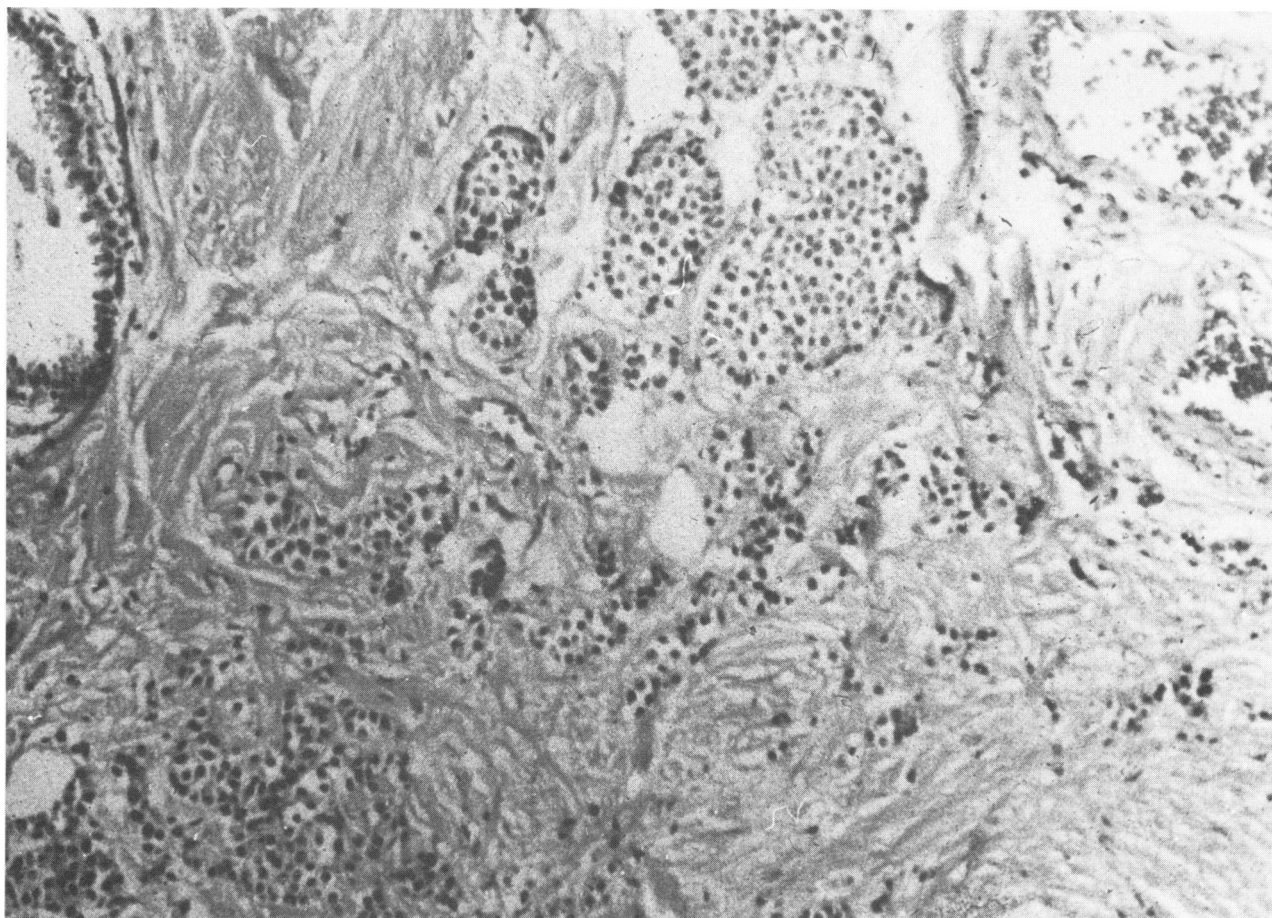


FIG. 2. Invasive lobular carcinoma with remnants of lobular carcinoma *in situ*.

## Results

### General

Lobular carcinoma was not diagnosed prior to 1960 at this institution, but since that date it was discovered in 36 or 2.7% of the 1210 new patients who had malignancies of the breast. The 36 cases are summarized in Table 1. Most were recognized recently in response to increased diagnostic efforts, often involving the preparation of numerous histologic slides from biopsy and mastectomy specimens. With such thorough examination of specimens 19 or 24.7% of the 77 patients who had mastectomies at this hospital for malignancies between February 1969 and January 1971 were found to have lobular carcinoma in the breast alone or in combination with other forms of cancer.

All patients were women. The mean age at diagnosis was 49.4 years, approximately 12 years younger than the mean age of all patients with invasive carcinoma of the breast seen at this institution, and the ages ranged from 29 to 77 years. Nine patients with *in situ* lobular cancer as the only malignant change in the breast averaged 45 years of age, 4 years younger than the average age of

the 24 patients in whom breasts also contained invasive cancer.

### Presenting Signs and Symptoms in the First Breast

In this series as in others LIS was discovered incidentally in association with other histologic changes. All patients had either coexistent invasive cancers which accounted for their clinical signs or overt findings consistent with cystic disease.

In nine cases LIS was the only malignant lesion found within the breast. Six of these women had nontender masses and one had a tender mass, all of which were due to single or multiple benign cysts. The eighth patient presented with bloody nipple discharge without a mass and was found to have extensive intraductal papillomatosis. The remaining patient had no signs or symptoms, and the diagnosis was made on incidental biopsy.

Of the nine patients with invasive lobular carcinoma, seven had masses, one of which was painful and another of which was associated with skin ulceration. One had a brown nipple discharge without a mass. All masses were apparently due to the invasive lobular carcinoma. The patient with nipple discharge had extensive papil-

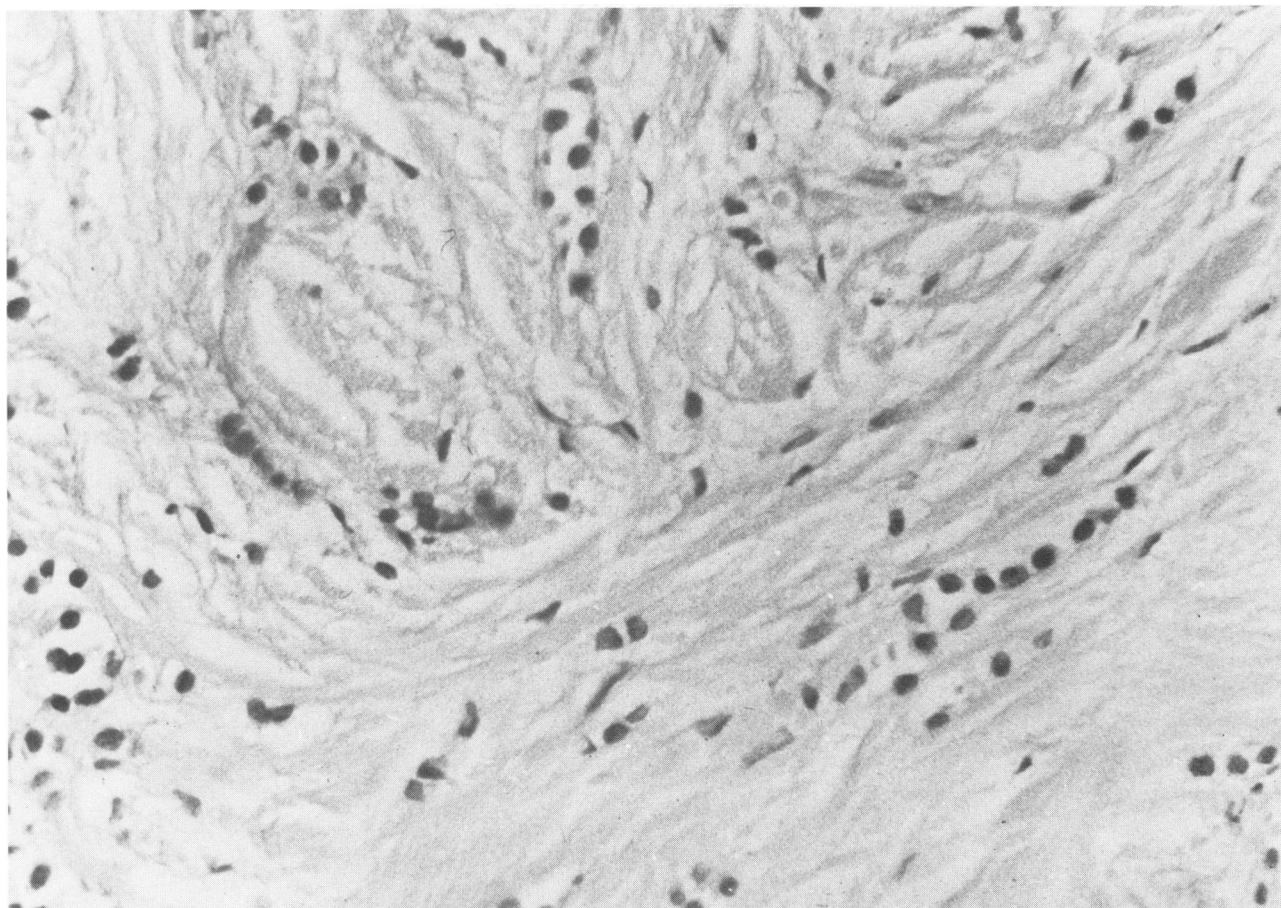


FIG. 3. High power field showing invading cells in linear arrangements.

lomatos within the mammary ducts which accounted for the discharge. The remaining patient had the presenting lesion, apparently a mass, removed elsewhere for diagnosis.

In the remaining 19 patients intraductal or invasive adenocarcinoma or both coexisted with LIS, and presenting signs included nontender masses (15 cases), painful masses (3 cases) and nipple discharge associated with a mass (1 case).

#### *Associated Lesions in the First Breast*

As shown in Table 2 invasive cancer was present with LIS in 24 patients. In nine of these patients invasion from lobules was definitely identified. In seven of the 24, *in situ* ductal carcinoma was an added histologic finding. This also occurred alone in association with LIS in three patients, i.e. in 27.8% of the total series. Sclerosing adenosis, lobular hyperplasia, papillomatosis or apocrine metaplasia were present alone or in combination in the breasts of 26 or 72.2% of the patients.

The axillary lymph nodes contained metastases in 14 (58.3%) of the 24 patients with invasive cancer, a frequency not significantly different from the metastatic rate (56.6%) associated with 1,203 invasive carcinomas

of the breast treated with radical mastectomy at the EFSCH-CRC from 1940–1965. Thus, the invasive cancer which originated from or occurred in conjunction with LIS appeared to be as prone to disseminate as the average invasive breast cancer.

#### *The Opposite Breast*

The histologic status of the opposite breast was already known in some instances, since three patients previously had mastectomies for invasive carcinoma. In eight other instances it was not feasible to obtain tissues from the second breast after initial treatment. Three patients died of metastases from the original cancer, and five more developed widespread recurrence so that a biopsy of the remaining breast would have been academic at best. Three additional patients developed signs of disease in the second breast, and biopsies were performed for clinical indications which included masses and nipple discharge. Of the remaining patients an elective biopsy was performed in 20, and in the majority it was performed simultaneously with or followed closely the initial treatment. Two remaining patients still without biopsy are asymptomatic.

The incidence of bilateral cancer among the total 36

TABLE 1. 36 Patients with Lobular Carcinoma of the Breast—EFSCII 1960–January, 1971

Case #	Pt.	Sex	Age	First Breast		Second Breast						Condition at Last Follow-up	
				Diagnosis	Treatment	Interval Until Bx (Mo)	Clinical Signs	Bx Results	Treatment	Final Dx	Recurrence of Cancer	Living or Dead	Mo. from 1st Dx
1	WS	F	29	LIS, DIS	RM	No Bx	0	No Bx	0	0	0	L	124
2	BD	F	49	LIS, IL, IC	RM	13	Masses	CCD	0	CCD	Bone	L	51
3	LD	F	45	LIS, IC	RM	No Bx	0	0	0	0	Generalized	D	34
4	M	F	64	LIS	SM	No Bx	No Breast	0	SM	Prev. Ca.	0	L	36
5	AR	F	38	LIS	MM	Simult.	0	CCD	0	CCD	0	L	25
6	SS	F	46	LIS	MSM	12	0	LIS	TM	LIS	0	L	18
7	IM	F	52	IL	RM	23	0	CCD	0	CCD	0	L	32
8	PC	F	36	LIS, IL, DIS	RM	No Bx	0	0	0	0	Bone	D	6
9	EA	F	48	LIS, IC	EM	No Bx	No Breast	0	RM	Prev. Ca.	Liver	D	24
10	CW	F	45	LIS, IL	0	No Bx	0	0	0	0	Persistent	L	32
11	EH	F	42	LIS, IC	RM	11	0	CCD	0	CCD	0	L	11
12	MR	F	30	LIS	TM	No Bx	No Breast	0	RM	Prev. Ca.	0	L	11
13	EL	F	53	LIS, IL	RM	No Bx	0	0	0	0	Local	D	11
14	MJ	F	45	LIS, IC	RM	7	0	CCD	0	CCD	0	L	10
15	NL	F	47	LIS, IC, DIS	RM	No Bx	0	0	0	0	Persistent	D	2
16	BC	F	29	LIS, IC, DIS	RM	No Bx	0	0	0	0	Bone	L	14
17	EK	F	46	LIS, IC, DIS	RM	No Bx	0	0	0	0	0	L	52
18	DK	F	74	LIS, DIS	RM	26	0	DIS	RM	LIS, DIS, IC	0	L	27
19	DH	F	44	LIS, IC	RM	25	0	CCD	0	CCD	0	L	25
20	LM	F	60	LIS, IC, DIS	RM	13	0	DIS	TM	DIS	0	L	20
21	GH	F	59	LIS	TM	3	0	LIS	TM	LIS	0	L	7
22	BH	F	50	LIS, IC	RM	8	0	CCD	0	CCD	0	L	8
23	AMS	F	52	LIS, IC	RM	4	0	CCD	0	CCD	0	L	8
24	AS	F	54	LIS, DIS	TM	Simult.	0	CCD	TM	CCD	0	L	3
25	DB	F	63	LIS, IC, DIS	TM	Simult.	0	IC, LIS, DIS	RM	IC, LIS, DIS	0	L	6
26	CJ	F	77	LIS, IL	RM	6	0	Atrophy	0	0	0	L	8
27	CJW	F	46	LIS	TM	Simult.	0	CCD	0	0	0	L	5
28	FH	F	52	LIS, IL, IC	RM	3	Sm. masses	LIS	TM	IC(3/17+LN)	0	L	5
29	PM	F	71	LIS, DIS, IC	RM	Simult.	0	IC	RM	IC	0	L	2
30	VB	F	75	LIS, IL, IC	RM	6	0	Benign	0	Benign	0	L	4
31	MD	F	46	LIS	TM	Simult.	0	LIS	TM	LIS	0	L	3
32	HG	F	30	LIS, IC	RM	No Bx	0	0	0	0	Bone	L	17
33	FD	F	36	LIS	TM	Simult.	0	CCD	0	0	0	L	1
34	EA	F	38	LIS	TM	Simult.	Tender mass	CCD	0	0	0	L	1
35	LC	F	43	IL, IC	RM	No Bx	0	0	0	0	Local	L	113
36	RG	F	63	LIS, IC	RM	3	0	CCD	0	0	0	L	1

LIS = Lobular carcinoma *in situ*DIS = Ductal carcinoma *in situ*

IC = Invasive carcinoma

IL = Invasive lobular carcinoma

CCD = Chronic cystic disease (various combinations of papillomatosis, sclerosing adenosis, cysts, and lobular hyperplasia)

RM = Radical mastectomy

SM = Simple mastectomy

MM = Modified mastectomy

EM = Extended mastectomy

TM = Total mastectomy

MSM = Modified simple mastectomy

patients is shown in Table 2. To date 11 or 30.5% have been found to have either invasive or *in situ* carcinoma in both breasts. Considering only patients in whom there has been an opportunity to examine tissue from both breasts, the rate of bilaterality is 42.3%.

### Elective Biopsy

After the original diagnosis of lobular carcinoma biopsies were performed upon the opposite breast in 23 patients, 63.9% of the total. In three there were clinical signs for which a biopsy was indicated, but in the remaining 20 there were no suspicious findings in the second breast on clinical examination and the biopsy was entirely an elective procedure. The results of the biopsies are shown in Table 3.

Eight of the 23 biopsies of the opposite breast were

positive for either *in situ* carcinoma (six cases) or invasive adenocarcinoma (two cases), a positive rate of 34.8%. Seven of the positive specimens were found in elective biopsies. Therefore, clinically normal breasts contained cancers in 35% (7/20) of cases.

After removal of the eight breasts from which biopsies had been positive, it was discovered that two of the six with only intraductal carcinoma on biopsy actually harbored invasive carcinomas. Thus, four (17.4%) of the 23 patients had invasive cancers (15% of the 20 who had elective biopsies), and four (17.4%) had carcinomas *in situ*. The four invasive cancers measured 0.2 to 1.0 cm. in diameter, and one of the four measuring only 0.7 mm. in diameter had produced metastases to three of 17 low axillary lymph nodes. Six of the 23 cases (26.1%) had lobular carcinoma in both breasts.

TABLE 2. Status of the Opposite Breast in 36 Cases of Lobular Carcinoma—EFSCCH 1960-1971

Ca. of First Breast	Tot. #	# Bx'd	No Ca.	Invasive Ca.	Ca. In-situ	Previous Breast Ca.
Invasive lobular Ca.	8	5	4	1		
Lobular Ca. <i>in situ</i>	9	7	4		3	2
Lobular Ca. <i>in situ</i> + invasive Ca.	9	6	6			1
Lobular + ductal Ca. <i>in situ</i> + invasive Ca.	7	3		2	1	
Lobular + ductal Ca. <i>in situ</i>	3	2	1	1		
Total	36	23		4	4	3

The lesion in the first breast frequently portended the nature of the findings in the second. When LIS existed alone in the first breast, elective biopsies of the second were positive in three of seven cases (42%), all of which were LIS. If LIS was combined with invasive carcinoma in the first breast, the second breast contained cancer in four of 13 cases (31%), and three of the four cancers were invasive.

#### Results of Elective Biopsy Versus Delay

Elective biopsy of the second breast was performed when possible during the anesthesia employed for treatment of cancer in the first breast. Some patients were identified as having lobular carcinomas only after retrospective review of mastectomy specimens, and therefore a considerable interval elapsed between treatment of the first cancer and the biopsy of the remaining breast. In Table 4 the interval between initial treatment and elective biopsy is correlated with the histologic findings in the second breast. When performed without delay three of seven patients (42.8%) were found to have subclinical cancer in the second breast. After an interval of 24 months or less 27.3% of 11 patients had occult cancers, and after 2 years an occult cancer was found in one of two breasts biopsied. Thus, breasts which remained clinically normal even after prolonged intervals nevertheless continued to harbor a significant number of subclinical cancers.

#### Single View Mammography

Mammograms were performed at various intervals prior to biopsies of the second breast in 11 cases utilizing a single view technic with the patient prone and the breast freely dependent (300 ma, 3.5 sec at 36 inches). The examination was of little assistance in this small series (Table 5). None were read as positive either prospectively or retrospectively, although on retrospective examination two were considered suspicious. Five of the breasts examined were found to contain cancers on biopsy. There was a 50% false negative rate when the examination was performed within 1 week of the biopsy. Calcium found in the tissues histologically in one patient was not evident roentgenologically. No standard mam-

mographic examinations were available in these instances with which to compare the results.

#### Discussion

Our experience to date confirms that women with lobular carcinoma have a high incidence of bilateral mammary cancer and indicates that they are a productive group in which to employ elective biopsy. Patient acceptance of elective biopsy has been good, and the procedure as performed was not deforming.

Our patients usually had combinations of pathologic conditions in the breast which included LIS as the common factor, but the experience of others with elective biopsy when LIS existed alone has been similar. Newman<sup>27</sup> found simultaneous involvement of the opposite breast in 25% of 16 patients with LIS, and among 13 patients with LIS treated by Benfield *et al.*,<sup>3</sup> two of five (40%) who had random biopsies (one simple mastectomy) were found to have LIS in the second breast. Urban<sup>37</sup> found bilateral simultaneous cancers, one of which was infiltrating, in 38% of 26 patients with LIS, and Lewison<sup>23</sup> reported bilaterality in 47% of 15 patients with LIS in whom the opposite breast was biopsied at various intervals after the first diagnosis. These discovery rates for occult cancers and ours (35%) are somewhat higher than the 25% cumulative incidence of clinically manifest contralateral cancers found over 20 years of follow-up by McDivitt *et al.*<sup>24</sup> in 47 patients with LIS, but they are comparable with these authors' projected incidence of 41% at 22 years. This close correspondence suggests that the pathologic prologue of future clinically

TABLE 3. Biopsy of the Opposite Breast in 23 Cases of Lobular Carcinoma—EFSCCH 1960-1971

Indication for Biopsy	Total No.	Benign	Invasive Ca.	Non-Invasive Ca.
Biopsy for clinical signs	3	2		1
Elective biopsy	20	13	2(10.0%)	5(25%)
Total biopsied	23	15	2(8.7%)	6(26.1%)
Subsequent mastectomy	8		4(17.4%)	4(17.4%)
			Total	(34.8%)

TABLE 4. Results of Elective Biopsies of the Second Breast Versus Interval After Treatment of First Cancer in 20 Patients With Breasts Containing Lobular Carcinoma—EFSCCH 1969–1971

Interval	Total No.	Negative for Ca.	Positive for Ca.	% Positive
Simultaneous	7	4	3	42.8
24 mo. or less	11	8	3	27.3
Greater than 24 mo.	2	1	1	50.0
Total	20	13	7	35.0

recognizable invasive malignancies is present with high frequency in the second breast at the time the first is treated and with diligence can be detected early. To the extent that the occult cancers found on elective biopsy are those destined to become clinical problems, the morbidity from second cancers presumably can be reduced.

Ordinarily from 1.0% to 12.0% of all mastectomy patients evolve clinically recognizable cancers in the retained breast, and even when discovered in operable stages they take an additional toll of life.<sup>22</sup> Robbins and Berg<sup>30</sup> estimated that the second cancer halved a patient's life expectancy. In a recent review of 15 consecutive patients with bilateral mastectomies for asynchronous primaries at EFSCCH-CRC, failure of treatment was manifest in three instances (20%) by recurrence on the side of the second cancer. In an additional three patients dissemination occurred without localization on the chest wall and may have been from either the first or second tumor. This limited experience gives the impression that from 20% to possibly 40% of patients were victims of second cancers.

In 1951 Pack<sup>29</sup> proposed routine prophylactic contralateral simple mastectomy to obviate the problem of second primaries and estimated that the practice would improve the overall survival rate by 7.5%. Hubbard<sup>16</sup> subsequently reported finding two cancers in 16 contralateral breasts removed prophylactically from predominantly young patients, three of whom had close relatives with breast cancer, and Leis,<sup>21</sup> who has practiced prophylactic mastectomy in selected high risk cases, discovered subclinical cancers in eleven (15.5%) of 71 specimens, five of which were invasive. Despite the evidence that prophylactic mastectomy benefits some patients, it

TABLE 5. Results of Single View Mammography Prior to Elective Biopsy of the Clinically Normal Second Breast of 11 Patients with Previous Diagnosis of Lobular Carcinoma

Interval Between Mammogram and Bx.	Reading of Mammogram	No. of Patients	Biopsy Ca.	Results No. Ca.	False Negatives
< 1 week	Suspicious	2	1	1	50%
	Normal	6	3	3	
4 to 24 mo.	Suspicious	0	0	0	33%
	Normal	3	1	2	

has not found wide acceptance. Pressures for preservation of a culturally valued organ are allied with the general impression that routine harvest of breasts even among high risk patients is a task out of proportion to the expected benefits.<sup>19,30,31</sup> Consequently, efforts to protect the mastectomy patient have been concentrated upon early detection rather than prophylaxis.

Conscientious attention to self examination by the patient and periodic examination of the remaining breast by a physician is advisable as a basic program of follow-up, but without augmentation it has proved of limited success for early detection of second primaries. Disappointment with this regimen has been noted in a number of reports.<sup>5,22,30</sup> In the EFSCCH-CRC clinic second primary lesions in the breast detected by periodic careful follow-up physical examinations of mastectomy patients have averaged 1.0 cm. smaller in diameter than the first cancers and have been somewhat more often clinically localized, but there has been no reduction in the rate of axillary metastasis.<sup>7</sup>

Mammography has been employed in follow-up with variable success. Performing mammograms at six monthly intervals Byrne *et al.*<sup>4</sup> found six carcinomas in a period of up to 84 months in 102 patients who had previous mastectomies for cancer. Only one of the six cancers had reached a palpable stage, and one had produced axillary metastases. Missakian *et al.*<sup>25</sup> followed 397 patients after mastectomy with one or more mammographic examinations as a supplement to physical examination and found 25 early carcinomas. Examinations were performed every six to 18 months. Ten of the 25 cancers were occult, and only one of these had produced metastases. The average size of the second cancers was 0.5 cms. less than that of the first ones, and the metastatic rate was reduced from 44% to 32%. By contrast Stephens and Weigen<sup>33</sup> found 13 cancers in 210 mastectomy patients followed for more than 5 years with mammograms, only three of which were recognized solely by roentgenography. Metastases to the axilla had already occurred in two of the three occult cancers.

The roentgenologic detection of lobular carcinoma *in situ* specifically is aided by the presence of characteristic stippled calcifications which occur in the lesion but more often in adjacent tissues in about 20% to 30% of cases.<sup>11,32</sup> However, less than half of patients with LIS have positive mammograms, and since similar calcifications can occur in nonmalignant conditions such as sclerosing adenosis and intraductal epithelial hyperplasia, only one of four or five breasts with them contain cancer.<sup>18</sup> A non-standard single view technic of mammography in a limited number of cases in our series proved of no assistance.

The most extensive experience with elective biopsy has been that of Urban.<sup>35,37</sup> Its supplemental role as a diagnostic technic is illustrated by his report in which

mammograms prior to operation failed to show x-ray signs of cancer in either breast in 42.9% of 21 patients who proved to have bilateral cancers on biopsy. Since 1964 he has biopsied 73% of available opposite breasts at the time of initial mastectomy and 96 or 14% were found to contain cancers. When no suspicious areas were evident on physical examination or mammograms, a generous biopsy was performed of the upper outer quadrant of the breast as well as of the quadrant corresponding to the mirror image of the first cancer, removing approximately 20% of the parenchyma. Using this technic 9% of 110 ostensibly normal breasts were found to contain occult cancers.

Compared with this 9% rate from mastectomy patients in general, the 35% positive rate from elective biopsy of our patients with LIS under similar conditions and with a more modest removal of tissue serves to illustrate their high risk status and their particular suitability for the procedure.

Attention to the distribution of LIS in the breast can perhaps further improve the detection of this lesion in elective biopsies. Lambird and Shelley<sup>20</sup> demonstrated by reconstructions of nine breasts removed for LIS that the lesion was concentrated beneath the periphery of the areola predominantly in the upper quadrants and usually within 5 cms. of the nipple. In addition, involvement tended to follow radial sectors of the breast. They calculated that an arc of breast tissue taken 3 to 4 cm. from the nipple measuring 3 cm. deep and 1 cm. wide would sample the upper quadrant duct system and would detect LIS if it were present with 90% reliability. A para-areolar incision as was used in our patients, therefore, appears to be desirable not only from the standpoint of providing easy access to suspect tissues but also from the cosmetic standpoint, perhaps an important consideration for patient acceptance of this procedure.

In reviewing the literature one finds that LIS of the breast has been treated with surgical extremes from local excision to radical mastectomy.<sup>9</sup> Although most follow-ups are short, removal of the breast appears to be curative in virtually 100% of cases. Radical mastectomy for the *in situ* lesion is generally considered supererogatory, and most authors have recommended simple mastectomy.<sup>2,12,23,34</sup> Farrow<sup>8</sup> advised simple mastectomy with a partial axillary dissection to eliminate the possibility of leaving regional nodal metastases from undetected infiltration. Haagensen<sup>13</sup> was not convinced that immediate treatment beyond local excision and careful follow-up was necessary, pointing out that not all instances progress to invasive cancer, the evolution to invasion often takes many years and perfect prophylaxis would require removal of both breasts.

Biopsy and local excision often fail to remove LIS entirely (76% of 25 breasts in our series contained residual

foci of lobular carcinoma after it had been identified in biopsy specimens), and therefore little prophylaxis against progress of the lesion is provided by limited procedures.

With respect to the proper choice of operation for lobular carcinoma *in situ*, it is not the authors' intention lightly to recommend yet another procedure to swell the ranks of those already endorsed, but two considerations have influenced our selection of therapy when LIS, or ductal carcinoma *in situ*, constitutes the major finding in biopsy material. The first is that biopsies are not always representative of the entire spectrum of malignant change within the breast. Invasion can be present when none is identified, and even small invasive primaries can metastasize to the regional lymphatics. In two of our six cases in which biopsies of the second breast showed only carcinoma *in situ*, invasive cancers were found in the mastectomy specimens, one of the two, measuring only 0.7 cm. in diameter, had metastasized to the axilla. Ozzello and Sanpitak<sup>28</sup> found no identifiable invasion of intraductal carcinoma in serial sections of mastectomy specimens from 22 patients although two of the patients had metastases in axillary lymph nodes and a third developed disseminated disease. For these reasons it is advisable to remove at least the low axillary lymph nodes, a measure which can provide the evidence on pathologic examination for the existence of an otherwise occult metastatic cancer and allow further treatment to be initiated if it is deemed necessary. This measure is particularly pertinent when the first breast contains an invasive cancer. Biopsy evidence notwithstanding, when the first cancer is invasive, the second cancer is likely to be so.

Secondly, because carcinoma *in situ* is often multifocal and breast tissue itself has a latent malignant potential, it seems advisable to perform a thorough removal of the gland. Residual parenchyma after removal of the protuberant breast is of no value to the patient, and as a focus for the development of future cancer can with some justification be compared with the retained cervix after subtotal hysterectomy. As usually performed, simple mastectomy does not remove all mammary tissue.

For these reasons our treatment of choice for patients who apparently have either LIS or *in situ* ductal carcinoma has been "total mastectomy" as described by Holleb and Farrow,<sup>15</sup> and this operation was employed in 11 of the 14 such occurrences in our series. The objective of total mastectomy is complete removal of all mammary parenchyma, a task which also necessitates dissection of the low axilla. Hicken's<sup>14</sup> studies of the mammary ducts in 385 breasts demonstrated that ducts ascend into the axilla in 95% of cases, pass downward into the epigastric area in 15%, reach beyond the latissimus dorsi muscle in 2% and occasionally cross the midsternal line (two cases). The mammary ducts frequently come into intimate con-



tact with the overlying skin. A dissection of wide extent is, therefore, necessary to insure complete removal of the gland. Thin skin flaps are required with development to the clavicle, the costal margin, the sternum and to the latissimus dorsi muscle. The fascia over the pectoralis major muscle is removed as are the low axillary contents in order to insure removal of the mammary tail of Spence and the low axillary nodes. The skin incision, a transverse one, need only encompass the areola and any biopsy scars, and since the sacrifice of skin is small, primary closure is possible. The important difference between this operation and simple mastectomy with low axillary dissection is the emphasis upon thoroughness.

The invasive form of lobular carcinoma is among the more aggressive of cancers, and although radical mastectomy has generally been employed, the results are not good. Since LIS is so readily curable the time for treatment would appear to be before invasion occurs. McDivitt *et al.*<sup>24</sup> reported that radical mastectomy for invasive lobular carcinoma in a series of 125 patients was followed by a 10-year survival of 42% and a 25-year survival of 34%. Five of the nine patients with invasive lesions at EFSCH-CRC have uncontrolled disease. Eight were treated with radical mastectomy, while the ninth had painful bony metastases as the first symptom and no mastectomy was performed. Although the cumulative 5-year survival of the nine is 78%, the disease free survival is only 33.4%.

The follow-up of cases in the EFSCH-CRC series is too short to evaluate the ultimate results of elective biopsy as a diagnostic aid. At present no recurrences have appeared in the patients treated for the subclinical cancers found in the second breast, and none with negative biopsies have developed second cancers. The success of this effort as a worthy addition to diagnostic capability will need to be reflected in a diminished incidence of clinically significant second primaries and in the attendant mortality. The impression at present, however, is that in the interests of early detection a more diligent search of biopsy and mastectomy specimens should be made to identify lobular carcinoma and that elective biopsy of the second breast in patients with known lobular carcinoma in one breast should be practiced more generally.

### Conclusion

In a series of 36 patients with lobular carcinoma of the breast 30.6% were found to have carcinoma bilaterally. Elective biopsy of clinically normal contralateral breasts at various intervals after treatment for the original cancer in 20 cases revealed either invasive or *in situ* carcinoma in 34.8%.

Patients with lobular carcinoma of the breast constitute a high risk group for development of second mammary cancers, and elective biopsy of the remaining breast

is an aid to early diagnosis and potentially to an improved prognosis.

### References

1. Anderson, D. E.: Genetic Considerations in Breast Cancer, p. 27, Breast Cancer Early and Late, Chicago, Ill., Year Book Medical Publishers Inc., 1970.
2. Benfield, J. R., Fingerhut, A. G. and Warner, N. E.: Lobular Carcinoma of the Breast. Arch. Surg., **99**:129, 1969.
3. Benfield, J. R., Jacobson, M. and Warner, N. E.: *In Situ* Lobular Carcinoma of the Breast. Arch. Surg., **91**:130, 1965.
4. Bryne, R. N., Bringham, L. S. and Gershon-Cohen, J.: Post-operative Detection of Cancer by Periodic Mammography of the Remaining Breast. Surg. Gynecol. Obstet., **115**:282, 1962.
5. Dobson, L.: Problem of Bilateral Nonsimultaneous Breast Cancer. Stanford Med. Bull., **13**:456, 1955.
6. Donegan, W. L.: Patterns and Prognosis of Advanced Breast Carcinoma. Missouri Med., **67**:853, 1970.
7. Donegan, W. L. and Spratt, J. S., Jr.: Cancer of the Second Breast, p. 180, Cancer of the Breast in the series Major Problems in Clinical Surgery Vol. 5. (J. E. Dunphy, ed). Philadelphia and London, W. B. Saunders Company, 1967.
8. Farrow, J. H.: Clinical Considerations and Treatment of *In Situ* Lobular Breast Cancer. Am. J. Roentgenol., **102**:656, 1968.
9. Farrow, J. H.: The James Ewing Lecture—Current Concepts in the Detection and Treatment of the Earliest of the Early Breast Cancers. Cancer, **25**:468, 1970.
10. Foote, F. W. and Stewart, F. W.: Lobular Carcinoma *In Situ*—A Rare Form of Mammary Cancer. Am. J. Path., **17**:491, 1941.
11. Gershon-Cohen, J., Berger, S. M. and Curcio, B. M.: Breast Cancer with Microcalcifications: Diagnostic Difficulties. Radiology, **87**:613, 1966.
12. Godwin, J. T.: Chronology of Lobular Carcinoma of the Breast. Cancer, **5**:259, 1952.
13. Haagensen, C. D.: Diseases of the Breast, p. 518, Philadelphia and London, W. B. Saunders Company, 1971.
14. Hicken, N. F.: Mastectomy—A Clinical Pathologic Study Demonstrating Why Most Mastectomies Result in Incomplete Removal of the Mammary Gland. Arch. Surg., **40**:6, 1940.
15. Holleb, A. I. and Farrow, J. H.: St. Agatha and Inadequate Simple Mastectomy. Am. J. Roentgenol., **99**:962, 1967.
16. Hubbard, T. B.: Nonsimultaneous Bilateral Carcinoma of the Breast. Surgery, **34**:706, 1953.
17. Hutter, R. V. P., Foote, F. W., Jr. and Farrow, J. H.: *In Situ* Lobular Carcinoma of the Female Breast, 1939–1968, p. 201, Breast Cancer Early and Late, Chicago, Ill., Year Book Medical Publishers Inc., 1970.
18. Hutter, R. V. P., Snyder, R. E., Lucas, J. C., Foote, F. W., Jr. and Farrow, J. H.: Clinical and Pathologic Correlation with Mammographic Findings in Lobular Carcinoma *In Situ*. Cancer, **23**:826, 1969.
19. Kilgore, A. R., Bell, H. G. and Ahlquist, R. E., Jr.: Cancer in the Second Breast. Am. J. Surg., **92**:156, 1956.
20. Lambird, P. A. and Shelley, W. M.: The Spatial Distribution of Lobular *In Situ* Mammary Carcinoma—Implications for Size and Site of Breast Biopsy. JAMA, **210**:689, 1969.
21. Leis, H. P., Jr.: Prophylactic Removal of the Second Breast. Hospital Med., **4**:45, 1968.
22. Leis, H. P., Jr., Mersheimer, W. L., Black, M. M. and Chabon, A. D.: The Second Breast. N. Y. State J. Med., p. 2460, Oct. 1965.

23. Lewison, E. F. and Finney, G. G., Jr.: Lobular Carcinoma *In Situ* of the Breast. *Surg. Gynecol. Obstet.*, **126**:1280, 1968.
24. McDivitt, R. W., Hutter, R. V. P., Foote, F. W., Jr. and Stewart, F. W.: *In Situ* Lobular Carcinoma—A Prospective Follow-up Study Indicating Cumulative Patient Risks. *JAMA*, **201**:96, 1967.
25. Missakian, M. M., Witten, D. M. and Harrison, E. G., Jr.: Mammography after Mastectomy, Usefulness in Search for Recurrent Carcinoma of the Breast. *JAMA*, **191**:1045, 1965.
26. Muir, R.: The Evolution of Carcinoma of the Mamma. *J. Path. Bact.*, **52**:155, 1941.
27. Newman, W.: *In Situ* Lobular Carcinoma of the Breast: Report of 26 Women with 32 Cancers. *Ann. Surg.*, **157**:591, 1963.
28. Ozzello, L. and Sanpitak, P.: Epithelial Stromal Junction of Intraductal Carcinoma of the Breast. *Cancer*, **26**:1186, 1970.
29. Pack, G. T.: Editorial—Argument for Bilateral Mastectomy. *Surgery*, **29**:929, 1951.
30. Robbins, G. F. and Berg, J. W.: Bilateral Primary Breast Cancers—A Prospective Clinicopathological Study. *Cancer*, **17**:1501, 1964.
31. Shellito, J. G. and Bartlett, W. C.: Bilateral Carcinoma of the Breast. *Arch. Surg.*, **94**:489, 1953.
32. Snyder, R. E.: Mammography and Lobular Carcinoma *In Situ*. *Surg. Gynecol. Obstet.*, **122**:255, 260, 1966.
33. Stevens, G. M. and Weigen, J. F.: Survey Mammography as a Case Finding Method for Routine and Postmastectomized Patients. *Cancer*, **24**:1201, 1969.
34. Stewart, F. W.: Tumors of the Breast. In *Atlas of Tumor Pathology*, Section IX, fasc. 34. Washington, D. C., Armed Forces Institute of Pathology, 1950.
35. Urban, J. A.: *Bilateral Breast Cancer*, p. 263, *Breast Cancer Early and Late*, Chicago, Ill., Year Book Medical Publishers, Inc., 1970.
36. Urban, J. A.: Bilaterality of Cancer of the Breast—Biopsy of the Opposite Breast. *Cancer*, **20**:1867, 1967.
37. Urban, J. A.: Biopsy of the "Normal" Breast in Treating Breast Cancer, p. 291, *The Surgical Clinics of North America—Problems in Surgical Oncology* (E. J. Beattie, Jr., ed). Philadelphia & London, W. B. Saunders Company, 1969.
38. *Vital Statistics of the United States*, Vol. II—Section 5, 1968, Life Tables, U. S. Department of Health, Education and Welfare.
39. Warner, N. E.: Lobular Carcinoma of the Breast. *Cancer*, **23**:840, 1969.