

# Juvenile Polyps of the Colon and Rectum

ROBERT FRANKLIN, M.D., BARTON McSWAIN, M.D.

*From the Departments of Surgery and Pathology, Vanderbilt University  
School of Medicine, Nashville, Tennessee*

JUVENILE POLYPS of the colon and rectum, also called retention or inflammatory polyps, were described as a pathologic entity by Versé<sup>9</sup> in 1908. They are distinctly different, especially microscopically, from adenomatous polyps, villous adenomas and the polyps of Peutz-Jegher's syndrome.

Roth and Helwig<sup>6</sup> suggested that such polyps arise from a cycle of mucosal ulcerations with inflammation of the surrounding glands and mucosa, causing blockage of the glands and formation of cystic spaces. Another possible etiologic factor is allergy, a personal or family history of which was found in 11 of 13 patients by Alexander and associates.<sup>1</sup> Juvenile polyps are not usually hereditary, although Smilow and associates<sup>8</sup> reported juvenile polyposis occurring in three successive generations.

Juvenile polyps are rare, occurring in 0.8 to 1.1 per cent of asymptomatic children.<sup>3</sup> They occur most often in children and young adults, but Roth and Helwig<sup>6</sup> (Table 1) found some of them in older age groups.

Colonic polyps in general have been given a bad name. Welch<sup>10</sup> stated that malignant potential is directly related to size, site and number of polyps. Some authors<sup>4, 5, 7</sup> believe that there is a histologic and clinical difference between adenomatous polyps and juvenile polyps. Shermeta and associates,<sup>7</sup> Kottmeier and Clatworthy<sup>5</sup> and Holgerson and co-workers<sup>4</sup> stated that juvenile polyps are not pre-

malignant lesions. Gelb and co-workers<sup>3</sup> described coexistent juvenile and adenomatous polyps in some patients.

The main reason for removal of any type of polyp is bleeding, obstruction (usually intussusception) and the possibility of the presence of or the development of carcinoma. The purpose of this study is to determine whether or not the above manifestations occur with juvenile polyps.

## Material, Including Pathologic Changes

Microscopic study of all polypoid lesions of the colon and rectum received in the Vanderbilt University Hospital surgical pathology laboratory from 1925 to 1970 revealed 100 cases which fit our pathologic criteria of juvenile polyp. Such polyps are usually pedunculated, although they are rarely sessile. The external surface is smooth, not velvety, and the cut surface usually shows visible cysts filled with grayish-white mucoid material (Fig. 1). Microscopically, they are usually ulcerated and show many polymorphonuclear neutrophils and eosinophils. There are mucus-secreting columnar cells surrounding spaces of varying size which contain mucus. There was no detectable microscopic difference between the polyps in children and those in adults (Fig. 2). We included no patients with pseudopolyps of ulcerative colitis.

## Age, Sex and Race

In our 100 patients, 64 were less than 10 years of age, and 79 less than 20 years of age (Fig. 3). There were 21 patients over 20 years old, and five who were over 50, the

Presented at the Southern Surgical Association Meeting held at Hot Springs, Virginia, December 6-8, 1971.

TABLE 1. *Roth—Cancer—1963—158 Patients*

Age	Per Cent*
0-10	60
11-16	0
17-19	10
20-35	22
35+	3**

\* Approximate.

\*\* One was 61.

eldest being 61. There were 58 males and 42 females. There were 87 Caucasians and 13 Negroes, approximately the ratio of white to black admissions during this period.<sup>2</sup>

### Symptoms

The most common complaint was bright red blood which was passed by rectum (Table 2). In 23 patients, there had been protrusion of a polyp from the rectum. Other complaints were change in bowel habits, abdominal pain and passing of polyps per rectum. Anemia was found in three patients (packed cell volume less than 30), but was severe enough to require transfusion in only one patient, this patient having multiple juvenile polyposis. The lowest packed cell volume was 25; there was no instance of massive bleeding. The passage of bright red blood was the most common presenting symptom (75 patients) (Table 3). Protrusion of the polyp from the rectum

was the complaint which brought 11 patients to the hospital.

### Method of Detection

Polyps were found on rectal examination in 60 patients and seen on sigmoidoscopy in 80 (Table 4). Barium enema revealed polyps in only 47, but was useful in ruling in or out polyps in parts of the colon beyond the reach of the sigmoidoscope. The history of protrusion or of having passed the polyps was found in 16 patients.

### Site

The sites of juvenile polyps are similar to those of adenomatous polyps or carcinomas. The rectum was the most common site with the rectosigmoid next in frequency and the sigmoid, third (Fig. 4). In five patients, polyps were present throughout the entire colon.

### Method of Removal

Most of the polyps could be removed through the rectum (27 patients, Table 5) or through the sigmoidoscope (47 patients). The polyp was passed spontaneously in five patients. In only 21 patients were the polyps at levels which required colotomy for removal. In five patients, the polyps were so extensive that subtotal colectomy was done (Table 5).

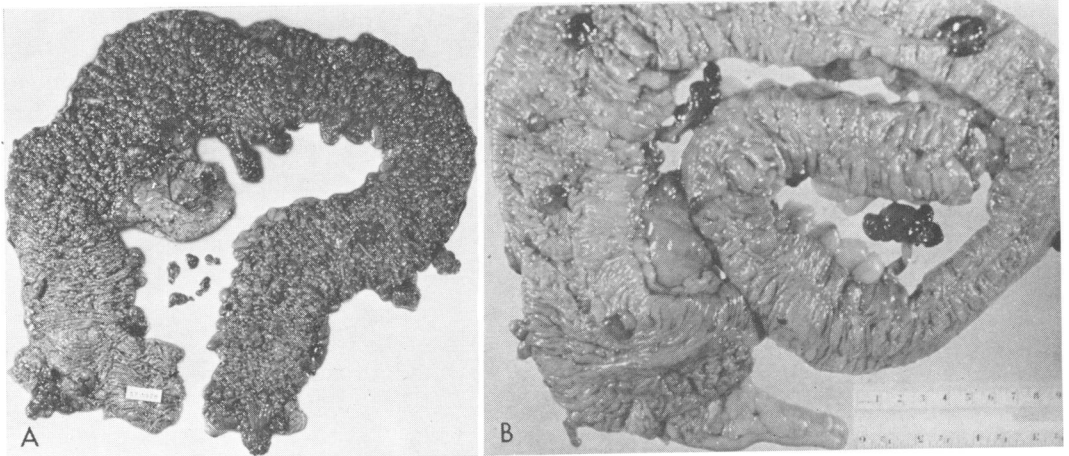


FIG. 1. (A) Familial polyposis. (B) Juvenile polyposis.

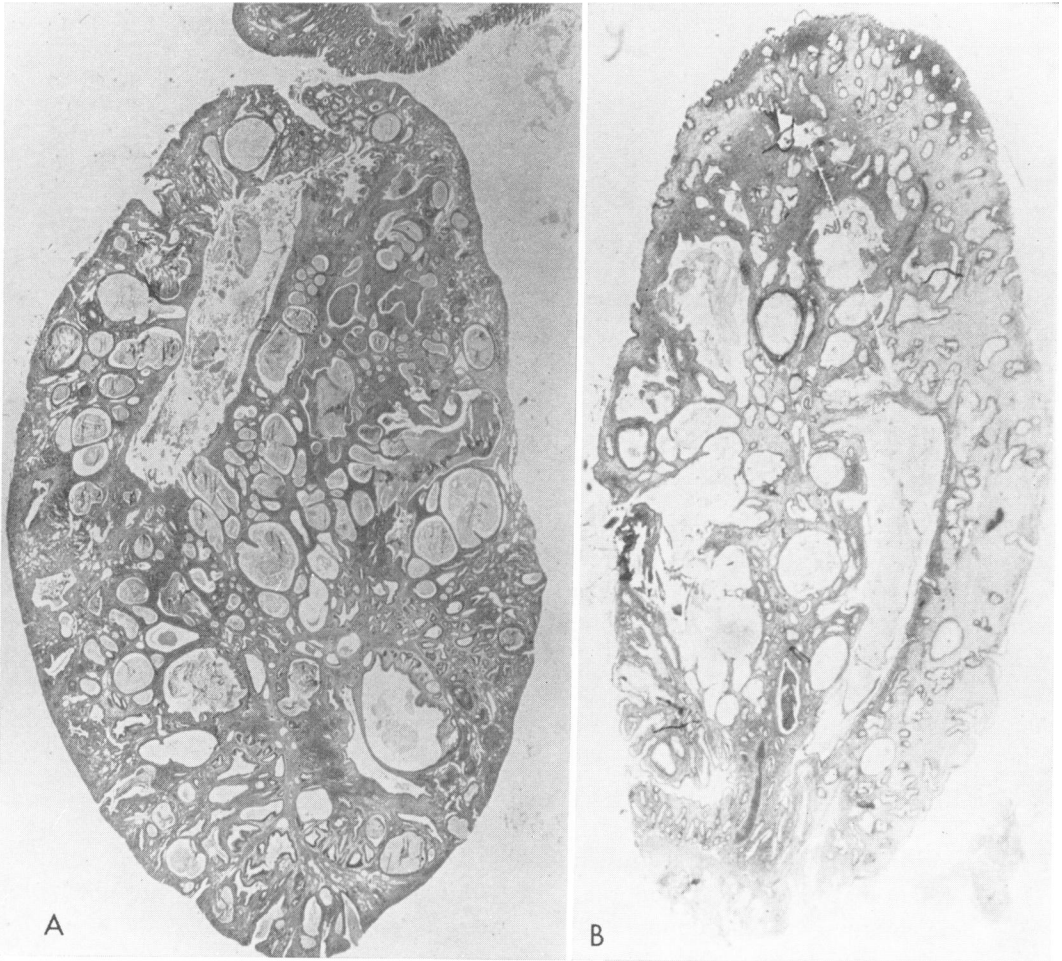


FIG. 2. (A) Juvenile polyp in a child. (B) Juvenile polyp in an adult.

**Number of Polyps per Patient**

Seventy patients had single polyps and 30 had two or more. In five patients who had polyps throughout the colon and rectum, the polyps were all of the juvenile

TABLE 2. *Symptoms*

Bright red blood	82
Protrusion	23
Change in bowel habits	16
Diarrhea	10
Constipation	6
Abdominal Pain	10
Polyp passed by rectum	5

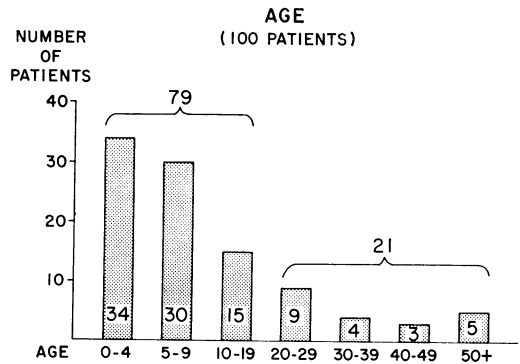


FIG. 3. Age (100 patients).

TABLE 3. *Presenting Symptom*

Bright red blood	75
Protrusion	11
Change in bowel habits	7
Polyp passed by rectum	5
Pain	2

type. Twenty-six of the 30 patients with multiple polyps were less than 20 years of age. All five of the patients with multiple juvenile polyposis were less than 20 years of age.

### Development of New Polyps

Each of 25 patients developed a new polyp at some time during the follow-up period, three of them requiring a third procedure for removal of one or more polyps. Although 61 of our patients have been followed more than 10 years, and 84 more than 5 years, 64 per cent of the patients developing new polyps did so within one year; only 12 per cent occurred after 5 years.

### The Question of Coexistence of Juvenile and Adenomatous Polyps and the Development of Carcinoma

In no patient did polypoid or villous adenoma exist with juvenile polyp. No patient with juvenile polyps, during our period of follow-up, had polypoid or villous adenoma and none subsequently developed carcinoma of the colon or rectum.

Even with multiple polyps (30 of our patients), it is extremely rare to encounter coexisting adenomatous polyps or villous adenomas. This fact, along with the high frequency of auto-amputation, makes excision less imperative in a patient with a juve-

TABLE 4. *Method of Detection of Polyp*

Digital rectal examination	60
Sigmoidoscopy	80
Barium enema	47

TABLE 5. *Method of Removal of Polyp\**

Through sigmoidoscope	47
By rectum	27
Colotomy	21
Passed spontaneously	5
Resection**	5

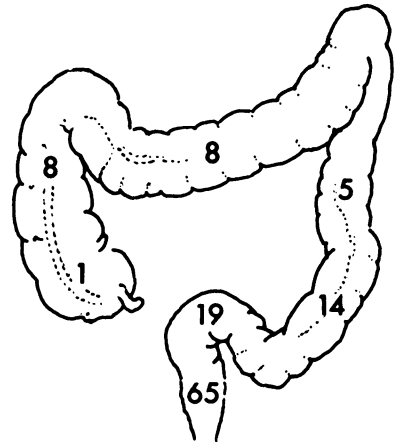
\* Some had polyps removed by more than one method.

\*\* These 5 patients were subjected to subtotal colectomy for multiple polyps, all of which were the juvenile type.

nile polyp beyond the reach of the sigmoidoscope. It may be that removal of such polyps can be done with the colonofiberscope.<sup>11</sup> If such a patient has symptoms, the polyp or polyps should be removed. If there are multiple polyps throughout the colon which are causing symptoms, it is better to perform subtotal colectomy with preservation of the rectum rather than multiple colotomies. Before or after subtotal colectomy, rectal polyps should be removed.

### Summary

We have presented the clinical manifestations of 100 patients with juvenile polyps and follow-up data on 95 of them.



\* 5 involved at multiple sites

FIG. 4. Sites of juvenile polyps.\*

### Conclusions

1. The so-called juvenile polyps can be found in adults.

2. In 100 patients, some had bleeding, but there was no patient with a packed cell volume less than 25, no instance of intussusception, no coexistence with polypoid or villous adenoma and no carcinoma at the time of removal of the polyp or later. Therefore, there is no necessity for removal of such a polyp requiring laparotomy if a polyp removed through the rectum or sigmoidoscope has showed the microscopic characteristics of a juvenile polyp and if the patient has no symptoms. However, removal should be done, if it can be done, through the rectum or through the sigmoidoscope. Furthermore, such a polyp should be removed by colotomy if no polyp can be obtained through the rectum or by the sigmoidoscope to prove that it is a juvenile polyp, or if symptoms are present.

### References

1. Alexander, R. H., Beckwith, J. B., Morgan, A. and Bill, A. H.: Juvenile Polyps of the Colon

and Their Relationship to Allergy. *Am. J. Surg.*, 120:222, 1970.

2. Franklin, R. and McSwain, B.: Carcinoma of the Colon, Rectum, and Anus. *Ann. Surg.*, 171:811, 1970.
3. Gelb, A. M., Minkowitz, S. and Tresser, M.: Rectal and Colonic Polyps Occurring in Young People. *N. Y. State J. Med.*, 62:513, 1962.
4. Holgersen, L. O., Miller, R. E. and Zintel, H. A.: Juvenile Polyps of the Colon. *Surgery*, 69:288, 1971.
5. Kottmeier, P. K. and Clatworthy, H. W., Jr.: Intestinal Polyps and Associated Carcinoma in Childhood. *Am. J. Surg.*, 110:709, 1965.
6. Roth, S. I. and Helwig, E. B.: Juvenile Polyps of the Colon and Rectum. *Cancer*, 16:468, 1963.
7. Shermeta, D. W., Morgan, W. W., Eggleston, J., White, J. J. and Haller, J. A., Jr.: Juvenile Retention Polyps. *J. Ped. Surg.*, 4:211, 1969.
8. Smilow, P. C., Pryor, C. A., Jr. and Swinton, N. W.: Juvenile Polyposis Coli: A Report of Three Patients in Three Generations of One Family. *Dis. Colon Rectum*, 9:248, 1966.
9. Versé, M.: Ueber die Histogenese der Schleimhautcarcinome. *Verh. d. Deutsch. Pathol. Ges.*, 12:95, 1908.
10. Welch, C. E.: Polypoid Lesions of the Gastrointestinal Tract. *Major Problems in Clinical Surgery*, 2:1, 1964.
11. Wolff, W. I. and Shinya, H.: Colonofiberoscopy. *JAMA*, 217:1509, 1971.