

# Genetic Aspects of the Z-E Syndrome:

## Prospective Studies in Two Kindred; Antral Gastrin Cell Hyperplasia

STANLEY R. FRIESEN, M.D., Ph.D.,\* R. NEIL SCHIMKE, M.D.,\*  
A. G. E. PEARSE, M.A., M.D.\*\*

*From the Departments of Surgery and Medicine,  
University of Kansas School of Medicine,  
Kansas City, Kansas 66103*

SINCE THE DESCRIPTION in 1955 by Zollinger and Ellison of the syndrome of fulminating acid-peptic ulcer disease and non-insulin-producing islet cell tumors of the pancreas,<sup>44</sup> there have been descriptions of many additional patients which illustrate interesting variations of clinical pictures. The frequent association of other endocrine tumors in these patients was pointed out by Ellison and Wilson in 1964,<sup>6</sup> and multiple endocrine adenomas now have been reported in up to 48% of patients with the classic Zollinger-Ellison (Z-E) syndrome.<sup>31</sup> The entire symptom-complex, including the Z-E Syndrome, is now commonly referred to as multiple endocrine adenomatosis, type I (MEA, I). The MEA syndrome was probably first introduced into the medical literature by Erdheim in 1903<sup>7</sup> when he reported an acromegalic with an eosinophilic adenoma of the pituitary and four enlarged parathyroid glands, on postmortem examination. In 1953, Underdahl and co-workers<sup>36</sup> brought attention to the common association of "multiple endocrine adenomas" of the pituitary, pancreas and parathyroid when they described eight new cases with tumors of two or more of these glands and 14 other cases in the literature. In 1954 Wermer<sup>43</sup> and Moldawer and associates<sup>23</sup> described the familial aggregation of multiple endocrine adenomas; Wermer proposed that this was a

distinct syndrome inherited as an autosomal dominant trait. The frequent occurrence of peptic ulcer disease was noted in these patients, leading these workers to suggest a genetic relationship between the ulcer diathesis and the endocrine adenomas. Ballard and co-workers<sup>1</sup> in 1964 presented a large family with the multiple endocrine adenomatosis syndrome and reviewed the clinical features of the disease in the 85 cases reported by that time. Islet cell involvement was present in 81.2% of the cases; the parathyroids showed adenomas or hyperplasia in 88.2% of the cases. The pituitary was involved in 64.9%, which was followed in order of decreasing frequency by the adrenals (37.6%) and the thyroid (18.8%).

As with most dominant disorders, considerable variability is present from patient to patient, even within the same family. Many of the reported cases of the MEA, I and the Z-E syndromes have been said to have a negative family history and have thus been considered to be new dominant mutations. However, when relatives of typically affected patients are carefully examined, many are found to have asymptomatic forms of the disease. Johnson and associates<sup>17</sup> carefully evaluated 27 relatives of a patient with the MEA syndrome who were 10 years of age or older and found that 12 of the 27 had endocrinopathies. The frequency of the involvement rose from zero in relatives studied at the end of the first decade of life to more than 50% of those examined in the 5th or 6th decades. The proportion of those involved who were symptomatic also increased with age. Other families have been described in which the Z-E ulcerogenic tumor has been associated with parathyroid and pituitary tumors as

---

Presented at the Annual Meeting of the American Surgical Association, April 26-28, 1972, San Francisco, California.

\* Departments of Surgery and Medicine, University of Kansas School of Medicine, Kansas City, Kansas 66103.

\*\* Department of Histochemistry, Royal Postgraduate School of Medicine, Hammersmith Hospital, London W 12, England.

These investigations were supported in part by NIH Grant RR-67, American Cancer Society Grants 67R1793 and T-528 and Grants from the Wellcome Trust and Medical Research Council, London.

well as lipomas and bronchial and carcinoid tumors.<sup>5,6,11,16,22,33,38,41</sup> In a recent report Vance *et al.*<sup>39</sup> studied the endocrine abnormalities in eight members of a family with multiple endocrine adenomatosis. Three members of this family had documented islet cell hyperplasia, adenoma and/or carcinoma associated with hypoglycemia or the Z-E syndrome, and all but one member of the family was found to have hypersecretion of insulin often associated with elevated blood glucagon and/or gastrin levels. A high incidence of asymptomatic endocrine abnormalities also was found. These investigators propose that the basic genetic defect in the MEA, I syndrome involves hyperplasia of the primordial cells of the islets of Langerhans with chronic oversecretion of one or more islet cell hormones, which in turn influence changes in the other foregut endocrine glands.

The pluriglandular, polyhormonal and familial manifestations of the MEA and Z-E syndromes suggest that there may be a basic, possibly genetic, abnormality of the endocrine cells of the embryologic foregut. The majority of these polypeptide-secreting cells have been shown to have common cytochemical characteristics;<sup>24</sup> although these cells appear to arise from the foregut endoderm, evidence has shown a common neural crest origin<sup>27</sup> and thus they are neuroectodermal.<sup>42</sup> Hyperplasia of these polypeptide-secreting cells is often seen in the affected endocrine glands in the MEA and the Z-E syndromes, either with or without associated adenomatous or neoplastic changes, but it is not known whether the cellular hyperplasia is on a primary genetic basis or is due to an abnormal differentiation of totipotential cells or is secondary either to trophic influences, to abnormal feedback control mechanisms, or to an altered polypeptide. Neither the parathyroid or adrenocortical endocrine cells have as yet been shown to have neural crest origins or cytochemical properties in common with polypeptide-secreting cells; therefore involvement of these endocrine glands may still be considered as secondary phenomena in the MEA syndromes, Types I and II. The latter syndrome, MEA II, encompasses primarily pheochromocytoma and medullary thyroid carcinoma which are tumors of cells which have a neural crest origin.<sup>27,32</sup> The two types of MEA syndromes, which are distinct genetically and represent effects of different gene mutations, do have a clinical overlap in that parathyroid hyperplasia is seen in both types.<sup>31</sup> Elevated serum gastrin levels with antral gastrin cell adenomatosis has been found in one patient with medullary carcinoma of the thyroid.<sup>29</sup> The spectrum of the interendocrine clinical features of the Z-E syndrome, as well as the inter-related embryology and functional cytology, has recently been documented.<sup>11</sup>

In the Z-E syndrome islet cell hyperplasia is not infrequently seen; for this reason ulcer symptoms may per-

sist even after complete surgical excision of suspected unifocal neoplasms.<sup>9</sup> Immunoreactive gastrin has been shown to be present in normal human pancreatic islets by immunofluorescent studies<sup>14,18</sup> and it is likely that the gastrin-containing cells are the classical delta (D) cells of Bloom.<sup>2</sup> Gastrin or substances having gastrin activity have been extracted from primary ulcerogenic tumors, metastases and in serum by bioassay and by radioimmunochemical assay.<sup>3,8,13,15,20</sup> The hyperplastic gastrin-secreting cell of the pancreas is the D cell, but the identification of the precise islet cell type in ulcerogenic tumors is not definite; the variable morphology of the tumor cells may represent a pathological change affecting the proven gastrin-secreting D cell of the normal islet.<sup>40</sup> Argrophil-metachromatic cells which are morphologically similar to the delta cells of the pancreas have been observed in the antropyloric mucosa of the stomach.<sup>35</sup> In studies of the distribution of the endocrine cells of the human stomach, duodenum and jejunum the gastrin (G) cells have been shown to be distributed primarily in the gastric antrum,<sup>28</sup> but they have also been observed in the duodenal bulb and gastrin has been extracted in minute amounts from the duodenal mucosa.<sup>10</sup> Morphologically the G cells appear as large, clear, oval cells distributed in a layer at the junction of the middle and deepest third of the antral mucosa (mid-zone). By immunofluorescence these cells have been demonstrated to store gastrin;<sup>19,25</sup> by electromicroscopy the secretory granules of these cells are round and of various densities and they vary in size (average 180 nm).

That antral gastrin cells may participate in inter-endocrine relationships and may even be implicated in the genetically-induced MEA syndrome is suggested by recent reports of G cell changes in several clinical states. Pearse and Bussolati<sup>25</sup> noted a consistent hyperplasia of antral G cells in cases of gastric acid hypersecretion. Solcia, Capella and Vassallo<sup>34</sup> reported that pyloric G cells were numerous or markedly increased in eight of 15 patients with gastric acid hypersecretion of duodenal ulcer or gastric ulcer with pyloric obstruction. Polak, Bussolati and Pearse<sup>28</sup> found a true hyperplasia of the gastrin-producing cells in four patients with hyperparathyroidism due to adenoma and hyperplasia. They used cytochemical technics, immunofluorescence with television image analysis and ultrastructural studies to show these cells to be fully granulated as well as hyperplastic. Creutzfeldt *et al.*<sup>4</sup> reported hyperplasia of the antral G cells in three patients with primary hyperparathyroidism without acid hypersecretion or ulcer disease. In acromegaly a profound degree of antral G cell hyperplasia with high levels of gastric acid secretion has been reported by Pearse and Bussolati.<sup>25</sup> Creutzfeldt<sup>4</sup> also reported hyperplasia of G cells in six patients with acromegaly, four of whom had significantly increased gastrin

TABLE 1. Routine Endocrine Studies Performed on the Patients with Z-E Syndrome and Their Families

A. Pituitary	
1. Serum growth hormone response to insulin, arginine, glucose	
2. Follicle-stimulating hormone	
3. Metapyrone study	
4. Thyroid stimulating hormone	
B. Parathyroid	
1. Serum calcium and phosphorus (3 determinations)	
2. Tubular reabsorption of phosphate	
3. Parathormone	
C. Pancreas	
1. Glucose tolerance test with measurement of insulin levels	
2. Serum gastrin	
D. Adrenal Cortex	
1. Urinary 17-ketosteroids and 17-ketogenic steroids, basal and with metapyrone	
2. Plasma cortisol	
E. Other Studies	
1. Plasma testosterone	5. Urinary 5-HIAA
2. True Thyroxine	6. Gastric analysis (12-hr. or BAC and MAC)
3. <sup>131</sup> I uptake	7. Antral mucosal biopsy (for G cell changes)
4. Urinary VMA	8. Miscellaneous

content of the antral mucosa, but only one of whom showed enhanced secretory activity. He suggested that the hypophysis may exert a trophic influence, as yet unproven, on the G cells of the antrum.

The G cell population of the gastric antrum in patients exhibiting the Z-E syndrome has not been well documented. In some patients exhibiting the Z-E syndrome, but in whom no pancreatic tumor was demonstrable, antral G cell hyperplasia has been found, while in other patients with pancreatic tumors no antral changes have been noted;<sup>29</sup> these observations have led to the suggestion that the hypergastrinism in patients exhibiting the Z-E syndrome may be accountable to gastrinosis of either the pancreatic islets or the gastric antrum.

It has become increasingly apparent that the Zollinger-Ellison syndrome should be considered as a component of the more inclusive multiple endocrine adenomatosis syndrome;<sup>1,30</sup> it is therefore important to study such patients and their families for the presence of other endocrine lesions including cellular hyperplasias. Antral G cells are reasonably accessible for study; observations of antral G cell changes, coupled with appropriate endocrine screening measurements may lead to the elucidation of the fundamental pathophysiologic abnormality.

#### Method of Study

Two families, ascertained through a proband affected with the Z-E syndrome, have been studied prospectively by thorough endocrine screening in a Clinical Research Unit. Additionally in one of these families, cytochemical

and ultrastructural assessments of the number and appearance of antral gastrin cells obtained by biopsies of antral mucosa during fiberoptic gastroscopy (Olympus GFB) were made. These latter observations have been correlated with the values for gastric acids, serum gastrin levels and other screening tests. The endocrine studies which were carried out in these families are shown in Table 1.

Antral gastrin cell studies were carried out whenever possible on the following groups of patients: (a) one of the two above families with MEA, I syndrome (the P. family) including both affected and non-affected members, and (b) randomly selected, non-related patients having diagnoses of duodenal ulcer, hyperparathyroidism, acromegaly, Z-E syndrome and patients with no known endocrine disease. The antral mucosal tissue was obtained by fiberoptic gastroscopic biopsies in most instances, or by direct surgical sampling during abdominal operations for duodenal ulcer or the Z-E syndrome. Whenever possible the biopsied mucosa was fixed immediately in 2.5% phosphate-buffered glutaraldehyde mixture, prepared and imbedded in Epon-Araldite resin. Sections (1 micron) from these blocks were stained with toluidine blue and scanned by light microscopy for estimation of the number of "clear" cells which have the morphologic appearance of G cells per rosette of gland. Only those sections through the mid-zone of the antral mucosa in which these cells were present were used for counting. From these identified blocks ultra thin sections were prepared for electronmicroscopic identification of gastrin cell granules and an estimation of the degree of granulation of these cells recorded as full, normal, or poor granulation. In nine patients, such as the probands of the families and others having had total gastrectomy previously, only light microscopy of available hematoxylin and eosin-stained paraffin sections was possible for the counting of cells having the morphology of G cells (large, "clear", oval cells) in the midzone of the antral mucosa. In the Z-E patients, the antral G cell findings were correlated with the presence or absence of grossly demonstrable pancreatic tumors. In eight patients, quantitative studies were possible and carried out (by A.G.E.P.) on 35 mm. color transparencies of immunofluorescent preparations, using a television image analyzer. In this instrument a television camera scans the photomicrographs and produces a colored image on a monitor. A particular color is selected by the operator to represent a particular density range. By electronic means the relative area occupied by the pre-selected color can then be determined.

#### Results

The pedigree of each of the two families is illustrated in Figure 1 and the endocrine abnormalities in them are

indicated in Table 2. In one family (R. family) of 29 members in four generations, 11 of 15 members studied to date have shown abnormalities. These include islet cell tumors (2) requiring total gastrectomy and hypophysectomy in one, gastroduodenal carcinoid tumor (1), hyperparathyroidism (4), gastric hyperrugation with ulcer (8). The proband (III-5) over a 16-year span has had a right adrenalectomy for adrenal cortical adenoma with Cushing's syndrome, a total gastrectomy for metastatic ulcerogenic tumor, a transthoracic removal of a mediastinal metastasis, a negative abdominal second-look procedure, several excisions of cervical and mediastinal lymph nodes containing metastases, a transfrontal hypophysectomy and a total thyroidectomy.<sup>10</sup> At the present time he is asymptomatic with a normal serum gastrin and x-rays show regression of a biopsy-proven mediastinal metastasis.

In the P. family, 11 of 14 members in three generations have been studied. Four of 11 have developed proven endocrine abnormalities including hyperparathyroidism due to adenoma and/or hyperplasia (4), metastatic islet cell tumor (1), a non-functional pituitary lesion (1) and a functional adrenal cortical lesion (1). Four of the eight children in the second generation have reached the third decade and three of the four have

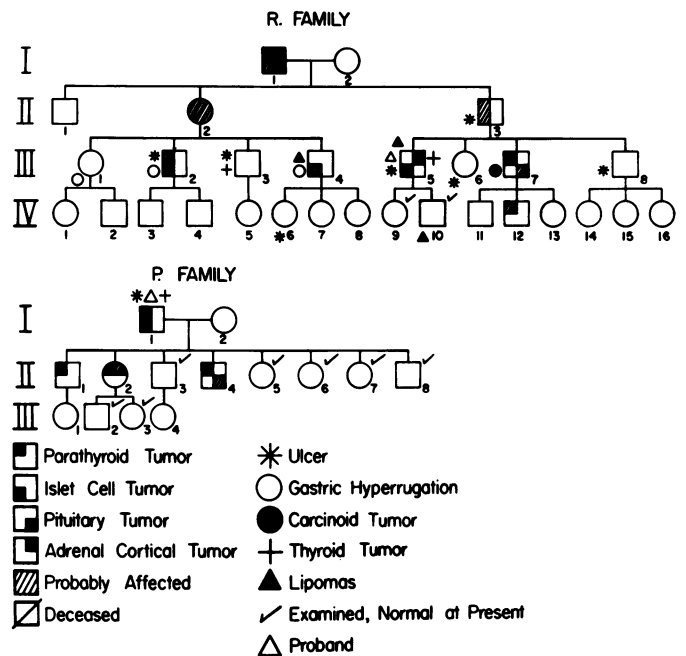


FIG. 1. Diagrams of the pedigree of two families which illustrate the autosomal dominant characteristic and the variable penetrance within the families. These families are being studied prospectively by routine endocrine screening tests listed in Table I. Occult and overt endocrine abnormalities, as indicated here and in Table 2, appear at ages of the early twenties, particularly in the P. family.

TABLE 2. Family Data

Family Pt. No.	Age at & 1st Study	Para-thyroid	Pancreas	Pitui-tary	Adrenal Cortex	Gastric Other	Rugae	Ulcer	Antral G Cell No/Rosette	Gastric Acids mEq/L BAC*	MAC*	Gastrin pg/ml	Comments
<i>R. Family</i>													
I-1	75	-	-	-	-	-	+	+	-	-	-	-	Duodenal Ulcer
II-2	65	-	-	-	-	-	-	+	-	-	-	-	Ulcer, Diabetes mellitus
II-3	65	?	?	-	-	-	+	+	-	60	-	-	Duodenal ulcer Recurrent ulcer Left renal stone Diabetes mellitus
III-1	59	0	0	0	0	0	+	0	-	0	73	120-199	Hiatus hernia
III-2	55	?	+	-	-	0	+	+	-	>100	-	2200	Postbulbar duodenal ulcer, perforated Recurrent stomal ulcer Total gastrectomy 1971
III-3	54	0	0	0	0	+	+	0	-	30	91	80-203	Renal stones Thyroidectomy 1948 for Adenoma Duodenal ulcer symptoms 12-hr gastric vol. 1760 ml.
III-4	44	0	?	0	0	0	+	0	-	0	110	69-100	Pancreatic tumor on sonogram
III-5	36	0	+**	0***	+	+	+	+	2-6	120	130	>1650	Lipoma Cushing's syndrome Rt. Adrenalectomy 1955 Total gastrectomy 1961 Second look 1966 Exc. metastases 1966, 1968 Hypophysectomy 1968 Total thyroidectomy 1969

TABLE 2. (Continued)

Family & Pt. No.	Age at 1st Study	Para-thyroid	Pancreas	Pitui-tary	Adrenal Cortex	Other	Gastric Rugae	Ulcer	Antral G Cell No/Rosette	Gastric Acids mEq/L BAC* MAC*	Gastrin pg/ml	Comments	
III-6	43	0	0	0	0	0	+	+	-	47	-	-	Lipomas Now well—normal serum gastrins
III-7	47	+	0	?	0	+	+	-	-	20	-	20-50	Pyloric ulcer by x-ray Gastroduodenal carcinoid tumors Subtotal gastrectomy 1969 Parathyroidectomy 1970 Expanding sella with increasing HGH
III-8	54	0	0	0	0	0	+	+	-	35	113	90	Duodenal ulcer
IV-6		-	-	-	-	-	+	+	-	-	-	-	Duodenal ulcer Esophagitis
IV-9	20	0	0	0	0	0	0	0	-	0	26	270	Asymptomatic
IV-10	24	0	0	0	0	0	0	0	-	0	46	40	Asymptomatic Lipomas Hypercalcemia
IV-2	18	?	-	-	-	-	-	-	-	-	-	-	
<i>P. Family</i>													
I-1	43	+	+	0	0	0	+	+	-	114	128	>850	Renal stones Post-bulbar duodenal ulcer S.T. parathyroidectomy 1960, 1962 Total Gastrectomy 1967 Regression of metastases Now well; serum gastrin 140 pg/ml.
II-1	26	+	0	0	0	0	0	0	2-4	58	130	20-195	Asymptomatic → renal stones Parathroid hyperplasia Sub-total parathyroidectomy 1971
II-2	25	+	0	0	?	0	0	0	2-4	0	0	25-78	Asymptomatic → renal stones Parathyroid hyperplasia Total parathyroidectomy 1971, 1972
II-3	23	0	0	0	0	0	0	?	4-8	60	130	20-138	Cushing's syndrome Asymptomatic Duodenal bulb deformity
II-4	20	+	0	?	0	0	+	0	2-4	22	91	20-209	Increasing gastric acids Asymptomatic Parathroid hyperplasia S.T. parathyroidectomy 1971 Enlargement of sella
II-5	19	0	0	0	0	0	0	0	-	0	79	83-297	Asymptomatic
II-6	16	0	0	0	0	0	0	0	4-8	58	132	20-248	Asymptomatic
II-7	12	0	0	0	0	0	0	0	4-8	54	124	20-293	Asymptomatic
II-8	4	0	0	0	0	0	0	0	-	-	-	133-90	Asymptomatic Delayed bone age
III-2	5	0	0	0	0	0	0	0	-	-	-	25	Asymptomatic
III-3	4	0	0	0	0	0	0	0	-	-	-	60	Asymptomatic Growth lag

LEGEND: + = positive; involved  
 0 = negative; not involved  
 ? = probably involved  
 - = not studied

\* BAC = Basal acid concentration; MAC = Maximal acid concentration after Histalog

\*\* Although there was metastatic involvement of nodes, liver and lung compatible with islet cell carcinoma, no grossly demonstrable lesion of the pancreas was found.

\*\*\* The pituitary gland was normal histologically at the time of hypophysectomy for metastatic disease.

TABLE 3. Antral G Cell Changes

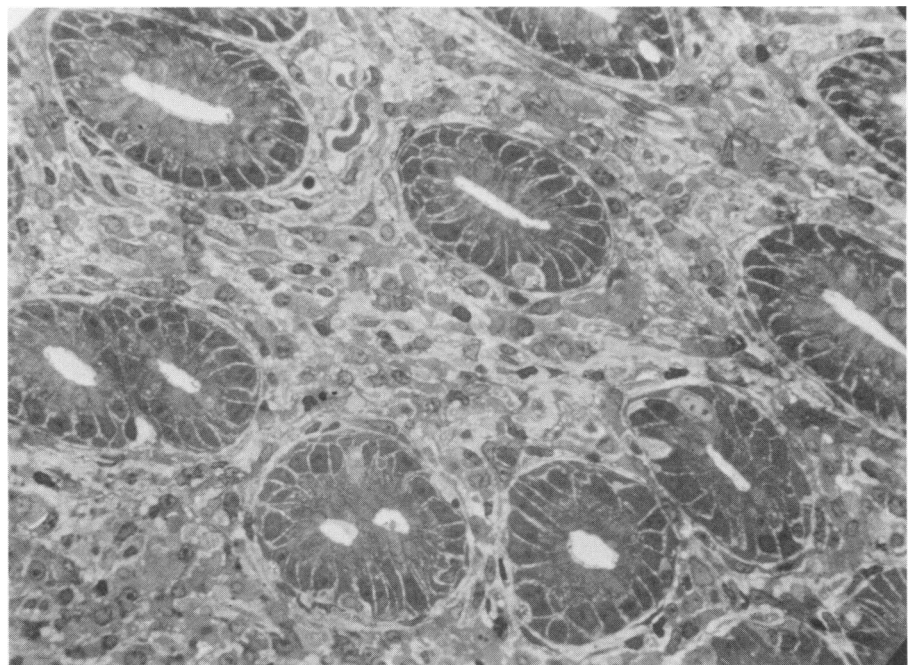
Diagnosis	Patients	No. of G Cells Rosette	G Cell Area (%)	G Cell Granulation	Gastric Acids mEq/L		Serum Gastrin pg/ml.
					BAC	MAC	
No endocrine disease	7	0-2	0.5	Normal	15	70	50-100
Duodenal ulcer	4	2-4	2.0	Full	46	124	24-110
Hyperparathyroidism	5	4-10	8.0	Full	38	130	20-195
Pituitary tumor	2	2-9	17.0	Full	22	91	80-120
Zollinger-Ellison Syndrome with pancreatic tumor	5	0-1	<0.5	Full	115	130	900-3700
Zollinger-Ellison Syndrome without pancreatic tumor	6	6-12	15.0	Full	120	130	2800-9500
Zollinger-Ellison Syndrome with medullary carcinoma of thyroid	1	4-10	10.0	Full	120		9000

required operative treatment. The proband (I-1) required three operations initially for excision of the parathyroid glands and a total gastrectomy for metastatic islet cell carcinoma after which there was visible regression of hepatic and pulmonary metastases.<sup>10</sup> He has had a transthoracic excision of a single recurrent pulmonary metastasis and is at the present time asymptomatic with no demonstrable evidence of metastases and a normal serum gastrin level.

The results of the antral G cell studies are indicated in Table 2 (P. family), Table 3 and in Figures 2-9. There was an increase over normal in the number of antral endocrine cells having the morphologic characteristics of G cells, as noted by light microscopy of toluidine blue-stained sections, in the members of the P. family. This observation was consistent whether the family members were symptomatic or asymptomatic and irrespective of the presence or absence of other endocrine ab-

normalities. The degree of apparent G cell hyperplasia seemed to correlate positively with gastric acid hypersecretion; the serum gastrin levels in this family were within the normal range, except in the presence of the Zollinger-Ellison syndrome. True but moderate G cell hyperplasia was noted in the antra of duodenal ulcer patients. A definite increase in the number and in the area of immunofluorescence of G cells was seen in hyperparathyroidism, acromegaly and in the Z-E syndrome in which pancreatic lesions were not grossly demonstrable. The serum gastrin values in the latter group of patients were extremely elevated (2,800-9,500 pg./ml.), and the antral gastrin cell population constituted 15% of the area of the antral mucosa, or 30 times the normal G cell fluorescent area. In hyperparathyroidism the G cells numbered 4-10 per gland rosette and represented 8% of the antral mucosal area. In acromegaly the G cells constituted 17% of the total mucosal area in one of the pa-

FIG. 2. Photomicrograph of the mid-zone glands of normal antral mucosa from a patient with no known endocrine disease illustrating sparse distribution (0-2/gland-rosette) of large clear oval cells having the morphologic characteristics of G cells. (Optical microscopy of glutaraldehyde-fixed, resin-embedded, toluidine blue-stained sections, original magnification  $\times 440$ .)



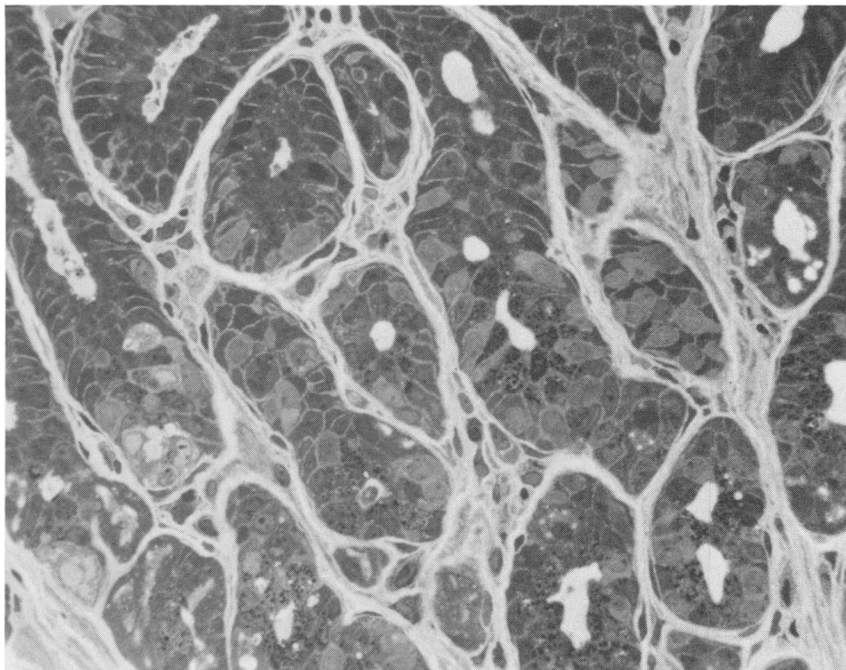


FIG. 3. Photomicrograph of the mid-zone glands of the antral mucosa from a patient (II-2 in P. family) with symptomatic endocrine involvement illustrating the numerous large clear oval cells having the morphologic appearance of G cells. (Optical microscopy of glutaraldehyde-fixed, resin-embedded, toluidine blue-stained sections, original magnification  $\times 440$ .)

tients. Antral G cell hyperplasia was not marked in those patients exhibiting the clinical features of the Z-E syndrome without grossly demonstrable pancreatic lesions, but including metastatic involvement of lymph nodes, liver and lung, and high serum gastrin levels for which total gastrectomy was performed. The number of G cells varied from six to 12 per gland rosette with immunofluorescence of 15% of the area, a hyperplasia of sufficient magnitude to be consistent with the term "gastrinoma"

or "gastrinoma." A marked gastrinosis of the antral mucosa was noted in a patient with severe symptoms due to gastric acid hypersecretion with high serum gastrin levels; at autopsy a medullary carcinoma of the thyroid gland was found and there was no demonstrable pancreatic lesion. One patient who exhibited severe clinical manifestations of the Z-E syndrome due to islet cell hyperplasia without tumor, and who required a total gastrectomy, also had antral G cell hyperplasia (2 to 7 G

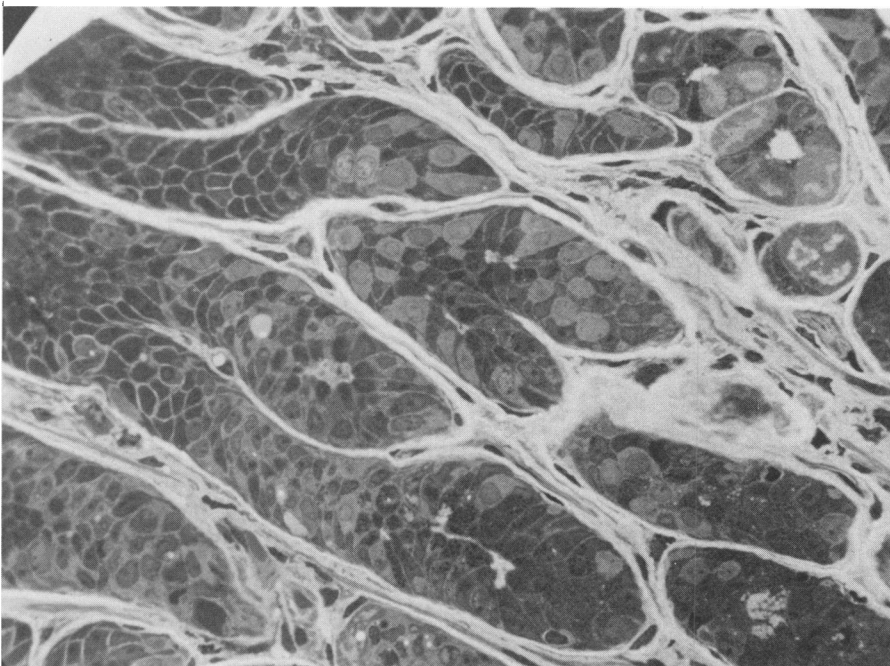


FIG. 4. Photomicrograph of the mid-zone glands of the antral mucosa from a patient (II-7 in the P. family) who is asymptomatic with no discernible endocrine involvement illustrating the numerous large clear oval cells having the morphological appearance of G cells. There are slightly elevated gastric acid concentration values. (Optical microscopy of glutaraldehyde-fixed, resin-embedded, toluidine blue-stained section, original magnification  $\times 440$ .)



FIG. 5. Photomicrograph of the glands of the antral mucosa from a patient, non-familial, with hyperparathyroidism due to an adenoma, illustrating numerous large clear oval cells having the characteristic appearance of G cells in the mid-zone of the mucosa. (Optical microscopy of glutaraldehyde-fixed, resin-embedded, toluidine blue-stained section, original magnification  $\times 275$ .)

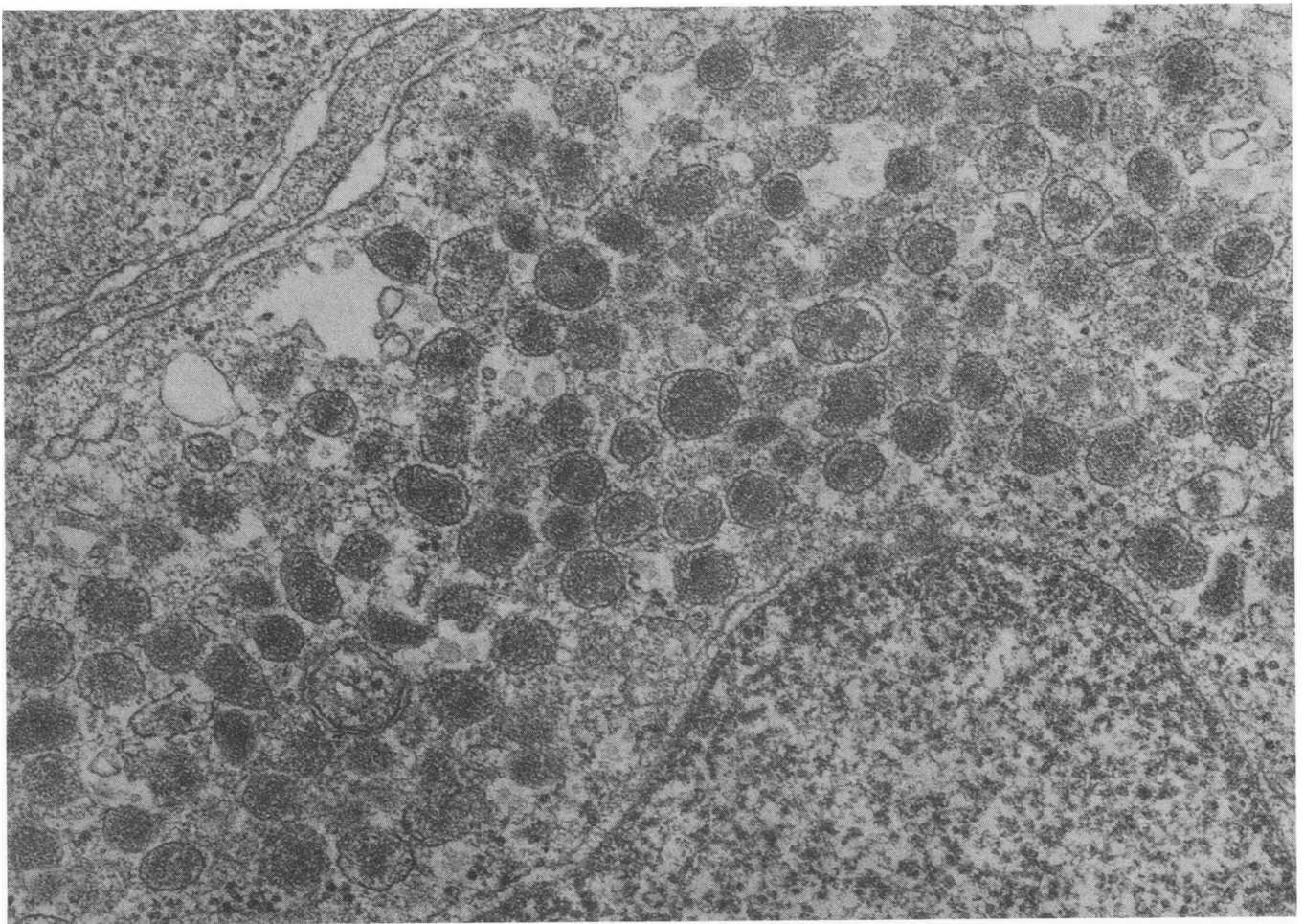
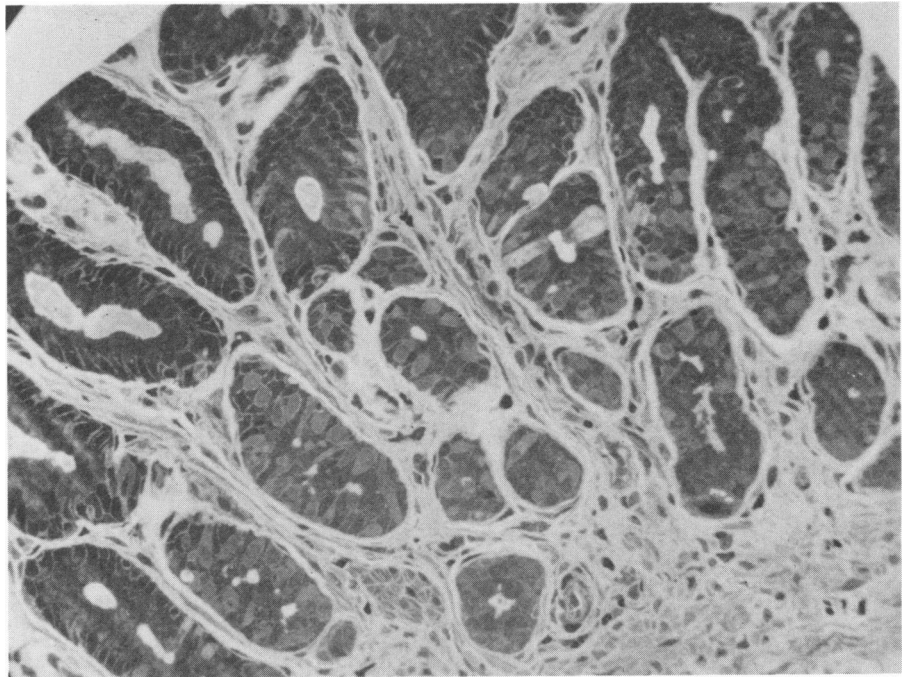


FIG. 6. Electronmicrograph of a portion of a gastrin (G) cell in the antral mucosa from a patient (II-2 in P. family) with symptomatic endocrine involvement illustrating the full secretory granulation of the cytoplasm. The granules are round and of varying densities. A portion of the large nucleus is at the bottom of the photomicrograph (original magnification  $\times 15,000$ ).



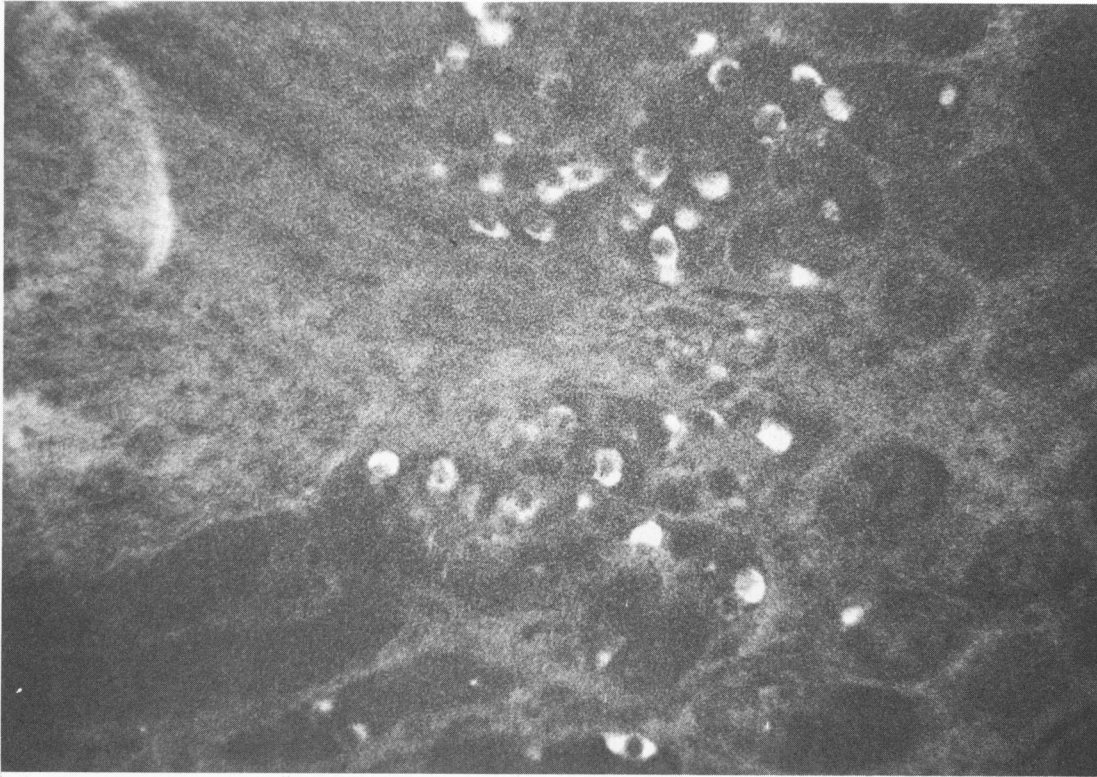


FIG. 7. Photomicrograph of the mid-zone of the antral mucosa from a patient with duodenal ulcer illustrating moderate hyperplasia of immunofluorescent G cells, (original magnification  $\times 720$ ).

cells per gland rosette). A definite discrete polypeptide tumor of the stomach wall (interpreted as a metastasis) was noted in a total gastrectomy specimen from a patient with gastrin-secreting carcinoma of the pancreas. In four

patients with demonstrable pancreatic islet cell tumors a normal population of antral G cells was noted, similar to the pattern observed in patients without endocrine disease.

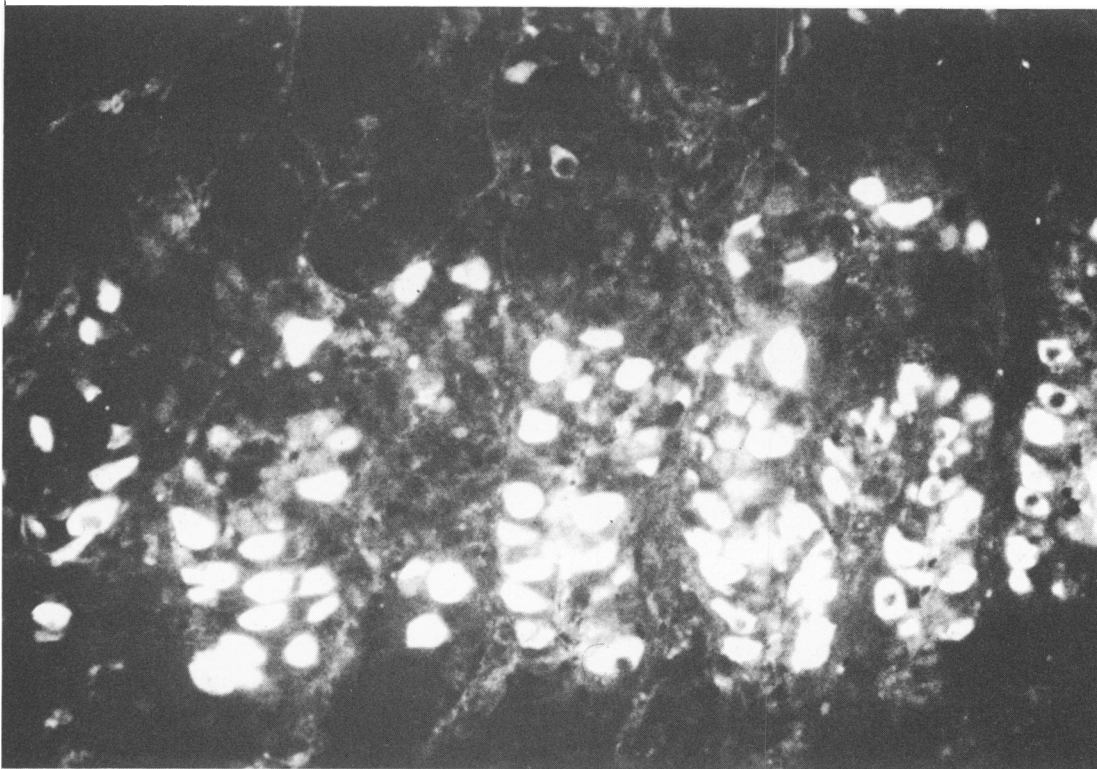
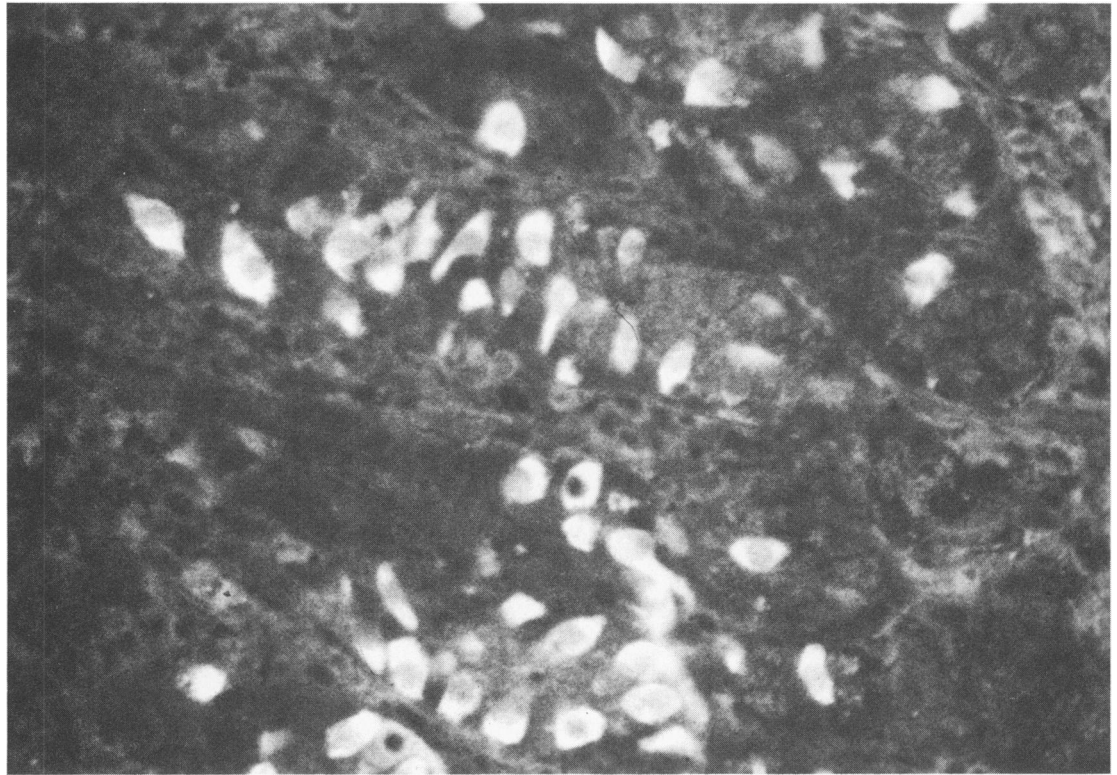


FIG. 8. Photomicrograph of the mid-zone of the antral mucosa from a patient with hyperparathyroidism illustrating marked hyperplasia of immunofluorescent G cells (original magnification  $\times 720$ ).

FIG. 9. Photomicrograph of the mid-zone of the antral mucosa from a patient with the clinical picture of the Zollinger-Ellison syndrome with high levels of gastric acids and serum gastrin, but without a grossly demonstrable pancreatic tumor; a marked hyperplasia of immunofluorescent G cells is shown (original magnification  $\times 720$ ).



### Discussion

The study of two kindred reveals that asymptomatic family members harbor endocrine abnormalities which can be elucidated by diagnostic screening and who become symptomatic with time. Two members of the P. family passed urinary tract stones after hypercalcemia was found. As the family members reached the third decade, hyperparathyroidism, gastric acid hypersecretion, pituitary and adrenal cortical abnormalities developed insidiously; while there may be a synchronous overlap of these endocrinopathies, there is a metachronous pattern which should lead to an expectant awareness of the possibility of the development of new endocrine manifestations in these patients. The advisability of prospective screening and counseling of families of probands affected with any of the foregut endocrinopathies seems more than obvious. As in other autosomal dominant traits, the two families presented in this report demonstrate a great deal of variability in expressivity. Some individuals have a full-blown pluriglandular involvement; others have, for a time, only asymptomatic hypercalcemia, while in others only the gastrointestinal symptoms are present. The most common clinical endocrine abnormality in these, as well as other families, is that of hyperparathyroidism due to chief cell hyperplasia. It is difficult to justify its relatively common frequency if it is considered that this abnormality is prob-

ably of secondary nature, i.e. responsive to the hypocalcemia of calcitonin secretion or to glucagon stimulation. Although the secretory product of the parathyroid glands is a polypeptide, the secretory cells have not as yet been shown to derive from neuroectodermal cells.

Based on these and other family descriptions there can be little doubt that there is a genetic basis for the development of the Z-E and the MEA syndromes as phenotypic variants of the same mutant gene; the exact genetic abnormality is not clear. The hereditary characteristics of simple duodenal ulcer disease are thought to be polygenic.

The observations of apparent antral gastrin cell hyperplasia in all members of the P family who had biopsies suggest that these changes precede the development of symptomatic endocrine disease. Furthermore, the antral G cell hyperplasia in patients exhibiting the Z-E syndrome without tumor suggests also that antral G cell hyperplasia may precede the development of islet cell tumors; why the G cell hyperplasia should "recede" if it is postulated that islet cell tumors develop sequentially is not understandable at this time. Perhaps the Zollinger-Ellison syndrome with high serum gastrin levels may occur as a result of gastrinosis of either the antral G cells or the pancreatic islet D cells, as has been suggested.<sup>20</sup> More studies for the purpose of correlating pancreatic and antral gastrin-secreting cell changes are needed to clarify these observations. Despite the anti-gastrin fluores-

cence similarities between pancreatic islet D cells and the antral G cells, there seem to be cytochemical differences in properties of the two gastrin-storing cells.<sup>40</sup> There have been descriptions of patients who have had the clinical findings of the Z-E syndrome, including high serum gastrin levels and even metastases consistent with islet cell carcinoma, yet who do not have grossly demonstrable pancreatic tumors.<sup>12a,12b</sup> These patients have been considered to have occult islet cell tumors or islet cell hyperplasia; the relatively new findings of antral G cell hyperplasia may account for the elevated serum gastrin levels in this small group of patients. In other clinical endocrinopathies hyperplasia of the antral G cells does not necessarily imply a functional hypersecretion of gastrin from these cells. The G cells are full of granules and are undoubtedly storing the gastrin, as in duodenal ulcer patients in whom the serum gastrin values are not elevated. When patients with duodenal ulcer are given bicarbonate by mouth the serum gastrin values rise,<sup>12b</sup> which indicates that these cells are capable of responding to a stimulus, and conversely, are inhibited from secreting by the acid secretions of the vagally-innervated stomach. The hyperplasia of antral G cells in duodenal ulcer and in other acid hypersecretory states may be a compensatory phenomenon in response to the continuous acid inhibition of gastrin release. Alternatively, the G cell hyperplasia may be secondary to an as yet unknown pituitary trophic influence or it could result from an abnormal cell differentiation such as an uncontrolled totipotential cell. Or finally, as is suggested by the data in this report, the antral G cell hyperplasia may be an underlying genetic abnormality in the polypeptide-secreting endocrine system. Glandular hyperplasia, and perhaps neoplasia with or without increased hormone synthesis may be due to a direct effect of mutation on gland function. Theoretically, all endocrine cells involved in this syndrome might contain a factor rendering them responsive to the same mutant gene, resulting in excessive growth of the affected cells.

The basic mechanisms for the pathogenesis of the Zollinger-Ellison and multiple endocrine adenomatosis syndromes remain unknown. Wermer<sup>43</sup> has proposed a pleiotrophic defect which stimulates cell growth in each of the glands. According to Vance *et al.*<sup>39</sup> the primary genetic defect resides in the islet cells, consisting of hyperplasia of the primordial islet cells. These produce a chronic oversecretion of one or more of the islet cell hormones, glucagon, insulin and/or gastrin. These in turn influence changes in the other polypeptide-secreting glands. This phenomenon of nesidioblastosis is supported by their study of a family in which a high frequency of pancreatic involvement was present. The pleomorphic functional capability of islet cells is compatible with their hypothesis. Although that theory is attractive, it

does not explain antral gastrin cell hyperplasia which seems to occur before measurable islet cell functional abnormalities. The possibility of an enteric to insular influence<sup>37</sup> is as plausible as an insular to enteric influence. For instance, gastric acid-stimulation of the release of enteric (duodenal) hormones such as secretin may affect islet cell function and structure. These various theories of the pathogenesis of the Z-E and MEA syndromes have been described in detail elsewhere.<sup>11</sup>

The observation of antral G cell changes in this study were made using four cytological technics: light microscopy of hematoxylin and eosin-stained, formalin-fixed paraffin sections for counting; light microscopy of toluidine blue-stained, glutaraldehyde-fixed, resin-embedded sections for counting; electronmicroscopy of glutaraldehyde-fixed sections for degree of granulation; and immunofluorescent micrography with television image estimation of G cell area. The reliability of observation increases respectively in the four technics. The optical microscopy for counting of cells which have the morphologic characteristics of G cells (large, oval "clear" cells with a large nucleus) is not proof that these endocrine cells are in fact gastrin-containing cells; experience in viewing many sections is required before such observations become meaningful.<sup>26</sup> Although such technics, particularly light microscopy of toluidine blue-stained sections, are practical for screening and counting purposes, the accurate and incontrovertible designation of the exact endocrine cell and its specific hormone content is extremely difficult. We, as others,<sup>21</sup> urge caution in such interpretations based only on light microscopy. The immunofluorescent technics, as used in some of the observations reported here, are much more reliable.

It is possible that the gastrointestinal endocrine cell which is the most accessible for study—the antral G cell—may lead the way to earlier diagnosis of the MEA, I syndrome of which the Zollinger-Ellison syndrome is a phenotypic variant.

### Conclusions

Further evidence is presented for a genetic autosomal dominant basis of the multiple endocrine adenomatosis syndrome of which the Zollinger-Ellison syndrome is a component. Two kindred which are being screened prospectively have yielded asymptomatic endocrinopathies which have become symptomatic and have required surgical treatment. Studies of gastrin cells obtained by antral biopsy from these and other patients suggest that an apparent hyperplasia of the antral G cells accompanies duodenal ulcer, hyperparathyroidism, acromegaly and some cases of the Z-E syndrome. The antral gastrin cell hyperplasia in the MEA, I syndrome is of sufficient magnitude to be consistent with the term "gastrincy-toma."

### Acknowledgment

The authors gratefully acknowledge the assistance of the following:

- Dr. Robert E. Bolinger, Professor of Medicine, University of Kansas Medical Center, for the assay of gastrin, parathormone, cortisol, growth hormone, insulin, true thyroxine and follicle-stimulating hormone;
- Dr. James E. McGuigan, Professor of Medicine, University of Florida, for some of the assays of serum gastrin;
- Dr. James Rhodes, Associate Professor of Medicine and Physiology, University of Kansas Medical Center, and his staff for the gastroscopic biopsies of antral mucosa;
- Dr. Dante Scarpelli, Professor of Pathology and Mrs. Kay Pierce, technician, University of Kansas Medical Center, for some of the cytological and electronmicroscopic studies.

### References

1. Ballard, H. S., Frame, B., and Hartsock, R. J.: Familial Multiple Endocrine Adenoma-peptic Ulcer Complex. *Medicine*, **43**:481, 1964.
2. Bloom, N.: New Type of Granular Cell in Islets of Langerhans in Man. *Anat. Rec.*, **49**:363, 1931.
3. Code, C. F., Hallenbeck, G. A. and Summerskill, W. H. J.: Extraction of a Gastric Secretagogue from Primary and Metastatic Islet Cell Tumors in Two Cases of the Zollinger-Ellison Syndrome. *J.A.S. Res.*, **2**:136, 1962.
4. Creutzfeldt, W., Arnold, R., Creutzfeldt, C., Feurle, G., and Ketterer, H.: Gastrin and G cells in the Antral Mucosa of Patients with Pernicious Anemia, Acromegaly and Hyperparathyroidism and in a Zollinger-Ellison Tumor of the Pancreas. *Europ. J. Clin. Invest.*, **1**:461, 1971.
5. Dutta, P., Wallace, M. R., Wrong, O. M., Taylor, S. and Welbourn, R. B.: Familial Multiple Endocrine Adenopathy (Primary Hyperparathyroidism and Zollinger-Ellison Syndrome) in two siblings. *Proc. Roy. Soc. Med.*, **61**:658, 1968.
6. Ellison, E. H., and Wilson, S. D.: The Zollinger-Ellison Syndrome: Reappraisal and Evaluation of 620 Registered Cases. *Ann. Surg.*, **160**:512, 1964.
7. Erdheim, J.: Zur normalen und pathologischen Histologie der Glandula Thyreoides, Parathyreoidea und Hypophysis. *Beitr. Path. Anat.*, **33**:158, 1903.
8. Friesen, S. R., Tracy, H. J., and Gregory, R. A.: Mechanism of the Gastric Hypersecretion in the Zollinger-Ellison Syndrome: Successful Extraction of Gastrin-like Activity for Metastases and Primary Pancreaticoduodenal Islet Cell Carcinoma. *Ann. Surg.*, **155**:167, 1962.
9. Friesen, S. R.: A Gastric Factor in the Pathogenesis of the Zollinger-Ellison Syndrome. *Ann. Surg.*, **168**:483, 1968.
10. Friesen, S. R., Bolinger, R. E., Pearse, A. G. E., and McGuigan, J. E.: Serum Gastrin Levels in Malignant Zollinger-Ellison Syndrome after Total Gastrectomy and Hypophysectomy. *Ann. Surg.*, **172**:504, 1970.
11. Friesen, S. R.: The Zollinger-Ellison Syndrome. Monograph in Current Problems in Surgery, Year Book Publishers, April, 1972.
- 12.a. Friesen, S. R.: The Effect of Total Gastrectomy on the Zollinger-Ellison Tumor: Observations by Second-look Procedures. *Surgery*, **62**:609, 1967.
- 12.b. Friesen, S. R.: Unpublished data.
13. Gregory, R. A., Tracy, H. J., French, J. M., and Sircus, W.: Extraction of a Gastrin-like Substance from a Pancreatic Tumor in a Case of Zollinger-Ellison Syndrome. *Lancet*, **1**:1040, 1960.
14. Greider, M. H. and McGuigan, J. E.: Cellular Localization of Gastrin in the Human Pancreas. *Diabetes*, **20**:389, 1971.
15. Grossman, M. I., Tracy, H. J., and Gregory, R. A.: Zollinger-Ellison Syndrome in a Bantu Woman, with Isolation of a Gastrin-like Substance from the Primary and Secondary Tumors. II. Extraction of Gastrin-like Activity from Tumors. *Gastroenterology*, **41**:87, 1961.
16. Hallenbeck, G. A.: The Zollinger-Ellison Syndrome. *Gastroenterology*, **54**:426, 1968.
17. Johnson, J. G., Summerskill, W. H. F., Anderson, V. E., and Keating, F. R.: Clinical and Genetic Investigation of a Large Kindred with Multiple Endocrine Adenomatosis. *N. Engl. J. Med.*, **277**:1379, 1967.
18. Lomsky, R., Langr, F., and Vortel, V.: Immunohistochemical Demonstration of Gastrin in Mammalian Islets of Langerhans. *Nature*, **223**:618, 1969.
19. McGuigan, J. E.: Gastric Mucosal Intracellular Localization of Gastrin by Immunofluorescence. *Gastroenterology*, **55**:315, 1968.
20. McGuigan, J. E., and Trudeau, W. L.: Immunochemical Measurement of Elevated Levels of Gastrin in the Serum of Patients with Pancreatic Tumors of the Zollinger-Ellison Variety. *N Engl J. Med.*, **278**:1308, 1968.
21. McGuigan, J. E. and Grieder, M. H.: Correlative Immunohistochemical and Light Microscopic Studies of the Gastrin Cell of the Antral Mucosa. *Gastroenterology*, **60**:223, 1971.
22. Moldawer, M.: Multiple Endocrine Tumors and Zollinger-Ellison Syndrome in Families: One or Two Syndromes? A Report of Two New Families. *Metabolism*, **11**:153, 1962.
23. Moldawer, M. P., Nordi, G. L., and Raker, W.: Concomitance of Multiple Adenomas of the Parathyroids and Pancreatic Islets with Tumor of the Pituitary: A Syndrome with Familial Incidence. *Am. J. Med. Sci.* **228**:190, 1954.
24. Pearse, A. G. E.: Common Cytochemical and Ultrastructural Characteristics of Cells Producing Polypeptide Hormones (the APUD series) and Their Relevance to Thyroid Ultimobranchial C-cells and Calcitonin. *Proc. Roy. Soc., London*, **170**:71, 1968.
25. Pearse, A. G. E. and Bussolati, G.: Immunofluorescence Studies of the Distribution of Gastrin Cells in Different Clinical States. *GUT*, **11**:646, 1970.
26. Pearse, A. G. E., Coulling, I., Weavers, B., and Friesen, S.: The Endocrine Polypeptide Cells of the Human Stomach, Duodenum, and Jejunum. *GUT*, **11**:649, 1970.
27. Pearse, A. G. E. and Polak, J. M.: Cytochemical Evidence for the Neural Crest Origin of Mammalian Ultimobranchial C cells. *Histochemie*, **27**:96, 1971.
28. Polak, J. M., Bussolati, G., and Pearse, A. G. E.: Cytochemical, Immunofluorescence and Ultrastructural Investigations on the Antral G Cells in Hyperparathyroidism. *Virchows Arch. Abt. B Zellpath.*, **9**:187, 1971.
29. Polak, J. M., Stagg, B. and Pearse, A. G. E.: Two Zollinger-Ellison Syndromes and Their Relationship to Duodenal Ulcer. *Gut* (In Press) 1972.
30. Ptak, T., and Kirsner, J. B.: The Zollinger-Ellison Syndrome, Polyendocrine Adenomatosis and Other Endocrine Associations with Peptic Ulcer, in Stollerman, G. H. (ed.), Ad-

- vances in Internal Medicine (Chicago: Year Book Medical Publishers, Inc. 1970), 16:213.
31. Rimoin, D. L., and Schimke, R. N.: Genetic Disorders of the Endocrine Glands (St. Louis: The C. V. Mosby Company, 1971).
  32. Schimke, R. N., Hartmann, W. H., Prout, T. E., and Rimoin, D. L.: Syndrome of Bilateral Pheochromocytoma, Medullary Thyroid Carcinoma and Multiple Neuromas. *N Engl J. Med.*, 279:1, 1968.
  33. Snyder, N. III, Scurry, M. T., and Deiss, W. P. Jr.: Five Families with Multiple Endocrine Adenomatosis. *Ann. Intern. Med.*, 76:53, 1972.
  34. Solcia, E., Capella, C., and Vassallo, G.: Endocrine Cells of the Stomach and Pancreas in States of Gastric Hypersecretion. *Gastroenterology*, 2:147, 1970.
  35. Solcia, E. and Sampietro, R.: Cytologic Observations on the Pancreatic Islets with Reference to Some Endocrine-like Cells of the Gastro-intestinal Mucosa. *Z. Zellforsch.*, 68:689, 1965.
  36. Underdahl, L. O., Woolner, L. B., and Black, B. M.: Multiple Endocrine Adenomas: Report of 8 Cases in Which the Parathyroids, Pituitary and Pancreatic Islets were Involved. *J. Clin. Endocrinol.*, 1:20, 1953.
  37. Unger, R. H., and Eisentraub, A. M.: Entero-insular Axis. *Arch. Intern. Med.*, 123:261, 1969.
  38. Vance, J. E., Stoll, R. W., Kitabchi, A. E., Williams, R. H., and Wood, F. C., Jr.: Nesidioblastosis in Familial Endocrine Adenomatosis. *JAMA*, 207:1679, 1969.
  39. Vance, J. E., Stoll, R. W., Kitabchi, A. E., Buchanan, K. D., Hollander, D. and Williams, R. H.: Familial Nesidioblastosis As the Predominant Manifestation of Multiple Endocrine Adenomatosis. *Am. J. Med.*, 52:211, 1972.
  40. Vassallo, G., Solcia, E., Bussolati, G., Polak, J. M. and Pearse, A. G. E.: Non-G Cell Gastrin-producing Tumours of the Pancreas. *Virch. Arch. B. (In Press)* 1972.
  41. Way, L., Goldman, L., and Dunphy, J. E.: Zollinger-Ellison Syndrome: An Analysis of Twenty-five Cases. *Am. J. Surg.*, 116:293, 1968.
  42. Weichert, R. F.: Neural Ectodermal Origin of Peptide-secreting Endocrine Glands. *Am. J. Med.*, 49:232, 1970.
  43. Wermer, F.: Genetic Aspects of Adenomatosis of Endocrine Glands. *Am. J. Med.*, 16:363, 1954.
  44. Zollinger, R. M., and Ellison, E. H.: Primary Peptic Ulceration of the Jejunum Associated with Islet Cell Tumors of the Pancreas. *Ann. Surg.*, 142:709, 1955.

#### DISCUSSION

DR. JAMES CHARLES THOMPSON (Galveston): We have studied the antral mucosal gastrin levels in patients with the Zollinger-Ellison syndrome—only three such patients—and found them to be normal. They were patients who had pancreatic tumors. I would like to ask Dr. Friesen if he has measured antral gastric mucosal levels in patients with the Zollinger-Ellison syndrome, with and without pancreatic tumors, and specifically to ask what the tissue gastrin levels are in patients who have this hyperplasia, or gastrinoma; and secondly, to ask what happens after antrectomy to the serum gastrin levels in patients who have antral gastrinomas and no pancreatic tumors.

DR. ROBERT M. ZOLLINGER (Columbus): I am really sorry I brought it up, it is causing so much trouble.

Dr. Friesen always comes up with new and stimulating concepts about these gastrin producing islet cell tumors. Sometimes I believe him, and sometimes I do not. This morning I am not quite sure, but I would like to believe him.

It is perfectly true, as he points out, that many of these instances do occur in families. In our experience, I think we have eight families of approximately 30 cases that we have studied rather intensively.

In addition, we have reviewed the records of about 800 reported cases through 1970, and we feel that the Wermer syndrome is involved in about one in 20, or 5%, and that multiple endocrine involvement is present in 20 to 25% of the cases.

However, I would point out that when you review the literature, there has been no mention of any endocrine survey in at least one half of the cases, so right off the bat we have about 400 cases in which we could not be sure about the true incidence of endocrine involvement. And furthermore, recent studies have demonstrated the islet cell tumors are associated with an increase in thyrocalcitonin, which in turn may result in hyperplasia of the parathyroid glands. So, when you begin to realize that the parathyroids are involved, in perhaps 20% of the cases, this may be a secondary effect, and not a true endocrine involvement, as we, at least, tend to regard it.

Dr. Friesen presents a very interesting concept concerning the antrum and gastrin cell hyperplasia, which he believes may be of sufficient magnitude to be consistent with the term "gastrin cytoma." The origin of the gastrin cell, I think, is still a little bit debatable. We heard Dr. Greider from Washington University talk to us the other day about this. She has been studying this problem for many, many years, and I am not sure that the light microscopists or the electron microscopists are really certain where, or to what extent these cells really occur.

I hope, however, that he is correct in this assumption and that biopsy of the antrum may assist the clinician. This may be particularly helpful in the borderline cases that we have heard about this morning, when the gastrin level tends to be low.

I would say just a word about low gastrin levels. When they are low, I mistrust the immunoassay rather than the patient. Of course, all tumors have to start small, and it is true that some of them are borderline, and here we would have an example of biopsy of the antral mucosa, which might help in these borderline cases.

PRESIDENT MOORE: I would like to ask Dr. Friesen a question. If this is a single gene, why does it involve so many different organs? Could it be that the pituitary is basic to most of the cases? I noticed you had, I think, one or two with enlarged sellae.

DR. S. R. FRIESEN (closing): I will answer Dr. Thompson's questions first, if I may. Did we measure the tissue antral gastrin content in Zollinger-Ellison patients? The answer is no. We have measured tissue gastrin values in the antrum in dogs, but not in these patients.

What happens to the serum gastrin after an antrectomy in which there is antral gastrinosis? I do not know exactly, except in the instance of one patient, particularly. This patient had very high gastric acid values, over 2000 ml. in 12 hours, over 100 mEq easily in that 12 hours of output of acid, and who had a serum gastrin value of 558, right in between the values for duodenal ulcer and the Zollinger-Ellison syndrome. At operation there was a nodular pancreas, and I biopsied the pancreas and a lymph node and found normal pancreas and no tumor in the