

# Abdominal Organ Cluster Transplantation for the Treatment of Upper Abdominal Malignancies

THOMAS E. STARZL, M.D., PH.D., SATORU TODO, M.D., ANDREAS TZAKIS, M.D., LUIS PODESTA, M.D., LUIS MIELES, M.D., ANTHONY DEMETRIS, M.D.,\* LEWIS TEPERMAN, M.D., RICK SELBY, M.D., WILLIAM STEVENSON, M.D., ANDREI STIEBER, M.D., ROBERT GORDON, M.D., and SHUNZABURO IWATSUKI, M.D.

Ten patients with primary malignant tumors of the biliary tract, duodenum, or stomach and with secondary involvement of the liver underwent removal of most or all of the stomach, liver, pancreas, spleen, duodenum, proximal jejunum, terminal ileum, and ascending and transverse colon. The void in the upper abdomen was filled with an organ cluster graft consisting of the liver, pancreas, duodenum, and variable segments of proximal jejunum. Eight of the ten patients are alive after 3 to 9 months, all with good liver and pancreas function, and most with satisfactory function of the gastrointestinal tract. One of the surviving patients was in the hospital for 4 months because of multiple enteric fistulas and infections; the other seven survivors were discharged after an average of  $43 \pm 17.61$  (SD) days. Recurrent tumor has not been proved in any of the surviving recipients and is suspected in only one. The study of such cases should provide insight and guidelines applicable to other visceral transplantation procedures that may be attempted in the future.

**I**N THE DEVELOPMENT OF THE human fetus, the liver and pancreas begin as ventral and dorsal diverticula from that portion of the foregut that later becomes the duodenum<sup>1</sup> (Fig. 1A). The anatomic relationship of these organs becomes more complex with their differentiation and rotation, but their intimacy, including the sharing of the terminal hepatic and pancreatic duct drainage into the duodenum, is not lost. Thus it is not surprising that malignant tumors developing at or near the original duodenal outpouchings are notoriously refractory to treatment, even if these are localized to a single organ. Tumors that originate in one of the three organs and metastasize to the other(s) or to the transverse mesocolon or

*From the Departments of Surgery and Pathology,\* University Health Center of Pittsburgh, University of Pittsburgh, and the Veterans' Administration Medical Center, Pittsburgh, Pennsylvania*

colon have been considered to be categorically nonresectable.

During the last year, we have examined the premise that radical excision of most of the foregut (Fig. 1) could allow complete removal of certain hepatic duct cell, duodenal, gastric, and pancreatic malignancies that had already spread to the liver, as well as extirpation of primary liver tumors whose spread was downward. Ten patients with these seemingly untreatable conditions underwent removal of the liver, stomach, spleen, pancreas, duodenum, proximal jejunum, terminal ileum, and ascending and transverse colon (Fig. 1B). The void in the upper abdomen was filled with cadaveric organ cluster grafts that included the liver, pancreas, duodenum, and variable amounts of proximal jejunum.

## Methods

### *Case Material*

The patients were 27 to 46 years old with an equal distribution between sexes (Table 1). None of the patients had liver failure, although six were jaundiced (Table 1). All had some weight loss, which was severe in two patients. Severe portal hypertension was not present in any of the patients.

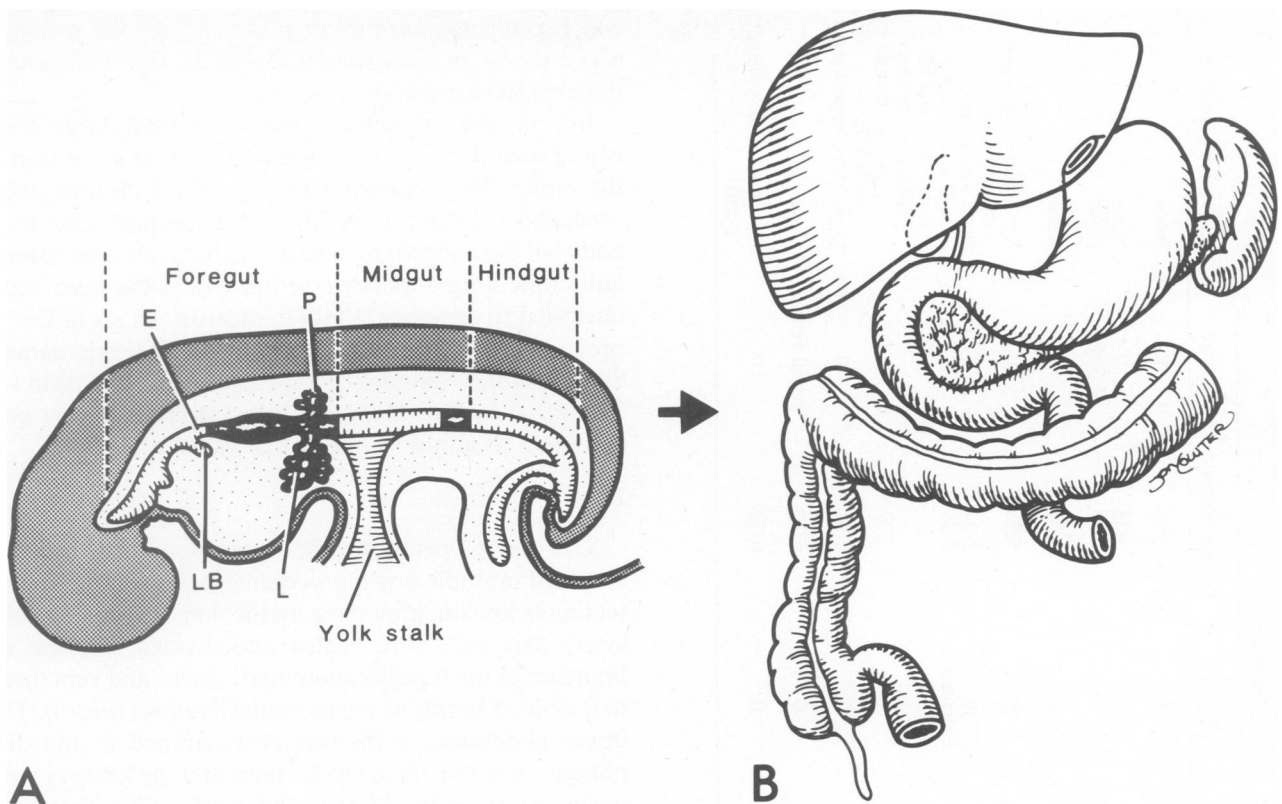
Five of the ten patients had not been previously operated on or instrumented, and only one had received chemotherapy (Table 2). Patient 7, a 29-year-old physician, had undergone resection of a superiorly located duct cell carcinoma (Klatskin tumor) with Roux-Y biliary reconstruction 2.5 years earlier. The tumor recurred with large

Presented at the 109th Annual Meeting of the American Surgical Association, Colorado Springs, Colorado, April 10-12, 1989.

Supported by research grants from the Veterans' Administration, and by Project Grant DK 29961 from the National Institutes of Health, Bethesda, Maryland.

Correspondence and reprint requests to: Thomas E. Starzl, M.D., Ph.D., Department of Surgery, 3601 Fifth Avenue, Falk Clinic, Pittsburgh, Pennsylvania 15213.

Accepted for publication: April 14, 1989.



FIGS. 1A AND B. (A) Delineation in embryonic life of that region of the gastrointestinal tract (dark shaded) that was resected in the organ cluster operation. E = esophagus, LB = lung bud, L = liver, and P = pancreas. (B) The adult organs deriving from the shaded primitive analage.

hepatic metastases, invasion of the Roux limb, obstruction of the bile duct, and liver abscess formation (Fig. 2 lower). The patient was moribund from uncontrolled sepsis at the time of the exceptionally difficult cluster operation. The problems of performing an organ cluster operation under these circumstances were illustrated when another patient (not included in this series) bled to death during preparation for a liver transplantation or possible cluster 7 years after right hepatic trisegmentectomy for a fibrolamellar hepatoma.

#### Tumor Pathology

Duct cell carcinomas were the most common (six examples); two of these were associated with sclerosing cholangitis (Table 2). There were two examples each of sarcomas and carcinoids. The liver was affected in all patients (Table 2, Figs. 2 to 5). The involvement of other tissues and organs is summarized in Table 2. One week after operation, patient 3 was found by CT scan to have multiple pulmonary lesions that probably predated transplantation. The patient refused a lung biopsy.

#### The Donors

Eleven donors who were 14 to 37 years old provided the organ clusters for the 10 recipients (Table 3). Six of

the 11 donors had minor liver function abnormalities. Special attention was paid to the glucose and amylase determinations. Two donors had significant hyperamylasemia (Table 3); all donors were hyperglycemic (Table 3). Patient 7, who has B blood type, was so ill that an O donor was accepted. Patient 6 was A blood type, but when his first graft of the same ABO type failed, retransplantation was carried out with an O donor. With these exceptions, all donors had the same blood type as the recipients. No attention was paid to HLA antigen matching,

TABLE 1. Recipient Patients

Number	Age/Sex/ Race	Preoperative Liver Function			Date of Operation
		Bilirubin	Albumin	Prothrombin Time	
1	27 M W	2.3	3.6	11.3	7/22/88
2	31 F W	0.6	3.8	12.9	7/28/88
3	35 F W	3.2	4.2	13.0	8/26/88
4	43 M W	0.6	3.6	10.7	9/17/88
5	37 F W	0.3	3.8	11.9	10/27/88
6	27 M W	0.3	1.9	13.9	11/23/88
					11/26/88
7	29 M W	9.3	2.9	14.0	11/25/88
8	30 M W	6.0	4.8	15.3	12/01/88
9	46 F W	14.0	3.1	13.2	1/01/89
10	40 F W	8.9	3.6	10.5	1/12/89

TABLE 2. Characteristics of Tumors

Case	Histopathology	Primary			Metastases				Previous Treatment
		Location	Size	Liver	Pancreas	Bowel	Lymph Nodes	Other	
1	Duct cell carcinomas, sclerosing cholangitis	Common duct	Diffuse	Minor	0	0	0/9	0	None
2	Spindle cell sarcoma	Duodenum	5 cm	Extensive	0	0	0/38	0	None
3	Duct cell carcinoma, sclerosing cholangitis	Hilum	9.5 cm	Extensive	0	0	12/50	Lungs*	None
4	Spindle cell sarcoma	Duodenum	8 cm	Extensive	0	0	0/57	0	None
5	Carcinoid	Duodenum (4th)	1.8 cm	Extensive	0	0	5/35	0	Adriamycin and tumor embolization
6	Carcinoid	Stomach (2nd)	3 cm	Extensive	0	0	2/27	0	Open liver biopsy
7	Duct cell carcinoma	Intra-hepatic	11 cm	Extensive	0	Extensive	0/28	0	Resection of Klatskin tumor right and left hepaticojejunostomy on 3/26/86 followed by 4500 RADS
8	Duct cell carcinoma	Liver hilum	7.5 cm	Regional	0	0	0/94	0	Exploratory laparotomy
9	Duct cell carcinoma	Common duct	10 cm	Extensive	Head, body	0	6/30	Portal vein	None
10	Duct cell carcinoma	Liver hilum	11.5 cm	Direct invasion	0	0	0/70	0	Percutaneous transhepatic stent

\* Diagnosed with CT scan 1 week postoperative, not proved histologically.

and the average number of matches with the recipient was only 1.1 of a possible 6 (Table 3). Cytotoxic cross-matches were negative.

In eight procurements in which the local donor team would permit it, 10 to 20 mgm OKT3 were given during the preliminary dissection as prophylaxis against graft-versus-host disease (GVHD). The antilymphocyte antibody has been shown to localize in graft lymphoid tissue,<sup>2</sup> and crude antilymphocyte serum (ALS) has been demonstrated to prevent GVHD in rodents.<sup>3</sup> In six of the 11 procurements, an intravenous bolus of 200 micrograms Sandozstatin<sup>R</sup> (Sandoz Pharmaceuticals, Division of Sandoz, Inc., East Hanover, NJ) was given during procurement to minimize the risk of pancreatitis.<sup>4</sup>

### Donor Operation

The donor operation (Fig. 6) was modified from the standard multiple organ procurement procedure.<sup>5</sup> In dissecting below the transverse mesocolon, the middle colic artery and vein were ligated and divided, as were all branches of the superior mesenteric artery and vein distal to the blood supply of the proximal jejunum (Fig. 6). The upper abdominal aorta was crossclamped at the diaphragm, and the organ cluster graft and the kidneys were cooled *in situ* with 1500 to 2000 mL of University of Wisconsin (UW) solution.<sup>6</sup> Cooling with aortic infusion quickly chills the splanchnic venous effluent as well.<sup>7</sup> As an extra precaution, the liver was further chilled by infusing 500 to 1000 mL UW solution through a superior mesenteric vein (Fig. 6, insert). A Carrell patch containing the origin of the celiac axis and superior mesenteric artery was removed with the specimen (Fig. 6). The specimen was immersed in UW solution, packed in an ice chest, and brought to Pittsburgh for further dissection and preparation of vascular cuffs for eventual anastomosis.

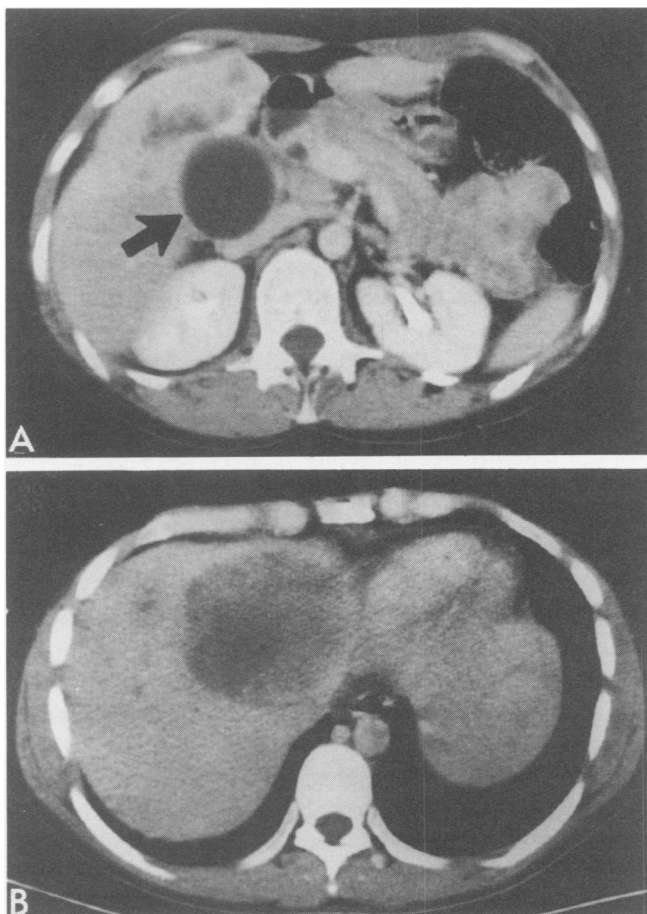
Six of the 11 donors also provided hearts, and all 11 provided kidneys. The hearts were not used in some cases because of cardiovascular instability and the need for pressors (Table 3). The mean preservation time was 11.1 ± 3 (SD) hours (Table 3).

### Recipient Operation

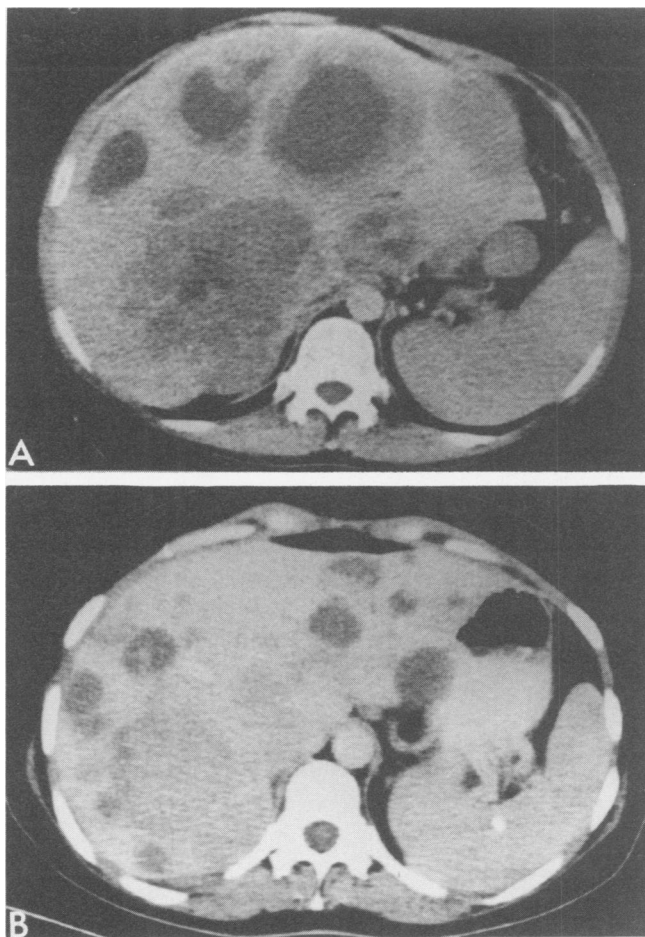
When time permitted, the intestinal tract of the recipient was purged with Golytely<sup>R</sup> solution (Braintree Laboratories, Braintree, MA) and a bowel prep was carried out with oral gentamycin, polymyxin E, and nystatin. A bilateral subcostal incision was made with upper and lower midline extensions. Dissection was begun below the transverse mesocolon by skeletonizing the superior mesenteric artery and vein. The iliocolic and middle colic artery and vein were ligated and divided, as were numerous pancreatic and duodenal branches of the superior mesenteric vessels. The bowel was transected at the terminal ileum, splenic flexure of colon, and jejunum beyond

the ligament of Treitz, taking care that there were good pulsations in the mesentery of the retained bowel. The transverse colon, spleen, and pancreas were mobilized toward the right, exposing the proximal portion of the superior mesenteric artery, which was further cleaned from the left lateral approach. The aorta was dissected free and the celiac axis was ligated at its origin in most cases, or more distally in two patients in whom the left gastric artery and proximal stomach were retained. In the other eight patients, the stomach was transected at the esophagogastric junction (Figs. 7 and 8) or just distal to this, leaving a small cuff of stomach that received its blood supply from above.

By completing the mobilization from left to right and by also mobilizing the ascending and transverse colon superiorly, the inferior vena cava was exposed and encircled above the entrance of the renal veins. Both on the left and right sides, the Gerota's fascia was taken with the



FIGS. 2A AND B. (A) CT scans of two patients with advanced duct cell carcinomas, biliary obstruction, and multiple parenchymal metastases. The pathologic condition of the tumor was highly unfavorable in patient 3 (see Table 2). Note the Courvoisier gallbladder (arrow). (B) Patient 7 had massive recurrence of a Klatskin tumor that had been resected 2.5 years before. This patient had liver abscesses and was dying of uncontrollable sepsis.



FIGS. 3A AND B. CT scan showing the massive liver metastases in (A) patient 4 and in (B) patient 5. The cell types were spindle cell sarcoma and carcinoid, respectively.

specimen or left behind as dictated by the location and degree of penetration of the tumor.

The excised specimen included the liver, nearly all of the stomach, spleen, pancreas, duodenum, proximal jejunum, terminal ileum, and ascending and transverse colon (Fig. 1B). The retrohepatic vena cava was removed with the specimen. The void in the upper abdomen was filled with a composite graft of the liver, pancreas, and duodenum, plus small segments of the proximal jejunum. The upper and lower vena caval anastomoses were performed first, followed in most cases by placement of the Carrell patch at the site of the recipient celiac axis (Fig. 7). Venous outflow for the intestines during removal of the specimen and performance of the first three vascular anastomoses was provided with a pump-driven veno-venous bypass that did not require heparinization (Fig. 7, insert).

After rearterializing the graft, the recipient's superior mesenteric artery was crossclamped to prevent acute venous hypertension, the catheter in the superior mesenteric

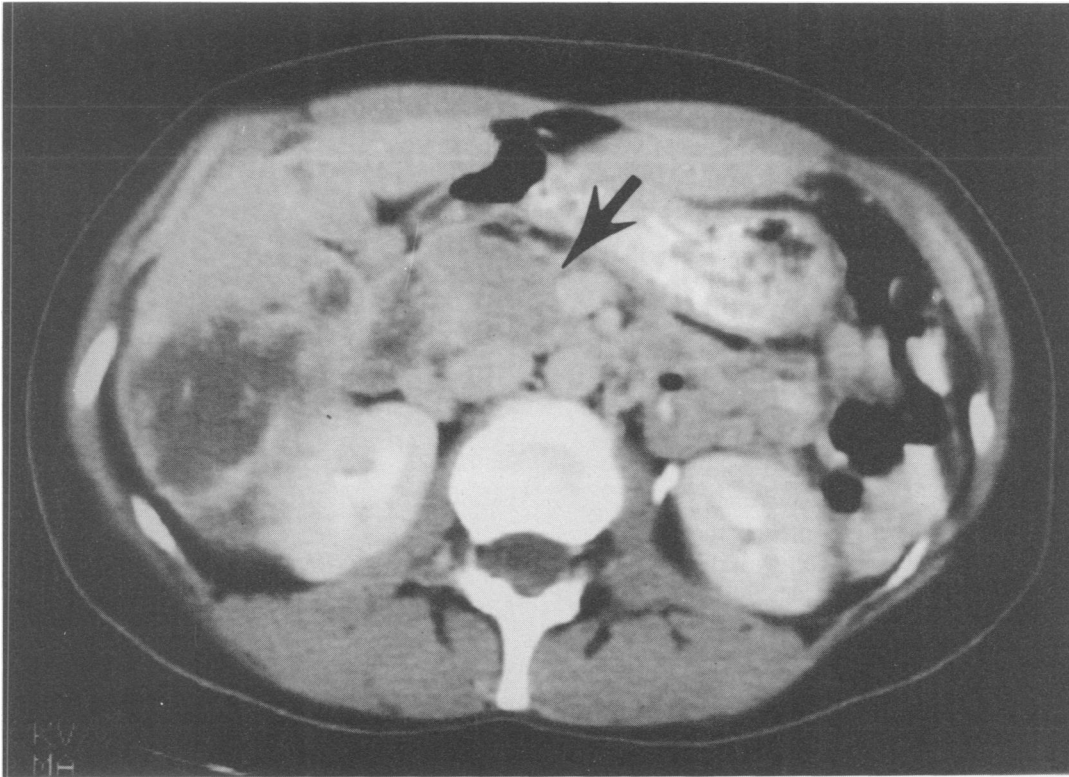


FIG. 4. CT scan of patient 9, who had a very extensive carcinoma of the common duct with liver invasion, and with direct invasion of the head and body of the pancreas (arrow). Multiple lymph node metastases can be seen.

vein was removed, and an end-to-end anastomosis was made of the donor and recipient superior mesenteric veins (Fig. 8).

Gastrointestinal reconstruction usually was performed as shown in Figure 8. After closing the duodenal stump, the end of the graft jejunum was anastomosed to the side of the host jejunum downstream from the jejunal anastomosis to the esophagus or gastric cuff. In Patient 5, whose proximal stomach was saved with an intact left gastric artery supply, the duodenum and proximal jejunum were placed in continuity with the gastrointestinal tract so that ingested food passed through the homograft intestine as soon as eating was resumed (Fig. 9). In this case the Carrel patch was attached to the recipient aorta in the infrarenal location (Fig. 9, right). Other gastrointestinal reconstructions, used one time each, are shown in Figure 10. The hand-in-glove technique (Fig. 10A) was made necessary in patient 1 when the duodenum of the organ cluster developed hemorrhagic necrosis and had to be completely removed.

Blood loss was  $16.8 \pm 9$  (SD) units (range, 6 to 27), the large losses reflecting coagulopathies that developed during removal of the huge specimen or shortly after revascularization of the organ cluster. In either circumstance, the dominant abnormality was fibrinolysis, which in some cases required treatment with epsilon amino caproic acid (EACA).

#### Postoperative Care

**Immunosuppression.** Baseline treatment was with cyclosporine and prednisone to which azathioprine was added when and if the white blood count was more than  $5000 \text{ mm}^3$  (Figs. 11 and 12). The drugs were started intravenously and switched to the oral route when feasible. All ten patients had a prophylactic 10-to-14 day course of OKT3 starting the day of or the day after operation.

**Adjuvant cancer therapy.** No other treatment than resection was given.

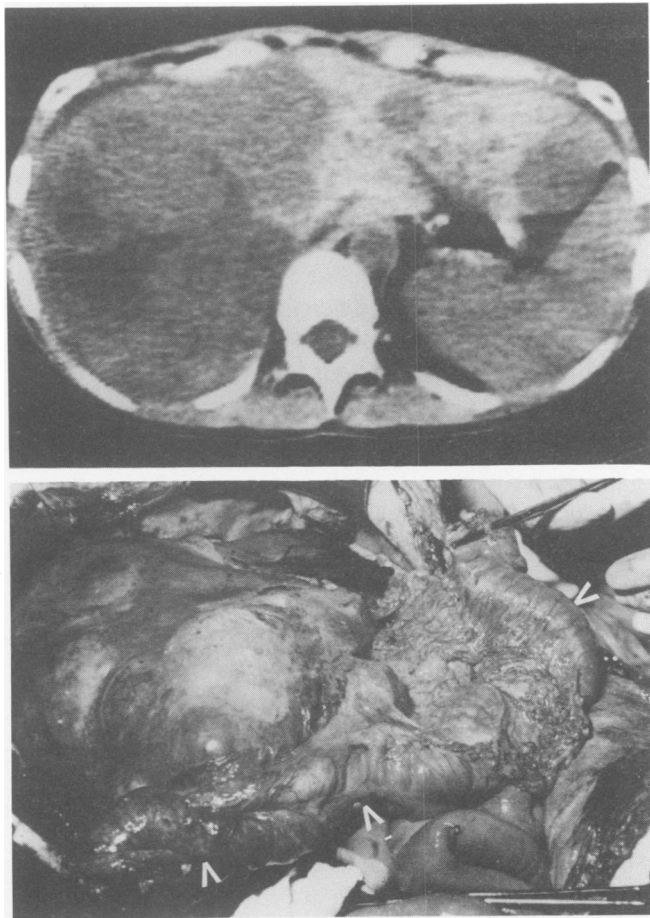
**Diet.** Eating was resumed when requested by the patient, and advanced quickly to multiple small feedings.

**Sandozstatin<sup>R</sup>.** All ten patients were treated during operation and for seven to 21 days afterwards with the synthetic somatostatin, Sandozstatin<sup>R</sup>, which has been shown to minimize experimentally caused pancreatitis.<sup>4</sup> Intravenous doses were 150 micrograms every eight hours. Because Sandozstatin<sup>R</sup> reduces the absorption of enteral cyclosporine,<sup>8,9</sup> unusual reliance was placed on monitoring cyclosporine blood levels, and on intravenous supplementation of the cyclosporine, when indicated.

#### Results

##### Mortality

Two patients died after nine and 112 days. In patient 1, hemorrhagic necrosis of the complete duodenum ne-



FIGS. 5A AND B. (A) The CT scan of patient 2 whose upper abdomen was filled with spindle cell sarcoma at the time of operation. (B) The tumor-laden liver is the structure to the left of the operating room photograph. Most of the right diaphragm was removed with the specimen. The transverse colon is marked with white arrows. The margins were free of tumor, and none of the 38 lymph nodes studied had metastases.

cessitated biliary and pancreatic reconstruction with a hand-in-glove jejunal anastomosis over the bare head of the pancreas (Fig. 10A). This anastomosis leaked and the fistula could never be closed until death 112 days after transplantation from multiple infections, including a cerebral infarction that we believe was caused by a fungus. Autopsy was denied.

Patient 6 had primary nonfunction of the liver and severe graft pancreatitis, necessitating retransplantation three days after the first operation. The cluster graft was necrotic. Sheets of *Candida albicans* were already present in the abdomen by the time of retransplantation. The patient developed multiple brain infarcts within a few days, and he died nine days after transplantation. There were findings of systemic candidiasis and multiple organ failure at autopsy, including extensive ischemic damage to the organ cluster graft.

TABLE 3. Features of 11 Donors for Ten Recipient Patients

Characteristics	Number
Age (range, 14 to 37 years)	23.1 ± 8.7 years (SD)
Race	
White	11
Sex	
Male	6
Female	5
Cause of donor death	
Trauma	7
Nontraumatic	4
Pressor support	6
Amylase > 100 IU	2
SGPT > 50 IU (127 ± 54, range 62 to 200)	6
Blood sugar (range, 161 to 300)	216 ± 53 (SD)
Total ischemia (range, 6 to 15.8 hours)	11.1 ± 3 hours (SD)
HLA matches (range, 0 to 3)	1.1 (SD)

\* All 11 donors gave kidneys; six gave hearts. The other hearts were not used because of donor instability or lack of need.

SGPT, serum glutamic-pyruvic transaminase (serum alanine aminotransferase).

### Survival

Eight of the ten patients are alive from 3 to almost 9 months after transplantation (Table 4). Patient 7 required

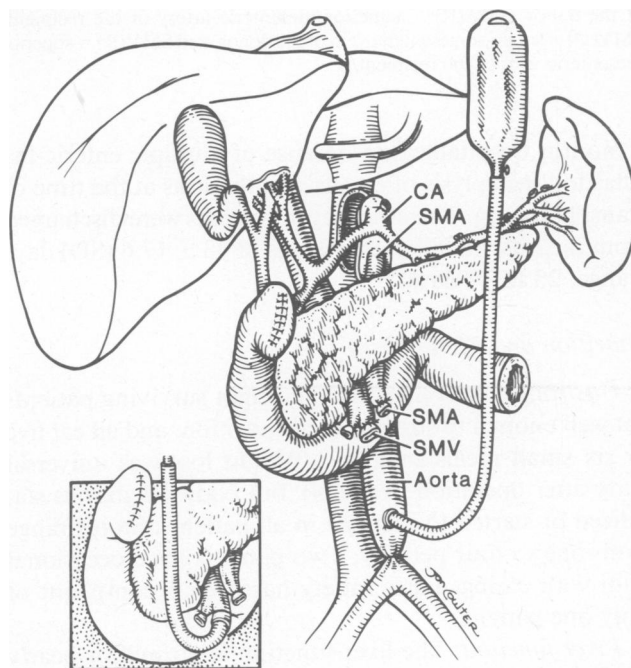


FIG. 6. Removal of organ cluster graft from donor. The specimen is initially cooled with an aortic infusion of UW solution after crossclamping the proximal abdominal aorta. Once the specimen has been removed with a Carrel patch containing the origin of the celiac axis and superior mesenteric artery (SMA), the liver is secondarily perfused on the back table with UW solution (insert) through the superior mesenteric vein (SMV).

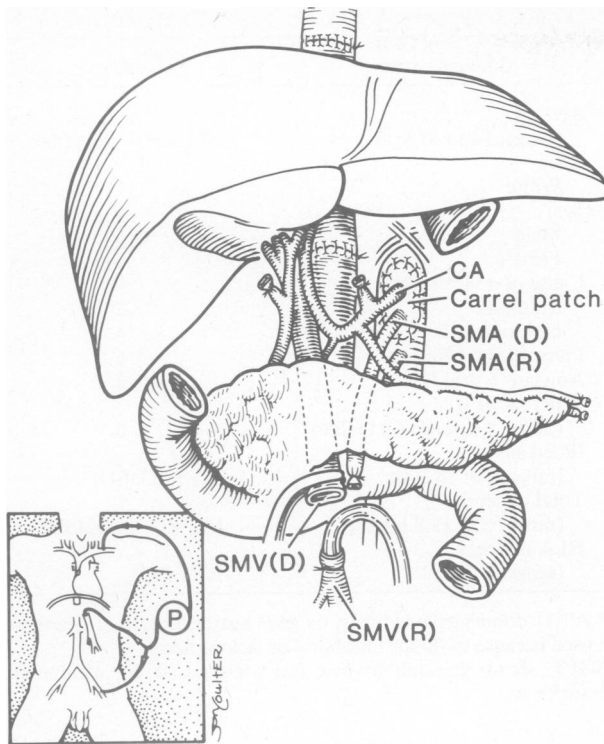


FIG. 7. Appearance of the recipient operation after removal of the host organs under veno-venous bypass (insert), insertion of the cluster graft, completion of the vena caval anastomoses above and below the liver, and anastomosis of the Carrel patch to the aorta at the natural location of the celiac axis. CA = celiac axis, SMA(D) = superior mesenteric artery of the donor, SMA(R) = superior mesenteric artery of the recipient, SMV(D) = superior mesenteric vein of the donor, and SMV(R) = superior mesenteric vein of the recipient.

4 months hospitalization because of multiple enteric fistulas following lysis of extensive adhesions at the time of transplantation. The other seven patients were discharged from the hospital after an average of  $43 \pm 17.6$  (SD) days (range, 23 to 74 days).

#### Nutrition and Metabolism

**Gastrointestinal function.** The eight surviving patients eat well enough to support their nutrition, and all eat five or six small meals each day. Weight loss was universal early after operation (Table 4), but body weight has stabilized or started to increase in all patients. Stools range from one to four per day. Two patients have occasional pain with eating. Early satiety has been a complaint of only one patient.

**Liver function.** The liver function is normal or nearly normal in the eight surviving patients (Table 4).

**Pancreas.** None of the surviving patients have required insulin at any time. All patients had perioperative hyperamylasemia, and the first graft of patient 6 had pancreatic necrosis. A pancreatic fistula caused the death of patient 1. Two of the eight surviving patients had significant

complications of pancreatitis. Patient 4 had a pancreatic fistula that was drained with a pigtail catheter with resolution in 1 week. The pancreas in patient 7 required several operative debridements. Pancreatic enzyme supplementation is not being provided for any patient.

**Cyclosporine absorption.** The oral dose of cyclosporine for the eight surviving patients after 3 to 9 months is  $700 \pm 470$  (SD) mg per day (range, 350 to 1800 mg) to maintain a 12-hour trough level of 500 to 1000 ng/mL. This average dose is not much different than that which is given to the average liver transplant recipient who has been followed for comparable periods.

#### Tissue Studies

Postoperative liver biopsies were obtained from the ten patients. Mild rejection was present in five patients during the first few weeks. After its successful treatment, cytomegalovirus (CMV) infection was strongly suspected or confirmed in these same recipients. Compared to the liver, which is transplanted alone,<sup>10</sup> these hepatic grafts had an unusual number of eosinophiles and neutrophils in the

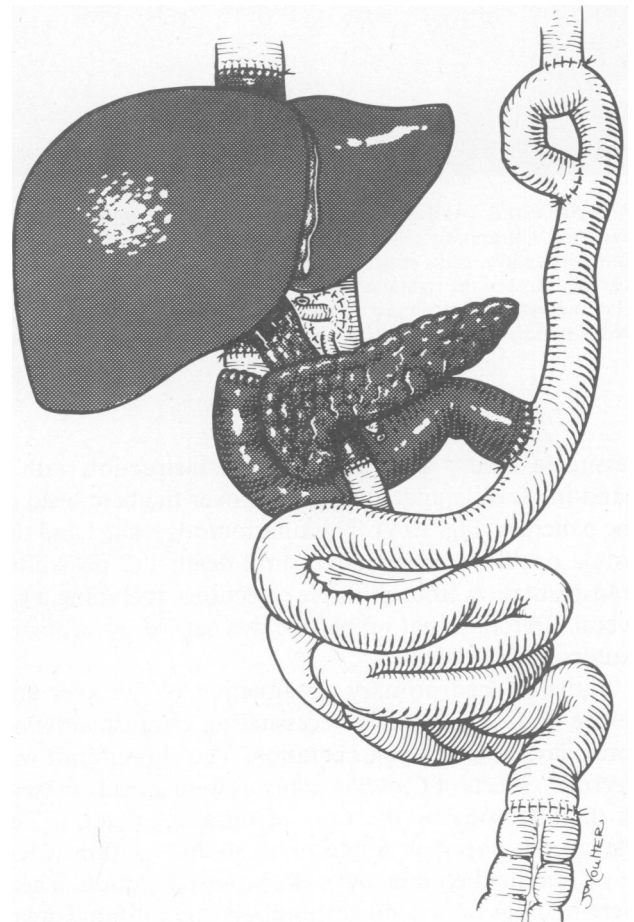
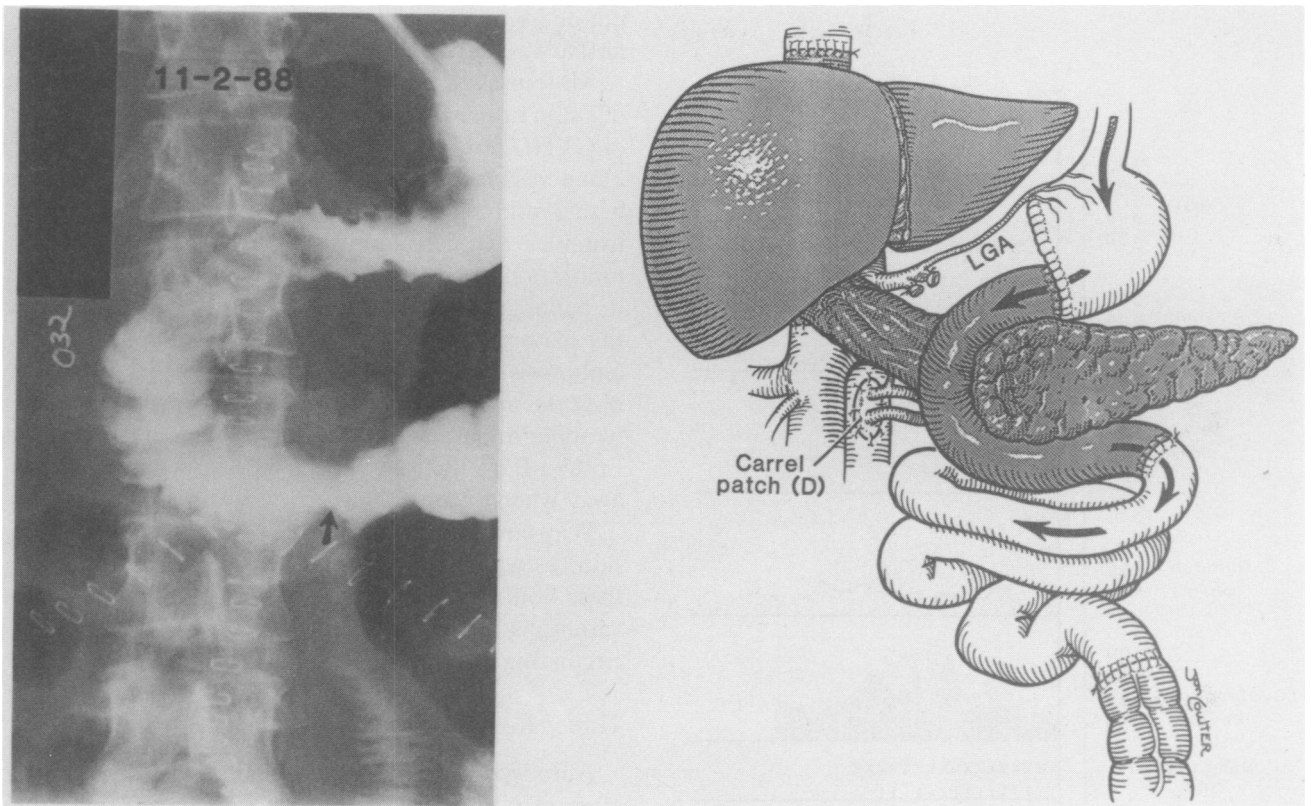


FIG. 8. Completed superior mesenteric vein reconstruction and usual gastrointestinal reconstruction.

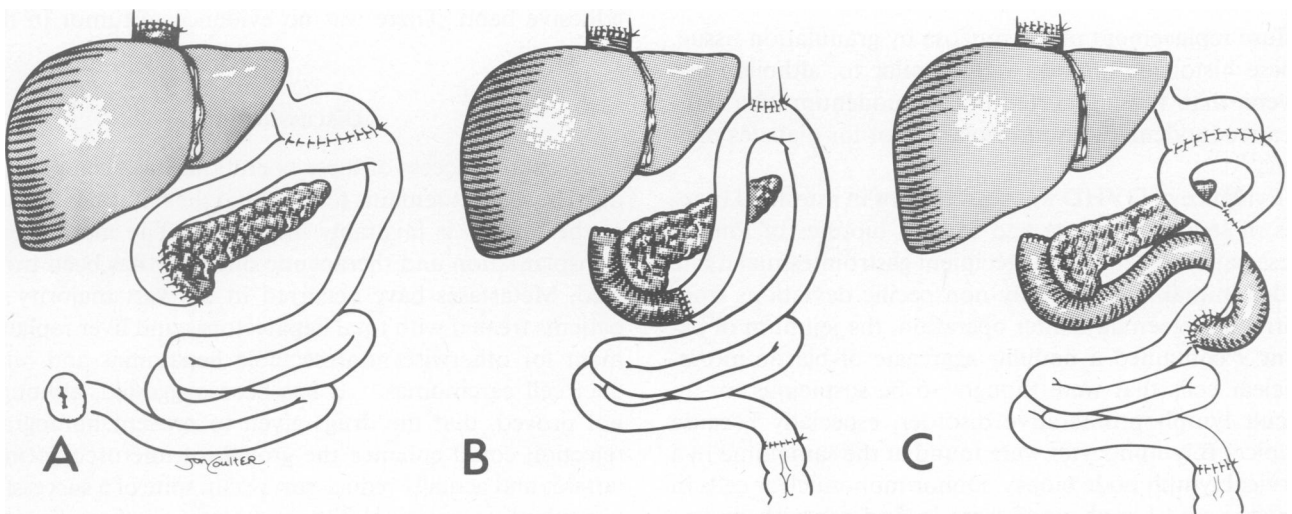


FIGS. 9A AND B. (A) Gastrointestinal series obtained in patient 5, six days after operation, showing homograft duodenum and jejunum in continuity with the patient's own stomach and jejunum. (B) Technique used. To preserve the recipient celiac axis and left gastric artery, it was necessary to place the donor Carrel patch below the left renal vein and the recipient superior mesenteric artery.

portal tracts and in the sinusoids. Kupffer cell hypertrophy and/or pigmentation also was common. Two pancreas biopsies had no signs of rejection.

The transplanted duodenum of patient 5 was biopsied through an endoscope 3 weeks after operation, ten days

after obtaining the gastrointestinal series shown in Figure 9. Although cellular rejection was diagnosed, immunosuppression was not increased because liver function was stable (Fig. 11). Two months later, another biopsy at a time when the patient had no eating difficulties showed



FIGS. 10A-C. Alternative methods of reconstruction used for (A) patient 1, (B) patient 2, and (C) patient 3.



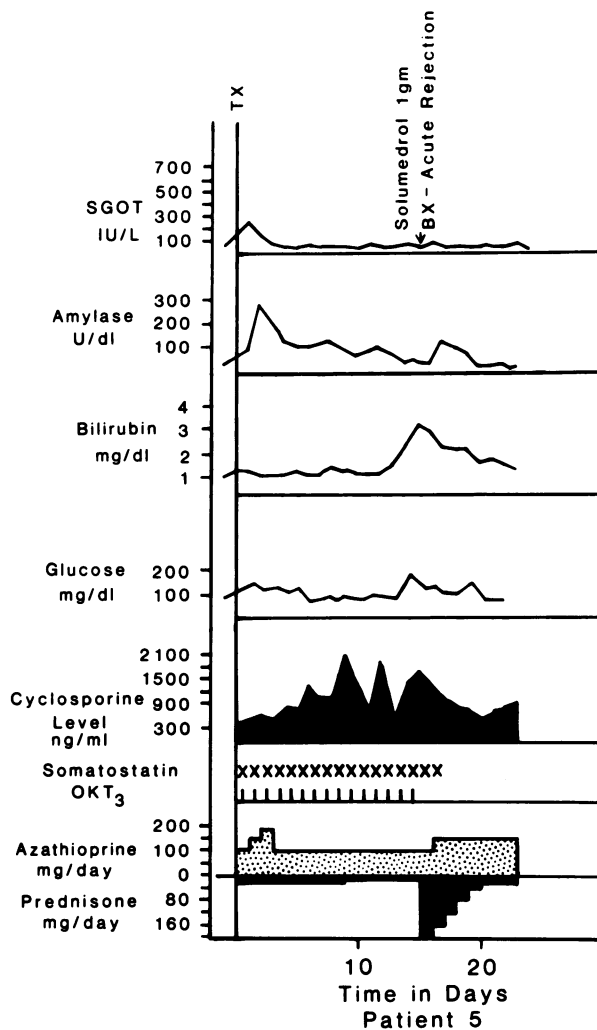


FIG. 11. The course of patient 5 (see also Figs. 3 and 9) who was treated with cyclosporine, prednisone, azathioprine, and OKT3. She was discharged from the hospital in 3.5 weeks. Bx = biopsy, Tx = transplantation.

diffuse replacement of the mucosa by granulation tissue. These histologic findings were similar to, although less severe, than those reported in the duodenum after pancreaticoduodenal homotransplantation for diabetes mellitus.<sup>11</sup>

Evidence of GVHD was searched for in intestinal biopsies of seven recipients and in skin biopsies of four of these patients. Most of the recipient gastrointestinal tissue had minimal and generally nonspecific deviations from normal. Sixteen days after operation, the jejunum of patient 9 contained a nodular aggregate of blastic mononuclear cells that were thought to be suspicious for an occult lymphoproliferative disorder, especially because atypical B lymphocytes were found at the same time in a cervical lymph node biopsy. Donor mononuclear cells in the skin and lymph node were looked for with donor-specific anti-HLA monoclonal antibodies, but these could

not be found. Two months later a mild eosinophilic infiltrate was the only abnormality in a repeat jejunal biopsy.

All four skin biopsies, which were performed because of a skin rash, had similar features that were not diagnostic of GVHD but which did not rule out this diagnosis. The blood vessels of the superficial dermis were surrounded with a mild inflammatory infiltrate of lymphocytes, neutrophils, and eosinophiles. There was mild lymphocyte infiltration into the overlying epidermis and hair follicles in patient 9 with increased epithelial mitoses. However the features diagnostic of GVHD, acidophilic necrosis (apoptosis) and the surrounding of epithelial cells by lymphocytes (satellitosis), were not prominent findings. A lymphoproliferative skin lesion in patient 1, which was Epstein-Barr nuclear antigen (EBNA) positive, melted away when immunosuppression was lightened.

Why eosinophiles were present in host (intestines and skin) as well as graft (liver) biopsies was not clear, but these could have been due to drug reactions, unusual variations of rejection or GVHD, or manifestations of circulating antigens or lymphokines.

#### Tumor Recurrence

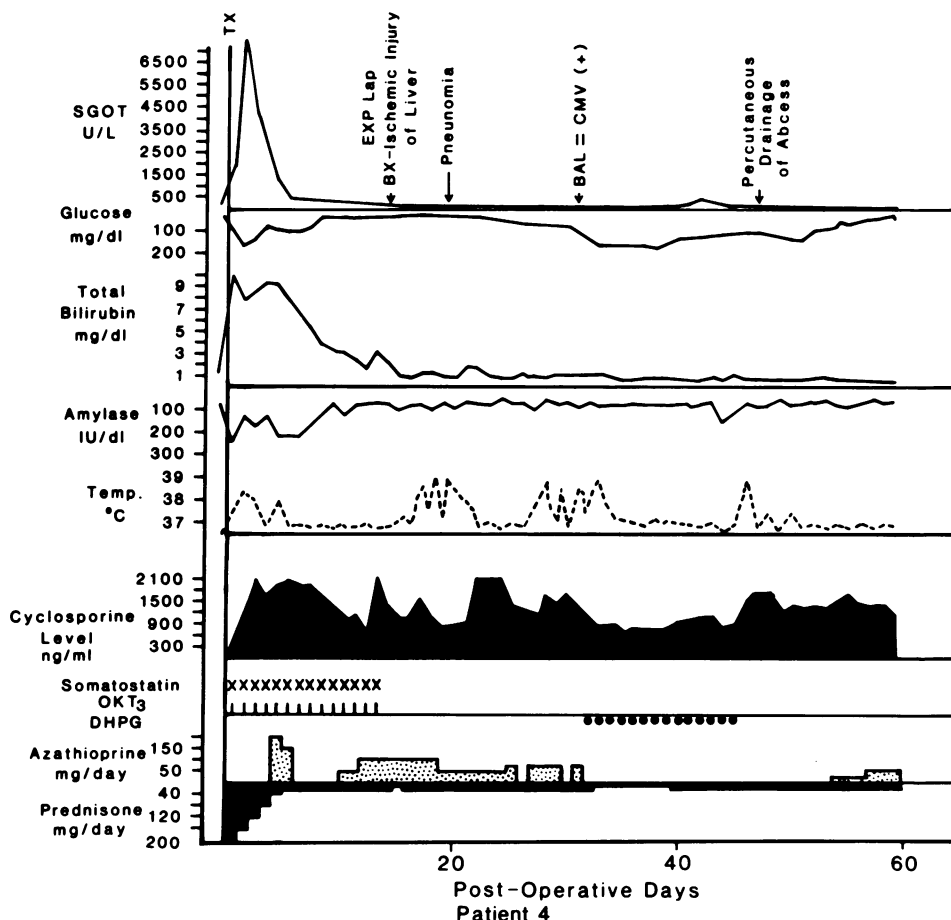
Autopsy was denied for patient 1, who died 112 days after operation, making it impossible to rule out residual tumor. In patient 6, who died after nine days, no tumor was found at autopsy.

None of the eight patients who are living have proved recurrent tumor after 3 to almost 9 months. However patient 3 had a CT scan of the chest eight days after operation that showed multiple pulmonary nodules that were thought to be metastases that predated transplantation. However these have not changed in the ensuing 7 months and they may have been pulmonary emboli from the veno-venous bypass. This patient recently underwent an exploratory laparotomy for intestinal obstruction from an adhesive band. There was no evidence of tumor in the abdomen.

#### Discussion

The early success of these operations has been gratifying. However it remains to be seen if the natural behavior of the tumors is favorably influenced. The marriage of transplantation and therapeutic oncology has been troubled. Metastases have occurred in the vast majority of patients treated with total hepatectomy and liver replacement for otherwise nonresectable hepatomas and hilar duct cell carcinomas.<sup>12</sup> It has been suggested, although not proved, that the drugs given to prevent homograft rejection could enhance the growth of microscopic metastases and actually reduce survival in spite of a successful transplant operation.<sup>13</sup> The metastases in these hepatic recipients began to appear within 3 months, after homing

FIG. 12. The course of patient 4, whose organ cluster graft sustained a very severe ischemic injury as reflected in the high SGOT. The same general immunosuppression was used as in Figure 11. The febrile episodes were attributable to cytomegalovirus (CMV) infection of the recipient intestinal tract, as well as of the cluster graft. Bx = biopsy, BAL = bronchoalveolar lavage.



to the new liver<sup>12,13</sup> and contributing steadily to the mortality at all times from 3 months onward.<sup>12-14</sup> Because our eight surviving patients are free of detectable metastases after 3 to 9 months, the next few months will be crucial for establishing tumor prognosis.

Freedom from metastases in these patients can not be explained solely by the selection of candidates who had slow-growing tumors with favorable patterns of spread. Six of the ten patients had duct cell carcinomas. These lesions have had a dismal prognosis after liver transplan-

TABLE 4. Liver, Pancreas, and Gastrointestinal Function

Patient	Latest Postop. Liver Function		Protime (sec)	Insulin or Enzyme Replacement	Weight			Early Satiety	Pain with Eating	Stools/day	Follow-up (days)
	Bilirubin (mg %)	Albumin (gm %)			Preop	Lowest	Now				
1	2.2	3.5	15	—	148	—	—	—	—	—	112 died
2	0.8	3.8	11.2	0	108	95	101	no	only with big meals	1*	258 alive
3	0.8	4.0	13.1	0	127	93.5	93.5	no	no	1-2*	231 alive
4	0.2	3.5	11.8	0	140	112	117	no	no	2	207 alive
5	0.7	3.6	12.7	0	159	137	137	occasionally	no	3-4*	168 alive
6	16.0	3.3	13.8	—	168	—	—	—	—	—	9 died
7	1.3	3.5	13.0	0	141	110	112	no	no	2-3*	139 alive
8	0.4	4.0	11.8	0	140	95	108	yes	no	3*	133 alive
9	1.2	3.3	12.2	0	93	78	80	no	no	2*	101 alive
10	0.5	4.0	12.0	0	168	140	140	occasionally	occasionally	3*	90 alive

\* Treatment for diarrhea with diphenoxylate HCL (patients 2, 3, 5, and 9), ioperamide HCL (patients 7, 10), and propantheline bromide (patient 8).

tation alone, even when they were far smaller and less advanced than those of the present series.<sup>12</sup> The biologic behavior of sarcomas and carcinoids tumors may be somewhat less aggressive,<sup>15</sup> but these tumors were multifocal and extensive in our patients. If tumor control has been achieved, it will support the logic of foregut resection. Further experience will be required, then, to determine which of the foregut tumors might be appropriate for this kind of treatment. Neoplasms such as pancreatic acinar adenocarcinoma, for which present treatment is usually futile, even without hepatic metastases,<sup>15</sup> could be on the list of possibilities.

The idea of such radical treatment was beyond comprehension before the availability of transplantation made replacement of excised vital organs possible. The liver and pancreas combination is a natural unit. The subtle metabolic and hormonal interplay between the liver and pancreas is so important and wide ranging that virtually no aspect of liver structure, function, or the capacity for regeneration can be understood without considering the moderating role of the pancreas.<sup>16,17</sup> Nevertheless there is an option of doing the same extensive resection with transplantation of the liver alone, and we have done this in one patient who was too sick to wait for a cluster donor and for whom a liver became available. The penalty of using the liver alone is the creation of diabetes mellitus, but on the positive side, the considerable morbidity and mortality associated with the transplanted pancreas can be avoided.

In addition to its specific potential use, the organ cluster operation can be a pathfinder for other visceral transplantation procedures, possibly including the so-called multivisceral transplantations that differ from the organ cluster operation in that the stomach is included at the upper end of the graft and the rest of the small intestine and colon is included at the lower end. All of the multivisceral recipients who survived their operations to date died later when they developed the lymphomas (lymphoproliferative disorders)<sup>2,18</sup> that are associated with Epstein-Barr virus infections.<sup>19,20</sup> Lymphomas were not seen in any of the ten cluster recipients, with the possible exception of patient 1. Duodenum and segments of jejunum have not caused problems in the surviving patients, and in one organ cluster recipient, who is alive 5.20 months after operation, all oral intake passes through a duodenojejunal segment before reaching the native small bowel. However this homograft small bowel has been seriously damaged by rejection, more so than the liver or pancreas in the cluster. The preferential susceptibility of the small bowel to rejection has been described before in pancreaticoduodenojejunal grafts.<sup>11</sup> Thus practical exploitation of intestinal homotransplantation beyond short segments such as those in cluster grafts will require better immunosuppression. We are deferring attempts to transplant larger grafts of hollow viscera until that time.

When any large organ complex that contains lymphoid tissue is engrafted, lethal GVHD can be produced, as was recognized long ago after multivisceral grafts in dogs<sup>21</sup> and studied decisively by Monchik and Russell in F1 hybrid rats undergoing intestinal transplantation.<sup>22</sup> Avoidance of GVHD has prompted us to deplete the lymphoid tissue of the grafts by giving OKT3 to multivisceral<sup>2</sup> or organ cluster donors. Shaffer et al.<sup>3</sup> have proved the efficacy of this approach in rats using antilymphocyte serum. A special kind of GVHD can be produced when a donor and recipient are of different, although compatible, ABO blood types (O donor to B recipient, for example).<sup>23</sup> Then the lymphoid tissue can produce isoagglutinins that hemolyze the recipient's red blood cells. Patient 7 in our organ cluster series who was B blood type received an O organ and survived despite a series of catastrophic surgical complications. The ability to control his humoral GVHD was encouraging, as was the absence of manifestations of classical GVHD in any of the other recipients.

#### Acknowledgment

The authors wish to thank Terry Mangan for planning, research editing, and typing of this and other complex manuscripts.

#### References

1. Arey LB. Developmental anatomy. 7th Ed., Philadelphia: W.B. Saunders, 1974.
2. Starzl TE, Rowe MI, Todo S, et al. Transplantation of multiple abdominal viscera. *JAMA* 1989; 261:1449-1457.
3. Shaffer D, Maki T, DeMichele SJ, et al. Studies in small bowel transplantation: prevention of graft versus host disease with preservation of allograft function by donor pretreatment with antilymphocyte serum. *Transplantation* 1988; 45:262-269.
4. Liu T, Sutherland DER, Chinn PL, Najarian JS. Effect of a cyclic hexapeptide analog (L363, 586) of somatostatin on the function of pancreas grafts in dogs. *J Surg Res* 1985; 39:39-45.
5. Starzl TE, Miller C, Broznick B, Makowka L. An improved technique for multiple organ harvesting. *Surg Gynecol Obstet* 1987; 165:343-348.
6. Jamieson NV, Sundberg R, Lindell S, et al. Successful 24-30-hour preservation of the canine liver: a preliminary report. *Transplant Proc* 1988; 20(Suppl.1):945-947.
7. Starzl TE, Iwatsuki S, Shaw BW, Jr, Gordon RD. Orthotopic liver transplantation in 1984. *Transplant Proc* 1985; 17:250-258.
8. Landgraf R, Landgraf-Leurs MMC, Nusser J, et al. Effect of somatostatin analogue (SMS 201-995) on cyclosporine levels. *Transplantation* 1987; 43:724-725.
9. Rosenberg L, Dafoe DC, Schwartz R, et al. Administration of somatostatin analog (SMS 201-995) in the treatment of a fistula occurring after pancreas transplantation. *Transplantation* 1987; 43:764-766.
10. Demetris AJ, Jaffe R, Starzl TE. A review of adult and pediatric post-transplant liver pathology. *Pathol Ann* 1987; II:347-386.
11. Starzl TE, Iwatsuki S, Shaw BW, Jr, et al. Pancreaticoduodenal transplantation in humans. *Surg Gynecol Obstet* 1984; 159:265-272.
12. Iwatsuki S, Gordon RD, Shaw BW, Starzl TE. Role of liver transplantation in cancer therapy. *Ann Surg* 1985; 202:401-407.
13. Starzl TE (with the assistance of C.W. Putnam). Experience in Hepatic Transplantation. Philadelphia: W.B. Saunders, 1969. pp. 369-373.
14. Starzl TE, Demetris AJ, Van Thiel D. Medical progress: liver transplantation. *New Eng J Med* (in press).

15. Michelassi F, Erroi F, Dawson PJ, et al. Periampullary tumors: experience with 647 consecutive patients. *Ann Surg* 1989; 210:544-556.
16. Starzl TE, Porter KA, Francavilla A. The Eck fistula in animals and humans. *Curr Probl Surg* 1983; 20:687-752.
17. Starzl TE and Terblanche J. Hepatotrophic substances. In Popper H, Schaffner F, eds. *Progress in Liver Diseases*, Vol. 6. New York: Grune and Stratton, 1979. pp. 135-152.
18. Williams JW, Sankary HN, Foster PF, et al. Splanchnic transplantation. An approach to the infant dependent on parenteral nutrition who develops irreversible liver disease. *JAMA* 1989; 261:1458-1462.
19. Hanto DW, Gajl-Peczalska KJ, Frizzera G, et al. Epstein-Barr virus (EBV) induced polyclonal and monoclonal B-cell lymphoproliferative disease occurring after renal transplantation. *Ann Surg* 1983; 198:356-369.
20. Starzl TE, Porter KA, Iwatsuki S, et al. Reversibility of lymphomas and lymphoproliferative lesions developing under cyclosporine-steroid therapy. *Lancet* 1984; 1:583-587.
21. Starzl TE, Kaupp HA, Jr, Brock DR, et al. Homotransplantation of multiple visceral organs. *Am J Surg* 1962; 103:219-229.
22. Monchik GJ, Russell PS. Transplantation of the small bowel in the rat: technical and immunologic considerations. *Surgery* 1971; 70:693-702.
23. Ramsey G, Nusbacher J, Starzl TE, Lindsay GD. Isohemagglutinins of graft origin after ABO-unmatched liver transplantation. *New Engl J Med* 1984; 311:1167-1170.

#### DISCUSSION

DR. FRANCIS D. MOORE (Boston, Massachusetts): Tom Starzl is one of the great innovators in transplant science of the world. This is one of the major new surgical fields of this century, previously only a dream. It was first reported to this society by Dr. Joseph Murray 32 years ago in 1957. It is a field of science and surgery to which many fellows of this society (many of them here this morning, including our distinguished President) have contributed in a very major way. This new field of surgery has had a world-wide impact that we scarcely can believe.

Tom, you recently reported a procedure like this, but including the colon, in two young patients with nonmalignant disease (as you just mentioned), both of whom died.

My first question is: what was the time relationship of those two experiences to this new series? There are ten cases here, operated sometimes at the rate of one or two a month in 1988, I believe. Is this series still expanding? You have suggested in your paper that it is, and if so, at about what rate?

One of those other patients with the nonmalignant disease, as you described in the literature, died after almost 1 year of survival, of a T-cell lymphoma associated with the Epstein-Barr virus (EBV).

My second question is: how was this EBV lymphoma obviated in this series? Was it by avoidance of transplantation of the terminal ileum and the ileal lymph nodes, by a different choice of immunosuppressive drugs, or was it just a matter of the age of the patients? As you have so clearly indicated, these are operations for cancer, sometimes cancer in the liver. Clearly we cannot judge whether the game is worth the candle until many more moons have set.

My third question, therefore, is what is the record of liver transplantation in hepatic malignancy? Can we expect anything better here? Certainly surgery has learned the hard way in the last 50 years that heroic technical extension of anatomic extirpation of malignant tumors rarely succeeds when lymph nodes are already involved.

Do you think that will be limiting here, or were many of these really primary local tumors and not all of them with lymph node involvement, as your slides suggest?

The removal of multiple organs for cancer is not new. Look at Alex Brunschweig and his pelvic clean-out operations, now a half century ago. Look at radical neck dissections, radical pancreatectomy, radical nephrectomies, and radical pneumonectomies. Replacement of multiple organs by transplantation is not new either. Yesterday President Najarian told us about pancreas and liver grafts, pancreas and kidney grafts. But this upper abdominal clean-out (which might be thought of as the general surgeon's daydream, or possibly nightmare) is new. It is most remarkably interesting, especially because, as shown by those other two cases, that done in this manner small bowel transplantation works and provides an absorptive nutritional surface despite its potential for GVH reactions and possibly EBV lymphoma.

Fourth, a sort of social or philosophical question that every fellow of this society must have on his or her mind: who should do this operation?

Dr. Starzl, you have remarkable "field strength" here, a team, a donor-hospital network, vast experience in every detail, and can show us this amazing series with eight survivors at 6 to 9 months. We know that others will not easily or quickly match this record. The skill factor in surgery is the great unmeasurable and unpredictable factor in outcome, and may be unteachable. Our President suggested that perhaps it is teachable. Sometimes I wonder. Like virtuosity in performance of a Bee-

thoven concerto, such surgical skill is partly inborn, partly a result of immense self-discipline and determination: instructable, yes, but certainly not teachable to your average raw recruit.

So my last question is: are we correct in addressing caution to the surgical world as these procedures are reported publicly and openly, an openness so much a part of the Starzl tradition? Are we right in saying to the surgical world, "hold off and wait a bit"?

DR. JOHN S. NAJARIAN (Minneapolis, Minnesota): I would just like to add another word to what Frannie has so eloquently stated. The history of extended radical extirpative procedures has been fraught with problems. The major problem has usually been recurrence of tumor. Just performing a liver transplant alone, we know that tumor recurrence is quite common with hepatomas. We were hoping that the Klatskin tumor, cholangiocarcinoma of the bile ducts at their bifurcation, was perhaps the most favorable of all primary liver tumors. Yet after transplanting a liver into three of these patients, with no lymph node metastasis found, within 12 to 18 months all three patients had recurrence of their disease and eventually succumbed.

I just would like to ask Dr. Starzl whether looking at this series at 6 and 9 months is like looking at the fellow who has jumped out of the window of a tall building; as he is falling down, somebody asks, "How are things going?" and he replies "Not bad so far." Are we going to see recurrence in these patients within 1 year, or perhaps 2 years? Is it now time to stop and perhaps wait to see if a similar fate with early recurrence will occur?

DR. THOMAS E. STARZL (Closing discussion): First let me say how touched and encouraged I was today by the remarks of Dr. Moore, just as I was almost 25 years ago at the meeting of the American Surgical Association when we presented our first paper to this group on the subject of liver transplantation (*Ann Surg* 1964; 160:411-438).

In responding to Dr. Moore, if I could, I would like to say something that goes back to yesterday when we heard how liver transplantation can, and really has, influenced the use of older operations such as the Kasai procedure or the Warren shunt. Bickering over these magnificent papers, which were given by Lilly and Henderson, would obscure the important point, as both of those authors yesterday emphasized, that liver transplantation has radically changed, and I believe forever, the way that any lethal liver disease will be treated.

This is what Frannie Moore and I really hoped for, or perhaps dreamed of, almost 31 years ago this coming June and July, when we first worked on this operation in our laboratories in Boston and Chicago unbeknownst to each other. So you can imagine my gratification at hearing these discussions yesterday, and also my warm feeling in listening again, as I did so long ago, to what Dr. Moore said. Today we are looking at the same general question of what the role will be of this larger operation that essentially is an extended liver transplantation for a different indication, namely, the treatment of cancer. As Dr. Najarian has pointed out, we have a somewhat more clouded crystal ball about the potential of this approach and of course, it is not surprising to any of us that Dr. Moore has asked all of the critical questions.

The problem with the Epstein-Barr virus lymphomas that we saw with our multivisceral transplantations (*JAMA* 1989; 26:1449-1457) has