

---

# Radiolabeled Antibody Imaging in the Management of Colorectal Cancer

## *Results of a Multicenter Clinical Study*

---

RALPH J. DOERR, M.D.,\* HANI ABDEL-NABI, M.D.,† DAVID KRAG, M.D.,‡ and EDITH MITCHELL, M.D.§

---

Presurgical colorectal cancer patients (n = 116) received single intravenous infusions of 1 mg of CYT-103 (OncoScint® CR103), an immunoconjugate of monoclonal antibody B72.3, radiolabeled with <sup>111</sup>In. Following gamma camera imaging, 103 patients underwent an operative procedure: 92 had primary or recurrent colorectal carcinoma, 1 patient evaluated for recurrence of colorectal cancer had a second primary malignancy (small cell lung), and 10 patients had no demonstrable evidence of malignancy. <sup>111</sup>In-CYT-103 immunoscintigraphic findings were consistent with the pathologic diagnoses for 70% of patients with colorectal cancer and 90% of disease-free patients. Antibody imaging contributed to surgical decision making through the detection of occult disease (12% of patients) and the confirmation of localized, potentially resectable disease without regional or metastatic spread. Seven patients (6%) experienced adverse effects, primarily fevers and itching, and 33% of patients developed antibodies to murine immunoglobulin after administration of <sup>111</sup>In-CYT-103. The results of this study suggest that <sup>111</sup>In-CYT-103 is a useful diagnostic tool for the presurgical evaluation of colorectal cancer patients.

**T**HE PROGNOSIS OF patients with colorectal cancer is related to the stage of disease at the time of diagnosis.<sup>1-3</sup> Thus the diagnosis of primary disease by barium enema, sigmoidoscopy, or colonoscopy with biopsy should be followed by staging procedures to determine the extent of tumor.<sup>4</sup> Current systems for staging colorectal malignancies depend primarily on surgical and pathologic findings. However there are limitations in the surgeon's ability to detect disease during operation.<sup>5</sup> An accurate, noninvasive method of staging colorectal tumors would permit precise individual treatment to be planned before surgery.<sup>2</sup>

One potential application in the presurgical staging of colorectal cancer is the use of monoclonal antibodies directed against tumor-associated antigens and radiolabeled

*From the Department of Surgery,\* Buffalo General Hospital, and the Nuclear Medicine Department,† Veterans Administration Medical Center, State University of New York at Buffalo, Buffalo, New York; the Division of Surgical Oncology,‡ University of California at Davis, Davis, California; and the Division of Hematology/Oncology,§ University of Missouri, Columbia, Missouri*

---

with gamma-emitting isotopes. Such agents have been administered to cancer patients to identify the anatomic distribution of a malignancy using immunoscintigraphy.<sup>6,7</sup>

Monoclonal antibody B72.3 has been investigated as a tumor imaging agent because of its pattern of extensive reactivity with mucin-producing adenocarcinomas and its limited reactivity with nonmalignant adult tissues.<sup>8</sup> Because TAG-72, the tumor-associated glycoprotein target of monoclonal antibody B72.3, reacts with up to 94% of colon adenocarcinomas, clinical studies of B72.3 immunoconjugates have been conducted in patients with colorectal cancer.<sup>9-12</sup> In one study in which <sup>131</sup>I-labeled B72.3 was administered intravenously to 20 patients with colorectal cancer, 70% of tumor lesions demonstrated radiolocalization that was at least three times that of the surrounding normal tissue.<sup>9,10</sup> In a second study conducted by the same investigators,<sup>11</sup> 8 of 12 patients had positive gamma camera scans after intraperitoneal administration of the radiolabeled monoclonal antibody; in seven of these patients, the images showed an excellent correlation with subsequent surgical findings. Importantly tumor lesions detected in 3 of the 12 patients in the latter study had been missed by conventional diagnostic tests. In a separate series, <sup>131</sup>I- or <sup>111</sup>In-labeled B72.3 was administered to 30 patients being evaluated for recurrence of colorectal carcinoma.<sup>12</sup> In this series immunoscintigraphy detected all five cases of local recurrence and three of five cases of liver metastases.

We present the results of a multicenter clinical trial in presurgical patients with primary and recurrent colorectal carcinoma using <sup>111</sup>In-CYT-103, an <sup>111</sup>In-labeled im-

---

Supported by a grant from Cytogen Corporation, Princeton, New Jersey.

Address reprint requests to Ralph J. Doerr, M.D., Department of Surgery, Buffalo General Hospital, 100 High St., Buffalo, NY 14203.

Accepted for publication August 6, 1990.

munoconjugate of B72.3 prepared using a unique site-specific conjugation method.<sup>13</sup> We have evaluated the safety profile, imaging performance, and ability of this investigational diagnostic agent to contribute to the management of presurgical patients with colorectal cancer.

### Materials and Methods

Purified, cell culture-produced monoclonal antibody B72.3 was obtained from Celltech Ltd. (Berkshire, United Kingdom) and site specifically conjugated with the linker-chelator complex, glycyl-tyrosyl-(N, $\epsilon$ -diethylenetriaminepentaacetic acid)-lysine (GYK-DTPA; JBL Scientific, Inc., San Luis Obispo, CA), at oxidized carbohydrate sites on the constant region.<sup>13</sup> The resulting immunoconjugate, B72.3-GYK-DTPA (OncoScint® CR103 or CYT-103; Cytogen Corp., Princeton, NJ), was concentrated by ultrafiltration and the monomeric antibody fraction was selected by gel filtration chromatography and filtered through a sterile 0.22- $\mu$ m filter. Single doses of 1 mg of the CYT-103 solution were aseptically filled into individual vials and stored at 4°C.

Presurgical, adult ( $\geq 21$  years old) patients with suspected or biopsy-proved primary or recurrent colorectal carcinoma were eligible for participation in this multicenter study. All patients were required to provide written informed consent, and the study protocol was approved by the institutional review board of each participating study site. Pregnant women and patients who either had received antitumor therapy within the past 4 weeks, had a Karnofsky performance status of less than 60%, had previously received a murine antibody, or had a second primary malignancy were excluded from the study.

Patients who fulfilled the enrollment criteria noted above were administered single intravenous doses of <sup>111</sup>In-CYT-103. Doses of radiolabeled antibody conjugate were prepared by adding a buffered solution of approximately 5.5 mCi of <sup>111</sup>InCl<sub>3</sub> (Amersham Corp., Arlington Heights, IL) to the vial containing the CYT-103 dose. The solution was mixed and incubated at room temperature for 30 minutes. The <sup>111</sup>In-CYT-103 was tested for free <sup>111</sup>In using an instant thin-layer chromatography procedure,<sup>14</sup> filtered through a 0.22- $\mu$ m sterile filter, and infused over approximately 5 minutes.

Planar gamma camera images, including anterior and posterior projections of the pelvis, abdomen, and thorax, were obtained using large field-of-view cameras with parallel hole medium-energy collimators. Imaging was performed on at least two occasions between 2 and 7 days after <sup>111</sup>In-CYT-103 administration and separated by at least 24 hours. Single photon emission tomographic imaging was to be performed during one of the imaging sessions. The gamma camera scans were interpreted prospectively during the course of the clinical trials by the

on-site nuclear medicine physicians. The results of immunoscintigraphy and the findings of other presurgical tests, including computed tomographic (CT) scans of the abdomen and pelvis (95 patients), chest x-ray (101 patients), barium enema (28 patients), colonoscopy (56 patients), magnetic resonance imaging (6 patients), and liver-spleen scan (12 patients), were recorded.

Surgery was to be performed after the completion of the two imaging sessions. The surgeon was apprised of the results of the presurgical workup, including the immunoscintigraphic findings. During surgery an attempt was made to confirm with tissue biopsy all potential lesions indicated by the scanning procedures. Suspected extra-abdominal disease sites were evaluated using biopsy procedures, as appropriate. Histopathologic examination and immunohistochemical analysis to quantitate the TAG-72 expression were performed on tissues obtained during surgery or biopsy.

Baseline serum levels of TAG-72 were determined using the CA 72-4 Radioimmunoassay (Centocor, Malvern, PA). Safety assessments included routine hematology, blood chemistry, and urinalysis determinations and vital sign measurements. Serum titers of human anti-mouse antibodies were measured using the ImmuSTRIP HAMA® Test System (Immunomedics, Warren, NJ), a direct enzyme-linked immunosorbent assay.<sup>15</sup>

Imaging performance parameters, including sensitivity, specificity, and accuracy, were tabulated on a per-patient and, when possible, per-lesion basis for antibody imaging and CT scanning. The study sample size was sufficient to estimate the sensitivities of immunoscintigraphy and CT imaging within  $\pm 10\%$ . The per-lesion sensitivity of immunoscintigraphy and CT imaging for liver and extrahepatic lesions was compared using McNemar's test. Fisher's exact test and the extended Mantel-Haenszel procedure were used to determine the effect of various factors (*e.g.*, tumor location and size, tumor antigen expression, and so on) on imaging performance. Data are expressed as means  $\pm$  standard deviation, and statistical significance is indicated by probability values of 0.05 or less.

## Results

### Imaging Performance

A total of 116 patients were enrolled in this trial at 24 study sites. The patient population was predominantly white (92%) and male (61%) and had a mean age of 64 years (range, 37 to 88 years). Sixty-two patients (53%) were evaluated for primary colorectal cancer and 54 (47%) were evaluated for recurrent disease. Each patient was administered a single intravenous infusion of 1 mg of CYT-103 radiolabeled with  $4.21 \pm 0.68$  mCi of <sup>111</sup>In. After gamma camera imaging studies, 103 of the 116 patients

underwent a biopsy or surgical procedure for diagnosis and/or treatment. Surgical and histopathologic findings revealed that 92 of these patients had colorectal adenocarcinoma, one patient evaluated for a recurrence of colorectal cancer had a second primary malignancy (small cell lung), and the remaining 10 patients were free of disease. The performance of immunoscintigraphy in these patients, based on prospective interpretations of the gamma camera scans by the nuclear medicine specialists at each study site, is summarized in Table 1.

Antibody imaging correctly identified at least 1 surgically confirmed tumor lesion in 64 of the 92 patients with adenocarcinoma (70% sensitivity), and antibody scans were negative for 9 of 10 patients who were free of malignancy (90% specificity). Therefore antibody imaging provided correct diagnoses for 73 of 102 patients, for an overall accuracy rate of 72%. In addition the  $^{111}\text{In}$ -CYT-103 did not localize to the small cell lung tumor in the remaining patient, thus helping to rule out a recurrence of colorectal carcinoma in this patient. In the 92 patients with colorectal cancer, immunoscintigraphy detected 65% of the adenocarcinoma lesions. Five additional areas of abnormal antibody uptake consistent with tumor lesions were evaluated histopathologically and found to be non-malignant tissues. Of these false-positive findings, three specimens were inflammatory lesions, one was a tubulovillous adenoma, and one was normal tissue. Immunohistochemical analysis, which was performed for three of the five tissues, revealed that one of the inflammatory lesions contained TAG-72 antigen, and the normal tissue and one other inflammatory lesion did not contain TAG-72.

$^{111}\text{In}$ -CYT-103 immunoscintigraphy detected occult disease, *i.e.*, tumor lesions that were not detected by phys-

ical examination or by standard presurgical diagnostic tests conducted before antibody imaging, in 11 of the 92 patients (12%) with surgically confirmed adenocarcinoma. Six of these patients were being evaluated for suspicion of disease recurrence based on clinical findings or elevated carcinoembryonic antigen (CEA) levels. Occult lesions were detected in five patients with primary colorectal cancer. In three of these patients, the antibody scans detected more extensive regional or metastatic disease, including bony metastasis, carcinomatosis, and a mid-abdominal lesion. In the other two patients, antibody imaging correctly located primary tumor lesions that were not detected by other presurgical diagnostic tests.

To delineate further the performance of  $^{111}\text{In}$ -CYT-103 immunoscintigraphy in colorectal cancer patients, imaging performance in various subgroups of patients and imaging sensitivity for the detection of various subsets of lesions were examined (Table 2). The accuracy of immunoscintigraphy was similar in patients with primary and recurrent disease. The influence of previous adjuvant therapy on antibody imaging performance also was investigated. Eleven patients had received previous radiation therapy and 16 received previous chemotherapy. Most patients had discontinued these adjuvant therapies more than 1 year before  $^{111}\text{In}$ -CYT-103 administration and none of the patients received antitumor treatments during the 4 weeks preceding infusion of the radiolabeled antibody conjugate. The data showed that antibody imaging performance in this subset of patients was similar to that in patients who did not receive previous adjuvant therapy.

In 10 patients with elevated CEA levels and negative presurgical workups, antibody imaging detected surgically confirmed occult lesions in four patients and confirmed the negative workup in three patients who were noted at surgery to have no evidence of tumor recurrence. In the remaining three patients, antibody imaging, as well as standard diagnostic procedures, failed to identify the surgically confirmed recurrence.

Antibody scan findings confirmed the absence of additional disease in 18 of 22 patients with isolated pelvic or liver recurrences. Importantly immunoscintigraphy detected extra-abdominal disease, including lesions in the lymph nodes (1), lung (3), bone (6), and brain (1), in 9 patients. Adenocarcinoma at these extra-abdominal sites was confirmed through biopsy of lung (2) and bone (1) in 3 of these patients. Brain (1) and/or bony lesions (3) initially identified by antibody imaging were detected by follow-up diagnostic tests in another 3 patients; the abnormal radiolocalizations noted for the 3 remaining patients were not explored surgically or examined by other imaging modalities.

Imaging sensitivity tended to be higher ( $p = 0.10$ ) in patients with positive (85%) versus negative (63%) serum titers of TAG-72 (Table 2). The sensitivity of antibody imaging increased significantly ( $p = 0.04$ ) with the TAG-

TABLE 1. Monoclonal Antibody (MAb) Imaging Performance in Presurgical Patients Evaluated for Colorectal Carcinoma ( $n = 102$ )

Patient Population	Per Patient Analysis		
	No. of Patients	% (No.) of Patients Correctly Diagnosed by MAb Imaging	Imaging Performance Parameter
Patients with confirmed adenocarcinoma	92	70% (64/92)	Sensitivity
Patients who were tumor-free at surgery	10	90% (9/10)	Specificity
All evaluable patients	102	72% (73/102)	Accuracy
Lesion type	Per Lesion Analysis		
	No. of Lesions Detected by MAb Imaging	Imaging Performance Parameter	
Confirmed adenocarcinoma	82/126 (65%)	Sensitivity	
Unconfirmed lesions	5	False positives	

TABLE 2. Influence of Various Factors on Antibody Imaging Performance

Group/Parameter Evaluated	Antibody Imaging Performance
A. Status of patient's disease	
Primary disease	Accuracy = 74% (45/61)
Recurrent disease	Accuracy = 68% (28/41)
B. Patients with isolated recurrences in the pelvis or liver	Confirmed isolated disease in 82% (18/22)
C. Patients with elevated CEA levels and negative presurgical workups	Accuracy = 70% (7/10)
D. Prior adjuvant therapy?	
Yes	Accuracy = 70% (14/20)
No	Accuracy = 72% (59/82)
E. Preinfusion serum TAG-72 titers	
Positive ( $\geq 10$ U/mL)	Sensitivity = 85% (17/20)
Negative	Sensitivity = 63% (39/62)
Not evaluated	Sensitivity = 80% (8/10)
F. Percentage of tumor cells that expressed TAG-72	
$< 5\%$	Sensitivity = 48% (10/21)
$\geq 5\%$ and $< 50\%$	Sensitivity = 65% (31/48)
$\geq 50\%$	Sensitivity = 79% (15/19)
Not evaluated	Sensitivity = 68% (26/38)

CEA, carcinoembryonic antigen.

72 antigen content of the tumor. Although the sensitivity of immunoscintigraphy was somewhat lower for the small tumor lesions, the antibody scans detected 50% (6 of 12) of lesions measuring 2 cm or less. Furthermore no statistically significant correlation was detected between imaging sensitivity and lesion size.

Eighty-five of ninety-two patients with surgically confirmed colorectal carcinomas, the patient with small cell lung cancer, and 9 of the 10 patients who were tumor-free at surgery were evaluated by CT imaging as well as by immunoscintigraphy. In these patients CT imaging correctly identified tumor lesions in 66% (56 of 85) of patients with surgically confirmed adenocarcinoma, and CT scans were negative for 8 of 9 patients (89%) found to be tumor free at surgery. Thus CT imaging provided correct diagnoses for 64 of the 94 patients evaluated, for an overall accuracy rate of 68%. In addition a CT scan detected abdominal and chest disease in the patient with small cell carcinoma of the lung. In the 85 patients evaluated by both imaging modalities, the per-patient accuracy (69% versus 66%) and the overall per-lesion sensitivity (Table 3) of antibody and CT imaging were numerically similar. However immunoscintigraphy correctly identified tumor lesions in 17 patients with negative CT scans, and CT imaging detected tumor in 14 patients with negative antibody images (Fig. 1). Thus, although the populations for whom CT and antibody imaging detected surgically confirmed tumor lesions overlapped, they were not identical. Furthermore the aggregate findings of CT and antibody imaging correctly identified tumor lesions in 73 of the 85 patients (86%) who were subsequently found to have surgically confirmed adenocarcinoma.

Although the overall performance of CT and antibody imaging was similar, antibody imaging detected a significantly ( $p = 0.02$ ) greater percentage of lesions in the pelvis and in other extrahepatic areas, whereas CT imaging detected a significantly ( $p = 0.002$ ) greater proportion of liver lesions (Table 2).

### Patient Management

The impact of antibody imaging on patient management was assessed in a subset of patients ( $n = 69$ ) through the use of questionnaires completed before and after surgery. Based on the surgical and histopathologic findings, the investigators considered immunoscintigraphy to have been beneficial or very beneficial for 26% of the patients (Table 4). In these patients the antibody scans detected previously occult lesions, confirmed the existence of localized disease without regional or metastatic spread, indicated that abnormal findings on other diagnostic tests corresponded to adenocarcinoma, and made a diagnosis of recurrent colorectal cancer less likely in a patient with a second primary malignancy (small cell lung cancer). The antibody scans of two of these patients are provided in Figures 2 and 3. Immunoscintigraphy was considered negative or very negative in the management of two patients; in these cases the antibody scan failed to localize the primary tumor lesion of one patient and a false-positive finding in the liver on the other patient's scan led to the performance of a contrast CT of the abdomen and a liver-spleen scan, which failed to confirm the result.

### Safety

All 116 patients enrolled in the trial were evaluated for safety. Seven patients (6%) experienced a total of nine adverse effects that were considered possibly or probably related to  $^{111}\text{In}$ -CYT-103 administration. The most frequent adverse reactions, each experienced by three patients, included fevers and itching. In addition one patient each experienced mild hypertension, queasiness, and an-

TABLE 3. A Comparison of the Detection Rates of Antibody and CT Imaging for Various Adenocarcinoma Lesions

Imaging Modality	Sensitivity by Lesion Location			Overall Sensitivity
	Pelvis*	Liver†	Other*	
Antibody scans	74% (29/39)	54% (20/37)	68% (27/40)	66% (76/116)
CT scans	59% (23/39)	86% (32/37)	48% (19/40)	64% (74/116)

\* Per lesion sensitivity of antibody imaging for disease located in the pelvis and other extrahepatic sites is significantly ( $p = 0.02$ ) greater than that of CT imaging.

† Per lesion sensitivity of CT imaging for liver lesions is significantly ( $p = 0.002$ ) greater than that of antibody imaging.

CT, computed tomograph.

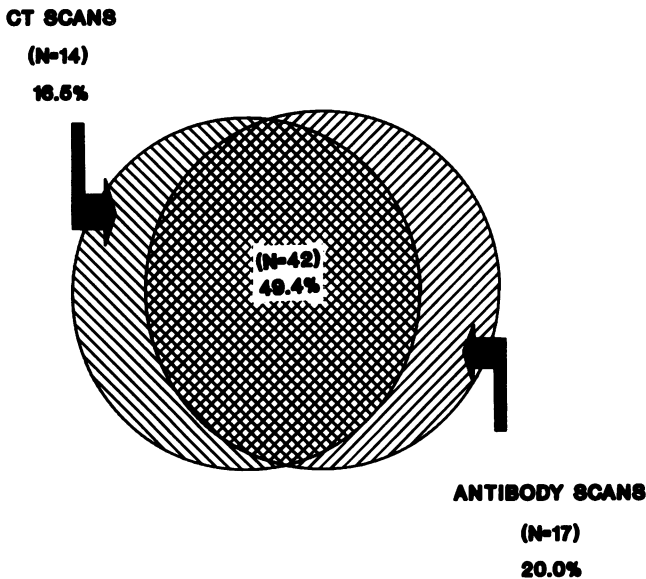


FIG. 1. A comparison of the populations of patients with surgically confirmed colorectal cancer who were correctly diagnosed by antibody and/or CT imaging. A total of 85 patients with adenocarcinoma were evaluated by both imaging methods.

gioedema. All of these adverse reactions resolved spontaneously or with appropriate treatment, and none of these signs or symptoms was considered serious. No clinically significant laboratory abnormalities related to the <sup>111</sup>In-CYT-103 infusions occurred during this study.

*HAMA Response*

Pre- and postinfusion serum samples were obtained from 95 of the 116 patients; these samples were evaluated for the presence of antibodies to murine immunoglobulin (HAMA). All patients were HAMA-negative before <sup>111</sup>In-CYT-103 administration, and 31 of the 95 patients (33%) developed positive HAMA titers after infusion.

**Discussion**

An ideal diagnostic approach for colorectal cancer would combine high sensitivity and specificity for primary or locally recurring colorectal tumors with the ability to detect accurately regional and distant metastases. This would include the detection of tumor deposits in lymph

TABLE 4. Investigators' Assessments of the Impact of Monoclonal Antibody (MAb) Imaging on Patient Management

Effect of the MAb Scan Findings on Management of the Patient	No. (%) of Patients
Very beneficial	6/69 (9%)
Beneficial	12/69 (17%)
No effect	49/69 (71%)
Negative	1/69 (1%)
Very negative	1/69 (2%)

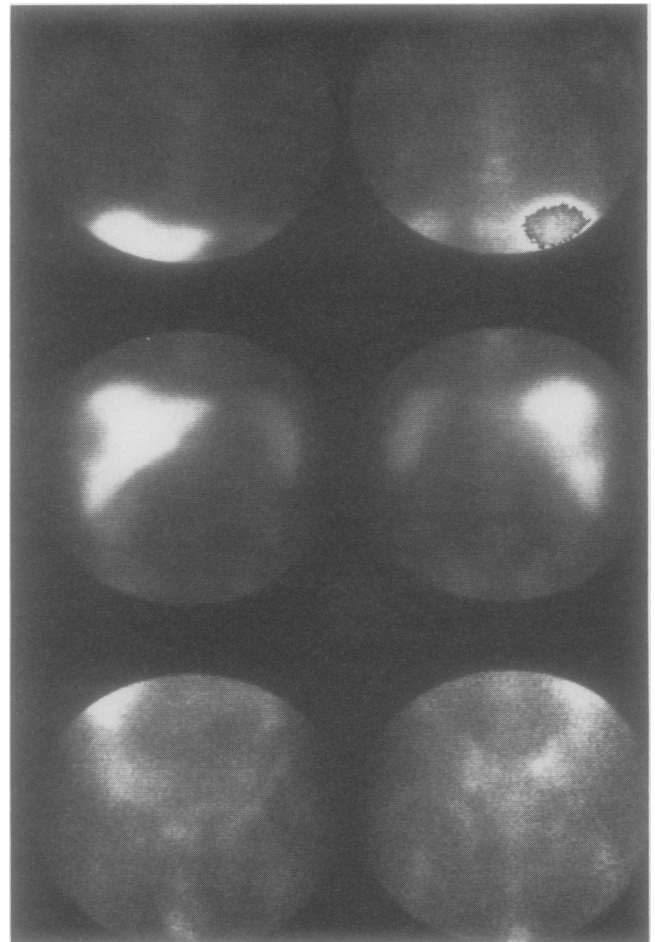


FIG. 2. Planar images, acquired 72 hours after <sup>111</sup>In-CYT-103 administration, of patient who presented with liver lesions and no known primary lesion. Antibody scan suggested colon primary, detected liver lesions, and also identified multiple bony metastases in the right shoulder, left posterior rib, and pelvis. Biopsy findings confirmed the presence of adenocarcinoma in liver and bone (rib). The previously scheduled placement of an intrahepatic artery catheter was not performed.

nodes and other soft tissues in the abdomen and retroperitoneal area that are commonly missed by currently available diagnostic tests.<sup>2</sup> Importantly any new modality must be able to influence the management of patients with colorectal cancer and compete with other diagnostic approaches in terms of relative cost and ease of use as well as sensitivity and specificity.<sup>16</sup> Such a procedure could be useful for the evaluation of both primary and recurrent disease patients. During the initial workup, this modality would be used for presurgical staging, thus assisting in planning and, potentially, in altering the operative approach. The identification of occult disease in patients who are scheduled for second-look surgery for suspected recurrence could help define the surgical procedure to be undertaken. Of special interest in this regard are patients with presumed isolated, resectable disease and patients with increasing serum CEA levels and negative presurgical workups.<sup>17</sup>

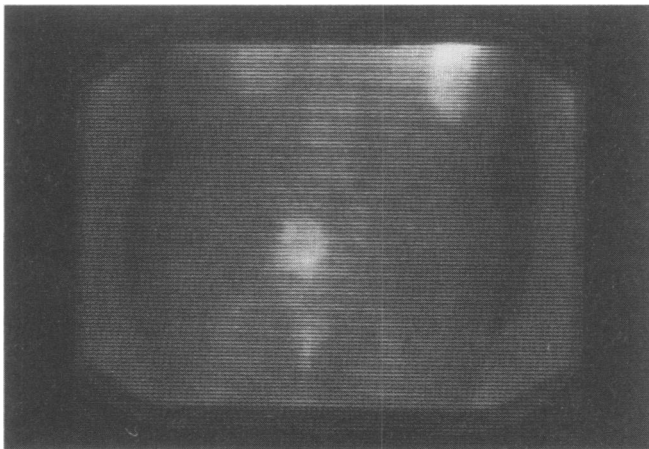


FIG. 3. Posterior planar images, acquired 48 hours after infusion, of patient evaluated for recurrence of colorectal adenocarcinoma. The antibody scan demonstrated that the pelvic mass detected by computed tomographic and magnetic resonance imaging represented a localized recurrence. These findings were confirmed at surgery.

The results of this multicenter clinical trial suggest that  $^{111}\text{In}$ -CYT-103 immunoscintigraphy can provide information that is complementary to that derived from standard diagnostic modalities and can contribute beneficially to the management of presurgical patients with colorectal carcinoma. Beneficial patient management effects were noted for both primary and recurrent disease patients. In a previous report, the management benefits related to administration of an  $^{111}\text{In}$ -labeled anticarcinoembryonic antigen-imaging agent were chiefly noted in patients with recurrent colorectal cancer.<sup>17</sup>

Importantly, antibody scans detected occult tumor lesions in 11 of 92 patients with surgically confirmed adenocarcinoma. Six were patients who were being evaluated for surgical removal of disease recurrence. The ability to assess more accurately the extent of disease in this patient population is important because a potentially curative procedure may be undertaken in recurrent disease patients with localized disease.<sup>18,19</sup> Alternatively the identification of unresectable disease may result in selection of more appropriate nonsurgical treatments, such as radiation or chemotherapy. Immunoscintigraphy also identified occult lesions in five patients with primary colorectal cancer. In these patients antibody imaging either detected more extensive disease or was the only presurgical test that correctly located the primary tumor. These findings could have a significant effect on surgical decision making, and these results suggest that the value of antibody imaging in the management of patients with colorectal carcinoma is not restricted to patients with recurrent disease.

$^{111}\text{In}$ -CYT-103 immunoscintigraphy provided accurate diagnoses for 7 of 10 patients with elevated CEA levels and otherwise negative presurgical workups. In four of these patients, antibody imaging detected occult lesions and the antibody scan findings confirmed the negative

workup in three patients with no evidence of recurrent disease at surgery. In the remaining three patients, immunoscintigraphy and standard diagnostic procedures failed to detect the surgically confirmed recurrence. Similar results have been reported using  $^{111}\text{In}$ -labeled ZCE-025, a monoclonal antibody directed against CEA.<sup>20</sup> The authors reported that radiolabeled ZCE-025 provided accurate diagnoses in 12 of 13 colorectal cancer patients with elevated CEA levels and negative radiologic workups. Taken together these findings indicate that immunoscintigraphy with radiolabeled monoclonal antibodies may substantially contribute to the evaluation of patients with increasing CEA levels who are at high risk for recurrence of colorectal cancer and for whom a major operative procedure is contemplated.

The assessments of the patient management impact of  $^{111}\text{In}$ -CYT-103 immunoscintigraphy corroborated the imaging performance findings for the study population and for various subgroups of patients. The antibody scan findings contributed beneficially to management decisions in 18 of 69 patients (26%) evaluated. Antibody scans contributed equally to the management of primary and recurrent disease patients. In general beneficial ratings were assigned in cases in which antibody imaging either detected previously occult lesions, which were later documented at surgery, or confirmed localized disease in patients scheduled for curative resections. In the two patients (3%) with negative patient management ratings, the antibody images failed to detect the primary tumor in one case and suggested additional imaging tests, which failed to confirm the abnormal radiolocalization, in the other.

Although the sensitivity and specificity of antibody imaging were similar to those of CT scanning, it is interesting to note that antibody imaging correctly identified tumor lesions in 17 patients with negative CT scans, and CT scans correctly identified tumor lesions in 14 patients with negative antibody images. In the population studied, CT was superior for detection of hepatic lesions, whereas immunoscintigraphy was superior for extrahepatic disease, including extra-abdominal lesions and those in the mid abdomen and in the pelvis, an area where CT imaging is purported to be helpful.<sup>21</sup> These results suggest that the use of a combination of these two presurgical diagnostic tests, each of which is particularly useful for evaluating certain anatomic regions, can provide complementary information and greater overall accuracy than either test used alone.

No serious clinical toxicity was observed in this multicenter trial. As noted one in three patients infused with  $^{111}\text{In}$ -CYT-103 developed positive HAMA titers after infusion. In this single-infusion study, all patients were HAMA negative before infusion of the study agent; therefore the impact of circulating HAMA on the safety and efficacy of  $^{111}\text{In}$ -CYT-103 was not evaluated. Published literature suggests that the clearance of monoclonal an-

tibody-based products may be increased in patients with detectable levels of HAMA.<sup>22</sup> However preliminary results indicate that these agents can be readministered safely in the presence of circulating HAMA and that diagnostic images have been obtained following repeated administration.<sup>23,24</sup> A study is in progress to investigate repeated administration of <sup>111</sup>In-CYT-103 in patients with colorectal carcinoma.

The limited clinical toxicity observed for this agent combined with its demonstrated ability to contribute beneficially to patient management decisions through detection of primary and recurrent colorectal tumors, including occult lesions, indicate that <sup>111</sup>In-CYT-103 is a useful tool in the presurgical evaluation of colorectal cancer patients.

### Acknowledgments

The authors thank the following clinical investigators who, in addition to the authors, participated in the <sup>111</sup>In-CYT-103 multicenter clinical trial: Henry F. Sears, M.D. and Thanjavur S. Ravikumar, M.D. (New England Deaconess Hospital), Steven J. Harwood, M.D. (Bay Pines V.A.M.C.), B. David Collier, M.D. (Medical College of Wisconsin), Robert F. Carretta, M.D. (Roseville Community Hospital), J. Gale Katterhagan, M.D. and Charles Neal, M.D. (Memorial Medical Center and Southern Illinois University School of Medicine), Michael B. Brachman, M.D. and Alan D. Waxman, M.D. (Cedars-Sinai Medical Center), John Olsen, M.D. (Ohio State University Medical Center), Sabah Tumeh, M.D. (Brigham and Women's Hospital), Pablo Dibos, M.D. and Douglas Van Nostrand, M.D. (Franklin Square Hospital), Jon A. Kotler, M.D. (Cleveland Clinic Florida, University of Miami), A. Bertrand Brill, M.D., Ph.D. (University of Massachusetts Medical Center), Stanley Grossman, M.D. (The Western Pennsylvania Hospital), Daniel Kenady, M.D. (University of Kentucky Hospital and Medical Center), Patrick V. Ford, M.D. (University of California Davis Medical Center), Ramesh D. Dhekne, M.D. (St. Lukes' Episcopal Hospital), Richard L. Wahl, M.D. and Alfred E. Chang, M.D. (University of Michigan Hospital), Frank DeLand, M.D. (Syracuse V.A.M.C.), Joseph A. Sanger, M.D. (NYU Medical Center), Edward H. Kaplan, M.D. (Rush-Presbyterian St. Lukes' Medical Center), Daniel Haller, M.D. (Hospital of the University of Pennsylvania), James Woolfenden, M.D. (University of Arizona), Gary Winzelberg, M.D. (Shadyside Hospital), and Alan D. Hughes, M.D. (Erlanger Medical Center).

### References

- Cairns J. The treatment of diseases and the war against cancer. *Sci Am* 1985; 253:51-59.
- Moss AA. Imaging of colorectal carcinoma. *Radiology* 1989; 170:308-310.
- Kelvin FM, Maglinte DDT. Colorectal carcinoma: a radiologic and clinical review. *Radiology* 1987; 164:1-8.
- Schein PS. Colonic cancer and rectal cancer. In Schein PS, ed. *Decision Making in Clinical Oncology*. Philadelphia: BC Decker, 1989, pp 82-85.
- Sickle-Santanello BJ, O'Dwyer PJ, Mojzisek C, et al. Radioimmunoguided surgery using the monoclonal antibody B72.3 in colorectal tumors. *Dis Colon Rectum* 1987; 30:761-765.
- Larson SM. Lymphoma, melanoma, colon cancer: diagnosis and treatment with radiolabeled monoclonal antibodies. *Radiology* 1987; 165:297-304.
- Goldenberg DM, Deland F, Kim E, et al. Use of radiolabeled antibodies to carcinoembryonic antigen for the detection and localization of diverse cancers by external photoscanning. *N Engl J Med* 1978; 298:1384-1388.
- Thor A, Ohuchi N, Szpak CA, et al. Distribution of oncofetal antigen tumor-associated glycoprotein-72 defined by monoclonal antibody B72.3. *Cancer Res* 1986; 46:3118-3124.
- Colcher D, Carrasquillo JA, Esteban JM, et al. Radiolabeled monoclonal antibody B72.3 localization in metastatic lesions of colorectal cancer patients. *Nucl Med Biol* 1987; 14:251-262.
- Esteban JM, Colcher D, Sugarbaker P, et al. Quantitative and qualitative aspects of radiolocalization in colon cancer patients of intravenously administered MAb B72.3. *Int J Cancer* 1987; 39:50-59.
- Carrasquillo JA, Sugarbaker P, Colcher D, et al. Peritoneal carcinomatosis: Imaging with intraperitoneal injection of I-131-labeled B72.3 monoclonal antibody. *Radiology* 1988; 167:35-40.
- Renda A, Salvatore M, Sava M, et al. Immunoscintigraphy in the follow-up of patients operated on for carcinoma of the sigmoid and rectum. *Dis Colon Rectum* 1987; 30:683-686.
- Rodwell JD, Alvarez VL, Lee C, et al. Site-specific covalent modification of monoclonal antibodies: *in vitro* and *in vivo* evaluations. *Proc Natl Acad Sci USA* 1986; 83:2632-2636.
- Zimmer AM, Kazikiewicz JM, Spies SM, Rosen ST. Rapid miniaturized chromatography for <sup>111</sup>In labeled monoclonal antibodies: comparison to size exclusion high performance liquid chromatography. *Nucl Med Biol* 1988; 15:717-720.
- LaFontaine GS, Hansen HJ, Weiss BF, Goldenberg DM. Enzyme immunoassay for the detection of circulating immunoglobulins in humans to mouse monoclonal antibody (HAMA). Presented at the Third International Conference on Monoclonal Antibody Immunoconjugates for Cancer, February 4-6, 1988.
- Haller DG. Monoclonal antibody imaging in the management of patients with colorectal cancer. *J Clin Oncol* 1988; 6:1213-1215.
- Beatty JD, Hyams DM, Morton BA, et al. Impact of radiolabeled antibody imaging on the management of colon cancer. *Am J Surg* 1989; 157:13-19.
- Sardi A, Minton JP, Nieroda C, et al. Multiple reoperations in recurrent colorectal carcinoma. An analysis of morbidity, mortality, and survival. *Cancer* 1988; 61:1913-1919.
- Adson MA, Van Heerden JA, Adson MH, et al. Resection of hepatic metastases from colorectal cancer. *Arch Surg* 1984; 119:647-651.
- Doerr RJ, Abdel-Nabi H, Merchant B. Indium 111 ZCE-025 immunoscintigraphy in occult recurrent colorectal cancer with elevated carcinoembryonic antigen level. *Arch Surg* 1990; 125:226-229.
- Thompson WM, Halvorsen RA, Foster WL, et al. Preoperative and postoperative CT staging for rectosigmoid carcinoma. *Am J Roentgenol* 1986; 146:703-710.
- Reynolds JC, Del Vecchio S, Sakahara H, et al. Anti-murine antibody response to mouse monoclonal antibodies: clinical findings and implications. *Nucl Med Biol* 1988; 16:121-125.
- Perkins AC, Pimm MV, Powell MC. The implications of patient antibody response for the clinical utility of immunoscintigraphy. *Nucl Med Commun* 1988; 9:273-282.
- Abdel-Nabi H, Doerr R, Roth SC, Farrell E. Screening for recurrent colorectal carcinoma with repeated infusions of In-111 ZCE-025 MoAb. Presented at the Fourth International Conference on Monoclonal Antibody Immunoconjugates for Cancer, March 1989; San Diego, California.