

ON THE BRONCHOCONSTRICTOR EFFECT OF SEROTONIN.
BRONCHOGRAPHIC STUDIES ON RABBITS
AND GUINEA-PIGS

BY E. O. JÄNKÄLÄ AND P. VIRTAMA

*From the Department of Anatomy, University of Helsinki, and
the Second Medical Clinic, University Central Hospital,
Helsinki, Finland*

(Received 24 October 1960)

Serotonin is known to be an effective bronchoconstrictor in animals (Herxheimer, 1953; Konzett, 1956; Balzer, Greef & Westermann, 1956). In man a clinical sign of this action is the fact that patients suffering from metastasizing carcinoid tumour often have asthmatic attacks; and Herxheimer (1955) found that although inhalation of serotonin aerosol in four normal cases had no effect, in three out of six asthmatics it elicited severe asthmatic attacks which were abolished by *iso*-propyladrenaline.

The observations made on the bronchoconstrictor action of serotonin have been based on indirect measurements. But it is a straightforward procedure to render the bronchial tree of test animals visible by the methods of clinical bronchography with radio-opaque substances; this technique has therefore been used to demonstrate the effects of serotonin on the bronchi.

METHODS

Twenty rabbits and fifteen guinea-pigs were used. Sixteen rabbits were anaesthetized with urethane intravenously, four with ether; all the guinea-pigs were anaesthetized with ether.

Most of the animals examined received reserpine (7 mg/kg) 24 hr before the experiment in order to abolish the effects of the natural stores of serotonin.

The trachea of the anaesthetized animal was exposed, and a polythene catheter introduced into it. The contrast agent used was Dionosil Aqueous (Glaxo Laboratories, Ltd.). In some experiments (see Table 1) serotonin was administered through the catheter before the injection of the contrast agent; in other experiments serotonin was administered intravenously. After the lungs had been filled with the contrast agent by letting it flow freely into the lungs while the animal was turned about, the trachea was tied and the lungs were removed.

The lungs were radiographed with a Siemens' fine-structure tube equipped with a copper anode at 30 kVp, with Crystallex (Kodak) fine-grain X-ray film developed in D76 fine-grain developer. This technique allowed a magnification by about ten diameters.

TABLE I

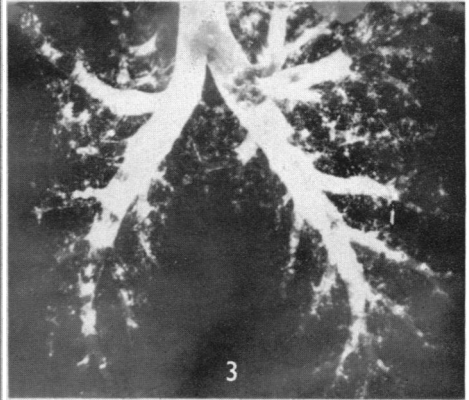
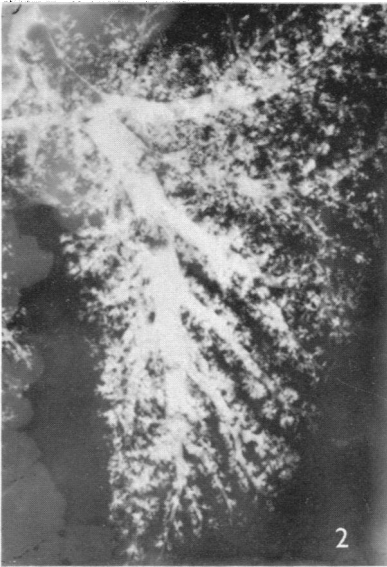
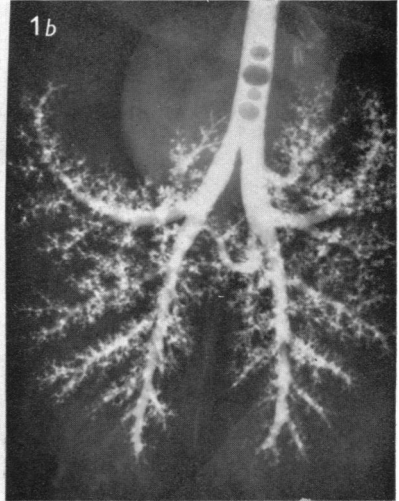
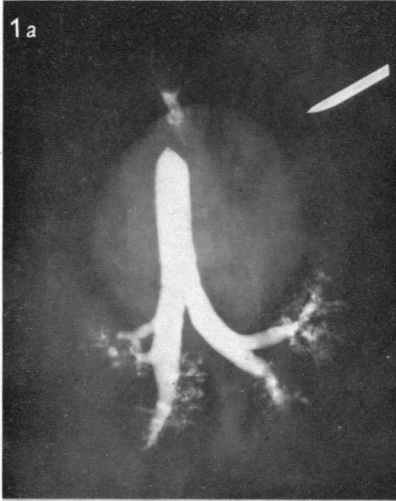
No. and species of test animals used	Premedication, reserpine 7 mg/kg intramusc. 24 hr before expt.	Mode of anaesthesia	Serotonin	Result
2 rabbits	No	Ether	No	Slight bronchospasm
2 rabbits	No	Ether	6 mg/kg i.v.	Slight bronchospasm
3 rabbits	No	Urethane i.v.	No	No bronchospasm
2 rabbits	No	Urethane i.v.	6 mg/kg i.v.	No bronchospasm
3 rabbits	Yes	Urethane i.v.	No	No bronchospasm
4 rabbits	Yes	Urethane i.v.	6 mg/kg endo-bronch.	No bronchospasm
4 rabbits	Yes	Urethane i.v.	6 mg/kg endo-bronch.	No bronchospasm
3 guinea-pigs	No	Ether	No	Moderate filling, some bronchospasm
6 guinea-pigs	Yes	Ether	1-12 mg/kg i.v.	Severe bronchoconstriction
6 guinea-pigs	Yes	Ether	1-10 mg/kg endobronch.	Severe bronchoconstriction

RESULTS

Table 1 summarizes the results. The guinea-pigs anaesthetized with ether and the rabbits anaesthetized with urethane or ether differed in their reactions to serotonin. Bronchoconstriction could be readily produced in the guinea-pigs, whether serotonin was given intravenously or endobronchially, and severe bronchospasm occurred (Pl. 1, fig. 1*a*). A normal bronchogram in the guinea-pig is shown for comparison in fig. 1*b*. In the rabbit under urethane, however, no bronchospasm could be evoked whether the animal was pre-treated with reserpine or not, or whether the serotonin was given into the bronchi or intravenously (Pl. 1, fig. 2). In the rabbit under ether a moderate bronchospasm could be induced (Pl. 1, fig. 3).

DISCUSSION

The aim of this work was to render visible the effect of serotonin on the bronchial tree of test animals. In the rabbit under urethane, serotonin had little action whether the animal was pre-treated with reserpine, to deplete its natural stores of serotonin, or not. Geiger & Alpers (1957) have shown that the contraction of smooth muscle by serotonin is antagonized by urethane; this may well explain our results on the rabbit under urethane. In the two experiments where ether anaesthesia was used in rabbits, serotonin given endobronchially or intravenously caused some, though only moderate, bronchoconstriction. The lungs of the rabbit contain relatively high amounts of serotonin. This could make the bronchi rather resistant to serotonin administered. The natural stores of serotonin in the lungs of



guinea-pigs are lower than those of rabbits (Weissbach, Waalkes & Udenfriend, 1957). In accordance with this fact was the striking bronchoconstriction caused by endobronchially or intravenously administered serotonin.

The bronchoconstrictor action of serotonin could thus be clearly demonstrated radiographically, and to some extent localized in the respiratory tract. The fact that it could be readily seen in etherized guinea-pigs, and only poorly or not at all in anaesthetized rabbits, conforms with the results of experiments with indirect methods by other authors (Schneider & Yonkman, 1954; Konzett, 1956).

SUMMARY

Reactions of bronchi to serotonin were examined with the aid of bronchography in rabbits and guinea-pigs. Serotonin had little effect on the bronchi of rabbits. On guinea-pigs the bronchoconstrictor effect was striking.

REFERENCES

- BALZER, H., GREEF, K. & WESTERMANN, E. (1956). Die bronchoconstrictorische Wirkung des Serotonins. *Klin. Wschr.* **34**, 1204.
- GEIGER, W. B. & ALPERS, H. S. (1957). Mode of action of antigen and other smooth-muscle stimulants. *Science*, **125**, 1141.
- HERXHEIMER, H. (1953). Further observations on the influence of 5-hydroxytryptamine on bronchial function. *J. Physiol.* **122**, 40-50 P.
- HERXHEIMER, H. (1955). The 5-hydroxytryptamine shock in the guinea-pig. *J. Physiol.* **128**, 435-445.
- KONZETT, H. (1956). The effects of 5-hydroxytryptamine and its antagonists on tidal air. *Brit. J. Pharmacol.* **11**, 289-294.
- SCHNEIDER, J. A. & YONKMAN, F. F. (1954). Species differences in the respiratory and cardiovascular response to serotonin (5-hydroxytryptamine). *J. Pharmacol.* **111**, 84-98.
- WEISSBACH, H., WAALKES, T. P. & UDENFRIEND, S. (1957). Presence of serotonin in lung and its implication in the anaphylactic reaction. *Science*, **125**, 235-236.

EXPLANATION OF PLATE

Fig. 1. (a) Severe bronchoconstriction in a guinea-pig under ether, induced by intravenously administered serotonin 1.2 mg/100 g. Reserpine premedication 7 mg/kg. (b) Normal bronchography in a guinea-pig under ether. Reserpine premedication 7 mg/kg. No serotonin.

Fig. 2. Good filling, no bronchospasm in a control rabbit under urethane. No premedication. Bronchography with Dionosil Aqueous. Identical pictures were obtained in rabbits injected with serotonin endobronchially or intravenously up to 6 mg/kg.

Fig. 3. Slight bronchospasm in a control rabbit under ether. Reserpine premedication 7 mg/kg. No serotonin.