

Reservoir Competency of Goats for the Ap-Variant 1 Strain of *Anaplasma phagocytophilum*

Robert F. Massung,^{1*} Thomas N. Mather,² and Michael L. Levin¹

Viral and Rickettsial Zoonoses Branch, Division of Viral and Rickettsial Diseases, CDC, Atlanta, Georgia,¹ and Center for Vector-Borne Disease, University of Rhode Island, Kingston, Rhode Island²

Received 2 September 2005/Returned for modification 8 October 2005/Accepted 8 November 2005

Field-collected ticks were used to infect goats with either Ap-ha, a strain associated with human disease, or a variant strain, Ap-Variant 1, of *Anaplasma phagocytophilum*. Goats were shown to be competent as a reservoir for Ap-Variant 1, and challenge and immunosuppression studies were used to further examine infection in the goat model.

Ap-Variant 1 represents a distinct strain of *Anaplasma phagocytophilum* that has not been associated with human disease. White-tailed deer (*Odocoileus virginianus*) appear to serve as a natural reservoir for Ap-Variant 1, and to date they are the only vertebrate species known to harbor this strain (1, 6, 7). However, deer are difficult to use in a laboratory setting and require specialized large animal facilities. Therefore, the potential for the domestic goat to serve as a smaller ruminant animal model was examined. The competency of goats as a natural reservoir for Ap-Variant 1 was also evaluated by tick-feeding and transmission studies.

Questing adult and nymphal ticks were collected by flagging from South Kingstown, Rhode Island, and allowed to feed on three pathogen-free goats. Two of the goats (A and B) became infected with *A. phagocytophilum* strains whose 16S rRNA sequences matched that of the human pathogenic strain Ap-ha. The third goat (goat C) became infected with the Ap-Variant 1 strain, as demonstrated by PCR amplification from blood and DNA sequencing, as previously described (8). EDTA-treated blood (3.5 ml) collected from goat C at 3 weeks postinfection was used to infect goat D with Ap-Variant 1. This showed that the DNA detected by PCR in the blood of goat C represented viable organisms. Larval and nymphal ticks were allowed to feed on goat C, allowed to molt, and fed on goat E, which became infected with Ap-Variant 1, thereby demonstrating the reservoir competency of goats.

Blood smears were prepared from goat D on day 14 postinjection, stained for visualization of cellular morphology, and fluorescein labeled using anti-*A. phagocytophilum* antibodies (Fig. 1). The fluorescein-labeled image (Fig. 1B) demonstrates that Ap-Variant 1 was detected only in segmented neutrophils. Blood samples from goats C, D, and E were collected sequentially and assessed for infection and serological titers. End-point titers in the sera were determined by an immunofluorescence assay using a fluorescein isothiocyanate-labeled rabbit anti-goat conjugate (Rockland Immunochemicals, Gilbertsville, PA). Table 1 summarizes

the source of infection and PCR, DNA sequencing, and immunofluorescence assay results for each of the five goats. Only goat A showed signs of clinical illness, including fever, lethargy, lameness, loss of appetite, and nasal discharge. Goat E was further tested every 2 to 3 days for 3 months by use of complete blood counts with differential and serum

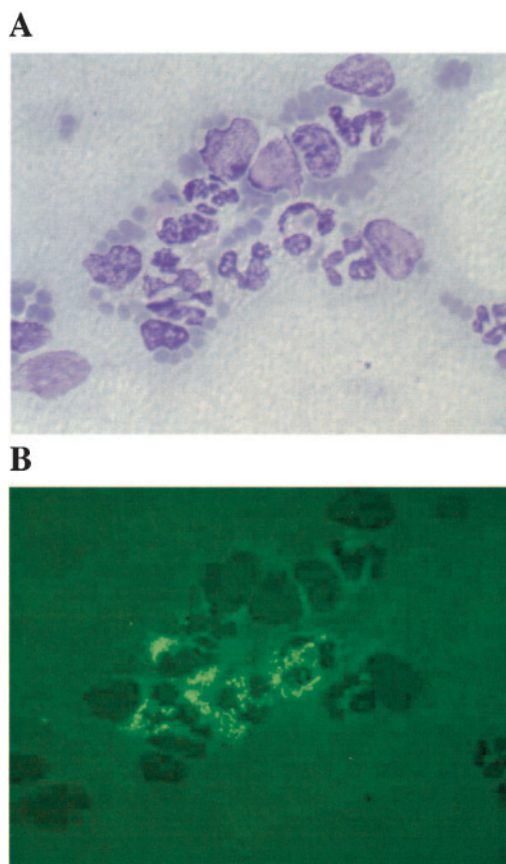


FIG. 1. Blood smear of EDTA-treated goat blood infected with Ap-Variant 1. The cells in panel A are stained to allow visualization of cellular morphology. Panel B shows the same cells labeled with fluorescein, using anti-*A. phagocytophilum* antibodies, to identify Ap-Variant 1 bacteria.

* Corresponding author. Mailing address: Centers for Disease Control and Prevention, 1600 Clifton Rd., MS G-13, Atlanta, GA 30333. Phone: (404) 639-1082. Fax: (404) 639-4436. E-mail: rfm2@cdc.gov.

TABLE 1. Infection sources and test results for goats infected with either Ap-ha or Ap-Variant 1

Goat	Infection method	Infecting strain ^a	Day of initial PCR-positive result	Days with PCR-positive result	Initial seroconversion (day) ^d	Maximum titer ^d	Maximum fever (°F)
A	Field-collected ticks ^b	Ap-ha	11	8	NT	NT	103.9
B	Field-collected ticks ^b	Ap-ha	11	1	NT	NT	104.3
C	Field-collected ticks ^b	Ap-Variant 1	10	14	17	1/1,024	100.6
D	Blood from goat C	Ap-Variant 1	7	12	9	1/256	103.3
E	Ticks fed on goat C ^c	Ap-Variant 1	5	19	7	1/512	103.5

^a Determined by PCR and DNA sequencing of the 16S rRNA gene.

^b Adult *Ixodes scapularis* ticks collected from South Kingstown, Rhode Island.

^c Fed as larvae and nymphs on goat C, allowed to molt, and fed as nymphs and adults on goat E.

^d NT, not tested.

chemistry profiles. Goat E had a slightly elevated temperature (103.5°F) on day 7 postinfestation only and showed mild and transient neutropenia and lymphopenia on days 10 and 7 postinfestation, respectively. Otherwise, goat E showed normal serum profiles and blood cell counts during the infection and through 3 months postinfestation.

Although each of the three goats infected with Ap-Variant 1 were PCR positive for various lengths of time, the infections appeared to be cleared because each goat was PCR negative past day 24. To assess the clearance of Ap-Variant 1 in goats, goat D was treated on day 110 postinfection and for five consecutive days with an intramuscular dose (4 mg/kg body weight) of dexamethasone as a strong immunosuppression regimen (3, 4). Goat D remained PCR negative through day 32 posttreatment, and the serum titer remained stable, at ≤ 128 . These results suggest that goat D had cleared the Ap-Variant 1 infection.

Goat C was treated with a regimen of the antibiotic oxytetracycline (10) at 3 months postinfection and, 25 days after treatment, infested with 50 nymphal ticks that were infected with Ap-ha. This goat became PCR positive on day 11 and remained positive through day 25, and the infectious agent was confirmed to be Ap-ha by DNA sequencing. Whereas the titer of goat C was 1/32 prior to the challenge, by day 21 postinfestation the titer had risen to 1/>2,048. These results demonstrate that the immune response induced by infection with Ap-Variant 1 did not provide protection from a subsequent infection with Ap-ha. This is in agreement with prior studies where sheep and mice were not protected when challenged with heterologous strains of *A. phagocytophilum* (5, 11).

Our ability to characterize the biological and molecular features of Ap-Variant 1 has been limited by several factors, primarily the lack of a tissue culture isolate of the agent and the lack of an animal model for laboratory studies. The current study addresses the latter of these needs and demonstrates that the domestic goat can be infected by the Ap-Variant 1 strain and is competent as a reservoir for maintenance of the agent in a natural vertebrate host-tick vector cycle. Blood from infected goats also provides an excellent resource for ongoing attempts to make a tissue culture isolate of the variant strain. The availability of sera from Ap-Variant 1-infected goats also provides a useful reagent that can be applied to characterizing the Ap-Variant 1 strain by use of Western blots, immunoprecipitation, or other methods for examining the antigenic composition of the agent.

Ap-Variant 1 has now been shown to infect goats and white-tailed deer but is not infectious in mice, hamsters, and gerbils (7; data not shown). These data suggest that Ap-Variant 1 is restricted to ruminant species and represents a lineage distinct from Ap-ha, which infects humans and numerous other mammals. A similar distinction between ruminant and nonruminant lineages in Europe has been suggested (9). However, the pathogenic potentials of ruminant strains from Europe and North America appear to differ dramatically. Tick-borne fever in Europe is a well-documented disease of sheep, cattle, and goats characterized by an acute febrile illness, with mortality rates as high as 30% in lamb herds (2, 12–14). In contrast, our experimental Ap-Variant 1 infections of goats caused few apparent clinical symptoms. This suggests that the North American Ap-Variant 1 strain has evolved into a less pathogenic form than the European ruminant strains. While Ap-Variant 1 has low pathogenic potential based on our experimental infections, it may be that the agent causes morbidity and mortality in a domestic or wildlife species that has not yet been examined. Continued studies are needed to examine the host range of Ap-Variant 1 to determine if ruminants other than white-tailed deer and goats are susceptible to infection and whether restriction of the variant to ruminant species is absolute.

We are grateful to Kimetha Slater, Danielle Ross, Leah Kostelnik, Amanda Loftis, and Jennifer Shields for excellent technical assistance and to Herbert Thompson for review of the manuscript and useful suggestions. We thank the Biotechnology Core Facility of the National Center for Infectious Diseases Scientific Resources Program for the synthesis of reagents used in this study.

REFERENCES

1. Courtney, J. W., R. L. Dryden, J. Montgomery, B. S. Schneider, G. Smith, and R. F. Massung. 2003. Molecular characterization of *Anaplasma phagocytophilum* and *Borrelia burgdorferi* in *Ixodes scapularis* ticks from Pennsylvania. *J. Clin. Microbiol.* **41**:1569–1573.
2. Gokce, H. I., and Z. Woldehiwet. 1999. Differential haematological effects of tick-borne fever in sheep and goats. *Zentbl. Veterinarmed. B* **46**:105–115.
3. Koptopoulos, G., M. Papanastasiopoulou, S. Lekkas, G. Skaragas, and O. Papadopoulos. 1992. Immunosuppression in goats by dexamethasone and cyclophosphamide. *Comp. Immunol. Microbiol. Infect. Dis.* **15**:235–242.
4. Kunicka, J. E., M. A. Talle, G. H. Denhardt, M. Brown, L. A. Prince, and G. Goldstein. 1993. Immunosuppression by glucocorticoids: inhibition of production of multiple lymphokines by in vivo administration of dexamethasone. *Cell Immunol.* **149**:39–49.
5. Levin, M. L., D. J. Coble, and D. E. Ross. 2004. Reinfection with *Anaplasma phagocytophilum* in BALB/c mice and cross-protection between two sympatric isolates. *Infect. Immun.* **72**:4723–4730.

6. **Massung, R. F., J. W. Courtney, S. L. Hiratzka, V. E. Pitzer, G. Smith, and R. L. Dryden.** 2005. *Anaplasma phagocytophilum* in white-tailed deer. *Emerg. Infect. Dis.* **11**:1604–1606.
7. **Massung, R. F., R. A. Priestley, N. J. Miller, T. N. Mather, and M. L. Levin.** 2003. Inability of a variant strain of *Anaplasma phagocytophilum* to infect mice. *J. Infect. Dis.* **188**:1757–1763.
8. **Massung, R. F., K. Slater, J. H. Owens, W. L. Nicholson, T. N. Mather, V. B. Solberg, and J. G. Olson.** 1998. Nested PCR assay for detection of granulocytic ehrlichiae. *J. Clin. Microbiol.* **36**:1090–1095.
9. **Petrovec, M., A. Bidovec, J. W. Sumner, W. L. Nicholson, J. E. Childs, and T. Avsic-Zupanc.** 2002. Infection with *Anaplasma phagocytophila* in cervids from Slovenia: evidence of two genotypic lineages. *Wien. Klin. Wochenschr.* **114**:641–647.
10. **Pugh, D. G. (ed.).** 2001. *Sheep and goat medicine.* Saunders, Philadelphia, Pa.
11. **Stuen, S., K. Artursson, and E. E. Olsson.** 1998. Experimental infection of lambs with an equine granulocytic *Ehrlichia* species resembling the agent that causes human granulocytic ehrlichiosis (HGE). *Acta Vet. Scand.* **39**:491–497.
12. **Stuen, S., K. Bergstrom, and E. Palmer.** 2002. Reduced weight gain due to subclinical *Anaplasma phagocytophilum* (formerly *Ehrlichia phagocytophila*) infection. *Exp. Appl. Acarol.* **28**:209–215.
13. **van Miert, A. S., C. T. van Duin, A. J. Schotman, and F. F. Franssen.** 1984. Clinical, haematological and blood biochemical changes in goats after experimental infection with tick-borne fever. *Vet. Parasitol.* **16**:225–233.
14. **Woldehiwet, Z.** 1983. Tick-borne fever: a review. *Vet. Res. Commun.* **6**:163–175.

Editor: J. T. Barbieri