

J. Physiol. (1953) 122, 193-202

## MUSCLE SPINDLES IN THE INTRINSIC MUSCLES OF THE HUMAN TONGUE

BY SYBIL COOPER

*From the University Laboratory of Physiology, and Nuffield Department  
of Surgery, University of Oxford*

*(Received 30 April 1953)*

The presence of a muscle spindle in a human tongue was first reported by von Franqué in 1891. Forster (1894) saw spindles in the genioglossus muscle and in the back part of the human tongue. Ceccherelli (1908) also saw small spindles, and localized them in the superior longitudinal muscle of the intrinsic musculature. Sherrington (1894) said he was unable to find spindles in the intrinsic muscles of the tongue. He used animal material and, unfortunately, does not make it clear which animals he used. Langworthy (1924*a, b*) reported structures which he called muscle spindles in the tongues of the embryo pig, cat, dog, opossum and rat; his two papers are contradictory as to whether these spindles were in the intrinsic or extrinsic muscles. Tarkhan (1936) reported spindles in the rabbit's tongue, but Boyd (1937, 1941) and Carleton (1938) working on the rabbit, and Weddell, Harpman, Lambley & Young (1940), on the rat and rabbit, were unable to confirm their presence in the intrinsic muscles. It is generally thought to-day, on the basis of this animal work, that if spindles are present in the human tongue they are sparse in distribution and confined to the extrinsic musculature. This has led to somewhat misleading statements about proprioceptors in the tongue. The present work is mainly concerned with a histological examination of the human tongue, special attention being paid to the localization of muscle spindles in the intrinsic muscles.

### METHODS AND MATERIAL

The first human tongue examined was from a 6-year-old child suffering from amyoplasia congenita. The undoubted presence of several spindles in the intrinsic muscles led to a small collection of tongues from full-term still-born babies being made, together with a few specimens from older children and from adults. The tongues were usually cut in half longitudinally and fixed in formalin. Frozen sections were cut at  $50\mu$ , some being parasagittal, other transverse, from various regions. These sections were stained by the Bielschowsky-Gros silver method. Other new-born babies' tongues were cut in half and embedded in paraffin, one of these half tongues was then cut into four parasagittal blocks, another into four horizontal blocks and yet another was cut transversely into

blocks of 4 mm thickness. Specimen sections were taken from each of these blocks, and stained with haematoxylin and eosin or by van Gieson's method. The tongue of a rhesus monkey, two tongues from new-born kittens and one from a new-born lamb were also examined.

## RESULTS

### *Human tongue*

The morphology of the human tongue has been described by Abd-el-Malek (1939). The organ contains two sets of muscles, an extrinsic set having bony attachments outside the tongue and an intrinsic set having no bony attachments. The intrinsic musculature consists of four groups of muscles: the superior longitudinal muscle lying the whole length of the tongue below the dorsal epithelium, the two inferior longitudinal muscles lying in the ventro-lateral parts of the tongue, the transverse muscles running from the lateral regions to the median septum and the vertical muscles which are seen as small groups of muscle fibres running dorso-ventrally in the distal and lateral parts of the tongue. The inferior longitudinal muscles lie in distinct bundles, but the other sets of muscles may interweave with each other, the bundles of the vertical muscle fibres lying among the fibres of the superior longitudinal muscle near the dorsum of the tongue, and among the fibres of the transverse muscle in the deeper part as shown in Pl. 1, fig. 1. In the adult these bundles are separated by much spongy connective tissue, but in the young child the interior of the tongue is a more compact muscular structure.

In the medial part of the tongue and in the extreme lateral regions the fibres of the extrinsic genioglossus, hyoglossus and styloglossus muscles may run parallel with the intrinsic muscle fibres so that the exact limits of each set are not easy to make out.

The first sections to be examined were complete transverse frozen sections taken from the middle of the tongue of the child with amyoplasia congenita. After staining with silver, it was possible to pick out cross-sections of muscle spindles in the superior longitudinal muscle, and longitudinal sections of spindles in the transverse muscle. Two of the latter sections are shown in the same field in Pl. 1, fig. 2. The spindles were characterized by very fine capsules, and they appeared to be quite short. They were, however, typical muscle spindles, often with numerous intrafusal fibres. Bigger spindles were seen in those parts of the genioglossus muscles which lie between the inferior longitudinal muscles near the base of the tongue.

The babies' tongues were only 3-5 cm long, and it was possible to examine parasagittal sections from the whole length of the tongue. It became obvious, as the work proceeded, that the muscle spindles were not distributed equally over the whole musculature. There were fewer present in the distal third or tip of the tongue, and this explains why it is possible to take a specimen block from near the tip of an adult tongue and to find no spindles. The Bielschowsky-

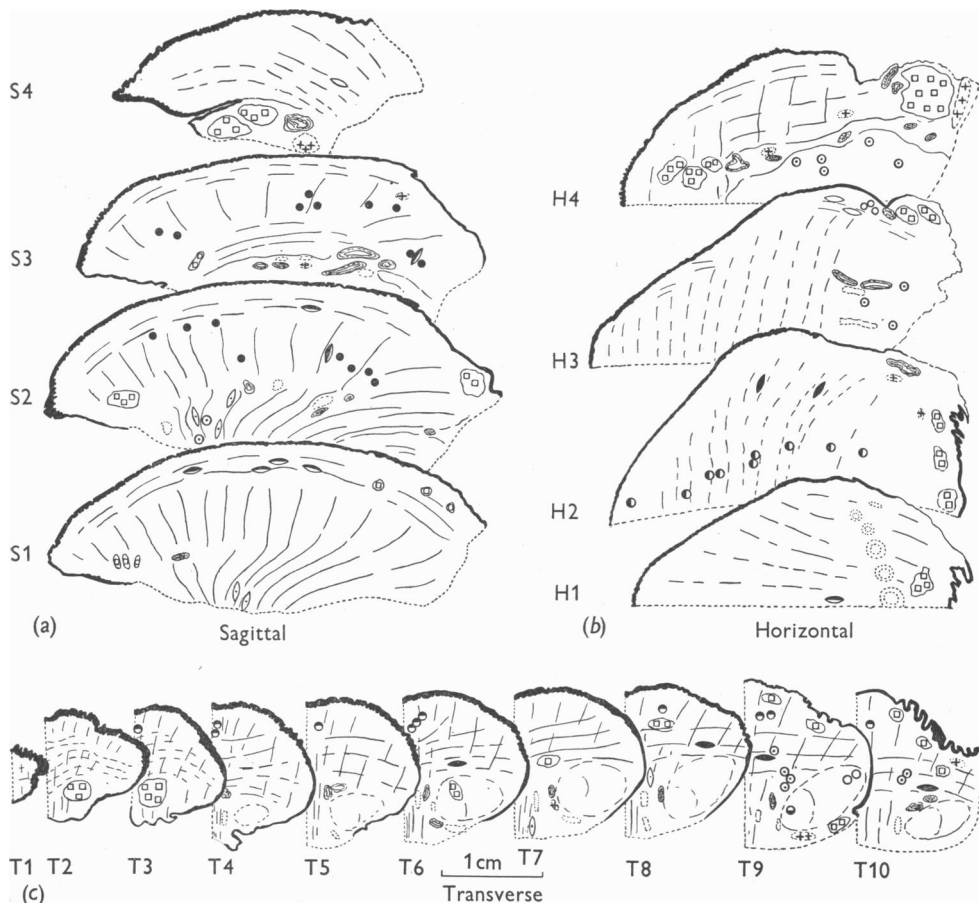
Gros staining revealed good specimens of spindles in the superior longitudinal muscle (Pl. 1, fig. 3), sometimes three or four spindles being seen in a single section taken fairly close to the mid-line. They lay below the upper surface of the tongue and just dorsal to the fibres of the transverse muscles. The spindles were about 1.0 mm or less in length and about  $100\mu$  in maximum diameter. The capsules were thin, but conformed with the typical spindle shape. Within the capsules slender striated muscle fibres were present and in some cases the groups of nuclei in the equator of a spindle were striking. The entry of nerve trunks through the capsule, the tangle of intrafusal nerve fibres at the equator and small nerve fibres going to endings on the intrafusal muscle fibres at the poles were all characteristic features of true muscle spindles.

In these parasagittal sections the fibres of the transverse muscles were seen in cross-section, and in certain regions small collections of muscle spindles in cross-section were seen. Again the spindles were of small diameter and their thin capsules did not make them particularly obvious (Pl. 1, fig. 4). Central nuclei in the intrafusal muscle fibres and encircling nerve fibres were the most recognizable features. These spindles were rarely seen near the tip of the tongue, they appeared to be collected a short way back from the tip and a second group occurred deep to the circumvallate papillae.

In the sections stained with silver the few spindles seen in the inferior longitudinal and vertical muscles were not enough to allow of generalization about their distribution. More spindles were seen later in these muscles in the paraffin sections. In the silver sections obvious spindles with thicker capsules were seen in those parts of the genioglossus muscles that enter the base of the tongue between the inferior longitudinal muscles.

In order to study the distribution of the muscle spindles in the tongue a series of paraffin sections was prepared and in Text-fig. 1*a-c*, diagrams are given traced from enlarged photographs of whole sections cut in the three planes of the tongue. The positions of cross-sections and longitudinal sections of muscle spindles found in these sections are indicated by circles and spindle-shaped symbols. Spindles seen in cross-section appear to be the more numerous but this is because the chances of finding them in cross-section are very much greater than of finding them in longitudinal section. A comparison of the positions of the spindles in each set of diagrams serves to elucidate their distribution in the whole tongue. The use of various markings within the symbols indicates the muscle in which each spindle was found.

The muscle spindles in the superior longitudinal muscle are most numerous near the mid-line, none is seen in the tip of the tongue or right at the back. Pl. 1, figs. 5 and 6, show photomicrographs of two of these spindles in cross-section. In the transverse muscle many spindles are indicated. They lie away from the mid-line and are found in the mid-region between the median septum and lateral border of the tongue or nearer the lateral border. Again no spindles



**Text-fig. 1.** Tracings from enlarged photographs of sections of babies' tongues. The general direction of the muscle fibres seen in longitudinal section, and the position of the main blood vessels, the nerve trunks and the glands are indicated. The sites of the muscle spindles are shown. (a) Four parasagittal sections, cut about 4 mm apart, from a half tongue. S1 is nearest to the mid-line. (b) Four horizontal sections cut about 4 mm apart. H1 is the uppermost section and the position of the circumvallate papillae is sketched in. (c) Ten transverse half sections cut about 4 mm apart. T1 is from the tip, T10 from near the root and a circumvallate papilla is seen. The scale applies to all three sets of drawings.

The sites of the muscle spindles are shown by circles for cross-sections and by spindle-shaped symbols for longitudinal sections. The muscles in which the muscle spindles lie are indicated by the markings given below, similar markings being used for the spindle-shaped symbols:

- Site of muscle spindle in the transverse muscle.
- ◐ Site of muscle spindle in the superior longitudinal muscle.
- ◑ Site of muscle spindle in the inferior longitudinal muscle.
- ◒ Site of muscle spindle in the vertical muscle.
- ◓ Site of muscle spindle in the extrinsic muscle.
- Site of muscle spindle, the muscle is uncertain.
- + Site of small collection of nerve cells.
- Site of glands.

were seen in the tip of the tongue; they lay, as was found with the silver sections, in two groups about a third and two-thirds of the way back through the tongue with odd spindles at the back of the tongue. Spindles were scarce in the inferior longitudinal muscle, the most likely place to find them being ventral to the circumvallate papillae. Such a one is indicated in Text-fig. 1 *c*, T9. Other spindles were found rather more laterally in this band of muscle at the base of the tongue, but they have not been assigned to any specific muscle, for they probably lie in the extrinsic muscles. In the sagittal and transverse sections it was not easy to find spindles in the vertical muscle, but on examining one of the horizontal sections, traced in Text-fig. 1 *b*, H2, a rather striking row of these organs with very small diameters was seen. Two such spindles are seen in Pl. 1, fig. 1. These spindles are assumed to be in the vertical muscle rather than in the insertion end of the genioglossus muscle, since a few occur in the tip of the tongue and the rest lie lateral to the main bulk of the genioglossus fibres. The spindles which undoubtedly lie in the genioglossus muscle are situated in the base of the tongue; they have a greater diameter and thicker capsules than those in the vertical muscle. A group of muscle spindles could always be found near the lateral edge of the tongue in its mid-region, such spindles being indicated in Text-fig. 1 *a*, S4, *b*, H3 and *c*, T9. It is not clear whether these spindles lie in the intrinsic or extrinsic muscles so the symbols have no specific marking.

There are also indicated by crosses, on the diagrams in Text-fig. 1, the places in which collections of nerve cells, amounting to small ganglia, were found. Such ganglia are indicated on the lingual nerve in the base of the tongue (Text-fig. 1 *a*, S4 and *c*, T9) and on the glossopharyngeal nerve just within the tongue (Text-fig. 1 *b*, H4). They were very common in these two positions and often contained many cells. Scattered nerve cells were frequently seen near nerves among the tongue muscles. No ganglia could be found on the hypoglossal nerve as it entered the base of the tongue.

#### *Animal tongues*

Some years ago Mr T. Marsland, Chief Technician of the Histological Department of the University Laboratory of Physiology, pointed out to me what he rightly took to be muscle spindles in the monkey's tongue, in class demonstration slides that he had prepared and stained with silver. During the course of the present work a set of parasagittal sections of a rhesus monkey's tongue was examined and numerous spindles were seen in cross-section in the transverse muscle. Spindles in longitudinal sections were not seen in the other intrinsic muscles, but only a few slides were examined. The most lateral sagittal section showed a small ganglion lying on the lingual nerve just within the base of the tongue.

Two kittens' tongues were examined in a series of transverse, parasagittal

and horizontal sections. No muscle spindles were seen. A striking feature of these sections was the number and size of the ganglia. Small groups of nerve cells were seen close to nerve fibres in all parts of the tongue and a very large collection of them lay along the branches of the lingual nerve for some way into the base of the tongue.

No spindles were seen in the intrinsic musculature of a new-born lamb's tongue, but one was found in the genioglossus muscle. Ganglia were again seen on the lingual and glossopharyngeal nerves, but not on the hypoglossal nerve, as they entered the tongue.

#### DISCUSSION

Though in this work no attempt was made to count the total number of muscle spindles in a complete human tongue, they are shown to be sufficiently numerous in certain positions to contribute to the proprioceptive sense of the tongue. This organ fulfils a number of functions, one of these being due to the presence of many sensitive touch endings. These endings are quick to send to the higher centres information about the position of the tongue and the state of the mouth and teeth. It has been shown by Carleton (1938) that paralysing these exteroceptive endings usually abolishes the sense of position of the tongue. This information has been used by this author as an argument that proprioceptive innervation may not exist in the tongue musculature. Weddell *et al.* (1940) consider that sensory endings at the origin of the genioglossus muscle are sufficient to explain any anomalous results about proprioceptors in the tongue.

A point on which we have very little information is the extent to which the impulses from the true muscle proprioceptors, such as muscle spindles and tendon organs, penetrate to the highest levels. Adrian (1941, p. 170) says that stretching a muscle in the cat's forelimb never gave more than a brief discharge in the cortex. Mountcastle, Covian & Harrison (1952, p. 364) state that 'direct stretch of muscle [in cats under sodium pentobarbital] does not elicit cortical responses if care is taken to avoid simultaneous excitation of deep receptors of the periosteum, or of adjacent tactile receptors'. Cooper, Daniel & Whitteridge (1953) found that the discharges set up on stretching the extrinsic eye muscles of the goat were greatly altered after crossing one or more synapses. They heard faint responses in the cortex near the visual area, but were unable to get records or to assess the latency of these discharges.

The extrinsic eye muscles and the intrinsic tongue muscles are peculiar in not being associated with joint movements, but they are associated with particularly sensitive exteroceptive systems, namely the retina of the eye and the touch endings of the tongue. These systems may provide information for the cortex, in relation to these muscles, which is used in a similar way to the information from the joints and periosteal endings in relation to the body musculature. The duty of the muscle proprioceptors is to keep the co-ordinating

centres of the brainstem and spinal cord informed about the state of the muscles, so that the latter are ready to respond both in the performance of the lower reflexes and to the demands of voluntary movements. The information from the muscles is probably largely or entirely dealt with at subcortical levels. If this is so, it is illogical to expect consciousness of the tongue's position when the exteroceptive endings have been put out of action.

The distribution of muscle spindles in the intrinsic muscles of the human tongue is interesting. They were found to be few in number in the tip, but numerous in a region proximal to the tip. The tip itself is richly supplied with touch endings, but the most flexible part of the human tongue is a short way proximal to the tip; it is this part that brings about the delicate movements of the tip needed for touching, tasting and speaking. It is just in this flexible part that the greatest number of spindles has been found in this survey. This is particularly true for the superior longitudinal and the transverse muscles which appear to be the most richly supplied. In the inferior longitudinal muscle and in the muscles near the lateral border the spindles lay somewhat further back in the tongue in that part that curves most in the fine lateral movements. The spindles in the vertical muscle occurred fairly far forward in the tongue in those muscle bundles that must be active in any movement which flattens the tongue or curls up the lateral edges.

The intrinsic muscles of the tongue receive their motor innervation from the hypoglossal nerve. This nerve may therefore carry the afferent impulses from the muscles; but the hypoglossal, like several other cranial nerves, has no obvious dorsal roots or dorsal root ganglia to point out the sensory pathway into the brainstem. Sensory type cells may occur scattered along the nerve proximal to the tongue (Tarkhan & Abd El-Malek, 1950), or collected into the small Froriep's ganglion which is analogous to the dorsal root ganglia; but the exact number and position of these cells differ in various species. In man, Pearson (1945) has shown that there are numerous sensory type cells belonging to the hypoglossal nerve and having an intramedullary position near the inferior olive. These may well be the cells of origin of the muscle spindle sensory endings in the human tongue.

Ganglion cells also occur in the tongue itself, as has been known for many years. They are illustrated by a good photomicrograph (taken by Hoen) in Barker (1899). Gairns & Garven (1952) have recently taken up the study of these cells and are doing further work on them. It is not yet known definitely whether any of them belong to the hypoglossal nerve. Ernyei (1937) associates them with the lingual and glossopharyngeal nerves. Kane (1952) says that in the pig many of them lie near the glossopharyngeal nerve.

The few observations made in the present work on man, monkey, cat and lamb suggest that the ganglion cells are certainly related to the lingual and glossopharyngeal nerves, none being found near the hypoglossal trunks. It is

impossible to assign many of the cells within the tongue to the lingual or hypoglossal nerves without degeneration experiments, since small branches of the former nerve have to pass through the muscle bundles to reach the epithelium and glands. The large number of ganglion cells in the cat's tongue was noted by Laruelle & Reumont (1936). They found that the cells were definitely altered by section of the lingual nerve but were unaffected by cutting the hypoglossal nerve.

It must not be lost sight of that, through the lingual nerve, the tongue has very rich afferent connexions with the fifth cranial nerve complex, and it is possible that some proprioceptors of the tongue send their messages to the brainstem by this nerve as suggested by Barron (1936). He based his evidence on the fact that he could detect no impulses in the cat's hypoglossal nerve on stretching the tongue. My own work does not confirm this, for I have found on cutting down some of the nerve bundles to the intrinsic muscles of the cat's tongue that I have been able to record electrically from units which give a sustained response to gentle stretch of the tongue. The issue is probably complicated by the great number of motor fibres and by finding the adequate direction of pull in an organ with muscle fibres running in such differing directions. Further work is in progress and will be reported elsewhere.

The presence of muscle spindles in the tongues of some species and their absence in the tongues of others presents the same problem as is met with in the case of the extraocular muscles (Cooper & Daniel, 1949). It is of further interest that the species are not the same in the two cases, spindles are present in the intrinsic tongue muscles of man and rhesus monkey, but absent from the same muscles in cats and lambs. They are present in the extraocular muscles of man and goats, but absent from these muscles in rhesus monkeys and cats. This certainly points to the danger of generalization on the distribution of these organs in mammals.

It is not always realized that other endings may act as low-threshold stretch receptors, since it is certainly possible to get responses from the fibres of the cat's third nerve on stretching an extraocular muscle in spite of the absence of muscle spindles in these muscles (Cooper & Fillenz, 1952). There are many endings in the small-fibred richly innervated muscles like the eye and tongue muscles that do not conform in structure with the generally accepted sensory endings. The simple nerve spirals found round the muscle fibres of human extraocular muscles are a case in point (Daniel, 1946). Further histological work may well reveal other atypical sensory endings in the intrinsic tongue muscles of those animals without spindles in these muscles. The present work proves that man has a good supply of the recognized low-threshold stretch receptors, the muscle spindles, in his tongue.



## SUMMARY

1. The presence of muscle spindles is confirmed histologically in the intrinsic muscles of the human tongue and the distribution of these organs in the four groups of intrinsic muscle fibres is given.

2. Muscle spindles are present in the intrinsic tongue muscles of the monkey, but they have not been seen in these muscles in the cat and lamb.

3. The pathway for the afferent impulses from these organs is thought to lie in the hypoglossal nerve and to be unrelated to the sensory type ganglion cells found in the tongue.

4. The part the muscle spindles play as the proprioceptors of the tongue is discussed.

I have to thank my colleagues, P. M. Daniel and F. D. Bosanquet, for supplying me with the tongues, and E. H. Leach for help in taking the photomicrographs. Mr T. Marsland, Mr A. Austin and Mr R. Beesley gave me much photographic and technical assistance.

## REFERENCES

- ABD-EL-MALEK, S. (1939). Observations on the morphology of the human tongue. *J. Anat., Lond.*, **73**, 201-210.
- ADRIAN, E. D. (1941). Afferent discharges to the cerebral cortex from peripheral sense organs. *J. Physiol.* **100**, 159-191.
- BARKER, L. F. (1899). *The Nervous System and its Constituent Neurones*. London: Hirschfeld Bros.
- BARRON, D. H. (1936). A note on the course of the proprioceptor fibres from the tongue. *Anat. Rec.* **66**, 11-15.
- BOYD, J. D. (1937). Proprioceptive innervation of mammalian tongue. *J. Anat., Lond.*, **72**, 147-148.
- BOYD, J. D. (1941). The sensory component of the hypoglossal nerve in the rabbit. *J. Anat., Lond.*, **75**, 330-345.
- CARLETON, A. (1938). Observations on the problem of the proprioceptive innervation of the tongue. *J. Anat., Lond.*, **72**, 502-507.
- CECCHERELLI, G. (1908). Contributo alla conoscenza delle espansioni nervose di senso nella mucosa del cavo orale e della lingua dell'uomo. *Int. Mschr. Anat. Physiol.* **25**, 273-350.
- COOPER, S. & DANIEL, P. M. (1949). Muscle spindles in human extrinsic eye muscles. *Brain*, **72**, 1-24.
- COOPER, S., DANIEL, P. M. & WHITTERIDGE, D. (1953). Nerve impulses in the brainstem and cortex of the goat. Spontaneous discharges and responses to visual and other afferent stimuli. *J. Physiol.* **120**, 514-527.
- COOPER, S. & FILLENZ, M. (1952). Afferent discharges from the extrinsic eye muscles of the cat. *J. Physiol.* **118**, 49 P.
- DANIEL, P. (1946). Spiral nerve endings in the extrinsic eye muscles of man. *J. Anat., Lond.*, **80**, 189-193.
- ERNYEI, S. (1937). Ein Beitrag zur Kenntnis der Nerven und Ganglien der Zunge. *Anat. Anz.* **83**, 274-281.
- FORSTER, L. (1894). Zur Kenntnis der Muskelspindeln. *Virchows Arch.* **137**, 121-154.
- FRANQUÉ, O. VON (1891). Beiträge zur Kenntnis der Muskelknospen. *Verh. phys.-med. Ges. Würzb.* **24**, 19-48.
- GAIENS, F. W. & GARVEN, H. S. D. (1952). Ganglion cells in the mammalian tongue. *J. Physiol.* **118**, 53-54 P.
- KANE, F. (1952). The nerve cells of the pig's circumvallate papilla. *J. Physiol.* **118**, 62-63 P.
- LANGWORTHY, O. R. (1924a). A study of the innervation of the tongue musculature with particular reference to the proprioceptive mechanism. *J. comp. Neurol.* **36**, 273-297.

- LANGWORTHY, O. R. (1924*b*). Problems of tongue innervation: course of proprioceptive nerve fibers, autonomic innervation of skeletal musculature. *Johns Hopk. Hosp. Bull.* **35**, 239-246.
- LARUELLE, L. & REUMONT, M. (1936). L'appareil neuro-ganglionnaire de la langue. *C.R. Ass. Anat.* **31**, 230-238.
- MOUNTCASTLE, V. B., COVIAN, M. R. & HARRISON, C. R. (1952). The central representation of some forms of deep sensibility. *Res. Publ. Ass. nerv. ment. Dis.* **30**, 339-370.
- PEARSON, A. A. (1945). Further observations on the intramedullary sensory type neurons along the hypoglossal nerve. *J. comp. Neurol.* **82**, 93-100.
- SHERINGTON, C. S. (1894). On the anatomical constitution of nerves of skeletal muscles; with remarks on recurrent fibres in the ventral spinal nerve-root. *J. Physiol.* **17**, 211-258.
- TARKHAN, A. A. (1936). Ein experimenteller Beitrag zur Kenntnis der proprioceptiven Innervation der Zunge. *Z. Anat. EntwGesch.* **105**, 349-358.
- TARKHAN, A. A. & ABD EL-MALEK, S. (1950). On the presence of sensory nerve cells on the hypoglossal nerve. *J. comp. Neurol.* **93**, 219-228.
- WEDDELL, G., HARPMAN, J. A., LAMBLEY, D. G. & YOUNG, L. (1940). The innervation of the musculature of the tongue. *J. Anat., Lond.*, **74**, 255-267.

### EXPLANATION OF PLATE

- Fig. 1. Horizontal section of a baby's tongue, about 6 mm below the dorsal surface, showing the fibres of the transverse muscle in longitudinal section and the fibres of the vertical muscle in cross-section. Note two muscle spindles, indicated by arrows, in the vertical muscle. (Paraffin section, Van Gieson stain.)
- Fig. 2. Transverse section of tongue of child with amyoplasia congenita, taken from the mid-region. Note two muscle spindles seen in longitudinal section in the transverse muscle. Each spindle has a small nerve trunk entering its capsule. (Thick frozen section, Bielschowsky-Gros silver stain.)
- Fig. 3. Parasagittal section of baby's tongue. The equator of a muscle spindle is seen in longitudinal section lying parallel to the fibres of the superior longitudinal muscle. Above the spindle are fibres of the vertical muscle. Note the outline of the spindle capsule, the small striated intrafusal muscle fibres, nerve fibres in the upper left-hand part of the spindle and densely stained groups of nuclei in the intrafusal muscle fibres. (Thick frozen section, Bielschowsky-Gros silver stain.)
- Fig. 4. Parasagittal section of baby's tongue showing cross-sections of muscle fibres belonging to the transverse muscle and longitudinal sections of fibres of the vertical muscle. A small muscle spindle is seen in cross-section in the transverse muscle. Note encircling nerve fibres in the thin capsule and intrafusal muscle fibres with central nuclei. (Thick frozen section, Bielschowsky-Gros silver stain.)
- Fig. 5. Transverse section of baby's tongue taken some 2 cm from the tip (total length of tongue 3.5 cm). A muscle spindle in cross-section is seen in the superior longitudinal muscle. The field is close to the median septum of the tongue. Note the thin capsule of the spindle and the septum which separates three of the intrafusal muscle fibres from the main periaxial space of the spindle; this suggests that the section is through the pole of the spindle. One of the intrafusal muscle fibres shows a very prominent central nucleus. (Paraffin section, haematoxylin and eosin.)
- Fig. 6. Transverse section of baby's tongue taken near the circumvallate papillae. A muscle spindle, seen in cross-section, lies in the superior longitudinal muscle and among some of the glands in the dorsum of the tongue. Note the thin capsule of the spindle with a small nerve trunk just outside its upper border. There are seven or more intrafusal muscle fibres, the lower large one has a central nucleus, the two upper large ones are packed with nuclei showing that the section is from the equatorial region of the spindle. Glands are seen on the left of the spindle. Extrafusal fibres of the superior longitudinal muscle are seen in the upper right-hand corner and fibres of the vertical muscle in the lower right-hand corner. (Paraffin section, haematoxylin and eosin.)

