

## CASE REPORTS

## Whipple's disease complicated by a retinal Jarisch-Herxheimer reaction: a case report

R J Playford, E Schulenburg, C S Herrington, H J F Hodgson

### Abstract

A 36 year old white man was diagnosed as having Whipple's disease after a prolonged illness of lethargy, night sweats, and weight loss associated with lymphadenopathy and splenomegaly. Biopsy specimen of an inguinal lymph node confirmed the presence of periodic acid Schiff positive macrophages and culture gave a pure growth of *Corynebacterium jeikeium*. Twelve hours after the introduction of oral co-trimoxazole and streptomycin the patient's condition deteriorated. He became confused, feverish, and developed florid retinal vasculitis with associated visual impairment. Both the systemic symptoms and the retinal vasculitis responded to treatment with corticosteroids and his vision returned to normal. We think this was a Jarisch-Herxheimer reaction not previously described in Whipple's disease and advise inspection of the fundi of such patients before starting treatment.

Whipple's disease or intestinal lipodystrophy is a multisystem disorder which was originally described in 1907 by G H Whipple.<sup>1</sup> Although it is rare, it is important to recognise cases as this once universally fatal disease can be effectively treated by prolonged courses of antibiotics.<sup>2</sup> Periodic acid Schiff (PAS) positive macrophages and the presence of coccobacilli within affected tissues remain the histological gold standard for diagnosis.<sup>3</sup> Whether the disorder is caused by a single type of bacteria, however, or an underlying poorly defined host immune defect that allows a variety of bacteria to cause damage remains unclear.<sup>4</sup>

We report a patient whose clinical course and investigation presented a number of unusual features which have important clinical implications.

### Case report

A 36 year old man first presented to hospital in 1986 with a six month history of lethargy, night sweats, and weight loss of seven pounds despite normal appetite.

On examination he seemed well and did not have a fever. He had palpable shotty lymph nodes in both axillae and groins, and his liver and spleen were both just palpable. Cardiovascular, respiratory, and neurological examination were

normal. Laboratory investigations showed the following: full blood count, urea, creatinine, and liver function tests were all normal; erythrocyte sedimentation rate was slightly raised at 19 (normal <10) mm/hour; immunoglobulins, autoantibodies, serum angiotensin converting enzyme (ACE), and Bence-Jones protein were all normal or negative. Chest x ray showed slightly increased shadowing in the right perihilar region and a small right pleural effusion. Bronchoscopy showed mild inflammation of the lung parenchyma. Transbronchial biopsies were performed and specimens showed slight alveolar wall thickening and a light lymphocytic infiltration, and a region suggestive of a granuloma was also identified. Liver and inguinal node biopsy specimen also showed non-caseating granuloma. Staining for acid fast bacilli was negative but no PAS stain was performed. Kveim test was negative. No firm diagnosis was established but a presumptive diagnosis of sarcoidosis was made and no medication was prescribed.

Over the next three months the patient's general condition worsened - he continued to lose weight and now complained of abdominal distension and steatorrhoea. He was then referred to the Hammersmith Hospital for further investigation. Examination now showed 6 cm hepatomegaly and 8 cm splenomegaly, with a 'doughy' feel on abdominal palpation. Visual fields and fundal examination were normal. Laboratory investigation showed a microcytic anaemia (haemoglobin 10.7 g/dl (normal 13.5-17.5), red cell volume 77 fl (normal 80-99), white blood count  $9.5 \times 10^9/l$  (normal 4-11) with evidence of malabsorption; albumen 28 g/l (normal 35-55), zinc  $10.5 \mu\text{mol/l}$  (normal 11.5-20), and iron  $5.8 \mu\text{mol/l}$  (normal 14.3-36). The inflammatory indices were raised; erythrocyte sedimentation rate 60 mm/hour (normal <10) and C reactive protein 99 mg/l (normal <10). Small bowel enema showed thickened mucosal folds, and a jejunal biopsy specimen gave the typical appearance of Whipple's disease. Repeat lymph node biopsy specimen again showed granuloma and the presence of PAS positive material, in keeping with Whipple's disease. Culture of part of the node showed a pure growth of *Corynebacterium jeikeium* which was fully sensitive to penicillin, tetracycline, and gentamicin.

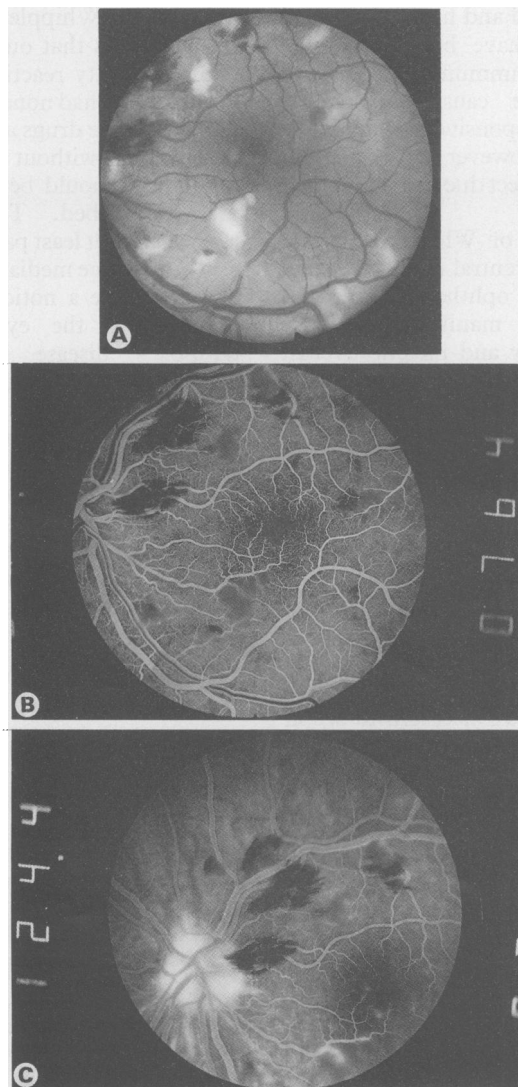
The patient was begun on co-trimoxazole (four tablets, twice daily) and streptomycin (1 g intramuscularly daily) as he was allergic to

Gastroenterology and  
Ophthalmology Units,  
Royal Postgraduate  
Medical School,  
Hammersmith Hospital,  
London

R J Playford  
E Schulenburg  
C S Herrington  
H J F Hodgson

Correspondence to:  
Dr R Playford,  
Gastroenterology Unit, Royal  
Postgraduate Medical School,  
Hammersmith Hospital,  
London W12 0NN.

Accepted for publication  
25 March 1991



(A) Multiple superficial and deep retinal haemorrhages with scattered 'cotton wool spots.' (B) Retinal fluorescein angiogram showing the early venous phase with areas of capillary closure nasal to and below the avascular macular zone. (C) Later retinal fluorescein angiogram showing dye leakage from these areas of capillary non-perfusion.

penicillin. Twelve hours after the first dose of antibiotics, however, he felt unwell and developed a fever of 38°C. Over the next 24 hours his condition deteriorated, he felt increasingly confused and had feelings of 'deja vu.' Visual acuity was 6/12 in each eye. Fundal examination now showed bilateral multiple deep and superficial retinal haemorrhages with 'cotton wool spots' in keeping with a retinal vasculitis (Figure A). Fluorescein angiography showed minimal leakage (Figure B and C). Cranial computed tomogram showed no focal lesions and lumbar puncture was performed. This showed an opening pressure of 75 mm cerebrospinal fluid (normal), no red or white blood cells, and no organisms. Electroencephalogram showed an abnormal focus in the right temporal region in keeping with temporal lobe epilepsy and a noticeable generalised disorganisation with a dominant slow rhythm in the rest of the brain. Cultures of blood and urine were sterile and a full blood count showed a white blood count of  $13.5 \times 10^9$  (normal 4–11). We considered that the patient's deterioration was due to a Jarisch-Herxheimer reaction and started him on prednisolone (30 mg once daily) and carbamazepine (200 mg twice daily). The co-trimoxazole was also reduced (two tablets twice daily).

The patient's general condition improved, and

after two weeks' treatment the antibiotic regimen was changed to oxytetracycline (250 mg four times daily) for three months followed by doxycycline (100 mg once daily, long term). After one month's treatment the retinal vasculitis had improved considerably with only an occasional haemorrhage seen. Visual acuity was now 6/9 in the right and 6/6 in the left eye. The corticosteroid dose was gradually reduced to zero over two months and the carbamazepine reduced to zero over six months without any deterioration. He remains well on doxycycline three years later and a recent jejunal biopsy specimen showed no evidence of atrophy, with scanty PAS positive macrophages.

### Discussion

This patient shows the ease in making the diagnosis of Whipple's disease once the typical features of malabsorption and weight loss are present. Until the abdominal features appear, diagnosis may be delayed unless it is considered as a specific possibility. Review of the histology of the lymph node taken previously from our patient showed that PAS positive material was present and could have led to the diagnosis being made three months earlier. Patients with Whipple's disease as their primary diagnosis may present to virtually any medical clinic such as rheumatology with symptoms of arthropathy, neurology with primary central nervous system involvement, or a respiratory clinic, as in our patient, with symptoms suggestive of sarcoidosis or tuberculosis, when the diagnosis is much less likely to be considered. In fact, delay in diagnosis seems to be the norm, as Enzinger found that over half the patients had symptoms attributable to Whipple's disease for at least five years before diagnosis.<sup>5</sup>

The good response to a variety of antibiotics and the presence of a cocco-bacillus within affected tissues has led to the general acceptance that a bacterium is important in the pathogenesis of this disease. It is unclear whether there is a single 'Whipple's bacillus' or if several different organisms are involved. We isolated a pure growth of *C. jejikeium* from the lymph node of our patient and it is of interest that we isolated a pure growth of the closely related *C. bovis* from the last patient presenting to our hospital with Whipple's disease.<sup>6</sup> Caroli *et al* also isolated a *Corynebacterium* from the lymph node and small intestine of a patient.<sup>7</sup> However, it was a different species from those present in our patients. Other workers have identified *Streptococci* or *Haemophilus* from lymph nodes or small intestine culture.<sup>8,9</sup> It is therefore important that any patient with suspected Whipple's disease has tissue sent for culture to establish whether one or several organisms are responsible for this disease.

It has also been suggested that there may be an underlying immune defect in these patients which allows a bacterium with low pathogenicity to infect the tissues. *C. jejikeium*, the organism found in our patient, is usually only found in patients who are immunosuppressed or have been hospitalised and on a range of antibiotics for long periods.<sup>10</sup> Our patient had only been in

hospital for a short period and had not received any antibiotics. There have been reports of impaired cell mediated immunity in patients with Whipple's disease causing cutaneous anergy and decreased responsiveness to phyto-mitogens.<sup>4</sup> It is unclear, however, whether this is a primary or secondary effect due to malnutrition or chronic infection.

Ocular manifestations of Whipple's disease are usually secondary to central nervous system involvement and include ophthalmoplegia and nystagmus.<sup>11</sup> Intraocular manifestations have been reported only rarely and include uveitis, vitreous opacities, and occasionally retinal vasculitis.<sup>11,12</sup> It is likely that the pathogenesis of intraocular involvement is either an immune mechanism causing a hypersensitivity reaction or, alternatively, direct damage to the ocular tissue caused by the organism. Evidence in favour of a hypersensitivity reaction as a cause is the identification of circulating rhamnose binding antibodies against the organism and the presence of circulating immune complexes.<sup>6</sup> There is also evidence, however, for direct invasion of the eye by the organism. Font reported a case of Whipple's disease with ocular involvement including retinal haemorrhages and necropsy studies subsequently showed the presence of rod shaped organisms in the retina.<sup>13</sup>

The Jarisch-Herxheimer reaction occurs in a mild form within a few hours of starting treatment in over half the patients with early syphilis.<sup>14</sup> It usually takes the form of fever, sweating, headache, and a temporary exacerbation of the symptoms of the disease. Much more severe forms of Jarisch-Herxheimer reaction are seen when treating louse borne relapsing fever and may result in cardiovascular collapse and death.<sup>15</sup> It seems likely that the mechanism inducing the reaction is endotoxin release caused by the death of the organisms.<sup>16</sup> Histological studies of Jarisch-Herxheimer reactions in syphilitic patients have shown increased congestion of the capillaries and small blood vessels with infiltration of neutrophils into the affected tissues.<sup>14</sup>

Our patient deteriorated rapidly upon starting treatment – suffering potentially sight threatening ocular complications as well as the onset of temporal lobe epilepsy. We consider that it was probably the result of a Jarisch-Herxheimer reaction because of its close relation to starting antibiotics. Although Jarisch-Herxheimer reactions are common in syphilitic patients, we are not aware of any previous reports of these in a

patient with Whipple's disease. An alternative explanation is that our patient suffered a drug hypersensitivity reaction, but we consider this unlikely as he had none of the more common side effects of these drugs and continued on the same medication without further deterioration, although it should be noted that steroids were later prescribed. This rapid deterioration suggests that at least part of the damage to tissues may be immune mediated and the retinal appearances do have a noticeable similarity to lupus vasculitis of the eye. Previous reports of Whipple's disease affecting the posterior chamber of the eye do not have any relation to starting antibiotics, involvement occurring before the start of treatment or relapse involving the eye occurring several months later.<sup>12</sup>

Because of the potentially sight threatening nature of our patient's deterioration on starting antibiotics, we advise clinicians to request patients to report any visual changes upon starting treatment and consider regular fundal examination mandatory.

We thank the MRC for funding RJP as a Training Fellow.

- Whipple GH. A hitherto undescribed disease characterised anatomically by deposits of fat and fatty acids in the intestinal and mesenteric lymphatic tissues. *Johns Hopkins Med J* 1907; 18: 382-91.
- Mischke LW, Bluncke S, Fische D, Kuchemann K, Schuler HW, Grozinger KH. Whipple's disease: etiopathogenesis, treatment, diagnosis and clinical course. Case report and review of the world literature. *Acta Hepato-Gastroenterol* 1974; 21: 307-26.
- Black-Schaffer B. Tinctoral demonstration of glycoprotein in Whipple's disease. *Proc Soc Exp Biol Med* 1949; 72: 225-7.
- Dobbins WO. Is there an immune deficit in whipple's disease? *Dig Dis Sci* 1981; 26: 247-52.
- Enzinger FM, Helwig EB. Whipple's disease: A review of the literature and report of fifteen patients. *Virchows Arch (Pathol Anat)* 1963; 336: 238-69.
- Gupta S, Pinching AJ, Onwubalili J, Vince A, Evans DJ, Hodgson HJF. Whipple's disease with unusual clinical, bacteriologic, and immunologic findings. *Gastroenterology* 1986; 90: 1286-9.
- Caroli J, Julien C, Eteve J, Prevot AR, Sebald M. Trois cas de maladie de Whipple. *Sem Hop Paris* 1963; 39: 1457-80.
- Charache P, Bayless TM, Shelley WM, et al. Atypical bacteria in Whipple's disease. *Trans Assoc Am Physicians* 1966; 79: 399-408.
- Tytgat GN, Hoogendijk J, Agenant D, Schellekens P Th. Etiopathogenic studies in a patient with Whipple's disease. *Digestion* 1977; 15: 309-21.
- Parker MJ, Collier LH, eds. *Principles of Bacteriology virology and immunity*. 8th ed. London: Edward Arnold, 1990: 76.
- Leland TM, Chambers JK. Ocular findings in Whipple's disease. *South Med J* 1978; 71: 335-8.
- Avila MP, Jalkh AE, Feldman E, Trempe CL, Schepens CL. Manifestations of Whipple's disease in the posterior segment of the eye. *Arch Ophthalmol* 1984; 102: 384-90.
- Font RL, Rao NA, Issarescu S, McEntee WJ. Ocular involvement in Whipple's disease: Light and electronic microscopic observation. *Arch Ophthalmol* 1978; 96: 1431-6.
- Anonymous. Jarisch-Herxheimer reaction [Editorial]. *BMJ* 1967; i: 384.
- Anonymous. The Jarisch-Herxheimer reaction [Editorial]. *Lancet* 1977; i: 340-1.
- Gelfand JA, Elin RJ, Berry FW, Frank MM. Endotoxaemia associated with the Jarisch herxheimer reaction. *N Engl J Med* 1976; 295: 211-3.