

Mucin associated Tn and sialosyl-Tn antigen expression in colorectal polyps

S H Itzkowitz, E J Bloom, T-S Lau, Y S Kim

Abstract

Sialosyl-Tn antigen and its immediate precursor, Tn antigen, are carbohydrate structures associated with the earliest steps of mucin O-linked glycosylation. Both antigens have been shown previously to be highly sensitive and specific markers of colorectal cancer. One hundred and three colorectal polyps (79 adenomatous; 24 hyperplastic) were examined for expression of Tn antigen using *vicia villosa* isolectin B4, and for sialosyl-Tn antigen by monoclonal antibody TKH2. Tn antigen was expressed by all of the polyps studied. Sialosyl-Tn, on the other hand was expressed weakly by a few cells in 7 of 24 (29%) hyperplastic polyps. Among the adenomatous polyps, 56% expressed sialosyl-Tn and expression correlated with larger adenoma size, greater villous component, and more severe grades of dysplasia. In individuals with two or more synchronous adenomas, the level of sialosyl-Tn expression within an adenoma was associated with the severity of cytological atypia. All the adenomas that contained a focus of invasive carcinoma expressed sialosyl-Tn. These results indicate that colorectal polyps manifest incomplete glycosylation, exposing antigens in the innermost region of mucin oligosaccharides. In addition, the correlation of sialosyl-Tn antigen expression with the adenoma-carcinoma sequence may make this a useful marker for studying malignant progression in the colon.

For years it has been known that mucin elaborated by colon cancers differs qualitatively from that of the normal colon.^{1,2} However, the potential role of mucin in the biology of the colon cancer cell, and the stage in tumorigenesis at which these alterations occur, are only recently being elucidated. As part of a continuing analysis of mucin-associated carbohydrate antigen expression in colorectal tissues, we have been investigating carbohydrate antigens that represent some of the initial steps in mucin O-linked glycosylation. The first step in mucin oligosaccharide synthesis involves the transfer of GalNAc to serine or threonine residues of the mucin polypeptide, forming the so called Tn antigen (GalNAc-O-ser/thr).³ This structure serves as a precursor for further glycosylation, such that if galactose is added to Tn, the T antigen (Gal β 1, 3GalNAc-O-ser/thr) is formed, whereas if sialic acid is added, this creates the sialosyl-Tn antigen (Sia α 2, 6GalNAc-O-ser/thr). In a previous study we reported that each of these three antigens is rarely, if ever, expressed in normal colon, whereas expression occurs in the vast majority of colon cancers.⁴ In another study that focused on T antigen expression, we

observed that 48% of hyperplastic polyps and 54% of adenomatous polyps reacted with monoclonal anti-T antibody, and in the adenomas, T antigen expression correlated with conventional histopathological parameters of malignant potential.⁵

With the recent availability of reagents that recognise Tn and sialosyl-Tn antigens, the present study aimed to elucidate the pattern of expression of these antigens in hyperplastic and adenomatous polyps and to determine whether expression might correlate with malignant potential in adenomas.

Methods

TISSUE SPECIMENS

A total of 103 polyps were obtained by endoscopic polypectomy. There were 24 hyperplastic polyps, each measuring less than 1 cm in diameter, and 79 adenomatous polyps with the following size distribution: ≤ 0.5 cm (n=12); 0.6–0.9 cm (n=35); 1.0–1.9 cm (n=24); and ≥ 2.0 cm (n=8). Using haematoxylin and eosin stained slides, polyps were classified as to histological type and grade of dysplasia according to the criteria of Konishi and Morson.⁶ Adenomas containing carcinoma in situ were grouped with those containing severe dysplasia. Six of the adenomas had a focus of invasive adenocarcinoma. Synchronous polyps occurred in five patients: four patients had two adenomas, and one patient had four adenomas plus a hyperplastic polyp.

All polyps were fixed in formalin, embedded in paraffin and cut into 4 μ m serial sections for immunohistochemical staining.

REAGENTS

Monoclonal antibody TKH2 (IgG1) was raised against ovine submaxillary mucin and recognises sialosyl-Tn antigen.⁷ Hybridoma supernatant was a generous gift from Professor Sen-itiroh Hakomori, Biomembrane Institute, Seattle, WA. The B4 isolectin of *vicia villosa* seeds specifically agglutinates Tn-exposed erythrocytes.⁸ Biotinylated isolectin B4 of *vicia villosa* agglutinin was obtained from Sigma Chemical Co St Louis, MO. Biotinylated rabbit anti-mouse IgG+IgA+IgM, streptavidin-peroxidase conjugate, normal mouse IgG1, and normal rabbit serum were purchased from Zymed Laboratories, South San Francisco, CA.

IMMUNOHISTOCHEMISTRY

Immunoperoxidase histochemistry was performed using a streptavidin-peroxidase

Gastrointestinal
Research Laboratory,
Department of Medicine,
and Department of
Biomathematical
Sciences, Mount Sinai
School of Medicine, New
York, USA
S H Itzkowitz
T-S Lau

Gastrointestinal
Research Laboratory, VA
Medical Center and
Department of Medicine,
University of California
Medical Center, San
Francisco, USA
E J Bloom
Y S Kim

Correspondence to:
Dr S Itzkowitz, Division of
Gastroenterology, Box 1069,
Mount Sinai Medical Center,
1 Gustave L. Levy Place,
New York, NY 10029, USA.

Accepted for publication
2 July 1991

technique with all steps conducted at room temperature as previously described.⁴ After deparaffinisation, slides were incubated with fresh 1% hydrogen peroxide in methanol for 10 minutes and then washed three times with buffered phosphate saline (PBS) (0.1 mol/l phos-

phate, 0.15 mol/l NaCl, pH 7.4). Next, normal rabbit serum (5% in PBS) was added for 20 minutes and blotted off. Slides were then incubated with monoclonal antibody TKH2 (1:10 solution of hybridoma supernatant) or biotinylated *vicia villosa* agglutinin (5 µg/ml) for 90 minutes and then washed three times. The slides that received TKH2 were then treated with biotinylated rabbit anti-mouse IgG+IgA+IgM (10 µg/ml in PBS) for 20 minutes and washed three times. All sections then received streptavidin-peroxidase conjugate (10 µg/ml) for 30 minutes followed by three washes. Finally, slides were reacted with 3,3' diaminobenzidine substrate for 10 minutes, rinsed with tap water, counterstained with methyl green, and mounted.

TABLE I Expression of Tn and Sialosyl-Tn antigens in colonic tissues

	Normal colon* (n=22)	Hyperplastic polyps (n=24)	Adenomatous polyps (n=79)	Cancer* (n=29)
Tn:	3 (14%)	24 (100%)	79 (100%)	21 (72%)
Sialosyl-Tn:	0	7 (29%)	44 (56%)	28 (96%)

*Data on normal colon and colon cancer taken from reference 4.

Negative controls consisted of substituting mouse IgG1 for monoclonal antibody TKH2 and preincubating biotinylated *vicia villosa* agglutinin with 0.2 mol/l GalNAc – both of which resulted in negative staining. Positive controls consisted of including an antigen-positive colon cancer slide with each assay. In addition, TKH2 often reacted with endothelial cells of mucosal blood vessels, which served as a useful internal positive control.

SCORING AND STATISTICAL ANALYSIS

Within each polyp, the percentage of antigen positive cells was estimated by examining each low power field (10× objective) containing adenomatous or hyperplastic colonic epithelium. To be scored as positive (as indicated in the Tables) a polyp had to exhibit antigen expression in at least 5% of cells. In adenomatous polyps, the relation of TKH2 reactivity (in cytoplasm or secretions) to adenoma size, histological type, and severity of dysplasia was analysed by logistic regression analysis. Slides were interpreted for antigen expression without knowledge of the final pathological diagnosis.

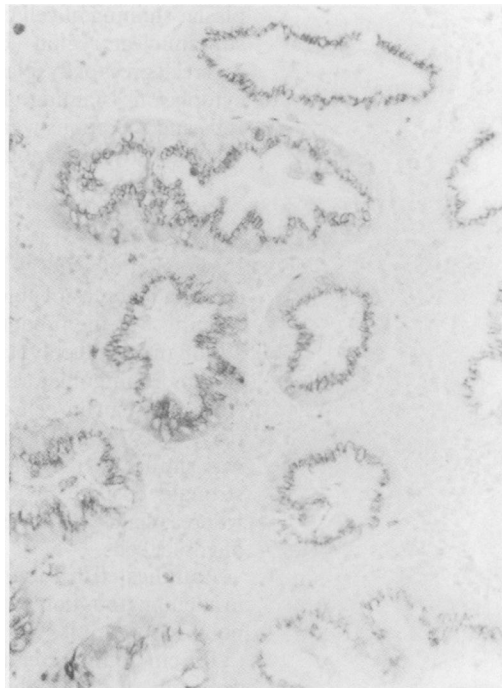


Fig 1A

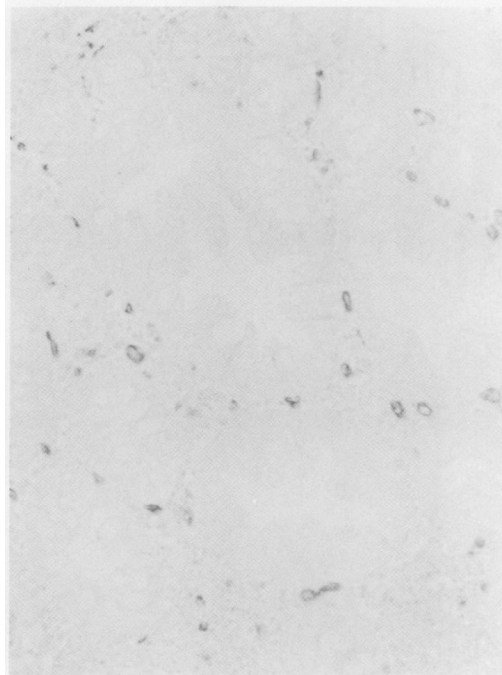


Fig 1B



Fig 1C

Figure 1: Expression of Tn and sialosyl-Tn antigens in hyperplastic polyps. (A) Tn is expressed in the supranuclear cytoplasm of cells in all of the hyperplastic glands (original magnification ×50). (B) Sialosyl-Tn is typically absent in the hyperplastic epithelial cells, but capillaries in the surrounding stroma are positive (×50). (C) A few hyperplastic polyps expressed sialosyl-Tn antigen, but only a small percentage of cells were positive (original magnification ×50).

Results

HYPERPLASTIC POLYPS

Tn antigen

All the 24 hyperplastic polyps reacted with *vicia villosa* agglutinin (Table I). As indicated in Figure 1A, Tn antigen expression was found predominantly in the supranuclear cytoplasm (Golgi region). In addition, goblet cells in normal looking crypts adjacent to hyperplastic polyps were strongly positive.

Sialosyl-Tn antigen

In contrast to Tn antigen, sialosyl-Tn was found in only 7 (29%) hyperplastic polyps (Table I).

Most hyperplastic polyps showed complete absence of sialosyl-Tn expression in the epithelial cells (Fig 1B). The few hyperplastic polyps that expressed sialosyl-Tn exhibited antigen expression in a small subpopulation of cells (Fig 1C). Goblet cells were negative. Curiously, mucosal blood vessel endothelial cells reacted with monoclonal antibody TKH2 in almost every case – a phenomenon also noted previously in normal colonic mucosa.⁴

ADENOMATOUS POLYPS

Tn antigen

All of the adenomatous polyps expressed Tn antigen (Table I). In adenomas with mild dysplasia, staining of cell cytoplasm occurred in the supranuclear region (Fig 2A), but with more severe degrees of dysplasia, cells exhibited diffuse cytoplasmic staining (Fig 2, B and C). Goblet cells and secretions were strongly positive in the vast majority of adenomas (Fig 2A).

Sialosyl-Tn antigen

Expression of sialosyl-Tn was noted in 44 of 79 (56%) adenomas (Table I). Diffuse cytoplasmic staining was the predominant pattern (Fig 3A), although several polyps displayed antigen expression more in goblet cell vacuoles and secretions (Fig 3B) than in cell cytoplasm. For the most part, the subcellular distribution of sialosyl-Tn was similar to that of Tn, except that Tn was strongly positive in most goblet cell vacuoles, whereas sialosyl-Tn was found in only a minority of goblet cells.

As indicated in Table II, sialosyl-Tn expression in adenomatous polyps was associated with larger polyp size. Of 12 diminutive adenomas (≤ 0.5 cm), only one exhibited sialosyl-Tn expression, whereas all eight adenomas over 2 cm in diameter were positive. Within each size cate-

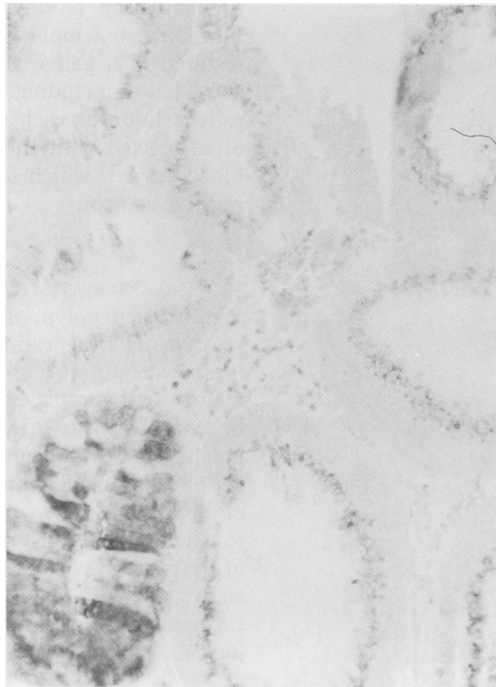


Fig 2A

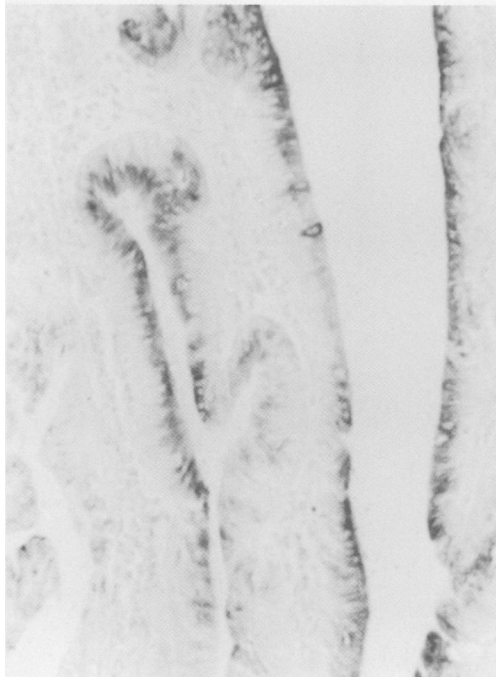


Fig 2B

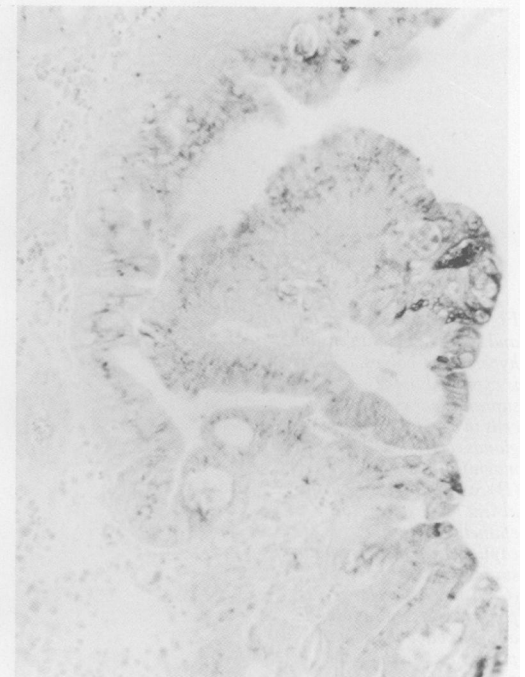


Fig 2C

Figure 2: Tn antigen expression in adenomatous polyps. (A) Tubular adenoma with mild dysplasia. Tn antigen is expressed primarily in the supranuclear region of adenomatous cells. Goblet cells within the polyp are also positive (gland at lower left) (original magnification $\times 50$). (B) Villous adenoma with moderate dysplasia demonstrating diffuse cytoplasmic expression of Tn antigen (original magnification $\times 50$). (C) Area of severe dysplasia in a tubulovillous adenoma. Supranuclear and diffuse cytoplasmic staining are present (original magnification $\times 50$).

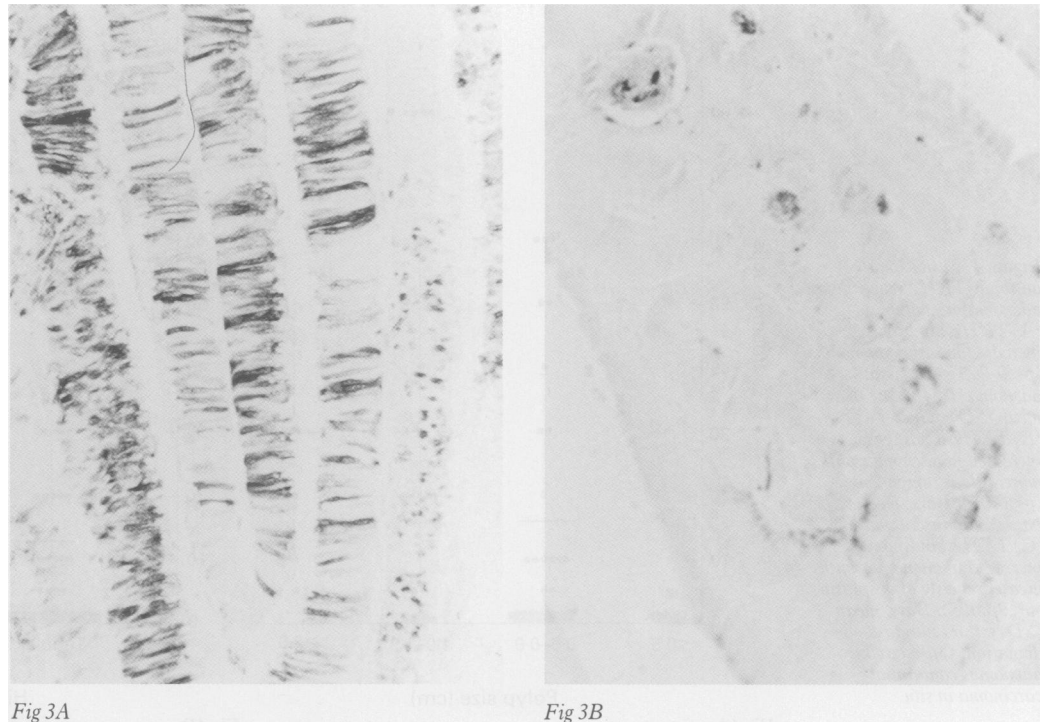


Figure 3: Sialosyl-Tn antigen expression in adenomatous polyps. (A) Villous adenoma with mild dysplasia demonstrating intense antigen expression diffusely in cell cytoplasm (original magnification $\times 50$). (B) Tubulovillous adenoma with severe dysplasia. Antigen expression is found in glandular secretions (original magnification $\times 50$).

gory, and for the entire group of adenomas, the percentage of positive cases was greater in adenomas with more villous histology and more severe grades of dysplasia. Conversely, within each histological subset and each category of dysplasia, the percentage of positive cases showed a direct correlation with increasing polyp size.

All of the villous adenomas and all but one of the adenomatous polyps with severe dysplasia or carcinoma in situ expressed sialosyl-Tn (Table II). Table III shows that for a given histological type, the percentage of positive cases increases according to the severity of dysplasia within the adenoma.

Not all the cells in a given adenomatous polyps express sialosyl-Tn. Therefore, Figure 4 depicts the estimated percentage of positive cells in each adenomatous polyps according to polyp size (Fig 4A), histological type (Fig 4B), and severity of dysplasia (Fig 4C). Within each of these three histopathological categories, there was considerable overlap in values among polyps of different subsets. However, within each category, there was a statistically significant increase in the percentage of positive cells according to increasing malignant potential. When all three histopathological categories were considered simultaneously, TKH2 reactivity correlated best with

dysplasia ($p < 0.005$) and adenoma size ($p < 0.05$), but not with histological type.

All six adenomas containing a focus of invasive carcinoma were sialosyl-Tn positive. However, the invading cancer cells were not always antigen positive.

The staining pattern of monoclonal antibody TKH2 in patients with synchronous polyps is shown in Table IV. This analysis demonstrated that even within a particular individual, the staining pattern of multiple polyps was not alike. In this group, it was the degree of dysplasia and not adenoma size or histological type that seemed to determine the level of sialosyl-Tn expression.

Discussion

Many studies have examined colorectal polyps for the expression of mucin species in general, using conventional mucin histochemical techniques,⁹ or particular carbohydrate structures on mucins, using monoclonal antibody or lectin immunohistochemistry.¹⁰⁻¹⁵ Generally, however, these studies have not focused on the expression of specific carbohydrate antigens in the innermost 'core' region of mucin O-linked oligosaccharides. In the present study two such antigens, Tn and sialosyl-Tn, were simultaneously examined in colorectal polyps because our previous study found these antigens to be highly sensitive and specific markers of colorectal cancer.⁴

TABLE II Sialosyl-Tn expression in adenomatous polyps according to size

	Size				Totals
	≤ 0.5 cm 1/12 (8%)	0.6-0.9 cm 18/35 (46%)	1.0-1.9 cm 17/24 (71%)	≥ 2.0 cm 8/8 (100%)	
Histological type:					
Tubular	1/10 (10%)	12/29 (41%)	11/14 (79%)	1/1 (100%)	25/54 (46%)
Tubulovillous	0/2 (0%)	3/3 (100%)	2/6 (33%)	5/5 (100%)	10/16 (63%)
Villous	-	3/3 (100%)	4/4 (100%)	2/2 (100%)	9/9 (100%)
Degree of dysplasia:					
Mild	1/11 (9%)	8/24 (33%)	8/14 (57%)	-	17/49 (35%)
Moderate	0/1 (0%)	5/5 (100%)	2/3 (67%)	2/2 (100%)	9/11 (82%)
Severe (cis)	-	5/6 (83%)	7/7 (100%)	6/6 (100%)	18/19 (95%)

cis=carcinoma in situ.

TABLE III Sialosyl-Tn expression in adenomas of different histological types

Histological type	Degree of dysplasia		
	Mild	Moderate	Severe (cis)
Tubular (n=54)	16/44 (36%)	4/4 (100%)	5/6 (83%)
Tubulovillous (n=16)	1/5 (20%)	2/4 (50%)	7/7 (100%)
Villous (n=9)	-	3/3 (100%)	6/6 (100%)

cis=carcinoma in situ.

Figure 4: Monoclonal antibody TKH2 reactivity in adenomatous polyps. (A) TKH2 binding is increased in larger adenomas ($p < 0.005$). Abscissa: adenoma size (in cm). Bars: mean (SD) values. (B) TKH2 binding is increased in adenomas with more villous component ($p < 0.01$). Bars (SD) values standard deviation. (C) TKH2 binding is increased in adenomas with greater severity of dysplasia ($p < 0.0005$). Bars: mean (SD) values standard deviation. Open circles: adenomas containing carcinoma in situ.

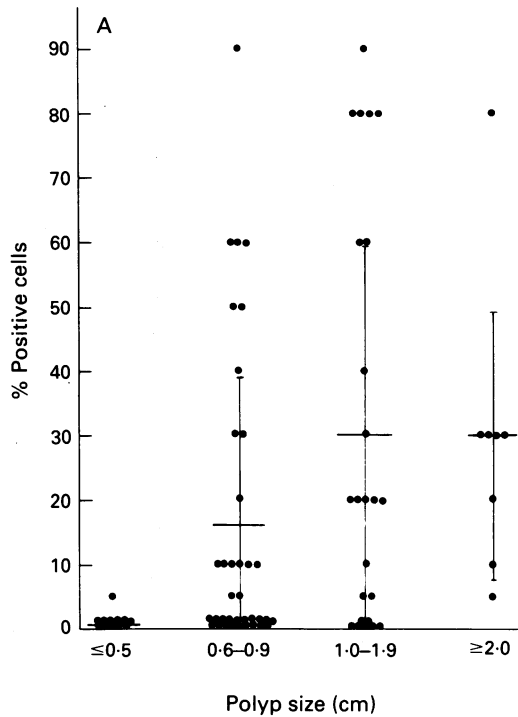


Fig 4A

Tn antigen was expressed by all hyperplastic and adenomatous polyps. Since hyperplastic polyps are believed to have no malignant potential,¹⁶ this finding would suggest that Tn antigen is not a good discriminant of malignant potential in polyps. However, it may be noteworthy that in adenomas, the cytological pattern of Tn antigen changed from a predominantly supranuclear (presumably Golgi) location to a diffuse intracytoplasmic pattern in accordance with increasing severity of dysplasia. Furthermore, the expression of Tn antigen in goblet cell vacuoles immediately adjacent to adenomatous and hyperplastic polyps is a pattern reminiscent of mucosa immediately adjacent to carcinomas but which was not seen in normal mucosa.⁴ Other investigators have also noted that *vicia villosa* agglutinin reacted with all hyperplastic and adenomatous polyps, with staining localised primarily to the supranuclear cytoplasm.¹⁷ However, in that study, *vicia villosa* agglutinin reac-

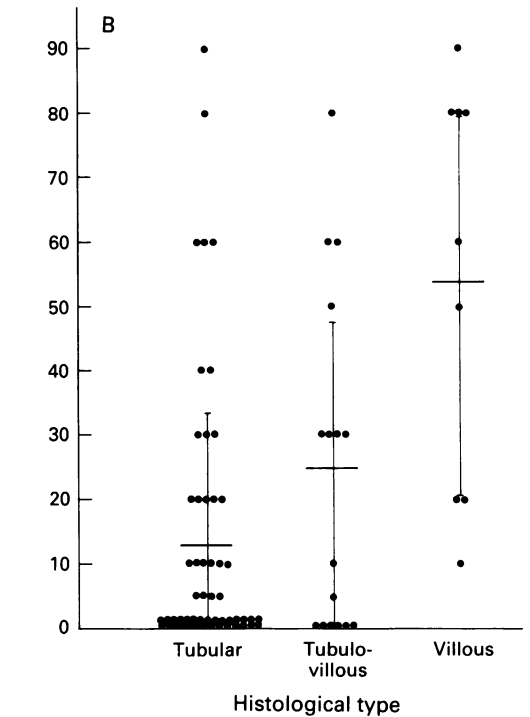


Fig 4B

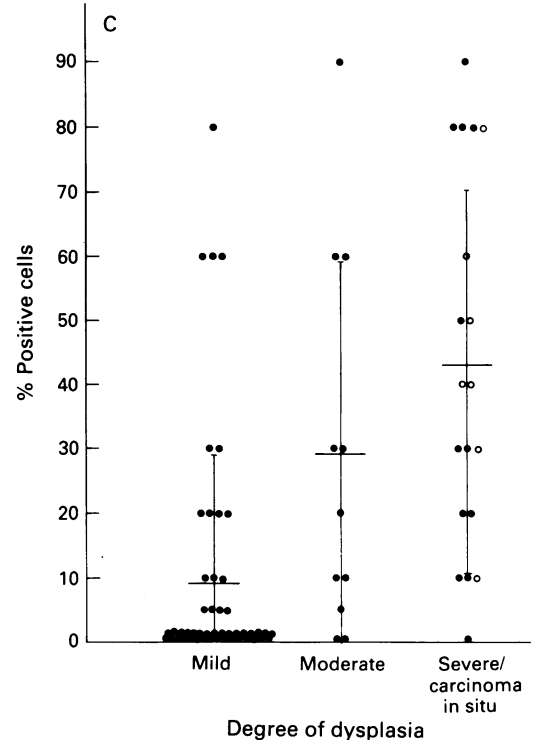


Fig 4C

TABLE IV Sialosyl-Tn expression in multiple polyps from the same individual

	Size (cm)	Histological type	Degree of dysplasia	Cytoplasm	Secretions
Patient A					
Adenoma 1	0.9	T	Mild	-	-
Adenoma 2	1.1	V	Severe	+++ (80)*	+(5)
Patient B					
Adenoma 1	1.0	T-V	Mild	-	-
Adenoma 2	0.9	T-V	cis	+++ (50)	-
Patient C					
Adenoma 1	0.5	T-V	Moderate	-	-
Adenoma 2	2.0	V	Severe	+++ (80)	+(10)
Patient D					
Adenoma 1	0.7	T	cis	+(40)	-
Adenoma 2	0.7	T	Severe	-	-
Patient E					
Adenoma 1	0.8	T	Mild	-	++ (10)
Adenoma 2	1.0	T	Mild	-	+(5)
Adenoma 3	0.8	T	Mild	-	+(20)
Adenoma 4	1.1	T	Mild	-	+(10)
Hyperplastic	0.9	NA	NA	-	-

T=tubular; T-V=tubulovillous; V=villous.
 *Staining intensity: - absent; + weak; ++ moderate; +++ strong.
 Numbers in parenthesis: estimated percentage of positive cells.
 NA=not applicable.

tivity was diminished in adenomas with carcinoma in situ and frank carcinomas.

Sialosyl-Tn, unlike Tn, did discriminate between hyperplastic and adenomatous polyps. Only a few hyperplastic polyps reacted with monoclonal antibody TKH2, and those that were positive usually exhibited weak staining intensity in only a few cells. Adenomatous polyps, on the other hand, expressed sialosyl-Tn in 56% of cases, and those that were positive were the larger, more villous, and more dysplastic adenomas. In fact, all adenomas over 2 cm in diameter, all villous adenomas, and all but one adenoma showing severe dysplasia or carcinoma in situ expressed sialosyl-Tn antigen. Thus, sialosyl-Tn antigen expression by adenomas

seems to be associated with their malignant potential. This is supported by the finding that in individuals with more than one adenoma, sialosyl-Tn expression correlated with the severity of cellular dysplasia. We have observed that sialosyl-Tn expression by colon cancer tissues was associated with a poor prognosis whereas individuals with sialosyl-Tn negative tumours had overall and disease free five year survival rates 100% and 94%, respectively.¹⁸ In addition, sialosyl-Tn expression is apparently increased in metastatic colon cancer cells.¹⁹ Thus, expression of sialosyl-Tn antigen seems to be a marker of malignant progression in the colon.

To our knowledge, no study, has examined sialosyl-Tn expression in colorectal polyps with monoclonal antibody TKH2. However, monoclonal antibody B72.3 has been used to stain colorectal polyps in a few studies.²⁰⁻²² In one study, only rare (<10% of cells) B72.3 reactivity was noted in 1/20 adenomas from patients with concomitant colon cancers, and in 5/18 adenomas from adenoma bearing patients.²⁰ However, in that study no villous adenomas were examined, and data concerning adenoma size and degree of dysplasia were not provided. Wolf *et al* reported monoclonal antibody B72.3 reactivity in 0/20 hyperplastic polyps and 13/81 (16%) adenomatous polyps, with staining associated only with tubulovillous or villous adenomas manifesting moderate or severe dysplasia.²¹ In contrast, Listrom *et al* found that 20/20 (100%) adenomatous polyps and 43/46 (96%) hyperplastic polyps reacted with monoclonal antibody B72.3.²² The discrepancies between the studies that have used B72.3 are difficult to explain, but could relate to differences in technique. In addition, although monoclonal antibody B72.3 has been shown to react with sialosyl-Tn antigen,^{7,23} recent data from the First International Workshop on Carcinoma-Associated Mucins (unpublished observations) indicates that this antibody also crossreacts with Tn antigen, whereas TKH2 used in the present study is specific for sialosyl-Tn.

Biochemical structural analysis of oligosaccharides on normal colonic mucin indicates that Tn and sialosyl-Tn antigens are frequently found as internal structures adjacent to the apomucin polypeptide.^{24,25} Typically, however, these normal oligosaccharides are several sugars in length, which presumably prevents the binding of lectins or monoclonal antibodies to the innermost structures. This might explain the lack of *vicia villosa* agglutinin or TKH2 binding to normal colonocytes. The present study, showing that *vicia villosa* agglutinin binds to hyperplastic and adenomatous polyps suggests that these lesions manifest incomplete glycosylation²⁶ thereby exposing the Tn antigen. The expression of sialosyl-Tn in colonic polyps is also consistent with this concept. However, sialosyl-Tn antigen, but not Tn antigen, was selectively expressed by polyps with greater malignant potential. This indicates that during malignant transformation, although incomplete glycosylation is common, certain glycosylation pathways are preferred.

Service and a Medical Investigator Award from the Veterans Administration (YSK), and awards from the Aaron Diamond Foundation and The Chemotherapy Foundation (SHI).

An abstract of this work has been published in *Gastroenterology* 1990; 98: A288.

The authors gratefully acknowledge Annabelle Frieria and Pat Martinez for technical assistance, and Marguerite Pizzati for manuscript preparation.

- Gold DV, Miller F. Comparison of human colonic mucoprotein antigen from normal and neoplastic mucosa. *Cancer Res* 1978; 38: 3204-11.
- Kim YS, Isaacs R. Glycoprotein metabolism in inflammatory and neoplastic diseases of the human colon. *Cancer Res* 1975; 35: 2092-7.
- Schachter H, Williams D. Biosynthesis of mucus glycoproteins. In: Chantler EN, Elder JB, Elstein M, eds. *Mucus in health and disease II*. New York: Plenum Publishing, 1982; 3-28.
- Itzkowitz SH, Yuan M, Montgomery CK, Kjeldsen T, Takahashi HK, Bigbee WL, *et al*. Expression of Tn, sialosyl Tn, and T antigens in human colon cancer. *Cancer Res* 1989; 49: 197-204.
- Yuan M, Itzkowitz SH, Boland CR, Kim YD, Tomita JT, Palekar A, *et al*. Comparison of T-antigen expression in normal, premalignant and malignant human colonic tissues using lectin and antibody immunohistochemistry. *Cancer Res* 1986; 46: 4841-7.
- Konishi F, Morson BC. Pathology of colorectal adenomas: a colonoscopic survey. *J Clin Pathol* 1982; 35: 830-41.
- Kjeldsen T, Clausen H, Hirohashi S, Ogawa T, Iijima H, Hakomori S. Preparation and characterization of monoclonal antibodies directed to the tumor-associated O-linked sialosyl-2→6α-N-acetylgalactosaminyl (sialosyl-Tn) epitope. *Cancer Res* 1988; 48: 2214-20.
- Tollefsen SE, Kornfeld R. The B₄ lectin from *Vicia villosa* seeds interacts with N-acetylgalactosamine residues α-linked to serine or threonine residues in cell surface glycoproteins. *J Biol Chem* 1983; 258: 5172-6.
- Griffioen G, Bosman FT, Verspaget HW, DeBruin PAF, Biemond I, Lamers CBHW. Mucin profiles and potential for malignancy of human colorectal adenomatous polyps. *Cancer* 1989; 63: 1587-91.
- Boland CR, Montgomery CK, Kim YS. A cancer-associated mucin alteration in benign colonic polyps. *Gastroenterology* 1982; 82: 664-72.
- Cooper HS, Reuter VE. Peanut lectin-binding sites in polyps of the colon and rectum: adenomas, hyperplastic polyps, and adenomas with in situ carcinoma. *Lab Invest* 1983; 49: 655-61.
- Rhodes JM, Black RR, Savage A. Glycoprotein abnormalities in colonic carcinomata, adenomata, and hyperplastic polyps shown by lectin peroxidase histochemistry. *J Clin Pathol* 1986; 39: 1331-4.
- Itzkowitz SH, Yuan M, Ferrell LD, Palekar A, Kim YS. Cancer-associated alterations of blood group antigen expression in human colorectal polyps. *Cancer Res* 1986; 46: 5976-84.
- Kim YS, Yuan M, Itzkowitz SH, Sun Q, Palekar A, Trump BF, *et al*. Expression of Le^x and extended Le^x blood group-related antigens in human malignant, premalignant and non-malignant colonic tissues. *Cancer Res* 1986; 46: 5985-92.
- Yuan M, Itzkowitz SH, Ferrell L, Fukushi Y, Palekar A, Hakomori S, *et al*. Expression of Le^x and sialylated Le^x-related antigens in human colorectal polyps. *J Natl Cancer Inst* 1987; 78: 479-88.
- Fenoglio-Preiser CM. Hyperplastic polyps, adenomatous polyps, and mixed hyperplastic adenomatous polyps of the colon. In: Steele Jr G, Burt RW, Winawer SJ, Karr JP, eds. *Basic and clinical perspectives of colorectal polyps and cancer*. New York: Alan R Liss, 1988: 3-12.
- Kellokumpu I, Karhi K, Andersson LC. Lectin-binding sites in normal, hyperplastic, adenomatous and carcinomatous human colorectal mucosa. *Acta Pathol Microbiol Immunol Scand [A]* 1986; 94: 271-80.
- Itzkowitz SH, Bloom EJ, Kokal WA, Modin G, Hakomori S, Kim YS. Sialosyl-Tn: a novel mucin antigen associated with prognosis in colorectal cancer patients. *Cancer* 1990; 66: 1960-6.
- Bresalier RS, Ho SB, Kim YS. Alterations in mucin type glycoproteins in human colorectal cancer metastases. *Gastroenterology* 1990; 98: A274.
- Stramignoni D, Bowen R, Atkinson BF, Schlom J. Differential reactivity of monoclonal antibodies with human colon adenocarcinomas and adenomas. *Int J Cancer* 1983; 31: 543-52.
- Wolf BC, D'Emilia JC, Salem RR, DeCoste D, Sears HF, Gottlieb LS, *et al*. Detection of tumor-associated glycoprotein antigen (TAG-72) in premalignant lesions of the colon. *J Natl Cancer Inst* 1989; 81: 1913-7.
- Listrom MB, Little JV, McKinley M, Fenoglio-Preiser CM. Immunoreactivity of tumor-associated glycoprotein (TAG-72) in normal, hyperplastic, and neoplastic colon. *Hum Pathol* 1989; 20: 994-1000.
- Gold DV, Mattes MJ. Monoclonal antibody B72.3 reacts with a core region structure of O-linked carbohydrates. *Tumour Biol* 1988; 9: 137-44.
- Podolsky DK. Oligosaccharide structures of human colonic mucin. *J Biol Chem* 1985; 260: 8262-71.
- Podolsky DK. Oligosaccharide structures of isolated human colonic mucin species. *J Biol Chem* 1985; 260: 15510-5.
- Hakomori S. Aberrant glycosylation in cancer cell membranes as focused on glycolipids: overview and perspectives. *Cancer Res* 1985; 45: 2405-14.