

# Cystic dystrophy of the gastric and duodenal wall developing in heterotopic pancreas: an unrecognised entity

J-F Fléjou, F Potet, G Molas, P Bernades, P Amouyal, F Fékété

## Abstract

Ten patients in whom cystic dystrophy developed in a heterotopic pancreas of the duodenal (nine patients) or gastric (one patient) wall are reported. All were young or middle aged white men, only two of whom were alcoholic. The symptoms were caused by intestinal or biliary stenosis, or both, secondary to the inflammation and fibrosis. Only endosonography provided strong evidence for the diagnosis in three patients. All patients underwent surgery: a pancreaticoduodenectomy was performed in eight patients. The surgical specimen showed cystic lesions of the gut wall, occurring in inflammatory and fibrous heterotopic pancreatic tissue. The pancreas proper was normal in all patients. It is suggested that cystic dystrophy is an uncommon and serious complication of heterotopic pancreas. Similar cases associated with chronic pancreatitis of the pancreas have been observed and it is suggested that this process could be responsible for some of the chronic pancreatitis encountered in young, non-alcoholic patients. (*Gut* 1993; 34: 343-347)

Pancreatic heterotopia is defined as the presence, outside its usual location, of pancreatic tissue that lacks anatomical and vascular continuity with the pancreas proper.<sup>1</sup> It has an incidence ranging from 1 to 14% on necropsy examination,<sup>2</sup> and the most common locations are the stomach, duodenum, and jejunum. Although heterotopic pancreas is usually asymptomatic, symptomatic cases have been described. Symptoms are non-specific, and they have been attributed mainly to the presence of overlying mucosal ulceration in the stomach or duodenum.<sup>3</sup>

We have observed the development of cystic dystrophy, an uncommon and serious complication of heterotopic pancreas, in 10 patients, in all of whom we have met major difficulties in diagnosis and treatment.

## Patients and methods

Cases were selected from the records of the Department of Pathology, Beaujon hospital, between 1959 and 1991. During this period we observed 17 surgical specimens that showed

Departments of Pathology, Gastroenterology, and Digestive Surgery, Beaujon Hospital, Clichy, France

J-F Fléjou  
F Potet  
G Molas  
P Bernades  
P Amouyal  
F Fékété

Correspondence to: Dr J-F Fléjou, Service d'Anatomie Pathologique, Hôpital Beaujon, F-92118, Clichy Cedex, France.

Accepted for publication 10 August 1992

TABLE I Clinical data, diagnostic procedures, treatment, and outcome in 10 patients who developed cystic dystrophy in heterotopic pancreas

Case no	Year of surgery	Age (y)	Sex	Chronic alcoholism	Clinical manifestations	Weight loss (kg)	Symptom duration (y)	Diagnostic procedures	Preoperative diagnosis	Type of surgery	Outcome
1	1959	31	M	No	Abdominal pain	0	7	0	Tumour of the duodenum	PD	Recurrence of pain at 5 y, then lost to follow up
2	1960	55	M	No	Abdominal discomfort, vomiting	26	0.5	Barium meal	Duodenal stenosis	PD	Well (5 y)
3	1963	36	M	No	Abdominal pain, nausea, jaundice	10	1.5	Barium meal	Tumour of the pancreas	PD	No postoperative complication, then lost to follow up
4	1968	37	M	No	Jaundice	17	1	Barium meal, oral cholecystography	Tumour of the papilla of Vater	PD	No postoperative complication, then lost to follow up
5	1970	42	M	No	Abdominal pain, vomiting, jaundice	6	7	Intravenous cholangiography	Tumour of the pancreas	PD	Well (1 y)
6	1970	56	M	No	Jaundice	4	0.3	Barium meal, intravenous cholangiography, endoscopy	Biliary stenosis due to tumour	CJ	Death due to acute pancreatitis (10 days after surgery)
7	1982	38	M	No	Abdominal pain, vomiting	15	4	Barium meal, endoscopy, US	Tumour of the pancreas	PD	No postoperative complication, then lost to follow up
8	1989	41	M	Yes	Abdominal pain, vomiting	7	0.7	Barium meal, endoscopy, US, ERCP, CT, endosonography	CDHP of the duodenum	PD	Well for 1.5 y, still alcoholic, regressive acute pancreatitis
9	1990	37	M	No	Haemorrhage, abdominal pain, vomiting	14	0.3	Barium meal, endoscopy, US, ERCP, CT, endosonography	CDHP of the antrum	Antrectomy	Well (1 y)
10	1990	34	M	Yes	Abdominal pain, vomiting	10	1	Barium meal, endoscopy, US, ERCP, CT, endosonography	CDHP of the duodenum	PD	Well (1.5 y), dumping syndrome, still alcoholic

PD: pancreaticoduodenectomy; CJ: choledocojejunostomy; US: ultrasonography; ERCP: endoscopic retrograde cholangiopancreatography; CT: computed tomography; CDHP: cystic dystrophy in heterotopic pancreas.

TABLE II Pathological findings in 10 cases of cystic dystrophy developing in heterotopic pancreas

Case no	Location of lesion	Overlying digestive mucosa	Size of cysts	Lining of cysts	Heterotopic pancreas				
					Location	Exocrine tissue	Endocrine tissue	Canals and glands	Pancreas proper
1	2nd duodenum under and above papilla of Vater	Oedematous, polypoid	2 cm	Clear epithelium, granulation tissue	SM, MP	+	0	+	N
2	2nd duodenum under the papilla of Vater	Loss of folds, polyps	0.5–2 cm	Clear epithelium, granulation tissue	MP	0	0	+	N
3	2nd duodenum under and above papilla of Vater	Oedematous, loss of folds, thickened	1–3 cm	Clear epithelium, granulation tissue	MP	0	0	+	N
4	2nd duodenum above the papilla of Vater	Embossed, giant folds	NA	Clear epithelium with erosions	MP	+	+	+	N
5	2nd duodenum above and under papilla of Vater	Oedematous, loss of folds	0.3–3 cm	Clear epithelium	MP	+	+	+	N
6	2nd duodenum under the papilla of Vater	Thickened with erosions	NA	Clear epithelium, granulation tissue	SM	+	0	+	N
7	2nd duodenum above the papilla of Vater	Irregular, polypoid	0.5 cm	Clear epithelium, granulation tissue	SM, MP	+	+	+	N
8	2nd duodenum above the papilla of Vater	Embossed micronodular	0.5 cm	Clear epithelium, abscesses	SM, MP	+	+	+	N
9	Antral greater curvature	Thickened, haemorrhagic	3 cm	Clear epithelium, granulation tissue	MP, serosa	+	+	+	NA
10	2nd duodenum above the papilla of Vater	Polypoid	0.5–2 cm	Clear epithelium, granulation tissue	MP, serosa	+	+	+	N

N: normal; NA: not available; MP: muscularis propria; SM: submucosa.

the lesions of cystic dystrophy in heterotopic pancreas of the duodenal (16 patients) or gastric (one patient) wall. Seven of these were associated with chronic pancreatitis of the main pancreatic gland. The 10 patients with no associated chronic pancreatitis form the basis of this study. Details of six have previously been published in French reports,<sup>4,5</sup> but the remaining four are new reports. The case histories of the patients were analysed with respect to alcohol consumption, previous disease, symptoms, and preoperative diagnostic procedures. The surgical resection specimens provided the material for the morphological study, together with an autopsy specimen. In all cases surgical specimens were systematically sampled, with particular attention given to the pancreatic side of the duodenum which was included in its entirety and sectioned serially.

### Results

The relevant clinical and pathology data from these 10 patients are summarised in Tables I and II. All patients were white men. Their mean age was 41 (range, 31–56) years. In two patients there was a history of chronic alcohol abuse.

### SYMPTOMS

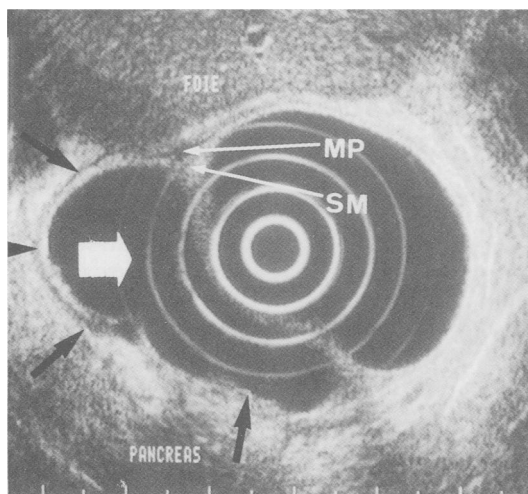
The initial clinical presentation was abdominal pain with vomiting or nausea in seven patients. These symptoms were associated with jaundice in two patients and with upper gastrointestinal haemorrhage in one. Episodes of jaundice were

the only symptom in two patients. In patient 1, chronic abdominal pain was the sole symptom. Weight loss occurred in all but one patient, and in all the symptoms had been present for a long time before surgery (up to 7 years in patients 1 and 5).

### DIAGNOSTIC PROCEDURES

Barium meal studies were performed in eight patients, and showed stenosis of the duodenum caused by a tumour on the pancreatic side of the second part of the duodenum (seven patients) and gastric antrum (one patient). Upper digestive endoscopy was performed in five patients, and showed intact mucosa but duodenal stenosis of the medial side of the second part of the duodenum (in four patients) or on the greater curvature of the gastric antrum and pylorus (in one patient). There was no ulceration. The endoscopic lesions were described as enlarged folds with oedema and congestion. In several patients a raised pseudotumour or sessile polyp was described. In four, mucosal biopsy specimens showed non-specific inflammatory changes. In patient 10, inflammatory cells were obtained by ultrasound guided biopsy of the abnormal area. Endoscopic retrograde cholangiopancreatography (ERCP) was normal in three patients. Ultrasound (four patients) and computed tomography (three patients) showed a diffuse hyperechogenic and hyperdense thickening of the duodenal or gastric wall. In patient 9, ultrasound showed two anechogenic areas in the thickened antral wall. Endosono-

**Figure 1:** Endosonographic aspect of cystic dystrophy developing in heterotopic pancreas. A cystic lesion (white arrow) with bilobed borders (black arrows) is present within the thickened duodenal wall (MP: muscularis propria, SM: submucosa).

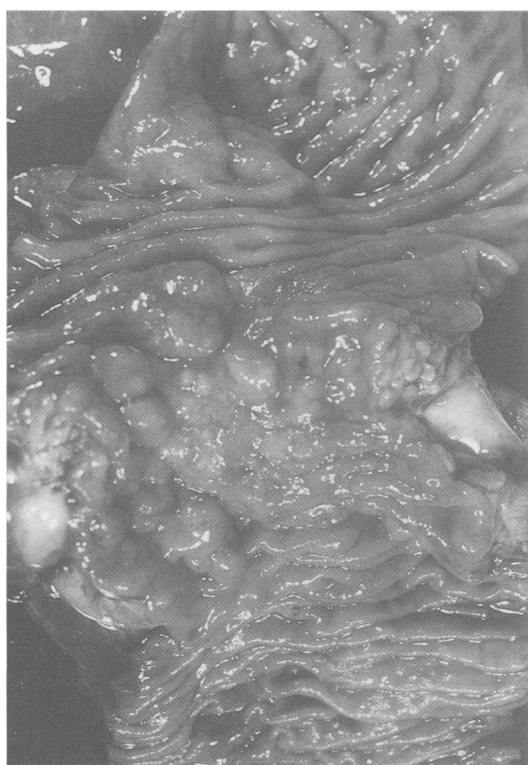


graphy, performed in patients 8, 9, and 10, showed identical abnormalities in all three, the antral (patient 9) or duodenal (patients 8 and 10) wall was thickened. This thickening was mostly hyperechogenic, but contained two to four anechogenic areas measuring 0.5 to 3 cm in diameter (Fig 1). No abnormalities were seen in the pancreas nor in the pancreatic and bile ducts.

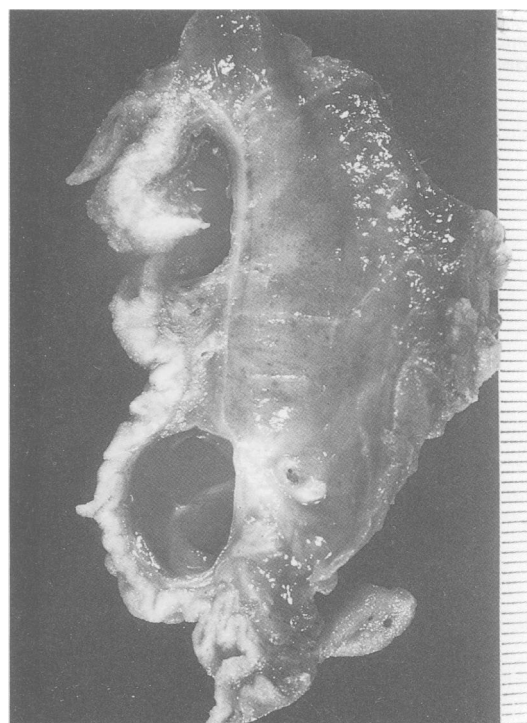The preoperative diagnosis was of a tumour of the pancreas or duodenum, probably malignant, in patients 1 to 7. In the remaining three patients, the diagnosis of cystic dystrophy in heterotopic pancreas was suspected, mainly on the basis of the endosonographic findings.

#### TREATMENT

Surgery consisted of pancreaticoduodenectomy (Whipple's procedure) in eight patients, choledocojejunostomy in one, and antrectomy in the one patient with a lesion of the gastric antrum.



**Figure 2:** A pancreaticoduodenectomy specimen shows duodenal stenosis with irregular polypoid appearance without ulceration.



**Figure 3:** Two large cysts are developed in the duodenal wall.

#### FOLLOW UP

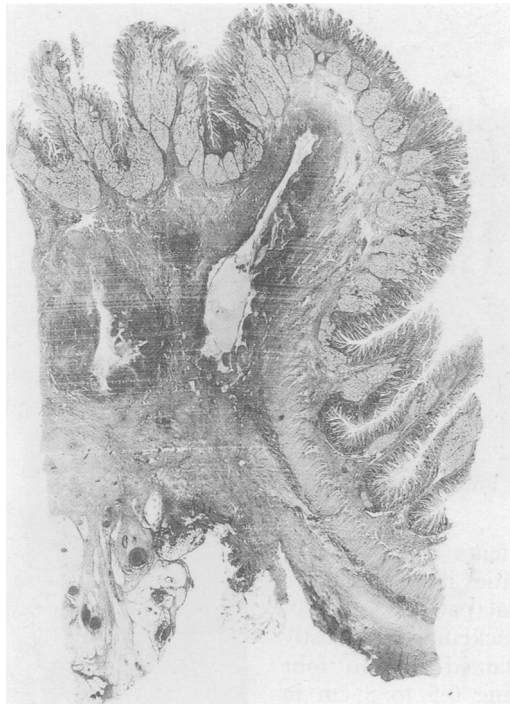Patient 6 died postoperatively from acute pancreatitis. The remaining nine patients had an uneventful postoperative course. Three patients were lost to follow up after surgery. Patient 1 experienced a recurrence of pain 5 years after surgery but refused further exploration and was then lost to follow up. Patient 8 was well 1.5 years after surgery. He was still alcoholic, and presented then with an attack of acute pancreatitis that resolved with medical treatment.

#### PATHOLOGICAL FINDINGS

##### Gross examination

Pancreaticoduodenectomy specimens showed similar features in all eight patients. The duodenal lumen was partially stenosed because of appreciable thickening of the duodenal wall. This thickening was uneven; it was predominant on the pancreatic side of the duodenum, above or below the papilla of Vater, or both. The latter looked normal in all patients, as was the low choledocus. The mucosa overlying the abnormal area was intact, but seemed irregular with giant folds or sessile polypoid lesions, or both, resulting in a pseudotumourous appearance (Fig 2). The main and constant features seen on serial sections were multiple cysts of variable size measuring up to 3 cm in diameter (Fig 3). The cysts were located in the thickened duodenal wall and contained either clear fluid or thick yellow material, together with stones in some patients. The macroscopic features of the antrectomy specimen in patient 9 were similar to those observed on pancreaticoduodenectomy specimens. The lesion was present on the greater curvature of the antrum. The mucosa was pseudovillous and haemorrhagic; cysts were seen in the antropyloric wall and appeared related

Figure 4: The duodenal wall contains cysts and pseudo-cysts surrounded by fibrosis.



to a whitish nodule on the serosa measuring 3 cm in diameter.

#### Microscopy

The cysts had the same appearances in all 10 patients. The smaller cysts were detected only on microscopy, and corresponded to dilated ducts lined with a clear cell columnar epithelium (Fig 4). The larger the cysts, the more flattened the lining epithelium. In the largest cystic lesions, the epithelium was partially or entirely eroded, and there was surrounding inflammatory granulation tissue (Fig 5). The lumina of the larger cysts frequently contained numerous degenerated polymorphonuclear cells. In some patients, protein plugs and stones were present. In all patients, the cysts were located in the submucosa and muscularis propria. The mucosa

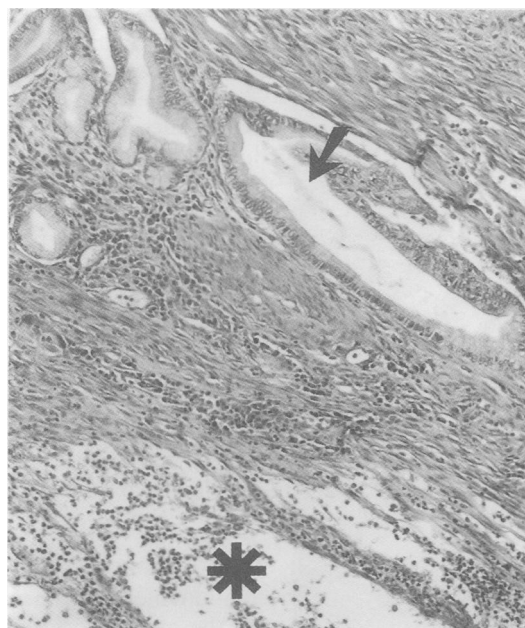


Figure 5: A cystic lesion is surrounded by granulation tissue (asterisk). A persisting excretory duct (arrow) is surrounded by normal glands.

was normal except for moderate congestion, mild non-specific inflammatory changes, and in some patients the presence of rare excretory ducts lined with the same clear cell epithelium encountered in the cysts. Hyperplastic Brunner's glands were frequently observed. In eight patients, characteristic ectopic pancreatic tissue was present around the cysts in the duodenal wall, with exocrine (eight patients) and endocrine (seven patients) tissues. The remaining two patients showed only ducts and lobules of glands lined with columnar, clear epithelium. Fibrosis and chronic inflammatory changes were present in all, giving features similar to those described in chronic pancreatitis of the normal gland. Interestingly, in all nine patients with a pancreas proper, the gland was essentially normal, with no feature of acute or chronic pancreatitis, except some mild fibrosis close to the ectopic tissue.

#### Discussion

Cystic dystrophy in heterotopic pancreas is a disorder that has not been previously described in the English published reports. It is characterised by the presence in the duodenal or gastric wall of cysts surrounded by inflammation and fibrosis, intermingled with pancreatic ducts and lobules. Although similar lesions can be observed associated with chronic pancreatitis of the pancreas proper, cases with a normal pancreas more clearly illustrate the epidemiological, clinical, diagnostic, and therapeutic aspects of this entity. Therefore, the aim of this paper was to describe 10 such patients whom we observed between 1959 and 1990. We have been able to find only three further patients in French and Spanish published reports<sup>6,8</sup> with features similar to those observed in our patients. All 13 cases have occurred in young or middle aged white men, most of whom had no history of chronic alcoholism. The most frequent symptom was abdominal pain that could either be attributed to local inflammatory changes or to duodenal stenosis. Other symptoms, including nausea, vomiting, and jaundice, can be attributed to duodenal or biliary stenosis.

Cystic dystrophy in heterotopic pancreas might be considered a very unusual complication of heterotopic pancreas, as only 13 patients have been reported so far, including the 10 in this series. However, cases of cystic and inflammatory lesions of the duodenopancreatic region that show features very similar to those that we have observed in our 10 patients have appeared in the published reports under various names. Stolte *et al* described as 'groove pancreatitis' 30 cases out of 123 specimens of pancreaticoduodenectomy performed for chronic pancreatitis.<sup>9</sup> In three, ectopic pancreas was present in the duodenal wall and showed chronic pancreatitis; the remainder of the pancreatic tissue was intact, except for scarring in the groove between the head of the pancreas, bile duct, and duodenum. Other reports detail patients with cystic lesions of the duodenal wall that have been considered as duplication or enterogenous cysts, in spite of the absence of intestinal and gastric epithelium,<sup>10</sup> and the presence of ectopic pan-

creatic tissue in some of the cases.<sup>11,12</sup> We feel that many of these cases represent cystic dystrophy in heterotopic pancreas.

The pancreas proper was normal in all our patients, as was the pancreatic duct in the three who underwent ERCP. In some patients, however, cystic dystrophy in heterotopic pancreas might provoke a stenosis of the pancreatic duct, and be responsible for chronic pancreatitis. We have observed seven such patients with concomitant cystic dystrophy in heterotopic pancreas of the duodenal wall and chronic calcifying pancreatitis (unpublished observations). These seven patients were young non-alcoholic men, as were eight of the 10 patients in this report. Some other patients have been reported in French publications with typical lesions of cystic dystrophy in heterotopic pancreas associated with chronic pancreatitis of the pancreas.<sup>4,13-15</sup> When pancreaticoduodenectomy specimens showing chronic pancreatitis have been systematically searched for dystrophic heterotopic pancreas of the duodenal wall, the lesion was found in 26 of 96 cases in the study of Martin,<sup>16</sup> and in 17 of 50 cases in that of Vankemmel.<sup>17</sup> Cystic dystrophy in heterotopic pancreas may have a role in the aetiology of chronic pancreatitis, especially that occurring in young non-alcoholic men.

The cause of the cystic and inflammatory changes observed in the heterotopic pancreas is unknown. Although heterotopic pancreas is localised in the duodenal wall in 25% of cases, cystic dystrophy in heterotopic pancreas occurred in this site in all our patients but one. The lesions could be the result of local conditions with repeated attacks of acute pancreatitis.<sup>18</sup> These episodes may be determined by obstruction of minor excretory ducts of ectopic pancreatic exocrine lobules. The dilated ducts that we have observed in all our patients favour this hypothesis. In only two of the 10 patients could the pathogenetic role of alcohol be suspected. Although a male predominance has been reported in surgical and autopsy series of heterotopic pancreas (male to female ratio 2 to 1),<sup>1,3</sup> we do not know why all our patients were men.

Difficult diagnostic and therapeutic dilemmas are raised by cystic dystrophy in heterotopic pancreas. In our retrospective series, seven patients were observed before the development of modern abdominal imaging techniques. In these patients, the symptoms and the barium meal studies favoured a diagnosis of malignancy of the pancreaticoduodenal region, although no definite preoperative diagnosis was made in any. Three patients were seen more recently, and

extensive investigations were performed. Barium meal and endoscopy again showed non-specific stenosis, and duodenal biopsy specimens were non-contributory. ERCP was normal, making a diagnosis of chronic pancreatitis very unlikely. Ultrasound and computed tomography confirmed the localisation of the abnormality to the duodenal or antral wall, but no specific features were observed. Endosonography showed multiple cystic lesions in a thickened gut wall, and confirmed the absence of chronic pancreatitis of the pancreas proper. Identical endosonographic features have been described in another case of cystic dystrophy in heterotopic pancreas.<sup>8</sup> Endosonography can therefore be considered as the most useful investigation when cystic dystrophy in heterotopic pancreas is suspected.

We thank Dr A B Price for kindly reviewing the manuscript.

- 1 Cubilla AL, Fitzgerald PJ. *Tumors of the exocrine pancreas*. Washington: Armed Forces Institute of Pathology, 1984.
- 2 Lai ECS, Tompkins RK. Heterotopic pancreas. Review of a 26 year experience. *Am J Surg* 1986; **151**: 697-700.
- 3 Armstrong CP, King PM, Dixon JM, Macleod IB. The clinical significance of heterotopic pancreas in the gastrointestinal tract. *Br J Surg* 1981; **68**: 384-7.
- 4 Potet F, Duclert N. Dystrophie kystique sur pancréas aberrant de la paroi duodénale. *Arch Fr Mal App Dig* 1970; **59**: 223-38.
- 5 Prandi D, Maillard JN, Potet F. Traitement chirurgical de la dystrophie kystique sur pancréas aberrant de la paroi duodénale. A propos de 3 cas. *Arch Fr Mal App Dig* 1972; **61**: 193-6.
- 6 Parc R, Soprani A, Louvel A. Hétérotopie pancréatique kystique de la paroi duodénale sans pancréatite chronique associée. *J Chir (Paris)* 1977; **114**: 185-92.
- 7 Hebrero J, Diego Estevez M, Martinez Arrieta F, Velasquez E, Campo R, Segura J, et al. Distrofia quística en Heterotopia de la pared duodenal. *Rev Esp Enforn Apar Dig* 1980; **57**: 51-6.
- 8 Andrieu J, Palazzo L, Chikli F, Doll J, Chome J. Dystrophie kystique sur pancréas aberrant. Apport de l'écho-endoscopie. *Gastroenterol Clin Biol* 1989; **13**: 630-3.
- 9 Stolte M, Weiss W, Volkholz H, Rosch W. A special form of segmental pancreatitis: "groove pancreatitis". *Hepatogastroenterology* 1982; **29**: 198-208.
- 10 Kalvaria I, Bornman PC, Girwood AH, Marks IN. Periapillary cysts: A surgically remediable cause of pancreatitis. *Gut* 1987; **28**: 358-62.
- 11 Bartels RJ. Duplication of the stomach. Case report and review of the literature. *Ann Surg* 1967; **33**: 747-52.
- 12 Holstege A, Barner S, Brambs HJ, Wenz W, Gerok W, Farthmann EH. Relapsing pancreatitis associated with duodenal wall cysts. Diagnostic approach and treatment. *Gastroenterology* 1985; **88**: 814-9.
- 13 Murat J, Gignoux M, Lesbros F. Dystrophie kystique sur pancréas aberrant du bulbe duodénal. *Ann Chir* 1971; **25**: 1203-8.
- 14 Léger L, Lemaigre G, Lenriot JP. Kystes sur hétérotopie pancréatique de la paroi duodénale. *Nouv Presse Med* 1974; **3**: 2309-14.
- 15 Eloit S, Charles J-F, L'Herdever G, Balouet G, Leroy JP. Dystrophie kystique sur pancréas aberrant. *Sem Hop Paris* 1987; **63**: 2545-9.
- 16 Martin ED. Paraampullary duodenal cysts: their relations with chronic pancreatitis. In: *The sphincter of Oddi*. Basel: Karger, 1977: 156-62.
- 17 Vankemmel M, Paris JC, Houcke M, Laurent JC, Burzynski A. Kystes para-duodénaux juxta-vatériens et pancréatite chronique. *Med Chir Dig* 1975; **4**: 181-5.
- 18 Léger L, Louvel A, Chiche B, Michali P. Les hétérotopies pancréatiques. A propos de 8 nouveaux cas. *J Chir (Paris)* 1979; **116**: 553-60.