

Congestive jejunopathy in portal hypertension

A S Nagral, A S Joshi, S J Bhatia, P Abraham, F P Mistry, I M Vora

Abstract

Twenty six patients with portal hypertension of different aetiologies were studied for endoscopic evidence of congestive gastroduodenopathy and histological evidence of congestive gastropathy and jejunopathy. Per oral biopsies of jejunum were taken by Watson's capsule. Normal biopsy tissues obtained from the antrum (26), fundus (10), and jejunum (26) were used as controls. Endoscopy showed congestive changes in the fundus (17 cases), antrum (17), and duodenum (4). Duodenopathy correlated with changes in the antrum but not in the fundus. Histology showed an increase in the size and number of vessels in the jejunal villi ('congestive jejunopathy') in 22 patients. These correlated with histological evidence of gastropathy in the fundus but not in the antrum. The incidence of congestive jejunopathy did not correlate with the Child-Pugh score in patients with cirrhosis or with the number of sclerotherapy sessions received. Congestive jejunopathy is part of the spectrum of congestive gastroenteropathy and occurs at least as frequently as changes in the stomach and duodenum. The clinical import of these jejunal changes remains to be explained.

(Gut 1993; 34: 694-697)

McCormack *et al*¹ were the first to describe the entity of congestive gastropathy in patients with portal hypertension. It was postulated that increased portal blood flow with relative ischaemia of the gastric mucosa because of capillary dilatation and arterio-venous shunting were associated with this disorder. These lesions are important because they are a major cause of gastrointestinal blood loss, either slow and insidious or severe and fatal. Similar changes were later described in other parts of the gastrointestinal tract, like the duodenum,² colon,³ and rectum,⁴ which are easily accessible to the endoscope. Endoscopic changes in the jejunum have recently been described in three patients, and the term 'gastroenteropathy' has been coined to cover the entire spectrum.⁵ Changes in the jejunum are also thought to contribute to blood loss.⁵ There is, however, no study in humans that describes the histological features of the jejunum in patients with portal hypertension, except in some necropsy specimens of the small intestine.¹

This study was undertaken to determine the presence and incidence of histological changes in the jejunum of patients with portal hypertension. The correlation of these changes with endoscopic and histological evidence of congestive gastropathy was also studied. In addition, we studied the incidence of *Helicobacter pylori* infection and intestinal metaplasia in patients with gastropathy and the correlation of gastropathy and

jejunal changes with the Child-Pugh score, the portal and splenic vein size, and the number of sclerotherapy sessions in patients with cirrhosis.

Patients and methods

Twenty six consecutive patients with portal hypertension (19 men and seven women) who were attending the gastroenterology department of an urban referral hospital were enrolled in the study. Their mean (SD) age was 36.7 (15.4) years. The aetiologies of portal hypertension in these patients were as follows: 15 cirrhosis (10 post necrotic, five alcoholic); nine extra-hepatic portal venous obstruction; and one each, non-cirrhotic portal fibrosis and Budd-Chiari syndrome. Eleven patients with cirrhosis and the patient with non-cirrhotic portal fibrosis were diagnosed by liver biopsy specimen; in the other cirrhosis patients the diagnosis was based on a cumulative score of clinical, biochemical, and liver scan findings in the presence of oesophageal varices.⁶ Extra-hepatic portal venous obstruction and the Budd-Chiari syndrome were diagnosed by abdominal ultrasound scan. None of these patients was taking any vasoactive drug or non-steroidal anti-inflammatory drug.

The sanction of the institution's ethics committee was obtained for the study protocol. Informed consent for biopsy was obtained from all patients.

Three patients were positive for hepatitis B surface antigen (RPHA). Liver function tests, which included serum albumin, serum bilirubin, and prothrombin time, were undertaken in all patients. The prothrombin time was normal in all patients as was the platelet count. Fourteen patients had ascites and four had had previous attacks of encephalopathy. A Child-Pugh score⁷ was given to all patients with cirrhosis: the mean (SD) score was 9.06 (2.13). Abdominal ultrasound was used not only to determine the status of the liver and the spleen and the presence of collateral channels but to measure the portal and splenic vein sizes. Collaterals were present in 16 patients, the mean (SD) portal vein size was 14.6 (4.15) mm. The mean (SD) size of the splenic vein was 9.54 (1.93) mm.

All patients underwent upper gastrointestinal endoscopy (XQ-20, Olympus, Japan). Any endoscopic evidence of congestive gastropathy and duodenopathy was noted and gastric changes were graded according to severity as: mild, comprising of a mosaic pattern or a snakeskin appearance; moderate, with diffuse erythema of the stomach; and severe, with cherry red spots.⁸ Congestive duodenopathy was graded as mild in the presence of patchy erythema; moderate where there was diffuse erythema; and severe when cherry red spots were present. The mean (SD) number of previous sclerotherapy sessions

Departments of
Gastroenterology and
Pathology, KEM
Hospital, Bombay, India
A S Nagral
A S Joshi
S J Bhatia
P Abraham
F P Mistry
I M Vora

Correspondence to:
Dr P Abraham, Professor and
Head, Department of
Gastroenterology, KEM
Hospital, Bombay 400 012,
India

Accepted for publication
15 September 1992

(11.5 (8.1)) was also noted. In addition, two biopsy specimens each were taken from the antrum and fundus, irrespective of the presence or absence of endoscopic congestive gastropathy. The tissues were stained by haematoxylin and eosin. Twenty six antral and 10 fundic biopsy specimens obtained from normal subjects were used as controls.

A per oral jejunal biopsy specimen was obtained by a paediatric Watson's small intestinal biopsy capsule in all the 26 patients. The jejunal biopsy tissues were stained with haematoxylin and eosin. An equal number of normal jejunal biopsy specimens obtained from subjects undergoing biopsy for other purposes were used as controls.

HISTOLOGY

All histological specimens were reviewed jointly by two pathologists (ASJ, IMV) who were aware of the diagnosis.

The fundic and antral biopsy specimens were analysed for the severity and type of infiltrate in the mucosa, the size and number of vessels in the mucosa, the presence of glandular atrophy (Whitehead's criteria),⁹ oedema in the lamina propria (separation of connective tissue in the lamina propria) and thickness of the muscularis mucosae (determined subjectively). In addition, the presence of intestinal metaplasia and *H pylori* infections was noted. The infiltrate severity was graded as mild, moderate, and severe,¹⁹ and mild infiltrate was considered normal. The depth of the abnormally increased infiltrate was also noted.

The jejunal biopsy tissues were analysed for the severity and type of infiltrate in the mucosa, the size and number of vessels, the presence of glandular atrophy, oedema in the lamina propria, thickness of the muscularis mucosae, the villus: crypt ratio, and the presence of focal haemorrhages.

The size and number of vessels were measured in five consecutive villi, and median values were derived. The maximum diameter of vessels, as measured on an optical micrometer scale, was taken as the size; each division of the scale corresponded to 3.5 μ with a magnification of 192.

STATISTICAL ANALYSIS

The number of patients with abnormalities in each of the above parameters in fundic, antral and jejunal biopsy specimens was compared with the number of controls with abnormalities by the χ^2 test with Yate's correction. Each of the parameters in patients with and without cirrhosis was also compared by the same test. Correlation between the presence of histological features of congestive gastropathy (that is changes in the fundus and antrum) with those in the jejunum was done with the Kendall rank correlation test. This test was also used for correlating the endoscopic and histological evidence of congestive gastropathy. Each of the histological and endoscopic parameters in the fundus, antrum, and jejunum was correlated with the age of the patients, the Child-Pugh score in patients with cirrhosis, the number of sclerotherapy sessions, and the portal and splenic vein size.

Results

ENDOSCOPY

Congestive gastropathy in the fundus was found at endoscopy in 17 patients (65%) – 12 mild, three moderate, and two severe. It was found in the antrum in 17 patients (65%) – 10 mild, five moderate, and two severe. Congestive duodenopathy (first part of duodenum) was seen in only four patients (16%) – two mild, one moderate, and one severe. There was significant correlation between the presence of changes in the fundus and in the antrum ($p < 0.0001$). The presence of duodenopathy correlated with changes in the antrum ($p < 0.0001$) but not in the fundus.

HISTOLOGY

Analysis of gastric fundic biopsy specimens showed that a significantly greater number of patients than controls had an increase in the vessel size ($p < 0.001$); there was no significant difference in the other parameters including the presence of intestinal metaplasia (Table). The number of control biopsy specimens studied was, however, small ($n = 10$).

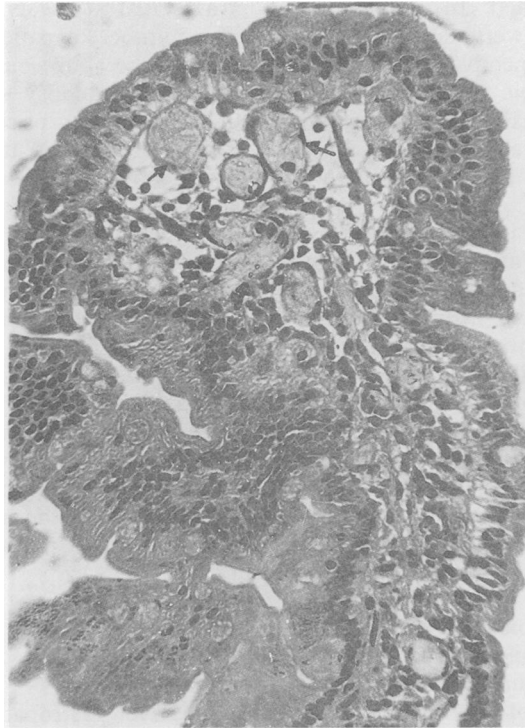
Analysis of gastric antral biopsy specimens again showed a significantly greater number of patients than controls with dilated vessels ($p < 0.025$) and a greater number of vessels ($p < 0.01$) in the patient group. Thick muscularis mucosae was also detected more frequently ($p < 0.05$) in patients with portal hypertension. Other parameters, including the presence of *H pylori* (25% in the patient group, 29% in the control group), were not significantly different in the two groups.

Jejunal biopsy specimens in the 26 patients showed an increase in the size of vessels compared with controls (median (range) 14 μ (<3.5–>175) *v* 7 μ (<3.5 to 63) respectively) and in the number of vessels per villus (median 10 *v* 4). A significantly greater number of patients than controls had large vessels ($p < 0.001$) and an increased number of vessels per villus ($p < 0.001$). Four patients had focal haemorrhages in the mucosa. Overall, these changes were present in

Comparison between histopathological parameters of patients and controls

Parameters	Patient no	Control no	p value
Fundus:	(n=26)	(n=10)	
Dilated vessels	22	1	<0.001
Increased vessel number	14	2	NS
Increased infiltrate	22	10	NS
Gland atrophy	4	1	NS
Oedema of lamina propria	12	2	NS
Thickening of muscularis mucosae	13	2	NS
Antrum:	(n=26)	(n=26)	
Dilated vessels	15	6	<0.025
Increased vessel number	13	3	<0.01
Increased infiltrate	20	24	NS
Gland atrophy	4	2	NS
Oedema of lamina propria	9	9	NS
Thickening of muscularis mucosae	14	6	<0.05
Jejunum:	(n=26)	(n=26)	
Dilated vessels	22	3	<0.001
Increased vessel number	22	1	<0.001
Increased infiltrate	25	26	NS
Gland atrophy	1	1	NS
Oedema of lamina propria	5	5	NS
Thickening of muscularis mucosae	11	4	NS

Figure 1: Photomicrograph of a jejunal villus in a patient with congestive jejunopathy showing multiple dilated vessels (arrows) in the mucosa (haematoxylin and eosin $\times 300$).



22 patients. The infiltrate severity and type, presence of glandular atrophy, oedema in the lamina propria, and the villus: crypt ratio in the two groups were not significantly different.

Comparison between the patients with and without cirrhosis did not show any significant difference in the histological parameters of the stomach and jejunum.

Based on these findings, congestive jejunopathy (Figs 1 and 2) was defined as the presence of abnormally dilated vessels (capillaries and venules) and an increase in the number of vessels to more than 6 per villus; this cut off level providing maximum discrimination.

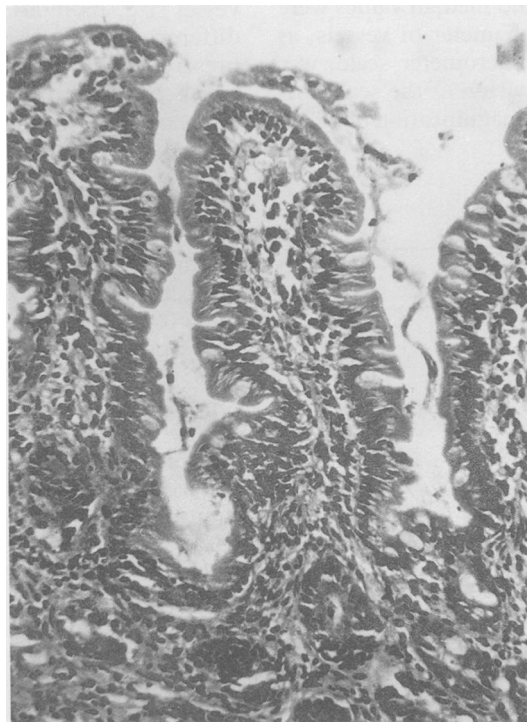


Figure 2: Photomicrograph of normal jejunal mucosa (haematoxylin and eosin $\times 192$).

CORRELATION BETWEEN ENDOSCOPY AND HISTOLOGY

There was no correlation between the endoscopic and the histological evidence of congestive gastropathy in either the fundus or antrum. Congestive gastropathy occurred more frequently endoscopically than histologically.

There was no histological correlation between congestive gastropathy in the antrum and fundus. The presence of congestive jejunopathy correlated significantly with that of histological congestive gastropathy in the fundus ($p < 0.002$) but not in the antrum. In the fundus, antrum, and jejunum there was good correlation between the vessel size and the number of vessels.

OTHER CORRELATIONS

The incidences of congestive jejunopathy and congestive gastropathy did not correlate with the number of sclerotherapy sessions. In patients with cirrhosis, the Child-Pugh score did not correlate with endoscopic or histological evidence of gastropathy in the fundus or antrum or with histological evidence of congestive jejunopathy.

There was no correlation between the portal vein size and congestive jejunopathy or endoscopic and histological evidence of congestive gastropathy in the fundus and the antrum. Nor did the presence of collaterals seen on ultrasound scan of the abdomen correlate with either congestive gastropathy or congestive jejunopathy.

Discussion

Congestive gastropathy is a well described entity and has been recognised as an important cause of upper gastrointestinal haemorrhage, accounting for 8–70% of bleeding sites in patients with portal hypertension.^{10,11} It has been graded endoscopically into mild, moderate, and severe forms.⁸ These patients have been reported as having hypergastrinaemia and low serum concentrations of pepsinogen 1.¹² In addition, their gastric mucosa is more susceptible to injury by noxious agents such as alcohol and aspirin.¹³ Impaired oxygenation of the gastric mucosa, and hence ischaemia, has been suggested as the probable mechanism for the increased susceptibility.¹⁴ Histology shows that these patients have dilated, ectatic vessels as the characteristic feature, with variable degrees of oedema and thickening of the muscularis mucosae but no significant increase in the amount of infiltrate.¹⁵ The chances of bleeding are said to be higher in patients with endoscopically severe congestive gastropathy (cherry red spots), and it has been suggested that these patients should be treated with propranolol with the aim of reducing portal pressures.^{16,17}

Recently, Kozarek *et al*³ showed vascular ectasia like lesions in the colon in a select group of patients with portal hypertension who had presented with haematochezia or haemoccult positive stool and anaemia. Similarly, the presence of rectal mucosopathy has been described.⁴ Thiruvengadam *et al*⁵ described similar lesions seen by extended upper gastrointestinal endoscopy in the proximal small bowel in three patients; no biopsy specimens were

taken. They coined the term 'congestive gastroenteropathy'.

In patients with portal hypertension in whom gastric mucosal lesions were being studied, full thickness small bowel specimens obtained at either surgery or necropsy were found incidentally to have similar histological changes in the mucosa.¹

Our prospective study was carried out to determine the presence and incidence of congestive changes in the stomach and jejunum on histology. Congestive changes were present on endoscopy in 65% of patients in the fundus, in 65% in the antrum, and in only 16% in the duodenum. Histology showed congestive changes in the fundus in 54% of the patients and in the antrum in 57%. Congestive jejunopathy, as defined by the presence of ectatic capillaries and venules in the villi, with an increase in the number of vessels (>6 per villus) seen on histology, was found in 84% of the patients. The muscularis mucosae was also thickened more frequently in the study group. Though oedema, gland atrophy, and chronic inflammatory infiltrate were present in varying amounts in patients with portal hypertension, they were not significantly different from the control biopsy specimens. Our histological assessment was limited by the fact that measurements were obtained on an optical micrometer scale; computerised morphometry would provide more accurate assessment, but was not available to us.

Although congestive gastropathy in the fundus and antrum are thought to be two distinct entities, we found good correlation between the two endoscopically, though not histologically. Evidence of gastropathy was more frequent on endoscopy than on histology; there was also a poor correlation between the severity of gastropathy endoscopically and histologically. Comparable with a recent study¹⁵ which ruled out *H. pylori* as a possible factor in the pathogenesis of congestive gastropathy, we found *H. pylori* in only 25% of patients, and its presence did not correlate with the gastropathy.

In patients with cirrhosis, the degree of hepatocyte dysfunction as measured by the Child-Pugh score did not correlate well with the presence of jejunopathy. In addition, the severity of portal hypertension, as judged by the portal vein size on ultrasonography and the presence of collaterals, did not predict the presence of jejunopathy. Congestive gastropathy has been reported as more common in patients with poorer liver functions,¹⁸⁻²⁰ and in those with a greater degree of portal hypertension.²¹ Other studies, however, have failed to show such an association.^{1,22} Sclerotherapy and large oesophageal varices have been found to increase significantly the risk of congestive gastropathy,¹⁵ but in our series this was not found to be the case.

This study suggests that the mucosal and vascular changes of jejunopathy are part of the spectrum found throughout the gastrointestinal tract in patients with portal hypertension. These

changes may be a manifestation of splanchnic dilatation and gut hyperaemia found in both patients and rat models of portal hypertension.²³ These could be a potential source of gastrointestinal bleed, requiring appropriate treatment. The part that these changes play in fluid and substrate transport in the small intestine remains to be studied.

Presented in part at mid-term Conference of the Indian Association for Study of the Liver, Bombay, 1992.

- McCormack TT, Sims J, Eyre-Brook I, Kennedy H, Goepel J, Johnson AG, et al. Gastric lesions in portal hypertension: inflammatory gastritis or congestive gastropathy? *Gut* 1985; 26: 1226-32.
- Chawla YK, Malik AK, Busnurmath SR, Dilawari JB. Duodenopathy in portal hypertension. *Indian J Gastroenterol* 1990; 9 (Suppl): A 51.
- Kozarek RA, Botoman VA, Bredfeldt JE, Roach JM, Patterson DJ, Ball TJ. Portal colopathy in patients with portal hypertension. *Gastroenterology* 1991; 101: 1192-7.
- Kochnar R, Malik AK, Rao AS, Goenka MK, Mehta SK. Rectosigmoid varices and mucosal changes in patients with portal hypertension. *Indian J Gastroenterol* 1991; 10 (Suppl): A 76.
- Thiruvengadam R, Gostout CJ. Congestive gastroenteropathy - an extension of nonvariceal upper gastrointestinal bleeding in portal hypertension. *Gastrointest Endosc* 1989; 35: 504-7.
- Mistry FP, Karnad DR, Abraham P, Bhatia SJ. A scoring system to differentiate cirrhotic from non-cirrhotic portal hypertension. *Indian J Gastroenterol* 1991; 10: 82-5.
- Pugh RNH, Murray-Lyon IM, Dawson JL, Pietroni MC, Williams R. Transection of the oesophagus for bleeding oesophageal varices. *Br J Surg* 1973; 60: 649-9.
- McCormick PA, Sankey EA, Cardin F, Dhillon AP, McInTyre N, Burroughs AK. Congestive gastropathy and *Helicobacter pylori*: an endoscopic and morphometric study. *Gut* 1991; 32: 351-4.
- Whitehead R, Truelove SC, Gear MWL. The histological diagnosis of chronic gastritis in fiberoptic gastroscopy biopsy specimens. *J Clin Pathol* 1972; 25: 1-11.
- Tabibian N, Graham DY. Source of upper gastrointestinal bleeding in patients with esophageal varices seen at endoscopy. *J Clin Gastroenterol* 1987; 9: 279-82.
- Papazian A, Brailion A, Dupas JL, Sevenet F, Capron JP. Portal hypertensive gastric mucosa: an endoscopic study. *Gut* 1986; 27: 1199-203.
- Quintero E, Pique JM, Bombi JA, Bordas JM, Sentis J, Elena M, et al. Gastric mucosal vascular ectasias causing bleeding in cirrhosis. A distinct entity associated with hypergastrinemia and low serum levels of pepsinogen I. *Gastroenterology* 1987; 93: 1054-61.
- Tarnawski AS, Sarfeh IJ, Stachura J, Hajduczek A, Bui HX, Dabros W, et al. Microvascular abnormalities of the portal hypertensive gastric mucosa. *Hepatology* 1988; 8: 1488-94.
- Sarfeh IJ, Soliman H, Waxman K, Coccia M, Rypins EB, Bui HX, et al. Impaired oxygenation of gastric mucosa in portal hypertension - the basis for increased susceptibility to injury. *Dig Dis Sci* 1989; 34: 225-8.
- D'Amico G, Montalbano L, Traina M, Pisa R, Menozzi M, Spano C, et al. Natural history of congestive gastropathy in cirrhosis. *Gastroenterology* 1990; 99: 1558-64.
- Hosking SW, Kennedy HJ, Seddon I, Triger DR. The role of propranolol in congestive gastropathy of portal hypertension. *Hepatology* 1987; 7: 437-41.
- Perez-Ayuso RM, Pique JM, Bosch J, Panes J, Gonzalez A, Perez R, et al. Propranolol in prevention of recurrent bleeding from severe portal hypertensive gastropathy in cirrhosis. *Lancet* 1991; 337: 1431-4.
- Rector WG Jr, Reynolds TB. Risk factors for hemorrhage from esophageal varices and acute gastric erosions. *Clin Gastroenterol* 1985; 14: 139-53.
- Franco D, Deporte A, Durandy Y, Bismuth H. Upper gastrointestinal haemorrhage in hepatic cirrhosis. *Lancet* 1977; i: 218-20.
- Teres J, Bordas JM, Bru C, Diaz F, Bruguera M, Rodes J. Upper gastrointestinal bleeding in cirrhosis: Clinical and endoscopic correlations. *Gut* 1976; 17: 37-40.
- Lebec D, deFleury P, Rueff B, Nahum H, Benhamou JP. Portal hypertension, size of varices, and risk of gastrointestinal bleeding in cirrhosis. *Gastroenterology* 1980; 79: 1139-44.
- Cales P, Zabotto B, Meskens C, Calucans JP, Vinel JP, Desmorat H, et al. Gastroesophageal endoscopic features in cirrhosis. Observer variability, interassociations, and relationship to hepatic dysfunction. *Gastroenterology* 1990; 98: 156-62.
- Vorobioff J, Bredfeldt JE, Groszmann RJ. Hyperdynamic circulation in portal-hypertensive rat model: A primary factor for maintenance of chronic portal hypertension. *Am J Physiol* 1983; 244: G52-57.