

## CASE REPORTS

## Extraintestinal lymphoma in association with Whipple's disease

C D Gillen, R Coddington, P G Monteith, R H Taylor

### Abstract

**A 45 year old man is described with Whipple's disease who presented with weight loss, lethargy, and ascites. He subsequently developed fever and a mass in the neck, but died despite antibiotic treatment and nutritional support. Necropsy showed extraintestinal lymphoma.**

(Gut 1993; 34: 1627-1629)

Whipple's disease, or intestinal lipodystrophy,<sup>1</sup> is a rare chronic systemic illness. Less than 1000 cases have been reported in world publications.<sup>2</sup> The cause is thought to be infective<sup>3</sup> and while 'Whipple's bacillus' has never been cultured, it has recently been identified by a molecular genetic approach.<sup>4</sup> Before antibiotic treatment was used, the condition was universally fatal.<sup>5</sup> Death due to treated Whipple's disease is now rare.<sup>6</sup> There is evidence of both an associated humoral and cellular immune defect in Whipple's disease, but no uniform abnormality has been shown.<sup>7</sup> This is the first reported

example of extraintestinal lymphoma in association with Whipple's disease.

### Case report

A 45 year old white man presented in October 1991 with a one year history of weight loss, lethargy, and fluid retention. He was educationally subnormal from birth with an IQ of 60. He had previously had a cholecystectomy and appendicectomy. He had a nine year history of a seronegative arthritis affecting his hands, knees, and feet.

On examination he was hyperpigmented and malnourished, with wasting of the face and trunk (Fig 1). There was gross ascites. The liver and spleen were not ballotable. He had non-pitting oedema of both legs with mild bilateral inguinal lymphadenopathy (Fig 2).

### INVESTIGATIONS

There was severe hypoalbuminaemia (serum albumin 14 g/l) and iron deficiency anaemia

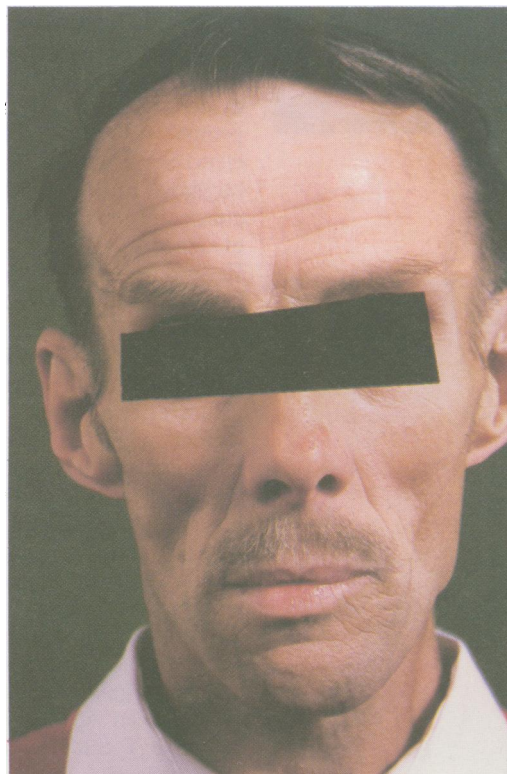


Figure 1: Hyperpigmentation and facial muscle wasting.

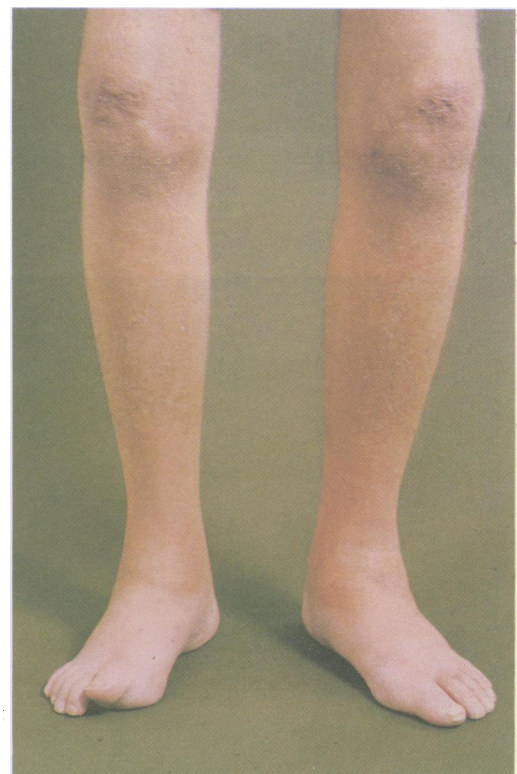

Figure 2: Non-pitting oedema of both legs.

Department of Medicine  
and Pathology, Royal  
Naval Hospital, Haslar,  
Gosport, Hampshire  
C D Gillen  
R Coddington  
P G Monteith  
R H Taylor

Correspondence to:  
Dr C D Gillen, Department of  
Gastroenterology, The  
General Hospital, Steelhouse  
Lane, Birmingham B4 6NH.

Accepted for publication  
17 March 1993

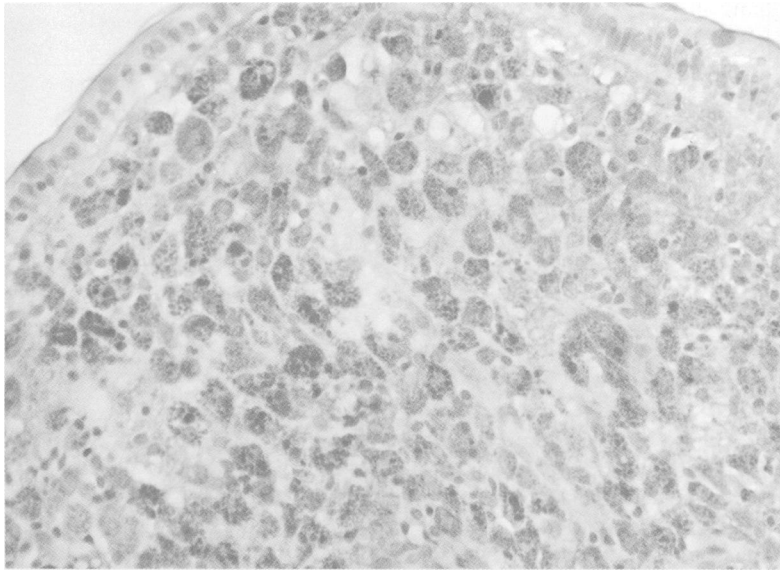


Figure 3: Jejunal biopsy specimen showing PAS positive macrophages.

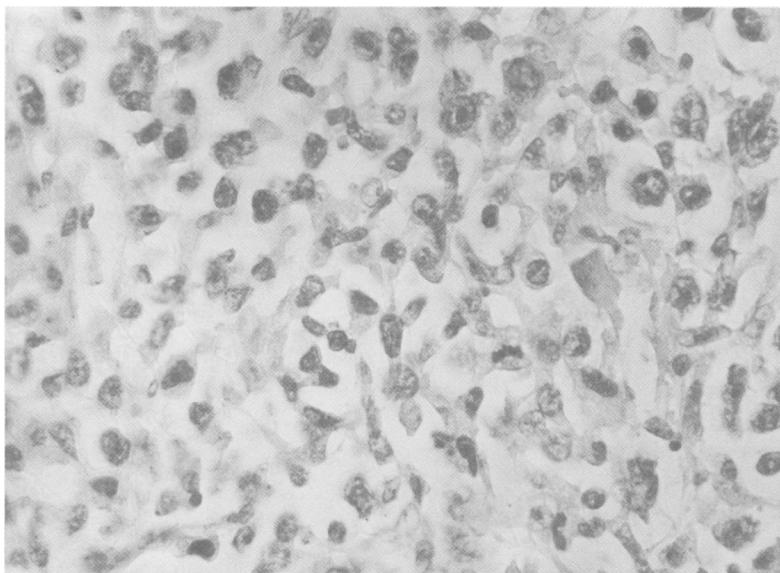


Figure 4: Polymorphic plasmacytoid lymphoma in parapharyngeal mass.

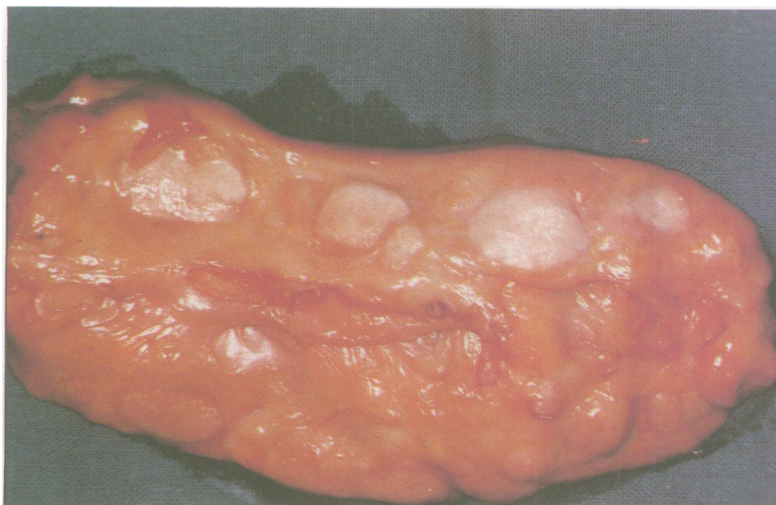

Figure 5: Enlarged lymph nodes in small bowel mesentery.

(total iron 1.4  $\mu\text{mol/l}$ , Hb 69 g/l). Jejunal biopsy showed the typical features of Whipple's disease, with PAS positive macrophages (Fig 3).

The patient responded well to nutritional support and treatment with benzyl penicillin and cotrimoxazole for more than a year. He made good progress until February 1992 when he was readmitted with a febrile illness and a tender mass in the right side of his neck, which was thought to be infective, but had not resolved despite treatment with flucloxacillin. His general condition deteriorated steadily, despite additional broad spectrum drugs and intensive nutritional support. Aspiration cytology of the neck mass showed only amorphous, necrotic material. Excision biopsy was carried out and before the result was available the patient deteriorated rapidly and died.

Postmortem examination showed a right sided parapharyngeal tumour, with the lower border just above the carotid bifurcation and had ulcerated into the pharynx. It had ensheathed, but not invaded the carotid artery. The cut surface was firm and pale, but with no areas of necrosis. Histological examination showed polymorphic lymphoplasmacytoid lymphoma (Fig 4). The oesophagus, stomach, small and large intestines were macroscopically normal. The small bowel mesentery was thickened and contained multiple enlarged lymph nodes (Fig 5). The liver was large and congested, but the spleen seemed normal. There was a terminal bronchopneumonia.

#### Discussion

The nature of the infecting organism in the aetiopathogenesis of Whipple's disease has recently been clarified, with the identification by Relman and his co-workers of the uncultured 'Whipple's bacillus' as a gram positive actinomycete, *Tropheryma whippelii*.<sup>4</sup> It is widely accepted that infection is the primary cause of Whipple's disease, but the importance of an associated immune deficiency in starting or promoting persistence of the infection is less clear. Several abnormalities of humoral and cell mediated immunity have been reported, but no consistent defect has emerged. There is no real evidence to support autoantibody production.<sup>7</sup> Early reports showed reduced concentrations of IgM,<sup>8,9</sup> but later studies showed normal or even raised immunoglobulin concentrations.<sup>10,11</sup> Reduced numbers of intestinal mucosal plasma cells have been reported, with a return to normal values after antibiotic treatment.<sup>12</sup> Evidence to support a defect in cell mediated immunity is more compelling. Reduced peripheral blood T lymphocyte counts, impaired macrophage function, and diminished cutaneous responses to a variety of antigenic stimuli have been reported, all of which have tended to return to normal after antibiotic treatment.<sup>11,13-16</sup> HLA B27 positivity in some patients and a granulomatous infiltration on histological examination in others would also support impaired cell mediated immunity.<sup>14,17,18</sup> It has been suggested by Dobbins that the defective T cell responses may be a secondary phenomenon, resulting perhaps from the combination of anergy triggered by infection,

incomplete intestinal lymphatic obstruction, and severe malnutrition. Before the introduction of antibiotic treatment Whipple's disease was universally fatal.<sup>5</sup> The gravity of central nervous system recurrence and hence the importance of appropriate antibiotic treatment in preventing relapse has been emphasised.<sup>6</sup> The outcome in this patient suggests that the delay in diagnosis and hence starting effective antibiotic treatment may have given rise to the abnormality in both the humoral response and T cell function, which on this occasion may have contributed to the development of an associated extraintestinal lymphoma.

- 1 Whipple GH. A hitherto undescribed disease characterised anatomically by deposits of fat and fatty acids in the intestinal and mesenteric lymphatic tissues. *Bull Johns Hopkins Hosp* 1907; 18: 382-91.
- 2 Dobbins WO (III). *Whipple's disease*. Springfield, Illinois: Charles C Thomas, 1987.
- 3 Yardley JH, Hendrix TR. Combined electron and light microscopy in Whipple's disease: demonstration of 'bacillary bodies' in the intestine. *Bull Johns Hopkins Hosp* 1961; 109: 80-98.
- 4 Relman DA, Schmidt TM, MacDermott RP, Falkow S. Identification of the uncultured bacillus of Whipple's disease. *N Engl J Med* 1992; 327: 293-301.
- 5 Paulley JW. A case of Whipple's disease (intestinal lipodystrophy). *Gastroenterology* 1952; 22: 128-33.
- 6 Fleming JL, Weisner RH, Shorter RG. Whipple's disease: clinical, biochemical and histopathologic features and assessment of treatment in 29 patients. *Mayo Clin Proc* 1988; 63: 539-51.
- 7 Dobbins WO (III). Is there an immune deficit in Whipple's disease? *Dig Dis Sci* 1981; 26: 247-52.
- 8 Crabbe PA, Heremans JF. The distribution of immunoglobulin-containing cells along the human gastrointestinal tract. *Gastroenterology* 1966; 51: 305-16.
- 9 Berens SC, Cohen RA, Schwabe AD. Diagnostic problems of partially treated Whipple's disease: report of a case with isolated deficiency of immunoglobulin M. *Calif Med* 1969; 110: 477-81.
- 10 Groll A, Valberg LS, Simon JB, Eidinger D, Wilson B, Forsdyke DR. Immunological defect in Whipple's disease. *Gastroenterology* 1972; 63: 943-50.
- 11 Clancy R, Muckle TJ, de Jesus D, Stevens D. Characteristics of the immune response in a patient with Whipple's disease. *Aust NZ J Med* 1977; 7: 294-8.
- 12 Dobbins WO (III), Ruffin JM. A light- and electron-microscopic study of bacterial invasion in Whipple's disease. *Am J Pathol* 1967; 51: 225-42.
- 13 Gupta S, Pinching AJ, Onwubalili J, Vince A, Evans DJ, Hodgson HJF. Whipple's disease with unusual clinical, bacteriologic and immunologic findings. *Gastroenterology* 1986; 90: 1286-9.
- 14 Feurle GE, Dorken B, Schopf E, Lenhard V. HLA B27 and defects in the T-cell system in Whipple's disease. *Eur J Clin Invest* 1979; 9: 385-9.
- 15 Martin FF, Vilseck J, Dobbins WO (III), Buckley CE (III), Tyor MP. Immunological alterations in patients with treated Whipple's disease. *Gastroenterology* 1972; 63: 6-18.
- 16 Keren DF, Weinrieb IJ, Bertovich MJ, Brady PG. Whipple's disease: no consistent mitogenic or cytotoxic defect in lymphocyte function from three cases. *Gastroenterology* 1979; 77: 991-6.
- 17 Babaryka I, Thorn L, Langer E. Epithelioid cell granulomata in the mucosa of the small intestine in Whipple's disease. *Virchows Arch [A]* 1979; 382: 227-35.
- 18 Southern JF, Moscicki RA, Magro C, Dickersin GR, Fallon JT, Bloch KJ. Lymphedema, lymphocytic myocarditis and sarcoid-like granulomatosis: manifestations of Whipple's disease. *JAMA* 1989; 261: 1467-70.