

# Antacid provides better restoration of glandular structures within the gastric ulcer scar than omeprazole

A Schmassmann, A Tarnawski, H A Gerber, B Flogerzi, M Sanner, L Varga, F Halter

## Abstract

**Mucosa of healed gastric ulcers displays histological abnormalities that are possibly the basis of ulcer recurrence. The influence of antacid and omeprazole treatment was studied on the quality of ulcer healing. Sixty four rats with gastric cryoulcers were treated daily either with placebo, antacid, omeprazole, or antacid plus omeprazole. Ulcer size was measured three times per week with a novel video endoscopic method. Prostaglandin generation (day 6), cell proliferation (day 8 and 15), height and cell composition of ulcer margin (day 8), and mucosal scar (day 15) were quantitatively assessed. Antacid, omeprazole, and antacid plus omeprazole significantly accelerated ulcer healing predominantly during days 3-8. Compared with placebo, the height of ulcer margin and mucosal ulcer scar was significantly increased in antacid (+7 and +9% respectively) and significantly decreased in omeprazole (-33 and -22% respectively) and antacid plus omeprazole (-26 and -18% respectively) treated rats. The number of bromodeoxyuridine labelled cells (+42%, day 8), epithelial cell mass (+42%, day 15), and the ratios of epithelial cells/connective tissue (+73%, day 15) and epithelial cells/gland lumen (+100%, day 15) were significantly increased in antacid treated rats. In conclusion, both antacid and omeprazole accelerate ulcer healing but antacid provides a better quality of healing. This advantage is lost by cotreatment with omeprazole.**

(Gut 1994; 35: 896-904)

Antacids are effective drugs in healing duodenal<sup>1-5</sup> and gastric<sup>6,7</sup> ulcers. The ulcer healing action of antacids was related to the neutralisation of gastric luminal acid for a long time,<sup>8</sup> but recent studies have shown that low dose of antacids with little acid neutralisation are also effective.<sup>9-12</sup> The precise mechanism of the ulcer healing action of antacids is unknown but seems to be much more complex than simple neutralisation of luminal acid. While antacids induce acceleration of ulcer healing to a similar extent as histamine H<sub>2</sub> receptor antagonists,<sup>2-7</sup> omeprazole induces faster healing of duodenal and gastric ulcers compared with histamine H<sub>2</sub> receptor antagonists.<sup>13,14</sup>

Assessment of gastric ulcer healing in a clinical setting, however, is usually based on

visual endoscopic inspection that only provides information about the absence or presence of an ulcer crater. Recent experimental data showed that the gastric mucosa of the re-epithelised ulcer crater displays prominent histological and ultrastructural abnormalities beneath the surface epithelium for a long time after the ulcer had healed.<sup>15-17</sup> Histological analysis of healed duodenal ulcers in humans showed that the ulcer scar remains histologically 'ill'.<sup>18,19</sup> As gastric ulcers tend to recur at a high frequency and usually at the same location,<sup>20</sup> we postulated that the abnormalities of the ulcer scar are possibly the basis of ulcer recurrence. In preliminary studies in the acetic acid ulcer model, we found that the aluminium containing antacid Maalox<sup>21</sup> and sucralfate<sup>22</sup> provided better restoration of glandular structures in the scar than omeprazole.

This study was designed to compare the effect of the antacid hydrotalcite, omeprazole, and hydrotalcite plus omeprazole on rate and quality of ulcer healing in the cryoulcer model.

## Methods

### ULCER INDUCTION

This study was approved by the animal study committee of Bern, Switzerland. A gastric cannula (steel, ID: 8 mm; Band, Bern, Switzerland) permitting video endoscopic examination of the gastric mucosa, was placed into the rumen of female Wistar rats (body weight: 200-220 g). Three weeks later, standardised gastric ulcers were produced by cryoinjury as previously described.<sup>23</sup> In brief, fed animals were anaesthetised with ether and the abdomen was opened by median incision. A freezing injury was made on the serosal surface of the posterior wall of the midcorpus. A cryoprobe (diameter: 6.5 mm) cooled by gaseous CO<sub>2</sub> to -60°C was pressed on the gastric wall for 45 seconds (Cryoprobe BM 250, Erbokryo 12, Rüeegg Medical, Baden, Switzerland). After spontaneous thawing of the lesion, the serosa was rinsed with sterile isotonic saline solution and the abdomen closed with catgut and silk sutures. The rats were kept under normal laboratory conditions with free access to water and a standard pelleted rat diet (Naphag, Gossau, Switzerland). Twenty four hours after cryoinjury, the ulcer size was measured by video endoscopy.<sup>24-26</sup> From a total of 72 rats, 64 rats that had round ulcers with an ulcer diameter of 5-7 mm, were allocated to the trial.

Gastrointestinal Unit,  
University Hospital,  
Inselspital, Bern,  
Switzerland

A Schmassmann  
B Flogerzi  
M Sanner  
L Varga  
F Halter

Gastroenterology  
Section, DVA Medical  
Center, Long Beach,  
University of  
California, Irvine,  
USA

A Tarnawski

Institute of Pathology,  
University of Bern,  
Switzerland  
H A Gerber

Correspondence to:  
Professor F Halter,  
Gastrointestinal Unit,  
Inselspital, University  
Hospital, 3010 Bern,  
Switzerland.

Accepted for publication  
28 October 1993

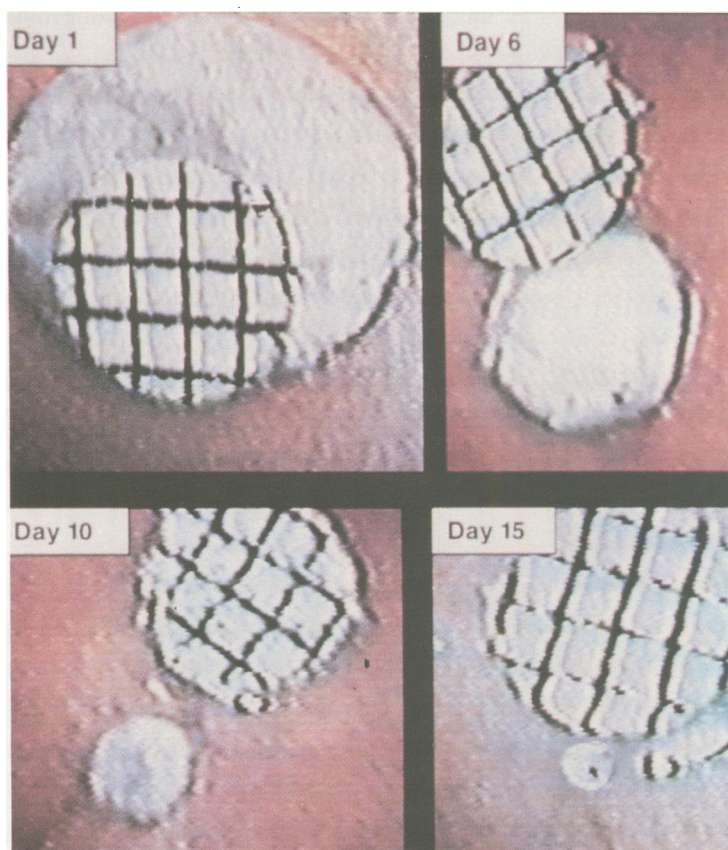


Figure 1: Video endoscopic view of the ulcer craters during healing. The ulcer outline and the calibration paper were traced. This permitted an objective measurement of the ulcer diameter.

#### TREATMENT

Twenty four hours after cryoinjury, the rats were randomly assigned to four groups, receiving the following treatment regimen: (a) placebo suspension 1 ml intragastric (hydrotalcite solvent, at 0800 and 1600) twice daily and placebo subcutaneously (omeprazole solvent (40% polyethylene glycol)) twice daily; (b) hydrotalcite suspension 1 ml (100 mg hydrotalcite) intragastric twice daily and placebo subcutaneously twice daily; (c) placebo suspension 1 ml intragastric twice daily and omeprazole 40  $\mu\text{mol/kg}$  once (0800) daily; (d) hydrotalcite suspension 1 ml (100 mg hydrotalcite) intragastric twice daily and omeprazole 1 $\times$ 40  $\mu\text{mol/kg}$  subcutaneously once daily.

The lattice like antacid hydrotalcite ( $\text{Mg}_6\text{Al}_2(\text{OH})_{16}\text{CO}_3 \times 4\text{H}_2\text{O}$ ) and placebo suspension (hydrotalcite solvent containing titanium dioxide) was provided by Bayer, Leverkusen, Germany.<sup>27</sup> The neutralising capacity of hydrotalcite is 2.78 mval per 1 ml hydrotalcite suspension (5.56 mval/day per rat and 22.2 mval/day per kg body weight).

The volume of each subcutaneous treatment was 0.25 ml. Omeprazole was provided by AB Hässle, Mölndal, Sweden. It was given subcutaneously, once daily, in a dose of 40  $\mu\text{mol/kg}$ . This dose completely inhibited basal and gastrin induced acid secretion for 24 hours. Half of the rats of each treatment regimen were treated for seven days, the other half for 14 days. The number of animals in each treatment group was 16, eight rats per time point.

#### VIDEO ENDOSCOPY

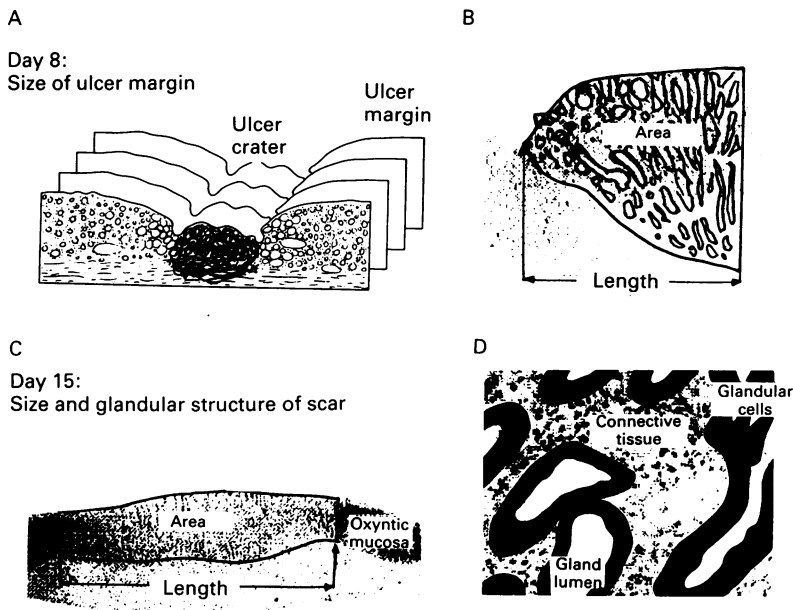
Endoscopic examinations were performed in rats with a gastric cannula (implanted into the rumen) through which a video endoscope (arthroscope, OD: 4 mm, 30° sideview, Storz, Tuttlingen, Germany; video camera OTV-F Olympus, Tokyo, Japan) was inserted. Video endoscopy was performed three times per week (on days 1, 3, 6, 8, 10, 13, and 15) without fasting.<sup>24-26</sup> Rats were gradually conditioned to being immobilised in Bollman cages. No anaesthesia was needed for endoscopy and the animals did not show signs of discomfort during endoscopy. Food in the stomach was washed out through the gastric cannula. For calibration, a round piece of calibration paper (diameter 4 mm) was placed with the tip of the endoscope close to the ulcer crater. Ulcer and calibration paper were recorded by video endoscopy and the image was transferred to a personal computer. The distance between the endoscope and the ulcer was the same as that between the endoscope and the calibration paper. Optical axis of the endoscope, ulcer crater, and calibration paper were aligned by adjusting the angle between the lines on the calibration paper to 90°. The gastric lumen was fully distended by air insufflation. First the ulcer outline and then a standard square (9 mm<sup>2</sup>) on the calibration paper was traced on the computer monitor permitting calculation of the ulcer diameter ( $2 \times \text{square root of (area}/\pi)$ ), (Fig 1). To ensure optimal standardisation, all ulcer measurements were done by the same two investigators, (A S, B F) who were unaware of the treatment regimen. Repeated measurements of the ulcer diameter showed a high reproducibility (inter-observer variation <5%). Ulcer diameter on different time points was expressed in a percentage of the ulcer diameter on day 1. Speed of ulcer healing (ulcer size reduction per day in %) was calculated from the ulcer diameter time curve; for example, ulcer healing speed on day 2 = ((ulcer diameter on day 1 in %) - (ulcer diameter on day 3 in %))/2 per day; for example, (100% - 86%)/2 = 7% per day.

#### MUCOSAL PROSTAGLANDIN GENERATION

Ex vivo prostaglandin generation was measured one hour after drug administration on day 6. Mucosal biopsy specimens were obtained with flexible biopsy forceps (FB-19CR Olympus) from the non-ulcerated oxyntic mucosa through the gastric cannula under video endoscopic guidance. The biopsy samples were carefully blotted and the wet weight was measured. The tissue specimens were then incubated in 0.6 ml of oxygenated Tyrode's solution at 37°C for 10 minutes. Release of prostaglandin 6-keto- $\text{F}_{1\alpha}$  (stable metabolite of prostacyclin) and prostaglandin  $\text{E}_2$  into the incubation medium was determined using specific radioimmunoassay as described.<sup>28 29</sup>

#### HISTOLOGICAL TEST OF ULCER SIZE

Two hours after the last treatment, the animals were anaesthetised with ether and laparotomised. For studies on cell proliferation, the



**Figure 2:** (A) The entire ulcer scar was analysed by serial sections that were cut perpendicular to the surface of the mucosa (distance between sections: 100  $\mu\text{m}$ ); (B) on day 8, area and length of the ulcer margin were traced. This permitted calculation of the height of the ulcer margin defined as margin area/margin length. The margin length was the distance between ulcer crater and normal mucosa (showing mature parietal cells with the expression of the 80 kDa phosphoprotein); (C) on day 15, area and length of the mucosal ulcer scar were traced. This permitted calculation of the height of the mucosal ulcer scar defined as scar area/scar length; (D) the percentage of glandular epithelial cells, connective tissue (between the glands), and gland lumen was determined in the mucosal ulcer margin (day 8) and scar (day 15).

rats received a single intraperitoneal injection of 100 mg/kg bromodeoxyuridine one hour before death. The stomach was removed, opened along the greater curvature, and pinned slightly stretched on a paraffin wax panel to prevent mucosal folding. Gastric tissue was then fixed for 16 hours in 4% paraformaldehyde in a 0.04 M potassium phosphate buffer, pH 7.4. The ulcerated mucosa and a calibration paper were photographed. After fixation, specimens of the entire gastric wall (25  $\times$  25 mm) containing the ulcer region were dehydrated and embedded in paraffin wax. Serial sections, 5  $\mu\text{m}$  thick, were cut perpendicularly to the surface of the mucosa. The sections were stained with haematoxylin and eosin and were analysed by light microscope. Morphometric analysis was done with a video camera (Ci-20 P Canon, Tokyo, Japan) and a semiautomatic image analysis system (Microvid software, Leica, Zürich, Switzerland). Mucosal thickness, defined as the distance from the epithelial surface to the muscularis mucosae, and ulcer area, defined as area of a mucosal defect penetrating through the muscularis mucosae, were measured. The histological ulcer diameter ( $2 \times$  square root of (area/ $\pi$ )) was calculated on day 8 and 15 and expressed as a percentage of the ulcer diameter on day 1 (assessed by video endoscopy).

#### BROMODEOXYURIDINE LABELLED CELLS

For bromodeoxyuridine immunostaining, sections were deparaffinised, incubated with 0.1% pepsin solution (Serva, Heidelberg, Germany, from swine) in 1 M HCl for 15 minutes at 37°C (to denature DNA), rinsed

in ice cold water, and immersed for one minute in cold TRIS buffered saline, pH 7.5. Immediately afterwards, the sections were covered with 1:50 diluted antibody to bromodeoxyuridine (mouse clone Bu20a, Dako M744) for 12 hours at 4°C. After washing in TRIS buffered saline, the avidin-biotin-peroxidase method (Dako, Glostrup, Denmark) was applied using diaminobenzidine as a chromogen.<sup>30 31</sup> The slides were counterstained briefly with Mayer's haematoxylin. The number of in vivo bromodeoxyuridine labelled epithelial cells located in a 600  $\mu\text{m}$  wide region of corpus mucosa adjacent to the mucosal defect and in non-ulcerated mucosa on day 8 and 15 was counted.<sup>23</sup> Labelled cells in 10 sections (with 20 ulcer margins) per rat were counted and the mean was calculated.

#### PARIETAL CELLS EXPRESSING THE 80 kDa PHOSPHOPROTEIN

To determine the border between normal and regenerating mucosa, mature parietal cells were identified by immunostaining the oxyntic mucosa for the 80 kDa phosphoprotein present on the apical membrane of gastric parietal cell. This 80 kDa phosphoprotein is phosphorylated upon cAMP mediate stimulation of gastric acid secretion. This protein is an important component, together with actin and the proton pump, of the isolated apical membrane, is closely related or identical to ezrin, and has properties of a membrane cytoskeletal linker in the induced apical microvilli.<sup>32-34</sup> The monoclonal antibody was kindly provided by Professor J G Forte, Department of Molecular and Cell Biology, Berkely, California, USA.<sup>32</sup> In brief, the sections were deparaffinised and incubated with the mouse anti-80 kDa phosphoprotein antibody (diluted 1:100 in TRIS buffered saline) or buffer (negative controls) for one hour at room temperature. After further incubation with biotinylated antimouse immunoglobulin (45 minutes) and washing in TRIS buffered saline, the avidin-biotin-peroxidase method (Dako, Glostrup, Denmark) was applied using diaminobenzidine as a chromogen.<sup>31</sup> Finally the sections were lightly counterstained with Mayer's haematoxylin.

#### QUANTITATIVE ASSESSMENT OF HISTOLOGICAL PARAMETERS

Sixty serial sections per rat containing the total ulcer region, were cut, 5  $\mu\text{m}$  thick, perpendicular to the surface of the mucosa at a distance of 100  $\mu\text{m}$  (60 sections = 6 mm per animal). For analysis of the ulcer margin on day 8, all sections (20-40 sections per rat) that showed an ulcer crater were analysed. Area and length of the ulcer margin on both sides of the ulcer were traced. The height of the ulcer margin in one section was defined as: margin area/margin length. The mean height of the ulcer margin was averaged from all analysed sections per rat. For analysis of the ulcer scar on day 15, all sections that showed mucosal ulcer scar tissue but no ulcer crater (40-60

sections per rat) were analysed. Area and length of the ulcer scar were traced, which permitted calculation of the ulcer scar height (scar height = scar area/scar length). The mean height of the ulcer scar was averaged from all analysed sections per rat. In addition, the percentage of epithelial gland cells, connective tissue, and gland lumen was determined in the mucosal ulcer margin and scar (Fig 2). The epithelial cell mass was calculated in the ulcer margin and scar by multiplying mucosal height by the relative amount of epithelial cells. Morphometric analysis was performed with a video camera (Ci-20 P Canon, Tokyo, Japan) and a semiautomatic image analysis system (Microvid software, Leica, Zürich, Switzerland).

#### PLASMA GASTRIN CONCENTRATION

To assess changes during treatment, plasma gastrin was measured in fed animals before and after treatment. Blood (0.7 ml) was collected in plastic tubes containing 20 µl of heparin

solution (corresponding to 50 IU). The blood was centrifuged and separated plasma was stored at -70°C. Gastrin was measured, as previously described by radioimmunoassay using antigastrin serum (a gift of Professor S R Bloom, Hammersmith Hospital, London, UK) and synthetic human gastrin I as the standard.<sup>35</sup> The antibody bound and free hormone were separated by dextran coated charcoal, counted separately, and the percentage binding was calculated. The intra-assay variation was below 10%; to avoid interassay variation, all samples were analysed in the same run.

#### STATISTICS

The significance of differences was tested by one way analysis of variance (ANOVA) and Kruskal-Wallis analysis. Correlation analyses were performed according to Pearson.<sup>36</sup> Probability values of <0.05 were regarded as significant. Results are expressed as mean (SEM).

#### Results

##### BODY WEIGHT AND THICKNESS OF NORMAL MUCOSA

Animals treated for 14 days had the same weight gain (from 240 (5) g to 263 (7) g) in all treatment groups. The mean thickness of the corpus mucosa outside the ulcer was 612 (14) µm; no significant difference was found between the groups.

##### SEQUENTIAL ANALYSIS OF ULCER HEALING BY VIDEO ENDOSCOPY

Ulcer diameter on day 1 was 6.2 (0.1) mm (mean (SEM)). In placebo treated rats, speed of ulcer healing expressed as daily reduction of ulcer diameter in percentage of the diameter on day 1, was 8.1 (0.4), 7.0 (0.4), 6.0 (0.4), and 4.0 (0.3) % during days 1-3, 3-8, 8-10, and 10-15 respectively (Fig 3). Antacid, omeprazole, and antacid plus omeprazole significantly accelerated ulcer healing during days 3-8, but did not change healing speed during days 8-15. Acceleration of healing was significantly increased in omeprazole or antacid plus omeprazole compared with antacid treated rats. According to the healing speed time curve, omeprazole plus antacid had no additive effect on healing speed (Figs 3, 4).

##### PROSTAGLANDIN GENERATION EX VIVO IN BIOPSY SPECIMENS

In placebo treated rats, prostaglandin 6-keto-F<sub>1α</sub> concentration in the incubate was 2487 (204) (mean (SEM), n=16) pg/mg and prostaglandin E<sub>2</sub> was 1634 (156) pg/mg biopsy weight. Prostaglandin generation was not significantly affected by the drugs given.

##### HISTOLOGICAL ULCER SIZE

Video endoscopic and histological ulcer sizes were closely ( $r=0.93$ ) correlated. In placebo

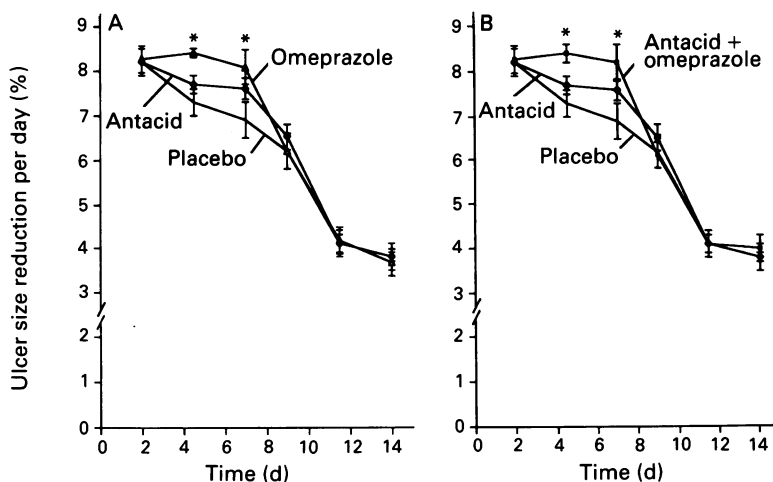


Figure 3: Ulcer healing speed time curve according to video endoscopic measurements. (A) Antacid and omeprazole showed accelerated healing during days 3-8 but not during days 8-15; (B) compared with placebo, antacid plus omeprazole showed accelerated healing during days 3-8, identical to omeprazole. \* $p<0.02$  v placebo and  $p<0.05$  v antacid.

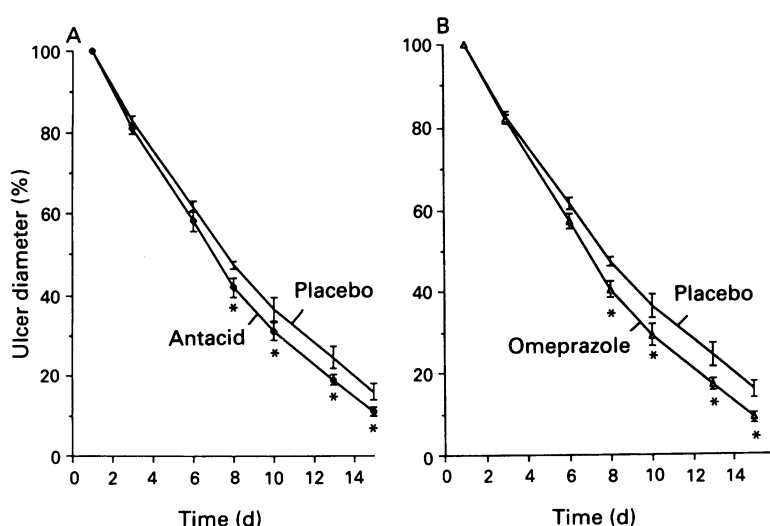


Figure 4: Ulcer diameter time curve according to repeated video endoscopic measurements. Compared with placebo, ulcer diameter was decreased in antacid (A) and omeprazole (B) treated rats on days 8-15. \* $p<0.02$  v placebo.



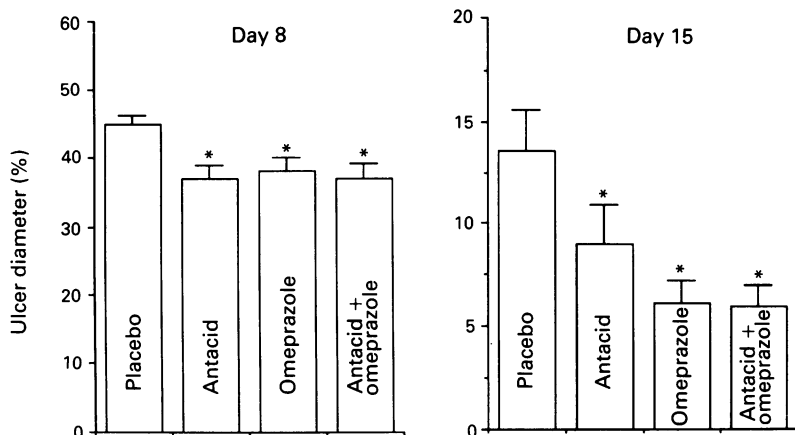
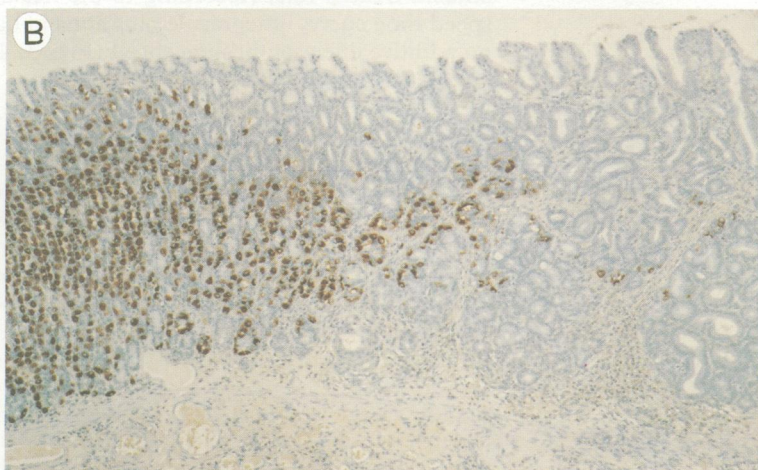
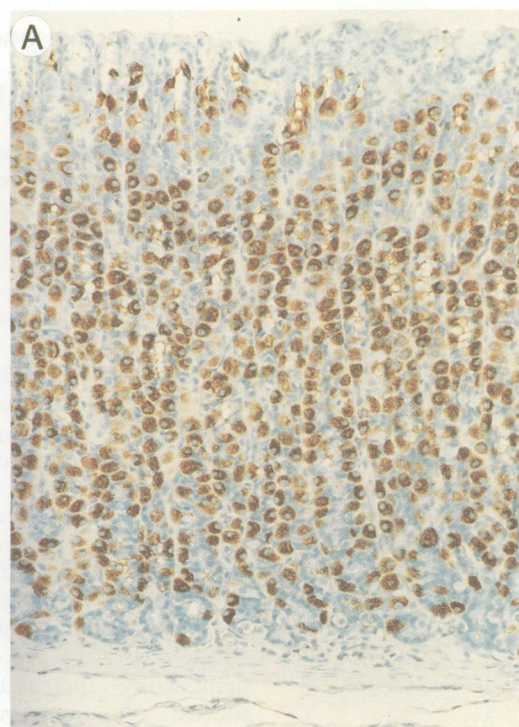


Figure 5: Histological ulcer diameter on day 8 and 15. Compared with placebo, histological ulcer diameter was significantly ( $p < 0.02$ ) decreased in antacid, omeprazole, and antacid plus omeprazole treated rats, both on days 8 and 15. Compared with antacid, histological ulcer diameter on day 15 was significantly ( $p < 0.05$ ) decreased in omeprazole and antacid plus omeprazole treated rats. \* $p < 0.02$  v placebo.

treated rats, histological ulcer diameter expressed as a percentage of the initial ulcer diameter on day 1, was 45 (1) % on day 8 and

Figure 6: (A) Sections (5µm) of rat gastric oxyntic mucosa show that the 80 kDa phosphoprotein is restricted to parietal cells (original magnification  $\times 200$ ); (B) sections of mucosal ulcer scar (day 15) show many parietal cells expressing the 80 kDa phosphoprotein in the normal oxyntic mucosa (left side) and a virtual absence of these cells in the mucosal ulcer scar (right side), thus permitting an easy distinction between normal and remodelled gastric mucosa (original magnification  $\times 100$ ).



14 (2) % on day 15. Compared with placebo, histological ulcer diameter was significantly decreased in antacid, omeprazole, and antacid plus omeprazole treated rats (Fig 5).

QUANTITATIVE HISTOLOGICAL ASSESSMENT

In placebo treated rats, the number of bromodeoxyuridine positive epithelial cells located in a 600 µm wide region of non-ulcerated oxyntic mucosa was 14 (1.3) (0.99 % of total number of mucosal cells); no significant differences were found between the groups. In placebo treated rats, the number of in vivo labelled bromodeoxyuridine positive epithelial cells located in a 600 µm wide region of corpus mucosa adjacent to the ulcer margin on day 8 was 83 (9), which represents a sixfold increase compared with the non-ulcerated mucosa. In antacid treated rats, significantly ( $p < 0.02$  v placebo) more labelled cells (118 (8); +42%) were present in the ulcer margin. In contrast, no significant differences were found between placebo and omeprazole (81 (16) labelled cells) and antacid+omeprazole (86 (14) labelled cells) treated rats.

Immunostaining with the anti-80 kDa phosphoprotein antibody showed a positive reaction in parietal cells of the non-ulcerated mucosa (Fig 6). Control staining (without antibody) did not show any positive reaction. Immunostaining showed a virtual absence of parietal cells expressing the 80 kDa phosphoprotein in the mucosal ulcer scar permitting an easy distinction between normal and remodelled mucosa of the ulcer scar (Fig 6).

Compared with placebo, the mean height of the ulcer margin (day 8) and the mucosal ulcer scar (day 15) was significantly increased in antacid and significantly decreased in omeprazole and antacid plus omeprazole treated rats (Figs 7–9). The epithelial cell mass in the mucosal ulcer margin and scar was significantly increased in antacid group compared with the other treatment groups (Fig 7). In the mucosal ulcer scar on day 15, the ratios of epithelial cells/connective tissue and epithelial cells/gland lumen were significantly increased in antacid group (+73% and +100% respectively) compared with the other treatment groups (Fig 10).

GASTRIN PLASMA CONCENTRATIONS

Gastrin plasma concentrations in fed, female rats were 94 (13) pmol/l (n=64) before treatment. In rats treated for 14 days with omeprazole, gastrin plasma concentrations were significantly ( $p < 0.001$ ) increased by 3.8-fold (3.8 (0.56)) compared with placebo. Antacid had no effect on gastrin plasma concentrations.

Discussion

Healing of gastroduodenal ulcers in different experimental models and in humans shows striking similarities in the morphology of ulcer healing. Regardless of the causes and species, once an ulcer develops, it undergoes the same



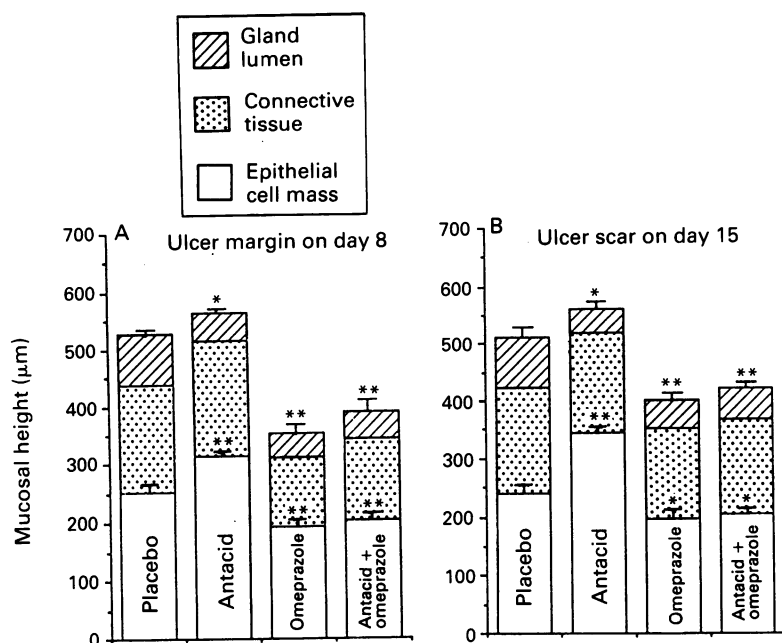


Figure 7: Compared with placebo, the mean height of the mucosal ulcer margin (A) and ulcer scar (B) respectively was significantly higher in antacid and significantly lower in omeprazole and in antacid plus omeprazole treated rats. The total mass of epithelial cells (mucosal height multiplied by the relative amount of epithelial cells) was increased in antacid compared with placebo treated rats (+25% on day 8 and +42% on day 15). \* $p < 0.05$ , \*\* $p < 0.005$ .

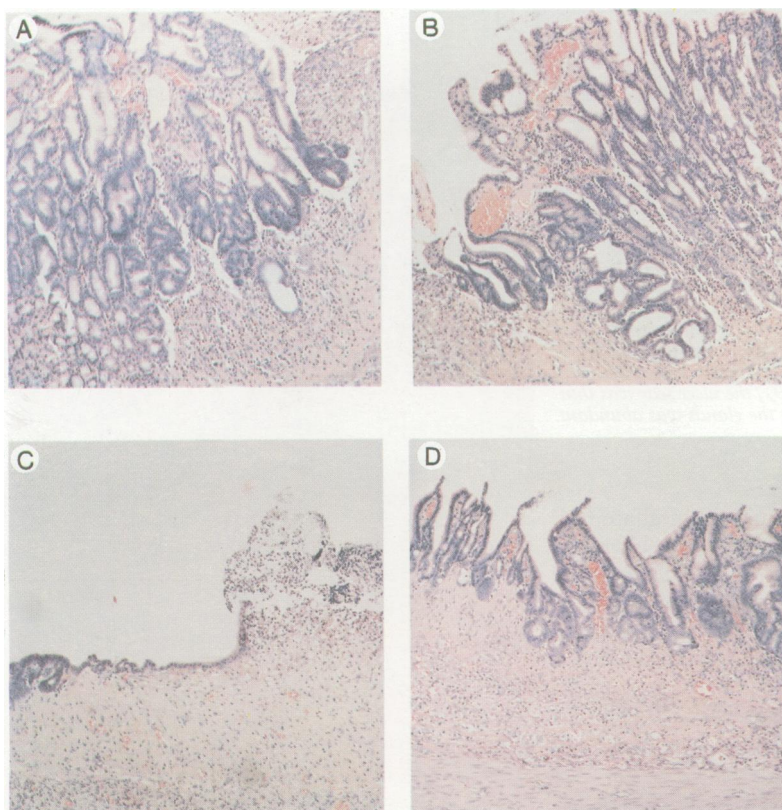


Figure 8: Microscopic appearances of gastric ulcer margin on day 8 (haematoxylin and eosin, original magnification  $\times 100$ ,  $\times 200$ ). In antacid treated rats, (A and B), the ulcer margin was thick and well reconstructed. In omeprazole treated rats (C and D), the ulcer margin was flat and only covered in part by one cell line.

common stages of repair and healing that follows some general principles of the wound healing process.<sup>37</sup> During the healing process, the gastric ulcer healing time curve follows a non-linear, exponential pattern both in humans<sup>38</sup> and in experimental ulcer models.<sup>39</sup> In our rat cryoulcer model, the analysis of the

individual ulcer healing curves, assessed by video endoscopy and quantitative histological examination showed that antacid, omeprazole, and antacid plus omeprazole significantly accelerate the early healing phase between days 3–8. In contrast, ulcer healing speed showed no significant differences between the groups in the late phase of healing. The finding that acid suppression accelerates healing of experimental ulcers only in the early healing phase is consistent with the finding that histamine induced hyperacidity delays ulcer healing also only in the early phase.<sup>39</sup> Comparisons between the treatment groups showed a significant higher speed of ulcer healing in omeprazole and antacid plus omeprazole compared with antacid treated rats. These results are in agreement with peptic ulcer healing studies in humans.<sup>1–14</sup>

Mucosa at the ulcer margin forms a healing zone that undergoes striking changes in structure and cellular composition. This process is mainly controlled by growth factors.<sup>40–42</sup> The dedifferentiated and proliferating cells migrate from the ulcer margin onto the granulation tissue to re-epithelialise the ulcer base when the connective tissue infrastructure permits. Bromodeoxyuridine immunostaining showed that cell proliferation is increased by sixfold in the ulcer margin compared with the non-ulcerated mucosa. Immunostaining for the 80 kDa phosphoprotein present on the apical membrane of mature stimulated parietal cells, permits morphological quantification of dedifferentiation. Gastric corpus wounds in the rat lacks mature parietal cells.<sup>17</sup> In this study, the mucosal ulcer scar showed a virtual absence of cells expressing this 80 kDa phosphoprotein. Thus, this immunostaining technique permits an easy and objective assessment of the border between the normal and remodelled mucosa of the ulcer scar. This distinction is important for objective quantification of all measured parameters.

Compared with placebo, the height of the ulcer margin and mucosal scar was significantly increased in antacid and significantly decreased in omeprazole treated rats. In addition, the epithelial cell mass was profoundly increased in the antacid group compared with the other treatment groups. The height of the ulcer margin is influenced by cell proliferation, cell life span, and cell migration over the ulcer crater. Cell proliferation was significantly increased in antacid, but not in omeprazole treated rats. The height of the mucosal ulcer scar is predominantly influenced by cell proliferation and cell life span while cell migration is less relevant. Histomorphometric analysis of the mucosal ulcer scar showed significantly more glandular epithelial cells, less connective tissue between the glands, and less gland lumen in antacid treated rats. These results support the contention that antacids similar to sucralfate are trophic for glandular epithelial cells in the ulcer scar by increasing cell proliferation probably through enhanced expression of growth factors and their receptors.<sup>21 22 43</sup> As this trophic action has only been seen so far for the two aluminium containing antacids hydroxide and Maalox



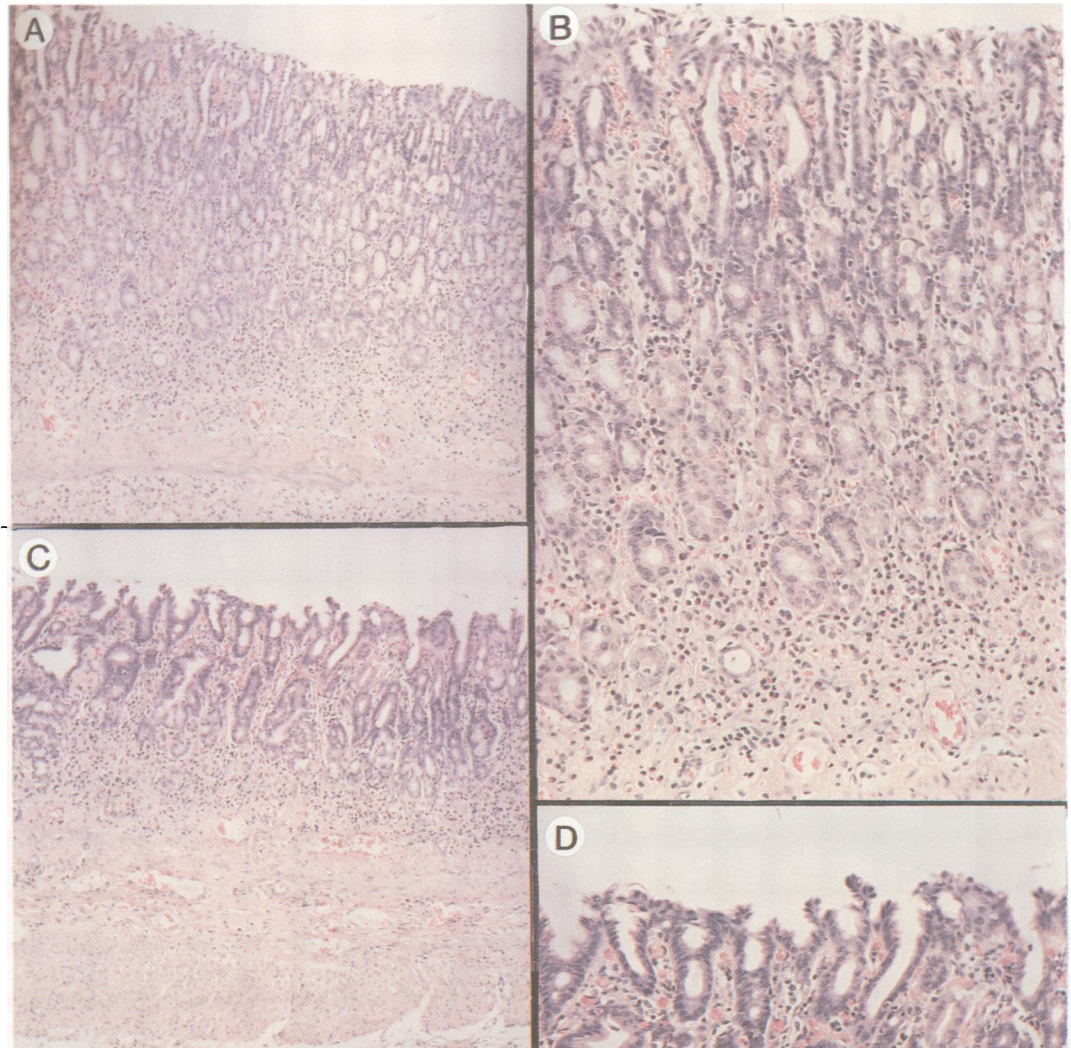


Figure 9: Microscopic appearances of mucosal gastric ulcer scar on day 15 (haematoxylin and eosin, original magnification  $\times 100$ ,  $\times 200$ ). In antacid treated rats (A and B), the ulcer scar was thick, the epithelial glandular structure was well remodelled, the connective tissue between the glands was scarce, and the gland lumen was small. In omeprazole treated rats (C and D), the ulcer scar was thin and the connective tissue between the glands was abundant.

and the aluminium containing sucralfate,<sup>21 22</sup> aluminium may be one of the relevant chemical compounds for this action. Moreover, the gastroprotective activity of antacid is predominantly related to the content of aluminium hydroxide.<sup>44</sup> As generation of prostaglandins is not or only minimally affected by antacid, it seems probable that prostaglandins are not an important mediator of the ulcer healing action of antacid.<sup>45 46</sup>

We have reported that sucralfate increases expression of epidermal growth factor, transforming growth factor  $\alpha$ , and their common receptor in the gastric oxyntic mucosa.<sup>43</sup> Thus, the trophic action of sucralfate on the regenerating mucosa may be mediated by growth factors that increase cell proliferation. It has been reported that the aluminium containing antacid Maalox, sucralfate, and basic fibroblast growth factor increase angiogenesis in granulation tissue of the ulcer base.<sup>26 47 48</sup> It has been suggested that the antacid and sucralfate induced enhancement

of angiogenesis is mediated by endogenous basic fibroblast growth factor.<sup>47 48</sup> As the regenerating mucosa of the scar is dependent on blood supply from the granulation tissue, the quality of the mucosal ulcer scar is possibly related to the trophic action of antacids both on epithelial cells and angiogenesis.

Omeprazole accelerated ulcer healing without increasing cell proliferation and without a significant increase of epithelial cells within the mucosal ulcer scar. Thus, it seems that the increased speed of ulcer healing seen during

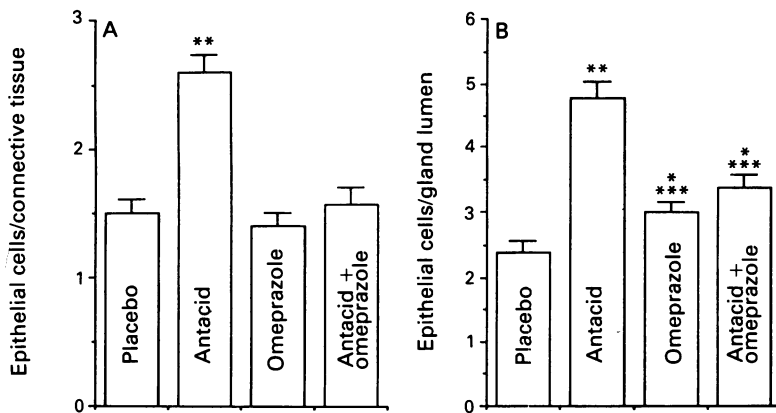


Figure 10: Cellular composition of mucosal ulcer scar on day 15. The ratios of epithelial cells/connective tissue (A) and epithelial cells/gland lumen (B) were significantly increased in antacid treated rats compared with the other treatment groups. \* $p < 0.05$  v placebo, \*\* $p < 0.005$  v placebo, \*\*\* $p < 0.05$  v antacid.

omeprazole treatment is predominantly due to accelerated migration of cells over the granulation tissue of the ulcer crater and not from a trophic effect. Whether this immature ulcer scar will undergo subsequent remodelling and whether this is also true in humans needs further studies.

The combined treatment antacid plus omeprazole shows no significant improvement of ulcer healing over omeprazole treatment alone. The trophic effect of the antacid on the ulcer margin and scar was nearly abolished by concomitant treatment with omeprazole. These results show that an acid environment is necessary for the full expression of the trophic actions of antacid. These results are similar to those reported in cytoprotection studies, showing that acidified antacid are several fold more effective than non-acidified antacid.<sup>45 49</sup>

We conclude that antacid, omeprazole, and antacid plus omeprazole accelerate experimental gastric ulcer healing, but antacid provides better quality of healing. This advantage is lost by cotreatment with omeprazole.

This study was supported by a Swiss National Science Foundation (grant: 32-26478-89) and Medical Research Service of Department of Veterans Affairs, USA. Parts of this study have been presented in abstract form at the AGA, 15-21 May, 1993, Boston.

- Peterson WL, Sturdevant RAL, Frankl HD, Richardson CT, Isenberg JJ, Elashoff JD, et al. Healing of duodenal ulcer with an antacid regimen. *N Engl J Med* 1977; 267: 341-5.
- Ippoliti AF, Sturdevant RAL, Isenberg JJ, Binder M, Camacho R, Cano R, et al. Cimetidine versus intensive antacid therapy for duodenal ulcer. *Gastroenterology* 1978; 74: 393-5.
- Ippoliti AF, Elashoff J, Valenzuela J, Cano R, Frankl H, Samloff M, et al. Recurrent ulcer after successful treatment with cimetidine or antacids. *Gastroenterology* 1983; 85: 875-80.
- Lauritsen K, Bytzer P, Hansen J, Bekker C, Rask-Madsen J. Comparison of ranitidine and high-dose antacid in the treatment of prepyloric or duodenal ulcer: a double-blind controlled trial. *Scand J Gastroenterol* 1985; 20: 123-8.
- Bianchi Porro G, Parente F, Lazzaroni M, Baroni S, Panza E. Medium-dose antacids versus cimetidine in the short-term treatment of duodenal ulcer. *J Clin Gastroenterol* 1986; 8: 141-5.
- Isenberg JJ, Peterson WL, Elashoff JD, Sandersfeld MA, Reedy TJ, Ippoliti AF, et al. Healing of benign gastric ulcer with low-dose antacid or cimetidine. A double-blind, randomized, placebo-controlled trial. *N Engl J Med* 1983; 308: 1319-24.
- Holtermüller KH, Liskay M, Bernard I, Haase W. Therapie des Ulcus ventriculi - Ein Vergleich zwischen dem niedrig dosierten Antazidum Hydroxalcit und Ranitidin - Ergebnisse einer randomisierten multizentrischen Doppelblindstudie. *Z Gastroenterol* 1992; 30: 717-21.
- Fordtran JS, Morawski SG, Richardson CT. In vivo and in vitro evaluation of liquid antacid. *N Engl J Med* 1973; 288: 923-8.

- Massarrat S, Eisenmann A. Factors affecting the healing rate of duodenal ulcer and pyloric ulcer with low dose antacid treatment. *Gut* 1981; 22: 97-102.
- Berstad A, Rydning A, Aadland E, Kolstad B, Frislid KL, Aaseth J. Controlled clinical trial of duodenal ulcer healing with antacid tablets. *Scand J Gastroenterol* 1982; 17: 953-9.
- Kumar N, Vij JC, Karol A, Anand BS. Controlled therapeutic trial to determine the optimum dose of antacids in duodenal ulcer. *Gut* 1984; 24: 1199-202.
- Blum AL. Stellung der Antacida in der modernen Ulcusterapie. *Dtsch Med Wochenschr* 1985; 110: 3-7.
- Lauritsen K, Rune SJ, Bytzer P, Kelbaek H, Jensen KG, Rask-Madsen J, et al. Effect of omeprazole and cimetidine on duodenal ulcer: a double-blind comparative trial. *N Engl J Med* 1985; 312: 958-61.
- Walan A, Bader JP, Classen M, Lamers CBHW, Piper DW, Rutgersson K, et al. Effect of omeprazole and ranitidine on ulcer healing and relapse rates in patients with benign gastric ulcer. *N Engl J Med* 1989; 320: 69-75.
- Tarnawski A, Hollander D, Krause WJ, Dabros W, Stachura J, Gergely H. 'Healed' experimental gastric ulcers remain histologically and ultrastructurally abnormal. *J Clin Gastroenterol* 1990; 12 (suppl 1): 139-47.
- Tarnawski A, Stachura J, Krause WJ, Douglass T, Gergely H. Quality of gastric ulcer healing: a new, emerging concept. *J Clin Gastroenterol* 1991; 13 (suppl 1): 42-7.
- Helander HE. Morphologic studies on the margin of gastric corpus wounds in the rat. *J Submicrosc Cytol* 1983; 15: 627-43.
- Fullman H, Van Deventer G, Schneidman D, Walsh J, Elashoff J, Weinstein W. 'Healed' duodenal ulcers are histologically ill. *Gastroenterology* 1985; 88: 1390.
- Bode G, Malfertheiner P, Mader U, Stanescu A, Ditschuneit H. Fine structure of active and healed duodenal ulcer. *Am J Gastroenterol* 1991; 86: 179-86.
- Litman A, Hanscom DH. The course of recurrent ulcer. *Gastroenterology* 1971; 61: 585-91.
- Tarnawski A, Douglass TG, Ishikawa T, Gergely H. Does antacid treatment provide better quality of experimental gastric ulcer healing than omeprazole? *Gastroenterology* 1992; 102: A175.
- Tarnawski A, Ichikawa Y, Stachura J, Douglass TG, Sarfeh IJ. Effect of sucralfate on the quality of experimental gastric ulcer healing - quantitative histologic assessment. *Gastroenterology* 1993; 104: A206.
- Inauen W, Wyss PA, Kayser S, Baumgartner A, Schürer-Maly CC, Koelz HR, et al. Influence of prostaglandins, omeprazole, and indomethacin on healing of experimental gastric ulcers in the rat. *Gastroenterology* 1988; 95: 636-41.
- Meyrat P, Baumgartner A, Kappeler M, Halter F. Simple gastroscopy technique in the rat. *Dig Dis Sci* 1984; 29: 327-9.
- Schmassmann A, Varga L, Flogerzi B, Halter F. A new endoscopic ulcer model in the rat: endoscopic ulcer induction by acetic acid and videoendoscopic assessment of healing by sequential morphometric analysis. *Digestion* 1991; 49 (suppl 1): 51-2.
- Tarnawski A, Halter F, Schmassmann A, Vatie J, Garner A. Experimental models for the assessment of antacid action on gastrointestinal mucosa and ulcer healing. *Eur J Gastroenterol Hepatol* 1992; 4: 966-76.
- Schnekenburger J. Struktur und Wirkmechanismus von Antacida. *Schwerpunkt Medizin* 1988; 11: 37-45.
- Peskar BM, Lange K, Hoppe U, Peskar BA. Ethanol stimulates formation of leukotriene C4 in rat gastric mucosa. *Prostaglandins* 1986; 31: 283-93.
- Peskar BM. Role of leukotriene C4 in mucosal damage caused by necrotizing agents and indomethacin. *Gastroenterology* 1991; 100: 619-26.
- Gratzner HG. Monoclonal antibody to 5-bromo- and 5-iododeoxy-uridine: a new reagent for detection of DNA replication. *Science* 1982; 218: 474-5.
- Naish SJ. *Handbook for chemical staining methods*. Carpinteria, Ca: Dako Corporation, 1989.
- Hanzel DK, Urushidani T, Usinger WR, Smolka A, Forte JG. Immunological localization of an 80-kDa phosphoprotein to the apical membrane of gastric parietal cells. *Am J Physiol* 1989; 256: G1082-9.
- Hanzel D, Reggio H, Bretscher A, Forte JG, Mangeat P. The secretin stimulated 80K phosphoprotein of parietal cells is ezrin, and has properties of a membrane cytoskeletal linker in the induced apical microvilli. *EMBO J* 1991; 10: 3978-81.
- Yao X, Thibodeau A, Forte JG. Ezrin-calpain I interactions in gastric parietal cells. *Am J Physiol* 1993; 265: C36-46.
- Witzel L, Heitz PU, Halter F, Olah AJ, Varga L, Werner O, Häcki WH. Effects of prolonged administration of metiamide on serum gastrin, gastrin content of the antrum and gastric corpus and G-cell population in the rat. *Gastroenterology* 1979; 76: 945-9.
- Sachs L. *Angeordnete Statistik*. Berlin, Heidelberg, New-York: Springer, 1973.
- Peacock EE. Wound healing and wound care. In: Schwartz SJ, ed. *Principles of surgery. Mechanism of ulcer healing*. New York: McGraw-Hill, 1969: 226-48.
- Scheurer U, Witzel L, Halter F, Keller HM, Huber R, Galeazzi R. Gastric and duodenal ulcer healing under placebo treatment. *Gastroenterology* 1977; 72: 838-41.
- Halter F, Barbezat GO, Van Hoorn-Hickman R, Van Hoorn WA. Healing dynamics of traumatic gastric mucosal defects in the normal and hyperacid stomach. *Dig Dis Sci* 1980; 25: 916-20.



- 40 Skov Olsen P, Poulsen SS, Therkelsen K, Nexø E. Effect of sialoadenectomy and synthetic human urogastrone on healing of chronic gastric ulcers in rats. *Gut* 1986; **27**: 1443-9.
- 41 Konturek SJ, Dembinski A, Warzech Z, Brzozowski R, Gregory H. Role of epidermal growth factor in healing of chronic gastroduodenal ulcers in rats. *Gastroenterology* 1988; **94**: 1300-7.
- 42 Wright NA, Pike C, Elia G. Induction of a novel epidermal growth factor-secreting cell lineage by mucosal ulceration in human gastrointestinal stem cells. *Nature* 1990; **343**: 1300-7.
- 43 Tarnawski A, Stachura J, Durbin T, Gergely H, Douglass TG. Sucralfate treatment induces increased expression of EGF, TGF $\alpha$  and their common receptor in the gastric mucosa. A key to the ulcer healing and trophic action? *Gastroenterology* 1993; **104**: A206.
- 44 Konturek SJ, Brzozowski T, Drozdowicz D, Nauert C. Gastroprotection by an aluminium- and magnesium hydroxide-containing antacid in rats. *Scand J Gastroenterol* 1989; **24**: 1113-20.
- 45 Konturek SJ, Brzozowski T, Drozdowicz D, Dembinski A, Nauert C. Healing of chronic gastroduodenal ulcerations by antacids. *Dig Dis Sci* 1990; **35**: 1121-9.
- 46 Lambrecht N, Trautmann M, Korolkiewicz R, Liskay M, Peskar BM. Role of eicosanoids, nitric oxide, and afferent neurons in antacid induced protection in the rat stomach. *Gut* 1993; **34**: 329-37.
- 47 Folkman J, Szabo S, Stovroff M, McNeil P, Li W, Shing Y. Duodenal ulcer: discovery of a new mechanism and development of angiogenic therapy that accelerates healing. *Ann Surg* 1991; **214**: 414-27.
- 48 Szabo S. The mode of action of sucralfate: the 1 $\times$ 1 $\times$ 1 mechanism of action. *Scand J Gastroenterol Suppl* 1991; **185**: 7-12.
- 49 Konturek SJ, Brzozowski T, Garlicki J, Majka J, Stachura J, Nauert C. Intra-gastric pH in the gastroprotective and ulcer-healing activity of aluminium-containing antacids. *Digestion* 1991; **49**: 140-50.