

Leading article – Tropical infection of the gastrointestinal tract and liver series

Gastrointestinal manifestations of schistosomiasis

Schistosoma sp cause considerable disease in the intestinal tract and liver. All species of this blood fluke infecting humans have this capability regardless of their primary target tissue: *S japonicum* primarily reside in mesenteric veins of the small intestine; *S mansoni* reside chiefly in the mesenteries of the large gut; and *S haematobium* inhabit the venous plexus of the urinary bladder. In residence, adult female schistosomes lay ova (from about 100/day per worm pair in the case of *S haematobium* to 500 to 3500/day/pair in the case of *S japonicum*) in the distal end of the predestined venous plexus. Some of the eggs (usually about half) work their way through the intestinal or bladder walls into the gut or urinary bladder. If, after being passed in urine or faeces, the ova reach fresh water, a larval stage (miracidium) of the parasite hatches and swims about seeking its specific freshwater snail intermediate host to continue its life cycle for transmitting the infection.

Gastrointestinal pathophysiology

The eggs that are retained in the body are of interest to clinicians because they are the principal cause of disease in schistosomiasis. Many ova are swept into the hepatic sinusoids of the liver where they provoke periportal fibrosis and, subsequently, portal hypertension. Other ova are retained in the intestinal wall where they may lead to intestinal bleeding and protein loss, intestinal polyposis, and other complications. There is a direct correlation, at least in children, between the amount of disease and the intensity of infection as measured by number of ova excreted in the stool and urine.

Most patients with schistosomiasis have the chronic form of the infection, which is caused by a granulomatous response around these retained ova.¹ The inciting factors are soluble antigens released from the eggs. The granuloma, changing somewhat as it matures, is composed

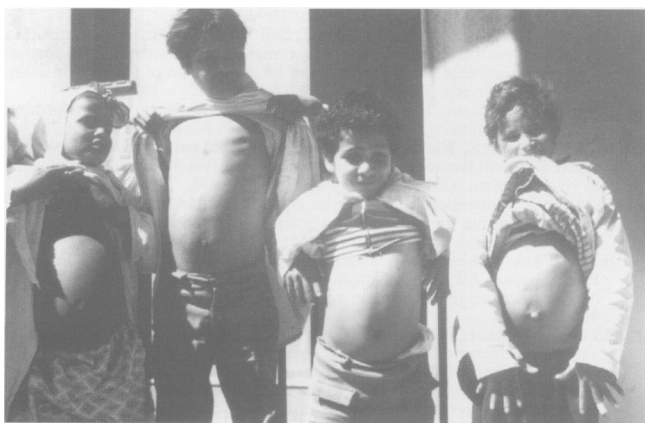

Figure 1: Egyptian boys admitted to the Tropical Medicine Department inpatient unit at Kasr El Aini Hospital for evaluation of hepatosplenomegaly. They all had high egg counts of *S mansoni* in their stools without other detectable causes for the liver and spleen enlargement.

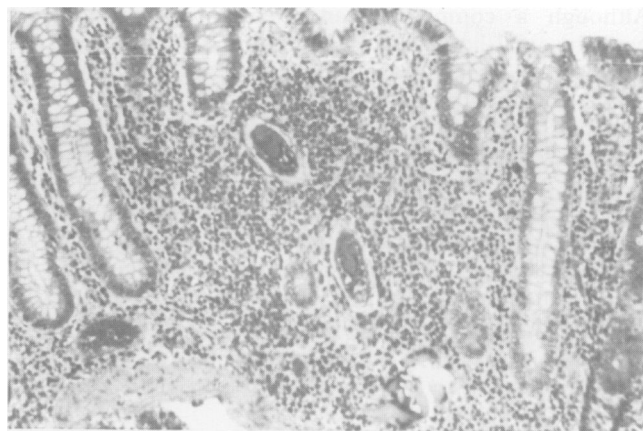


Figure 2: Rectal biopsy specimen from Egyptian patient with gastrointestinal schistosomiasis stained with haematoxylin and eosin. *S mansoni* ova are present in the mucosa and submucosa along with cellular infiltrate of erythrocytes and leucocytes.

of lymphocytes, eosinophils, macrophages, and multinucleated giant cells. Recent investigations in rodent models of infection have shown that lymphocytes and macrophages within the granuloma secrete cytokines and other factors, which promote fibrogenesis, and ultimately hepatic fibrosis. Chronic murine *S mansoni* infections cause an imbalance in thymus helper cell activity with an increase in Th2 subset activity and cytokines, which induce immunoglobulin E and eosinophils and concomitantly down regulate the Th1 subset with reduced interferon gamma and interleukin 2 production.^{2 3}

The morbid immune response to schistosomiasis is complex and has been extensively studied. Of particular interest is down regulation of granulomatous inflammation subsequent to the initial infection.⁴ A hypothesis to explain why only a small percentage of subjects with chronic infections develop severe complications, for example, Symmer's pipe-stem fibrosis, intestinal polyposis, is that this immunosuppressive adaptation fails to develop.

Clinical gastrointestinal schistosomiasis

Acute schistosomiasis syndrome, an immune complex reaction, almost never occurs in those from endemic areas. Schistosomiasis presents as a chronic disease because of extensive and repeated exposures and treatment. Factors (for example, anti-idiotypic antibodies, schistosomal antigens) passed from immune mothers to fetuses and infants are important in the expression of disease. Maternal to fetal immunity provides both protection during the first few months of life as well as down regulation of the initial immune response responsible for acute schistosomiasis.⁵

Endemic gastrointestinal schistosomiasis is almost always insidious in onset. Most often the infected child does not seek medical assistance because the symptomatology is not considered abnormal. They may report a

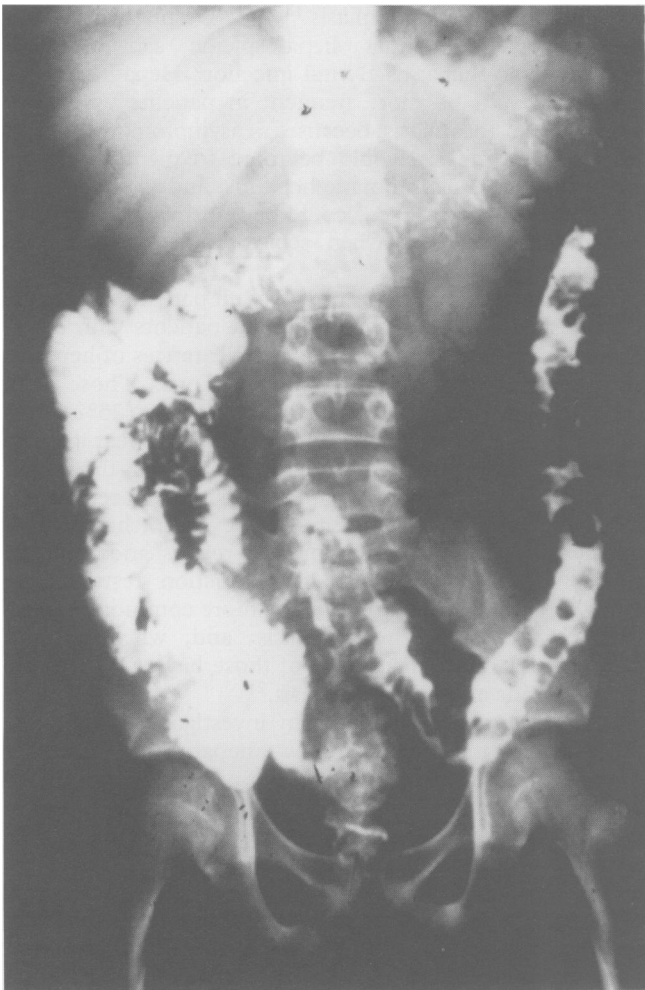


Figure 3: Barium enema of the colon showing intestinal polyposis in an Egyptian patient who was heavily infected with *S. mansoni*.

pricking sensation of the skin at the time of, or shortly after, bathing or other water exposure. This is sometimes followed by the characteristic swimmer's itch, a pruritic, erythematous, papular eruption. Intermittent blood and mucus in the stool has been associated with the presence of, and intensity of infection.⁶ Diarrhoea and jaundice, however, are no more common in schistosome infected than in non-infected children from the same communities. Characteristic clinical signs are the presence of an enlarged liver and spleen. In *S. mansoni* endemic areas of Brazil enlargement of the right hepatic lobe has been particularly noted. Before the wide availability of praziquantel chemotherapy, the presence of, and magnitude of, hepatosplenomegaly correlated with the intensity of infection.⁶ A characteristic syndrome, Egyptian splenomegaly, was highly associated with endemic schistosomiasis.⁷

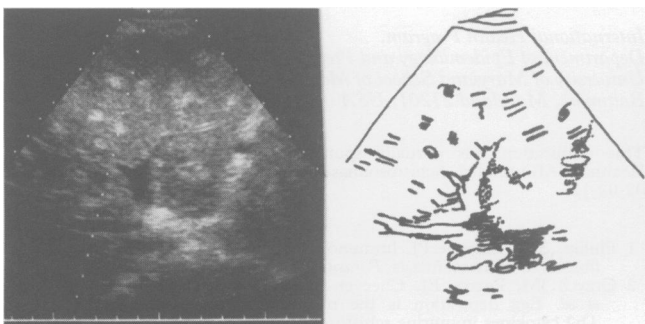


Figure 4: Abdominal ultrasound of an Egyptian patient showing grade II periportal fibrosis with a widening of the distal portal tracts. (Reprinted with permission from *Trans R Soc Trop Med Hyg* 1993; 87: 132-7.

Children, almost always boys, presented with abdomens distended by massively enlarged livers and spleens (Fig 1). These boys came from villages endemic for schistosomiasis *mansoni* and usually had very heavy infections with greater than 1000 ova/g of stool.

Laboratory abnormalities associated with endemic schistosomiasis include eosinophilia, mild to moderate anaemia, and an increase in immune globulin values, mostly immunoglobulin G, and alkaline phosphatase.⁶ Liver function tests were usually normal unless the patient had a concomitant viral hepatitis. In addition to schistosome eggs, the infected patient also usually had red cells and mucus in their stools. Rectal biopsy specimens almost always showed ova in the mucosa and submucosa along with inflammation and haemorrhage (Fig 2).

The most common complication of gastrointestinal schistosomiasis, periportal fibrosis, leads to portal hypertension and resultant upper gastrointestinal haemorrhage. It is unusual for a patient with chronic gastrointestinal schistosomiasis to develop high grade periportal fibrosis, called Symmer's pipe stem fibrosis, but the large number of infected subjects in endemic areas makes bleeding from oesophageal varices an important cause of morbidity and mortality in these communities. If bleeding can be stopped (usually with sclerotherapy), the portal hypertension can be reduced (with a combination of specific chemotherapy for the schistosomiasis and a shunt operation) and repeat infections are prevented, the prognosis is good as liver function remains comparatively normal unless the patient has concomitant chronic hepatitis or cirrhosis.

Another less frequent complication, which occurs more often in Egypt than in Brazil and elsewhere, is intestinal polyposis, which is caused by an exudative response to eggs retained in the wall of the large bowel. The patient complains of frequent bloody loose stools and usually has anaemia and hypoproteinaemia. Polyps can be detected by barium enema (Fig 3) and colonoscopy and may clear after praziquantel treatment. Those that persist can usually be removed during colonoscopy and rarely require surgery. Hepatic failure with jaundice, ascites, small shrunken livers, and abnormal liver function tests occurs in some patients with chronic gastrointestinal schistosomiasis but they almost always have additional complications of hepatitis B and C.

Abdominal ultrasonography

The recent introduction of diagnostic ultrasonography, which uses a pulse echo device to record reflected waves of a sound beam in two dimensions, has revolutionised the evaluation of schistosomal morbidity.^{8,9} The technique has the following advantages. It is comparatively inexpensive and rapid; produces images in real time; can provide images in any plane without revision of the format; causes no biological hazard when used in the diagnostic range; is

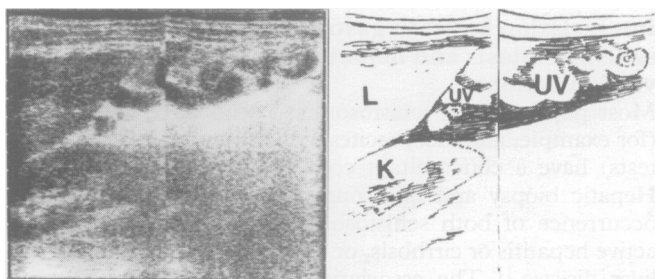


Figure 5: Abdominal ultrasound in an Egyptian man with cirrhosis of the liver with portal hypertension showing a considerably dilated umbilical vein (UV). Please note the normal right kidney (K) and the right lobe of the liver (L).

portable and easily used in communities^{8 10}; and because of its speed, is ideal for screening populations and directing interventions, for example, biopsies and aspirations. Abdominal ultrasound can accurately measure liver and spleen size and configuration and detect and grade periportal fibrosis (Fig 4)^{11 12} and portal hypertension (Fig 5). The technique can accurately and safely predict the presence and magnitude of oesophageal varices and risk of upper gastrointestinal haemorrhage by using a scoring system based upon the grade of periportal fibrosis, portal vein diameter, spleen size, and portasystemic anastomoses.¹³ When it is used to screen randomly selected representative populations, the data generated show that hepatic abnormalities are common in populations exposed to *S mansoni*, that the lesions are often asymptomatic, and in the earlier stages are reversible with praziquantel treatment.^{8 10 14}

Gastrointestinal manifestations of *S haematobium* infection

Adult flukes of *S haematobium* primarily reside in the venous plexus of the urinary bladder. Ova pass through the bladder wall and out in the urine. Therefore, pathophysiology of schistosomiasis haematobia is almost exclusively limited to the genitourinary tract. About 20 years ago, however, physicians in upper Egypt, where only *S haematobium* was endemic, began to occasionally report patients having hepatosplenomegaly with no evidence of past or present infection with *S mansoni*, or other causes for the liver lesions.¹⁵ These patients had *S haematobium* egg granulomas and schistosomal fibrosis in liver biopsy specimens. Other evidence suggesting *S haematobium* can cause periportal fibrosis is the frequency that its ova could be detected in rectal snip biopsy specimens. In fact, this remains a means of diagnosing schistosomiasis haematobia in patients who are not excreting the eggs in their urine.

Abdominal ultrasound provided a means of confirming that *S haematobium* infection could cause periportal fibrosis. I recently collaborated with two Egyptian groups performing epidemiological investigations of schoolchildren in upper¹⁶ and middle¹⁷ Egypt, areas endemic for *S haematobium*, but not *S mansoni*. The methodology differed, but the results were similar: hepatomegaly, splenomegaly, and borderline or grade I periportal fibrosis were frequently present in the children in the two communities. All three abnormalities were more frequently present in children having *S haematobium* infections than in those not having ova in their urine. In addition, a control population matched for age and sex from a nearby city where exposure to *S haematobium* is very rare had virtually no hepatomegaly, splenomegaly or periportal fibrosis detected by ultrasound. The subject of hepatic lesions caused by *S haematobium* infection remains controversial, and to this point, it has only been reported in middle and upper Egypt.¹⁵⁻¹⁷

Interrelation between gastrointestinal schistosomiasis and hepatitis B and hepatitis C viral infections

Most patients with schistosomiasis who have liver failure (for example, jaundice, ascites, and abnormal liver function tests) have a concomitant complication of viral hepatitis. Hepatic biopsy and ultrasound have shown the frequent occurrence of both schistosomiasis mansoni and chronic active hepatitis or cirrhosis, or both, in patients with chronic liver disease.¹¹ The association between hepatitis B and hepatosplenic schistosomiasis has been reported from Brazil,¹⁸ upper Egypt,¹⁹ and the Philippines.²⁰ These studies did not show an increased risk for hepatitis B infection in

patients with schistosomiasis.^{18 19 21} Despite this, it is generally believed that hepatosplenic schistosomiasis predisposes to hepatitis B viral infection. Hepatitis B viral infection could be more frequent in patients with, than without, schistosomiasis: because (a) asymptomatic patients with schistosomiasis would be more frequently detected when they have symptomatic hepatitis; and (b) hepatitis B (and probably hepatitis C) could be transmitted by reusing contaminated needles when schistosomiasis was treated parenterally.²²

A recent follow up study of 145 adult patients with acute viral hepatitis has clearly shown that patients with active *S mansoni* infection have prolonged clearances of hepatitis B (and probably hepatitis C) infections. Those with concomitant infections had a threefold greater (25% v 9%) carrier rate of hepatitis B surface antigen one year after an acute hepatitis B infection in comparison with those who did not have *S mansoni* ova in their stools or rectal snip biopsy specimens. In addition, they also had higher mean values for liver function test results and a higher percentage with abnormal liver function tests during follow up visits. Splenomegaly was more common in those with concomitant schistosomiasis, and, when present, persisted for one year in 69% of those having both acute viral hepatitis and schistosomiasis.²¹

Very recent data, again from investigations with two different Egyptian groups, shows hepatitis C antibodies were present in 47.2% and 73.5% of patients who were being evaluated for chronic liver disease (submitted data). As expected, the anti-HCV rate was higher in those exhibiting complications of viral hepatitis (that is, chronic active hepatitis, cirrhosis, hepatocellular carcinoma) than in those with schistosomal hepatic fibrosis. The anti-HCV rates in the second group (33%) were, however, about 50% greater than that of the general adult population (about 20%), which includes many with schistosomal infections. The odds ratio of having an active *S mansoni* infection (in comparison with no or inactive infections) was 2.1 ($p=0.002$) in 1023 Egyptian patients with chronic liver disease. Clearly, there is a relation in rural areas of Egypt between schistosomiasis mansoni and hepatitis C infection. This virus could have been transmitted, as was mentioned for hepatitis B infection, with the reuse of needles for parenteral treatment for schistosomiasis. I believe endemic schistosomiasis is an important reason for the very high prevalence of HCV infection in Egypt and do not think the reuse of contaminated needles fully explains this association. A recent study showing an imbalance in T helper cell subsets in mice infected with *S mansoni* results in a delayed clearance of a viral infection after challenge²³ encourages me to use this approach for investigating the interrelation between schistosomiasis mansoni and hepatitis B and C infections.

G THOMAS STRICKLAND

International Health Program,
Department of Epidemiology and Preventive Medicine,
University of Maryland School of Medicine,
Baltimore, Maryland 21201, USA

This publication was partially sponsored by the Egyptian Ministry of Health/USAID-funded Schistosomiasis Research Project, 263-014.2, grant 02-02-12.

- 1 Phillips SM, Lammie PJ. Immunopathology of granuloma formation and fibrosis in schistosomiasis. *Parasitol Today* 1986; 2: 296-302.
- 2 Grzych JM, Pearce EJ, Cheever A, Caulada ZA, Caspar P, Heiny S, et al. Egg deposition is the major stimulus for the production of Th2 cytokines in murine schistosomiasis mansoni. *J Immunol* 1991; 146: 1323-7.
- 3 Sher A, Fiorentino D, Caspar P, Pearce E, Mosmann T. Production of IL-10 by CD4⁺ T lymphocytes correlates with down regulation of Th1 cytokine synthesis in helminth infection. *J Immunol* 1991; 147: 2713-6.

- 4 Ottesen EA, Hiatt RA, Cheever A, Sotomayor ZR, Neva FA. The acquisition and loss of antigen-specific cellular immune responsiveness in acute schistosomiasis in man. *Clin Exp Immunol* 1978; **33**: 38–45.
- 5 Colley DG, Montesano MA, Elio-Santos SM, Powell MR, Parra JC, Toes A. Idiotypic networks in schistosomiasis. In: McAdam KPWJ, ed. *New strategies in parasitology*. Edinburgh: Churchill Livingstone, 1989: 179–90.
- 6 Strickland GT, Merritt W, El-Sahly A, Abdel-Wahab F. Clinical characteristics and response to therapy in Egyptian children heavily infected with *Schistosoma mansoni*. *J Infect Dis* 1982; **146**: 20–9.
- 7 Hashem M. The etiology and pathogenesis of the endemic form of hepatosplenomegaly: 'Egyptian splenomegaly'. *J Egypt Med Assoc* 1947; **30**: 48–79.
- 8 Strickland GT, Abdel-Wahab MF. Abdominal ultrasonography for assessing morbidity from schistosomiasis. 1. Community studies. *Trans R Soc Trop Med Hyg* 1993; **87**: 132–4.
- 9 Abdel-Wahab MF, Strickland GT. Abdominal ultrasonography for assessing morbidity from schistosomiasis. 2. Hospital studies. *Trans R Soc Trop Med Hyg* 1993; **87**: 135–7.
- 10 Abdel-Wahab MF, Esmat G, Narooz SI, Yosery A, Struewing JP, Strickland GT. Sonographic studies of schoolchildren in a village endemic for *Schistosoma mansoni*. *Trans R Soc Trop Med Hyg* 1990; **84**: 69–73.
- 11 Abdel-Wahab MF, Esmat G, Milad M, Abdel-Razek S, Strickland GT. Characteristic sonographic pattern of schistosomal hepatic fibrosis. *Am J Trop Med Hyg* 1992; **40**: 72–6.
- 12 Abdel-Wahab MF, Esmat G, Farrag A, El-Boraey YA, Strickland GT. Grading of hepatic schistosomiasis by the use of ultrasonography. *Am J Trop Med Hyg* 1992; **46**: 403–8.
- 13 Abdel-Wahab MF, Esmat G, Farrag A, El-Boraey Y, Strickland GT. Ultrasonographic prediction of esophageal varices in schistosomiasis *mansoni*. *Am J Gastroenterol* 1993; **88**: 560–3.
- 14 Homeida MA, El-Tom IA, Sulaiman SM, DaFalla AA, Bennett JL. Efficacy and tolerance of praziquantel in patients with *Schistosoma mansoni* infection and Symmer's fibrosis: a field study in the Sudan. *Am J Trop Med Hyg* 1988; **38**: 495–8.
- 15 Nooman ZM, Nafeh MA, El-Kateb H, Atta SM, Ezzat ES. Hepatosplenic disease caused by *Bilharzia haematobium* in Upper Egypt. *J Trop Med Hyg* 1974; **77**: 42–8.
- 16 Nafeh MA, Medhat A, Swifae Y, Mofteh FM, Mohamed A, Soliman A-GA, et al. Ultrasonographic changes of the liver in *Schistosoma haematobium* infection. *Am J Trop Med Hyg* 1992; **47**: 225–30.
- 17 Abdel-Wahab MF, Esmat G, Ramzy I, Fouad R, Abdel-Rahman M, Yosery A, et al. *Schistosoma haematobium* infection in Egyptian schoolchildren: demonstration of both hepatic and urinary tract morbidity by ultrasonography. *Trans R Soc Trop Med Hyg* 1992; **86**: 406–9.
- 18 Lyra LD, Reboucas G, Andrade ZA. Hepatitis B surface antigen carrier state in hepatosplenic schistosomiasis. *Gastroenterology* 1976; **71**: 641–5.
- 19 Nooman ZM, Khalil M, Nafeh M, Elwan SI, El-Sharkaive M, Omar AM, et al. Behavior of hepatitis B antigen in bilharzial patients infected with HBsAg positive viral hepatitis. *Egypt J Bilharziasis* 1978; **4**: 79–87.
- 20 Domingo EO, Lingao AL, Tui E, Lao JY, Olveda RM. HBV exposure and HbsAg positivity rates in schistosomiasis japonica: study in a Philippine community endemic for both infections. *Southeast Asian J Trop Med Public Health* 1983; **14**: 456–62.
- 21 Ghaffar YA, Fattah SA, Kamel M, Badr RM, Mahomed FF, Strickland GT. The impact of endemic schistosomiasis on acute viral hepatitis. *Am J Trop Med Hyg* 1991; **45**: 743–50.
- 22 Madwar MA, El Tahawy M, Strickland GT. The relationship between uncomplicated schistosomiasis and hepatitis B infection. *Trans R Soc Trop Med Hyg* 1989; **83**: 233–6.
- 23 Actor JK, Shairai M, Kuhlberg MC, Buller RML, Sher A, Berzofsky JA. Helminth infection results in decreased virus-specific CD8⁺ cytotoxic T-cell cytokine responses as well as delayed virus clearance. *Proc Natl Acad Sci USA* 1983; **90**: 948–52.