

Mesalazine induced interstitial nephritis

P J Thuluvath, M Ninkovic, J Calam, M Anderson

Abstract

5-Aminosalicylic acid (5-ASA) has structural similarities to both phenacetin and aspirin, which are known to cause 'analgesic nephropathy'. Because of the increasing use of 5-ASA, this paper draws attention to two cases of severe interstitial nephritis resulting from 5-ASA and emphasises the importance of monitoring renal functions of patients with inflammatory bowel disease who are receiving 5-ASA preparations.

(Gut 1994; 35: 1493-1496)

Sulphasalazine was until recently the preferred drug for many patients with inflammatory bowel disease. Because of the considerable adverse effects, probably related to the sulfapyridine component, the recent trend has been to use the active moiety of sulphasalazine, 5-aminosalicylic acid (5-ASA). 5-ASA is commercially available in the United Kingdom and the United States as mesalazine (Pentasa, 250 mg microgranules coated with ethyl cellulose as a slow release preparation, Asacol, 400 mg tablets coated with an acrylic based resin, which is released in the gut when pH is above 7) and olsalazine (Dipentum 250 mg tablets where two molecules of 5-ASA are linked by an azo bond). We report two cases of severe interstitial nephritis induced by Asacol to emphasise the importance of monitoring renal functions of patients who take 5-ASA preparations.

Case reports

CASE 1

A 28 year old man with no previous medical problems was seen in the gastroenterology clinic in April 1988 with bloody diarrhoea and lower abdominal pain. Clinical examination, blood counts, urine analysis, urea, and electrolytes were normal. Flexible sigmoidoscopy showed features suggestive of mild ulcerative colitis, which was confirmed on rectal biopsy. The symptoms settled down with mesalazine (Asacol) 400 mg three times daily and hydrocortisone (Colifoam) enema. In June 1990 he had a flare up of colitis and barium enema showed mild total colitis. Asacol was increased to 800 mg three times daily and prednisolone 40 mg was started. Although he improved initially, when prednisolone was reduced the diarrhoea worsened and he was admitted for intravenous hydrocortisone. During that admission he was found to have increased urea (7 mmol) and creatinine (394 μmol/l) values. Creatinine clearance was 45 ml/minute and urine protein was 2.9 g/24

hours. Asacol was stopped. Renal ultrasound, urine microscopy, calcium anti-glomerular basement membrane antibodies (GBM), anti-nuclear antibodies (ANA), rheumatoid factor, DNA binding, anti-cardiolipin antibody, cryoglobulins, immunoglobulins, and complements were either normal or negative. His creatinine clearance remained at 49 ml/min at three months after treatment with the drug had finished and a renal biopsy performed at that stage showed severe interstitial nephritis (Figure). A trial of prednisolone 60 mg daily was given without any improvement in renal functions. At the time of reporting he had developed hypertension, which required medical treatment. The ulcerative colitis has remained quiescent without any treatment.

CASE 2

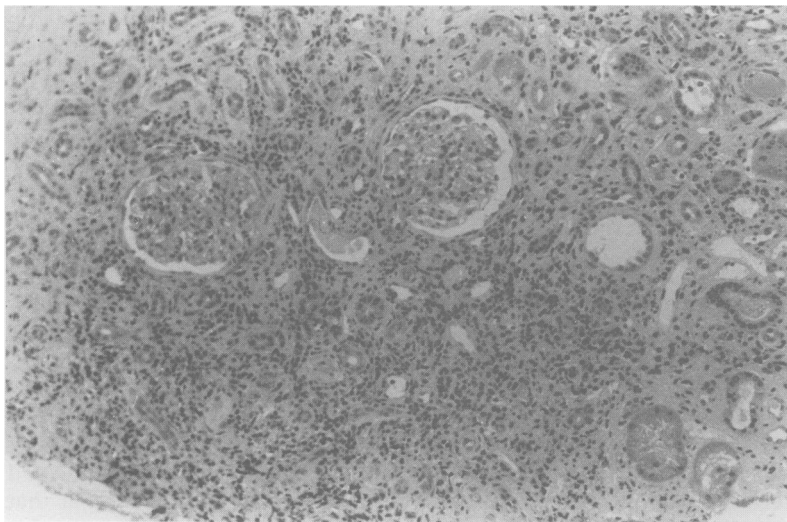
A 24 year old man without any previous medical history was seen in the gastroenterology clinic in February 1988 with a short history of bloody diarrhoea. Sigmoidoscopy showed diffuse colitis and biopsy showed ulcerative colitis. A white cell scan showed pancolitis. His renal functions showed normal electrolyte, urea (3.6 mmol), and creatinine (88 μmol/l) values. He was treated with Asacol 800 mg three times daily and hydrocortisone enemas with symptomatic recovery. He was given maintenance treatment with Asacol 800 mg three times daily. He had a relapse of colitis a few months later, which required oral prednisolone. When prednisolone was withdrawn in December 1989 he had a further relapse, which was again treated with corticosteroids. His creatinine rose through the normal range and was abnormal at 153 μmol/l in August 1989 and by February 1991 had reached concentrations over 300 μmol/l when Asacol was withdrawn. He was given maintenance treatment with prednisolone 6 mg daily. His renal functions remained unchanged and in April 1991 he was admitted for renal biopsy. Clinical examination, blood counts, electrolytes, liver function tests, calcium and C reactive protein were normal. Anti-neutrophil cytoplasmic antibodies, anti-GBM, ANA, rheumatoid factor, DNA binding, anti-cardiolipin antibody, cryoglobulins, complements, and immunoglobulins were normal or negative. Urine microscopy was normal and creatinine clearance was 47 ml/min. There was only minimal proteinuria. Renal biopsy showed inflammatory infiltrates with few eosinophil, periglomerular scarring, and peritubular scarring. Immunofluorescence for IgG, IgA, IgM, and C3 were negative. The histological appearances were consistent with active chronic interstitial nephritis. He was given a

West Middlesex
University Hospital,
Isleworth, Middlesex
P J Thuluvath
M Anderson

Hammersmith
Hospital, London
M Ninkovic
J Calam

Correspondence to:
Dr P J Thuluvath, Division
of Gastroenterology, Blalock
935, The Johns Hopkins
Hospital, 600 N Wolfe
Street, Baltimore MD
21205, USA.

Accepted for publication
31 January 1994



Renal biopsy specimen showing chronic severe interstitial nephritis.

trial of prednisolone 60 mg daily, but there was no improvement in renal functions. At the time of reporting his colitis is quiescent while receiving prednisolone 3 mg daily and serum creatinine stable at 280 $\mu\text{mol/l}$.

Discussion

Acute and chronic tubulointerstitial diseases are caused by a variety of agents.¹ The clinical presentations depend on the type of the insult, the site and the extent of renal damage. As the histological changes are very non-specific with regard to the aetiology, the diagnosis is made on the basis of history. The chronic interstitial nephritis in our patients was probably caused by 5-ASA (mesalazine) as they did not have any other known aetiological factors and had normal renal functions before the treatment.

'Analgesic nephropathy' characterised by interstitial nephritis and papillary necrosis is the most common cause of drug related renal failure. Phenacetin, aspirin or salicylate compounds and non-steroidal anti-inflammatory drugs (NSAIDs) are known to cause this type of nephropathy.²⁻⁴ 5-ASA has structural similarities to salicylates and phenacetin. In experimental models 5-ASA was shown to be nephrotoxic.⁵⁻⁷ The mechanism of renal damage caused by 5-ASA may be similar to that of salicylates, probably by causing hypoxia of renal tissues either by uncoupling oxidative phosphorylation in renal mitochondria or by inhibiting the synthesis of renal prostaglandins.^{4,8} High renal concentrations of salicylates also make the kidneys susceptible to oxidative damage by reducing renal glutathione concentration by inhibition of the pentose phosphate shunt.⁸ Our first patient (case 1) had proteinuria in the nephrotic range. Similar cases, with histological changes mainly confined to interstitium, have been previously reported in association with other NSAIDs; it has been suggested that the nephrotic syndrome in these cases may be mediated by T-lymphocyte activation.^{9,10}

Despite the theoretical risk of microcrystallisation of sulfapyridine in the renal tubules, only few cases of renal toxicity have been

reported with sulphasalazine use.^{11,12} In the small number of published reports, renal toxicity was seen as a part of a generalised hypersensitivity reaction to the drug. Since the introduction of 5-ASA, however, five cases of renal toxicity have been published.¹³⁻¹⁷ In addition to that, the Committee on Safety of Medicines in England and Wales has released information on nine possible cases of serious nephrotoxicity (four cases of interstitial nephritis, two nephrotic syndrome, and two renal failure) between February 1988 and December 1990 (including the cases reported here).¹⁸ Two of these patients had previous allergic reaction to sulphasalazine and one had renal dysfunction while receiving the drug. The two cases reported here were not receiving sulphasalazine before treatment with mesalazine. The significant delay between the onset of renal damage after treatment with mesalazine had started and the absence of other organ dysfunction suggest that the renal toxicity was not caused by a hypersensitivity reaction.

A number of studies have shown a significant correlation between the duration, the intensity, and the total dose of analgesics consumed and the degree of renal impairment.^{2,3,4,8} Our patients were receiving mesalazine 800 mg three times daily for 18-24 months when they were found to have renal impairment. 5-ASA is acetylated, independent of the acetylator status, to *N*-acetyl 5-ASA in the wall of ileum and colon.¹⁹ 5-ASA is absorbed in both the acetylated and non-acetylated form and once absorbed behaves similarly to other salicylates. Although it has been suggested that non-acetylated salicylates are less nephrotoxic,^{20,21} more recent studies have shown that both acetylated and non-acetylated forms of salicylate induce renal damage at similar doses.^{4-7,22} Under normal physiological conditions over 80% salicylate is inactivated in hepatic mitochondria to salicylurate, which is not known to cause uncoupling of oxidative phosphorylation in renal mitochondria. In the kidney salicylate is filtered and secreted by proximal tubules. Passive reabsorption occurs throughout the nephron resulting in high cortical and medullary concentration compared with the plasma concentrations.⁸ Clearance of salicylate, possibly related to saturation of the secretory mechanism, shows a direct correlation with urine flow and negative correlation with the plasma concentration.

The absorption of 5-ASA and acetyl-5-ASA is predominantly from the small intestine.^{23,24} Plasma concentrations of 5-ASA and acetyl-5-ASA are higher in subjects with intact colon compared with those with ileostomy.²⁵ The considerable individual variation in the absorption of these compounds makes it difficult to compare the published data on small group of subjects,²⁶ yet detection of these compounds in subjects who had only enema preparations of 5-ASA or acetyl-5-ASA suggest that significant absorption may take place in the colon.²⁷ The absorption from small bowel and colon depend on the pH, the

transit time, the mode of delivery of the drug, and perhaps the integrity of the mucosa.²⁵⁻³¹ Of these, the mode of delivery may be an important factor determining the peak plasma concentrations and thereby renal toxicity. On the basis of serum and 24 hour urinary excretion of 5-ASA and acetyl-5-ASA, it seems that maximum absorption is from plain 5-ASA preparations (almost 100%) followed by Asacol (20-30%), Pentasa (28-36%), and Dipentum (22-25%) in that order. The absorption from Asacol (coated with Eudragit S) seems to be lower than similar compounds like Claversal and Salofalk (coated with Eudragit L); this is related to the more proximal release of 5-ASA from these preparations.²⁵⁻³¹ It is interesting to note that the serum concentrations of 5-ASA and acetyl-5-ASA from Pentasa, designed to deliver 5-ASA throughout the small bowel, is less than Asacol and similar compounds. This may result from incomplete release of 5-ASA from the granules²⁶; or perhaps because the slow delivery does not overwhelm the acetylation capacity of the intestinal mucosa³² and assuming that acetyl-5-ASA is less well absorbed than 5-ASA. The absorption from olsalazine (Dipentum) seems to be similar to sulphasalazine making this compound, at least theoretically, less nephrotoxic.³¹ Our patients had total colitis. It is difficult to know whether this has predisposed them to the toxic effects of Asacol. It is possible that backwash ileitis and the change in pH may have led to the release of 5-ASA more proximally in the small bowel. Inflammation may also modify the mucosal acetylation and the absorption of 5-ASA and acetyl-5-ASA. The available data are insufficient, however, to find out if the absorption and the acetylation of 5-ASA compounds are related either to the extent or the severity of the disease.

Renal damage resulting from smaller doses of Asacol (400 mg three times daily) has also been reported suggesting that factors other than the amount of drug ingested may be involved. It has been suggested that prostaglandin inhibition enhances renal damage in the presence of hypovolaemia and salt depletion.⁴ With reference to this report, intravascular volume depletion resulting from diarrhoea may be a predisposing factor in patients with active inflammatory bowel disease. The longterm prognosis of our patients remain unclear. There has been no deterioration in renal functions since the drug was withdrawn, but the follow up of these patients has not been long enough to predict the future course. In patients with analgesic nephropathy, about a third improve, a third remain stable, and a third deteriorate.³³

In the case of analgesics, NSAIDs and 5-ASA, only a few patients develop renal damage. Patients with inflammatory bowel disease are more susceptible to damage because they will probably become dehydrated during exacerbation of their disease. As Asacol has been on the market longer than some other 5-ASA preparations, it is possible that nephrotoxicity may be noted with other

preparations in the future. Sterile pyuria and low specific gravity are early features in salicylate induced renal damage. Proteinuria and hypertension may suggest advanced disease. As there are definite advantages in using 5-ASA preparations over sulphasalazine in the treatment of inflammatory bowel disease, especially the higher doses in small bowel Crohn's disease, it will be important to monitor renal functions and urine microscopy.

- 1 Eknoyan G. Chronic tubulointerstitial nephropathies. In Schrier RW, Gottschalk CW, eds. *Diseases of the kidney*. Toronto: Little, Brown, 1988; 2191-221.
- 2 Eknoyan G. Analgesic nephrotoxicity and renal papillary necrosis. *Semin Nephrol* 1984; 4: 65-76.
- 3 Dubach UC, Rosner B, Pfister E. Epidemiologic study of abuse of analgesic containing phenacetin. Renal morbidity and mortality (1986-1979). *N Eng J Med* 1983; 308: 357-62.
- 4 Clive DM, Stoff JS. Renal syndromes associated with non-steroidal anti-inflammatory drugs. *N Engl J Med* 1984; 310: 563-72.
- 5 Calder IC, Funder CC, Green CR, Ham KN, Tange JD. Nephrotoxicity lesion from 5-aminosalicylic acid. *BMJ* 1972; 1: 152-4.
- 6 Briggs D, Calder I, Woods R, Tange J. The influence of metabolic variation on analgesic nephrotoxicity: experiments with Gunn rat. *Pathology* 1982; 14: 349-53.
- 7 Casadevall G, Moreno JJ, Franch MA, Queralt J. N-acetyl-D glucosaminidase (NAG) and alanine aminopeptidase (AAP) excretion after acute administration of acetaminophen, salsalate and aspirin in rats. *Res Commun Chem Pathol Pharmacol* 1983; 81: 77-89.
- 8 Duggin GG. Mechanisms in the development of analgesic nephropathy. *Kidney Int* 1980; 18: 553-61.
- 9 Brezin JH, Katz SM, Schwartz AB, Chinitz JL. Reversible renal failure and nephrotic syndrome associated with non-steroidal anti-inflammatory drugs. *N Engl J Med* 1979; 301: 1271-3.
- 10 Finkelstein A, Fraley DS, Stachura I, Feldman HA, Gandy DR, Bourke E. Fenpropfen nephropathy: lipid nephrosis and interstitial nephritis: a possible T-lymphocyte disorder. *Am J Med* 1982; 72: 81-7.
- 11 Chester AC, Diamond LH, Schreiner GE. Hypersensitivity to salicylazosulfapyridine. Renal and hepatic toxic reactions. *Arch Intern Med* 1978; 138: 1138-9.
- 12 Barbour VM, Williams PF. Nephrotic syndrome associated with sulphasalazine. *BMJ* 1990; 301: 818.
- 13 Mehta RP. Acute interstitial nephritis. *Can Med Assoc J* 1990; 143: 1031-2.
- 14 Novis BH, Korzets Z, Chen P, Berheim J. Nephrotic syndrome after treatment with 5-aminosalicylic acid. *BMJ* 1988; 296: 1442.
- 15 Ruf-Ballauf W, Hofstadter F, Krentz F. Akute interstitielle nephritis durch 5-aminosalicylsäure. *Internist* 1989; 30: 262-4.
- 16 Henning HV, Meinhold J, Eisenhauer T, Scheler F. Chronische interstitielle Nephritis nach Behandlung mit 5-aminosalicylsäure. *Dtsch Med Wochenschr* 1989; 114: 1091.
- 17 Von Muhlendahl KE. Nephritis durch 5 amino-salicylsäure. *Dtsch Med Wochenschr* 1989; 114: 236.
- 18 Anonymous. Nephrotoxicity associated with mesalazine (Asacol). *Current Problems* 1990; 30: 2.
- 19 Ireland A, Priddle JD, Jewell DP. Acetylation of 5-aminosalicylic acid by isolated human colonic epithelial cells. *Clin Sci* 1990; 78: 105-11.
- 20 Patrono C, Pierucci A. Renal effects of non-steroidal anti-inflammatory drugs in chronic glomerular disease. *Am J Med* 1986; 81 (suppl 2B): 71-83.
- 21 Reimann IW, Golbs E, Fisher C. Influence of intravenous acetylsalicylic acid and sodium salicylate on human renal function and lithium clearance. *Eur J Clin Pharmacol* 1985; 29: 435-41.
- 22 Abraham PA, Stillman MT. Salsalate exacerbation of chronic renal insufficiency: relation to inhibition of prostaglandin synthesis. *Arch Intern Med* 1987; 147: 1674-6.
- 23 Myers B, Evans DNW, Rhodes J, Evans BK, Hughes BR, Lee MG, et al. Metabolism and urinary excretion of 5-aminosalicylic acid in healthy volunteers when given intravenously or released for absorption at different sites in the gastrointestinal tract. *Gut* 1987; 28: 196-200.
- 24 Nielson OH, Bondesen S. Kinetics of 5-aminosalicylic acid after jejunal instillation in man. *Br J Clin Pharmacol* 1983; 16: 738-40.
- 25 Christensen LA, Fallinborg J, Abildgaard K, Jacobsen BA, Sanchez G, Hansen SH, et al. Topical and systemic availability of 5-aminosalicylate: comparisons of three controlled release preparations in man. *Aliment Pharmacol Ther* 1990; 4: 523-33.
- 26 Rasmussen SN, Bondesen S, Hvidberg EF, Hansen SH, Binder V, Halskov S, et al. 5-aminosalicylic acid in a slow release preparation: bioavailability, plasma level and excretion in humans. *Gastroenterology* 1982; 83: 1062-70.
- 27 Campieri M, Lanfranchi GA, Boschi S, Brignola C,

- Bazzocchi G, Gionchetti P, *et al.* Topical administration of 5-aminosalicylic acid enemas in patients with ulcerative colitis: studies on rectal absorption and excretion. *Gut* 1985; **26**: 400-5.
- 28 Bondesen S, Nielsen OH, Jacobsen O, Rasmussen SN, Hansen SH, Halskov S, *et al.* 5-aminosalicylic acid enemas in patients with active ulcerative colitis: influence of acidity on the kinetic pattern. *Scand J Gastroenterol* 1984; **19**: 677-82.
- 29 Rijk MCM, Van Hogeand RA, Van Schaik A, Van Tongren JHM. Disposition of 5-aminosalicylic acid from 5-aminosalicylic acid delivering drugs during accelerated intestinal transit in healthy volunteers. *Scand J Gastroenterol* 1989; **24**: 1179-85.
- 30 Rijk MCM, Van Schaik A, Van Tongeren JHM. Disposition of 5-aminosalicylic acid by 5-aminosalicylic acid delivery compounds. *Scand J Gastroenterol* 1988; **23**: 107-12.
- 31 Laursen LS, Stokholm M, Bukhave K, Rask-Madsen J, Lauritsen K. Disposition of 5-aminosalicylic acid by olsalazine and three mesalazine preparations in patients with ulcerative colitis: comparison of intraluminal colonic concentrations, serum values, and urinary excretion. *Gut* 1990; **31**: 1271-6.
- 32 Pieniaszek HJ, Bates TR. Capacity-limited gut wall metabolism of 5-aminosalicylic acid, a therapeutically active metabolite of sulphasalazine, in rats. *J Pharm Sci* 1979; **68**: 1323-5.
- 33 Nanra RS. Analgesic associated nephropathy. In: Massry SG, Glasscock RJ, eds. *Textbook of nephrology*. Baltimore: Williams & Wilkins, 1983; 6:195-201.