

Copper associated childhood cirrhosis

S P Horslen, M S Tanner, T D B Lyon, G S Fell, M F Lowry

Abstract

Several papers have reported severe liver disease in association with massive hepatic copper accumulation, which do not seem to be either of the recognised copper associated liver diseases, namely Wilson's disease and Indian childhood cirrhosis. A further case is reported in which novel copper kinetic studies were carried out using the stable isotope ^{65}Cu , showing that this patient did not suffer from Wilson's disease. It is suggested that these cases can be divided into two groups on the basis of age, clinical course, and history of excessive copper ingestion. The benefits of using ^{65}Cu for in vivo studies of copper metabolism is discussed.

(Gut 1994; 35: 1497-1500)

High concentrations of copper are found in the livers of patients suffering from Wilson's disease, Indian childhood cirrhosis, and conditions in which chronic cholestasis is a feature, although not usually to the same extent as seen in the first two conditions.¹ There are sporadic reports of children with

severe liver disease associated with extremely high liver copper concentrations who do not have Wilson's disease or Indian childhood cirrhosis.²⁻⁹ These cases may be divided into two groups; the first being infants in whom the copper accumulation has been attributed to excess copper intake from their water supply and a second group of older children with no evidence of excess copper intake.

We present a further family exemplifying the second condition and describe a newly validated method of studying copper kinetics using the stable isotope ^{65}Cu . We suggest that this condition is inherited in an autosomal recessive manner.

Case report

AAM was born in Bangladesh in 1983, came to the United Kingdom in 1986, and presented in 1990 with a six week history of jaundice, anorexia, and weight loss. He was found to have a firm enlarged liver. An older brother had died in Bangladesh at the age of nine years after jaundice for two years. Before death he developed abdominal distension and swollen legs. No investigations were available. Also, a paternal uncle had died in 1989, again in Bangladesh, aged 20 years after six months of jaundice and abdominal swelling. There is no history of excessive copper ingestion in AAM.

AAM had a mild iron deficiency anaemia, normal prothrombin time, and abnormal plasma concentrations of liver enzymes (Table I). Plasma caeruloplasmin and copper were normal, but the urinary excretion of copper was increased especially after penicillamine challenge (Table II). Liver biopsy (Fig 1) showed hepatocyte damage with ballooning, vacuolation, and intracellular hyaline inclusions as well as portal tract expansion and inflammation with early bridging. There

TABLE I Comparison of basic investigation results before treatment and after 18 months of penicillamine treatment

	November 1990	May 1992
Haemoglobin	10.9	10.1 g/dl
Prothrombin time (patient/control seconds)	$^{19}/_{14}$	$^{27}/_{16}$
Total bilirubin (ref range 0-17 $\mu\text{mol/l}$)	21	14
Alkaline phosphatase (ref range 110-295 IU/l)	485	579
γ -glutamyltransferase (ref range <45 IU/l)	498	47
AST (ref range 10-40 IU/l)	1286	61
ALT (ref range <30 IU/l)	819	23
Albumin (ref range 30-50 g/l)	35	33
Serum copper (ref range 11-25 $\mu\text{mol/l}$)	13.7-22.0	9.8
Caeruloplasmin (ref range 0.2-0.6 g/l)	0.25-0.35	0.25
Urinary copper excretion:		
Before penicillamine (ref range 0.2-0.8 $\mu\text{mol/day}$)	3.8	
After penicillamine (>25 $\mu\text{mol/day}$ suggests Wilson's disease ²²)	309	2.4
Liver copper (ref range <50 $\mu\text{g/g}$ dry weight)	2319	35

AST=aspartate aminotransferase; ALT=alanine aminotransferase.

TABLE II Review of published works of children with copper associated cirrhosis

Author	Country	Age, sex	Genetic	Liver copper	Outcome
<i>Cases in whom high water copper concentrations were reported</i>					
Walker-Smith ³	Australia	14 months, M	No	3360	Death in 6 weeks
Muller-Hocker ³	Germany	7 months, F	No	228*	Death in 3 months
Muller-Hocker ⁴	Germany	9 months, F	No	2154	Death in 4 months
		5 months, M		698*	Treated
Gormally (personal communication, 1992)	Ireland	7 months, M	No	Very high	Death in 2 months
<i>Cases in whom no excess copper ingestion was reported</i>					
Adamson ⁵	USA	2, M	Consanguinity	1500	Death in 8 months
Lefkowitz ⁶	USA	6, F	Siblings	1031	Death in 12 days
		5, M	Aunt died at 10 with cirrhosis	2083	Death in 6 months
		4, M		708	Death in 6 months
		5, F		992	Death in 6 months
Maggiore ⁷	Italy	10, M	No	1970	Treated
Lim ⁸	Singapore	4, F	Siblings	NA	Died
		4, F		NA	Died
		6, F		NA	Died
		5, M		1200	Treated
Bartok ⁹	Hungary	6, F	Consanguinity	2967-3564	Death in 32 months

Liver copper concentrations are in $\mu\text{g/g}$ dry weight, except where marked*, where the units are $\mu\text{g/g}$ wet weight; the conversion factor is approximately 3. NA=not available.

Department of Paediatrics, Children's Hospital, Sheffield

S P Horslen
M S Tanner

Institute of Biochemistry, Royal Infirmary, Glasgow

T D B Lyon
G S Fell

District General Hospital, Sunderland
M F Lowry

Correspondence to:
Dr S P Horslen, Department of Paediatrics, Children's Hospital, Sheffield S10 2TH.

Accepted for publication

12 January 1994

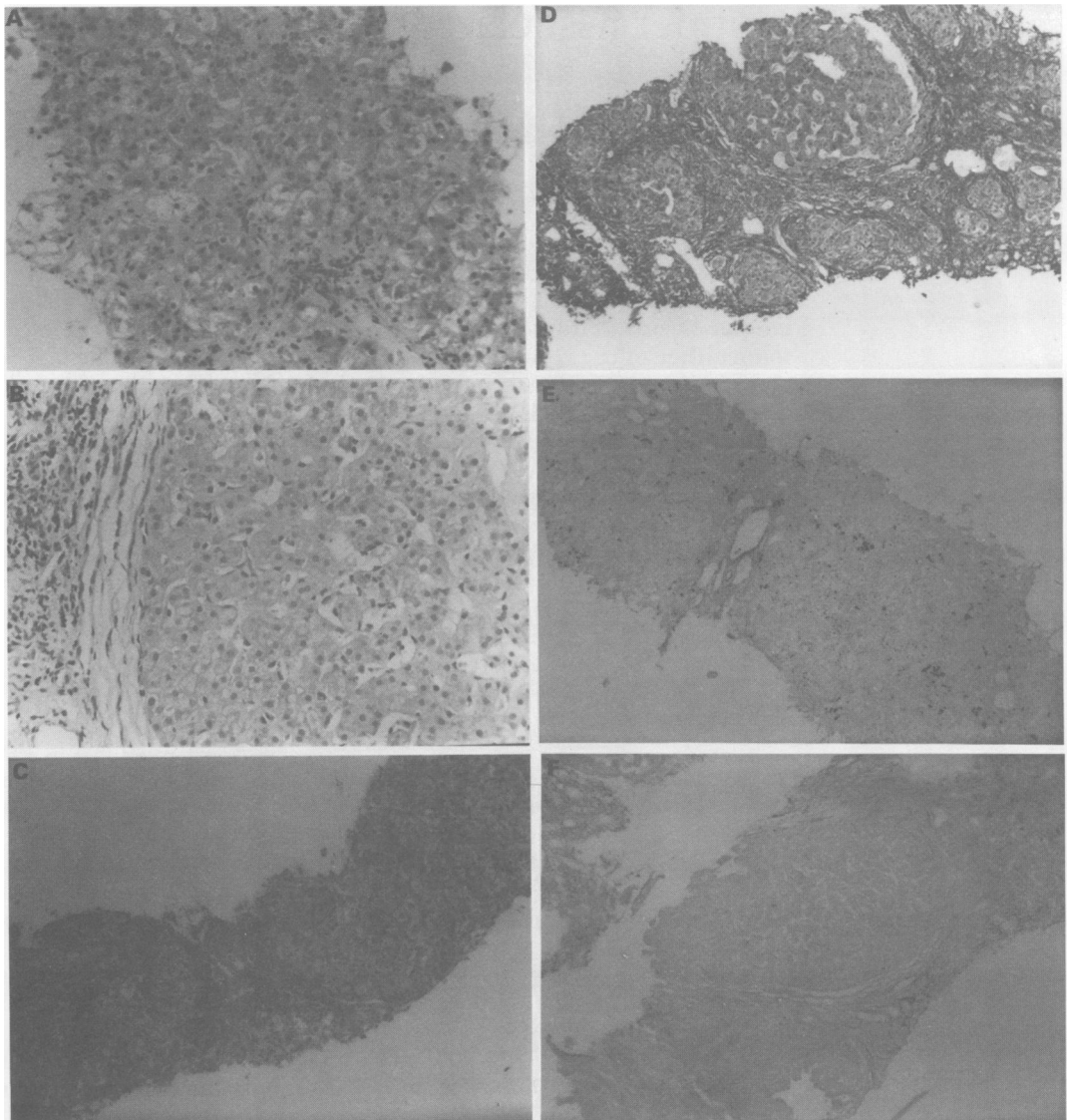


Figure 1: Liver histology – before and after 18 months of penicillamine treatment. Before treatment (A, C, E) – inflammatory cell infiltrate in periportal areas, ‘ballooning’ of hepatocytes, some bridging fibrosis and orcein positive (copper associated protein) granulation throughout. After treatment (B, D, F) – signs of active inflammation and orcein positive granules have disappeared, however, the hepatic fibrosis has progressed to a micronodular cirrhosis. (A and B: haematoxylin and eosin, original magnification $\times 200$; C and D: Van Geissen, original magnification $\times 100$; E and F: orcein, original magnification $\times 100$).

was gross orcein positive granular staining representing increased copper associated protein as well as evidence of increased ionic copper with rhodanine and rubeanic acid stains. Unlike Indian childhood cirrhosis, the parenchyma did not show intralobular pericellular fibrosis. The hepatic copper concentration was raised at 2319 $\mu\text{g/g}$ dry weight (normal $\leq 50 \mu\text{g/g}$).

He was treated with penicillamine 20 mg/kg/day from November 1990. His liver function tests progressively improved. On review in May 1992 he was well and well grown. He had a large irregular liver palpable three to four centimetres below the right costal margin and a spleen enlarged to seven centimetres. His plasma transaminases and caeruloplasmin were virtually normal (Table I), though the prothrombin time was prolonged. Plasma copper and zinc were both slightly low at 10.5 mmol/l and 9.8 mmol/l respectively (reference range for both metals 11–25 mmol/l), however, urinary copper losses remained raised (Table II). Repeat liver biopsy

(Fig 1) showed a dramatic decrease both in copper and copper associated protein, and liver copper content had fallen to within the normal range at 35 $\mu\text{g/g}$ dry weight. Inflammation was reduced, but fibrosis and nodularity increased, the features of an inactive cirrhosis. During this admission the ^{65}Cu enrichment study was performed.

Methods

Penicillamine treatment was stopped 48 hours before and for the duration of the test. A solution containing 2 mg of ^{65}Cu , as copper nitrate, was given in a cold drink after a baseline blood sample. Further blood samples were taken at 2, 6, and 50 hours. The serum was separated from the blood samples and stored at -20°C before transport. Inductively coupled plasma mass spectrometry was used to measure the $^{65}\text{Cu}/^{63}\text{Cu}$ ratio in serum samples, and the percentage by which the samples had been enriched with ^{65}Cu was calculated and then plotted against time.¹⁰

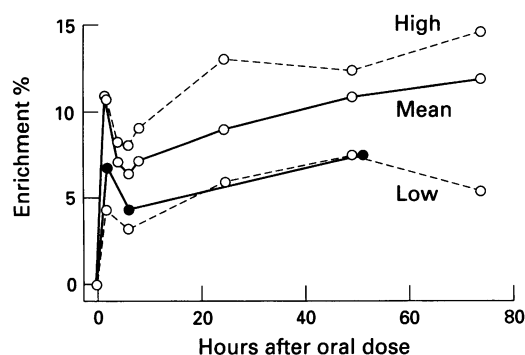


Figure 2: Result of ^{65}Cu isotope enrichment study on AAM (●—●—●) compared with the mean values and lower limits found in eight normal adults.

Results

The percentage enrichment of plasma ^{65}Cu in AAM reflected that seen in normal subjects (Fig 2) – that is, an early peak at about two hours followed by a rapid decrease and then a more gradual secondary rise over the next few days.

Discussion

Copper accumulation in hepatic tissue is commonly associated with chronic cholestasis of any cause, but cholestasis was not a feature in our patient. In Wilson's disease and Indian childhood cirrhosis the hepatic copper concentrations are usually much higher. In Wilson's disease there is an inability to incorporate copper into caeruloplasmin and to excrete biliary copper¹¹; in Indian childhood cirrhosis excessive ingestion of dietary copper is believed to be the cause, probably in association with other environmental and possible genetic factors.¹²⁻¹⁴ The other cases reported as having cirrhosis in childhood associated with massive liver copper concentrations fall into two groups according to whether excess dietary copper was identified (Table II). We have termed these type I and type II copper associated childhood cirrhosis (CACC). Other differences between type I and type II CACC include age at presentation, clinical course, and liver ultrastructure.

The patient described in this paper and the other cases of types I and II CACC in Table II do not have Wilson's disease for these reasons: (a) plasma caeruloplasmin concentration was normal; (b) the histology is dissimilar to that seen in Wilson's disease, in that staining for copper and copper associated protein was strongly positive. Characteristically in Wilson's disease at a young age these stains are unremarkable despite high liver copper measured biochemically¹¹; (c) the age at presentation of these cases was unusually young; (d) we have shown in our case normal incorporation of copper into caeruloplasmin.

This family and the others described as type II CACC differ from Indian childhood cirrhosis in these respects: (a) the median age at presentation of cases of Indian childhood cirrhosis is 18 months, with a range of about nine months to four years.¹⁵ All but one case of type II CACC presented during or

beyond their fourth year; (b) there was no history of excess copper ingestion; (c) jaundice in Indian childhood cirrhosis is a late and preterminal feature, and even with treatment with penicillamine it would be unusual for a jaundiced child with Indian childhood cirrhosis to survive.

Cases with type I CACC, however, have demonstrable excess copper intake from their water supply and have presented as infants. All the affected infants have received animal milk reconstituted with well water with high copper contents.^{2 16} All of the cases have been from rural families rather than urban and all have been fatal. This syndrome may represent Indian childhood cirrhosis in non-Indian children.

Type II CACC thus seems to be a distinct syndrome. As two of the families reported had consanguineous parents and three families had more than one affected child, we suggest that this is an autosomal recessive disorder.^{5 6 8 9} In this and other cases penicillamine treatment normalises plasma transaminases and in our patient lowered hepatic copper, although, like some survivors of penicillamine treated Indian childhood cirrhosis, our patient is left with an inactive cirrhosis. The outlook for AAM in the long term may include portal hypertension and further deterioration of hepatic function to end stage liver disease. He will require careful follow up as he already has established cirrhosis and his prothrombin time is now prolonged reflecting inadequacy of hepatic synthetic function. We feel that AAM should continue taking penicillamine for the foreseeable future as we believe he has an inherited disorder of copper metabolism, whereas it is our practice to discontinue penicillamine treatment in Indian childhood cirrhosis (and by implication type I CACC).

A similar condition to type II CACC is recognised by veterinary science. The copper toxicosis affecting Bedlington terriers is autosomal recessive, has massive hepatic copper loading, normal serum concentrations of copper and caeruloplasmin, and similar histological findings.^{17 18} Initially an affected animal is well, but may suddenly develop jaundice and fatal liver failure under the stress of whelping or being shown. Other affected animals may develop chronic hepatitis and cirrhosis. In neither type II CACC or Bedlington terrier disease is the primary metabolic defect known. The two possible explanations for copper accumulation in these conditions are either increased gut absorption of copper, which seems unlikely as AAM did not seem to have a higher than expected initial peak in the ^{65}Cu enrichment study, or impaired excretion. The main route of excretion of copper is biliary so we hypothesise that the metabolic defect in type II CACC may entail an inability to excrete copper into bile as has been suggested for Bedlington terrier copper toxicosis.¹⁹

Copper kinetics have in the past been difficult to carry out as the only suitable radioisotopes of copper, ^{64}Cu and ^{67}Cu , are not readily available and have short lives. This

means that careful arrangements are required to get patient and isotope together, and that blood samples need to be analysed almost immediately. After ^{64}Cu is given orally an early rise in the isotope in plasma, which is attributed to copper binding to albumin, is followed by an equally rapid fall, as copper is extracted from the circulation by the liver. In the liver the copper is bound to metallothionein (copper associated protein). From about six hours after ingestion of the copper a much more gradual rise in the plasma radio-isotope activity occurs in normal subjects as copper is incorporated into caeruloplasmin, which then passes back into the blood.^{20 21} In Wilson's disease there is no significant incorporation of radio-copper after the initial absorption peak.²⁰ Using the new technique of inductively coupled plasma mass spectrometry to separate the stable isotopes of copper, ^{63}Cu and ^{65}Cu , the same pattern of copper incorporation has been shown (G S Fell *et al* presented at the 2nd European Copper Research Group Meeting, April 1993). This method has the advantages that the ^{65}Cu can be stored without decaying ready for use when required; the patient is not exposed to a dose, albeit a small dose, of radiation; serum samples can be saved and transported for analysis. We have shown that useful results can be obtained from just four venous blood samples, taken at 0, 2, 6, and any time between 48 and 72 hours, making it more acceptable for children to undergo this investigation.

- 1 Danks DM. Copper and liver disease. *Eur J Pediatr* 1991; 150: 142-8.
- 2 Walker-Smith J, Blomfield J. Wilson's disease or chronic copper poisoning? *Arch Dis Child* 1973; 48: 476-9.
- 3 Muller-Hocker J, Weiss M, Meyer U, Schramel P, Wiebecke B, Belohradsky BH, *et al*. Fatal copper storage

- disease of the liver in a German infant resembling Indian childhood cirrhosis. *Vichows Arch A* 1987; 411: 379-85.
- 4 Muller-Hocker J, Meyer U, Wiebecke B, Hubner G, Eife R, Kellner M, *et al*. *Pathol Res Pract* 1988; 183: 39-45.
- 5 Adamson M, Reiner B, Olson JL, Goodman Z, Plotnick L, Bernardini I, *et al*. Indian childhood cirrhosis in an American child. *Gastroenterology* 1992; 102: 1771-7.
- 6 Lefkowitz JH, Honig CL, King ME, Hagstrom JWC. Hepatic copper overload and features of Indian childhood cirrhosis in an American sibship. *N Engl J Med* 1982; 307: 271-7.
- 7 Maggiore G, De Giacomo C, Sessa F, Burgio GR. Idiopathic hepatic toxicosis in a child. *J Pediatr Gastroenterol Nutr* 1987; 6: 980-3.
- 8 Lim CT, Choo KE. Wilson's disease in a 2 year old child. *J Singapore Paediatric Soc* 1979; 21: 99-102.
- 9 Bartok I, Szabo L, Horvath E, Ormos J. Juvenile zirrhosmit hochgradiger kupferspeicherung in der leber. *Acta Hepato-Splenologica* 1971; 18: 119-28.
- 10 Lyon TDB, Fell GS. Isotopic composition of copper in serum by inductively coupled plasma mass spectrometry. *J Anal Atom Spect* 1990; 26: 135-7.
- 11 Tanner S. *Paediatric hepatology*. Edinburgh: Churchill Livingstone, 1989.
- 12 Tanner MS, Portman B, Mowat AP, Williams R, Pandit AN, Mills CF, *et al*. Increased hepatic copper concentration in Indian childhood cirrhosis. *Lancet* 1979; i: 1203-5.
- 13 Popper H, Goldfisher S, Sternleib I, Nayak NC, Madhavan TV. Cytoplasmic copper and its toxic affects. Studies in Indian childhood cirrhosis. *Lancet* 1979; i: 1205-8.
- 14 Tanner MS, Kantarjian AH, Bhav SA, Pandit AN. Early introduction of copper-contaminated animal milk feeds as a possible cause of Indian childhood cirrhosis. *Lancet* 1983; i: 992-5.
- 15 Tanner MS. Indian childhood cirrhosis. In: Meadow SR, ed. *Recent advances in paediatrics* (8). Edinburgh: Churchill Livingstone, 1986; 103-20.
- 16 Schramel P, Muller-Hocker J, Meyer U, Weiss M, Eife R. Nutritional copper intoxication in three German infants with severe liver cell damage (features of Indian childhood cirrhosis). *J Trace Elem Electrolytes Health Dis* 1988; 2: 85-9.
- 17 Rutgers HC, Haywood S. Chronic hepatitis in the dog. *J Small Anim Pract* 1988; 29: 679-90.
- 18 Owen CA, Ludwig J. Inherited copper toxicosis in Bedlington terriers. *Am J Pathol* 1982; 106: 432-4.
- 19 Su LC, Owen CA Jr, Zollman PE, Hardy RM. A defect of biliary excretion of copper in copper-laden Bedlington terriers. *Am J Physiol* 1982; 6: G231-6.
- 20 Sternlieb I, Scheinberg IH. The role of radio copper in the diagnosis of Wilson's disease. *Gastroenterology* 1979; 77: 138-42.
- 21 Hodges S, Lobo-Yeo A, Donaldson P, Tanner MS, Vergani D. Autoimmune chronic active hepatitis in a family. *Gut* 1990; 32: 299-302.
- 22 Martins da Costa C, Baldwin D, Portmann B, Lolin Y, Mowat AP, Meile-Vergani G. Value of urinary copper excretion after penicillamine challenge in the diagnosis of Wilson's disease. *Hepatology* 1992; 15: 609-15.