

## Mapping of X-Linked Myxomatous Valvular Dystrophy to Chromosome Xq28

Florence Kyndt,<sup>1</sup> Jean-Jacques Schott,<sup>1</sup> Jean-Noël Trochu,<sup>3</sup> Florence Baranger,<sup>3</sup> Odile Herbert,<sup>2</sup> Valérie Scott,<sup>1</sup> Edith Fressinaud,<sup>4</sup> Albert David,<sup>2</sup> Jean-Paul Moisan,<sup>2</sup> Jean-Briec Bouhour,<sup>3</sup> Hervé Le Marec,<sup>1,3</sup> and Bernard Bénichou<sup>1,2</sup>

<sup>1</sup>Institut Nationale Santé Etude et Recherche Medical CJF 96-1, <sup>2</sup>Service de Génétique Médicale, <sup>3</sup>Clinique de Cardiologie, and <sup>4</sup>Service d'Hématologie Hôtel-Dieu, Centre Hospitalo-Universitaire de Nantes, Nantes, France

### Summary

Myxoid heart disease is frequently encountered in the general population. It corresponds to an etiologically heterogeneous group of diseases, idiopathic mitral valve prolapse (IMVP) being the most common form. A rarely observed form of myxoid heart disease, X-linked myxomatous valvular dystrophy (XMVD), is inherited in an X-linked fashion and is characterized by multivalvular myxomatous degeneration; however, the histopathological features of the mitral valve do not differ significantly from the severe form of IMVP. In this article, we describe the genetic analysis of a large family in which XMVD is associated with a mild hemophilia A. The coagulation factor VIII gene position in Xq28 provided a starting point for the genetic study, which was conducted by use of polymorphic markers. Two-point linkage analysis confirmed this localization, and a maximum LOD score of 6.57 was found at  $\theta = 0$  for two polymorphic microsatellite markers, INT-3 and DXS1008, the first one being intronic to the factor VIII gene. Haplotype analysis of this chromosomal region allowed the definition of an 8-cM minimal interval containing the gene for XMVD, between DXS8011 and Xqter.

### Introduction

Two inherited and nonsyndromic myxoid valvular heart dystrophies have been reported, and, of them, idiopathic mitral valve prolapse (IMVP), in its familial form or in

sporadic cases, is by far the most commonly encountered: IMVP is observed with a 4% and 2% frequency in the young adult population (for women and men, respectively) (Savage et al. 1983). Most affected patients are asymptomatic, but some of them suffer from atypical chest pain. Endocarditis, spontaneous cordal rupture, progressive mitral regurgitation, and sudden death are rare complications. Histologically, in the severe adult form, the mitral valve shows a myxomatous degeneration (King et al. 1982; Tamura et al. 1995); the mode of inheritance of this trait is usually considered to be autosomal dominant, with an age- and sex-dependent expression (Hunt and Sloman 1969; Kramer et al. 1981; Devereux et al. 1982). IMVP is the most common familial cardiovascular abnormality in humans to be inherited in a Mendelian fashion. By use of linkage analysis in some informative families, four collagen genes have been excluded as candidate genes for IMVP (Henney et al. 1989; Wordsworth et al. 1989); however, this result cannot be taken as definitive, since genetic heterogeneity is possible, which could, in addition, underlie the severity of the lesions.

The second myxoid valvular heart disease is called X-linked myxomatous valvular dystrophy (XMVD), or sex-linked valvular dysplasia (MIM 314400; McKusick 1997). This congenital cardiac dystrophy is thought to be rare and was first identified three decades ago (Monteleone and Fagan 1969). The mode of inheritance has been defined as X-linked and recessive. Clinically, the male patients present with multivalvular defects that, in a number of cases, necessitate surgery. Histologically, the cardiac valves show a myxomatous degeneration with secondary calcification, and the histological features of pathological mitral valves are reminiscent of severe forms of IMVP. Only males have been reported as being affected, whereas obligate carrier females have been registered as unaffected (Monteleone and Fagan 1969; Newbury-Ecob et al. 1993).

So far, and possibly because of the small size of the pedigrees reported, none of the inherited forms of non-syndromic cardiac valvular dystrophy has been mapped

Received June 19, 1997; accepted for publication December 22, 1997; electronically published March 4, 1998.

Address for correspondence and reprints: Dr. Hervé Le Marec, Laboratoire de Physiologie et de Pharmacologie Cellulaires et Moléculaires, INSERM CJF 96-1, Centre Hospitalo-Universitaire de Nantes, 9 quai Monousu, 44093 Nantes Cedex 1, France. E-mail: herve.lemarec@chu-nantes.fr

© 1998 by The American Society of Human Genetics. All rights reserved. 0002-9297/98/6203-0016\$02.00

on human chromosomes, and thus no responsible gene has been identified. We present here the first large XMVD family that allowed a precise genetic study of this disease. The genetic linkage analysis, facilitated by the X-linked mode of inheritance and by the association with a mild form of hemophilia A in this pedigree, permitted a rapid chromosomal mapping of the XMVD gene.

### Subjects, Material, and Methods

#### *Family Studies, Phenotyping of Patients, and Collection of Materials*

This large five-generation XMVD pedigree is of French origin and was not consanguineous (fig. 1). The cardiac clinical status of 92 members has been ascertained through two-dimensional standard echocardiography and color-coded Doppler analysis according to the recommendations of the American Society of Echocardiography and the criterion defined for the mitral apparatus (Henry et al. 1980; Weissman et al. 1994). The coagulation status was analyzed following standard protocols. The linkage analysis did not include deceased family members, for whom clinical status could be inferred only anecdotally from living relatives. All patients who participated in this study granted informed consent with respect to the genetic analysis.

#### *Clinical Characterization of XMVD*

Detailed clinical features of this obviously X-linked disease (no male-to-male transmission was recorded in this family), including the previously undescribed occurrence of moderately affected women, are to be reported in detail elsewhere (Trochu JN, Schott JJ, Kyndt F, Gueffet JP, Bénichou B, Le Marec H., unpublished data). Patients were considered to be affected when echocardiographic analysis identified at least a trivial regurgitation of one of the left cardiac valves and/or when an obvious dystrophy of the mitral valve was present, whether or not associated with billowing. They were considered to be unaffected when the echocardiogram was normal or when the regurgitation was physiological (Henry et al. 1980; Weissman et al. 1994).

Nine male patients were obviously affected by mitral valve dystrophy, and six of them had severe or moderate aortic regurgitation. These findings led to cardiac valve surgery in four cases: patients III-4, III-10, and III-14 underwent surgery for severe aortic regurgitation and had moderate mitral regurgitation as well, and patient V-11 had mitral valvuloplasty because of severe mitral regurgitation secondary to mitral valve prolapse. Histological examination of the excised aortic valves showed typical features of myxomatous valvular dystrophy. The five other affected males had obvious mitral

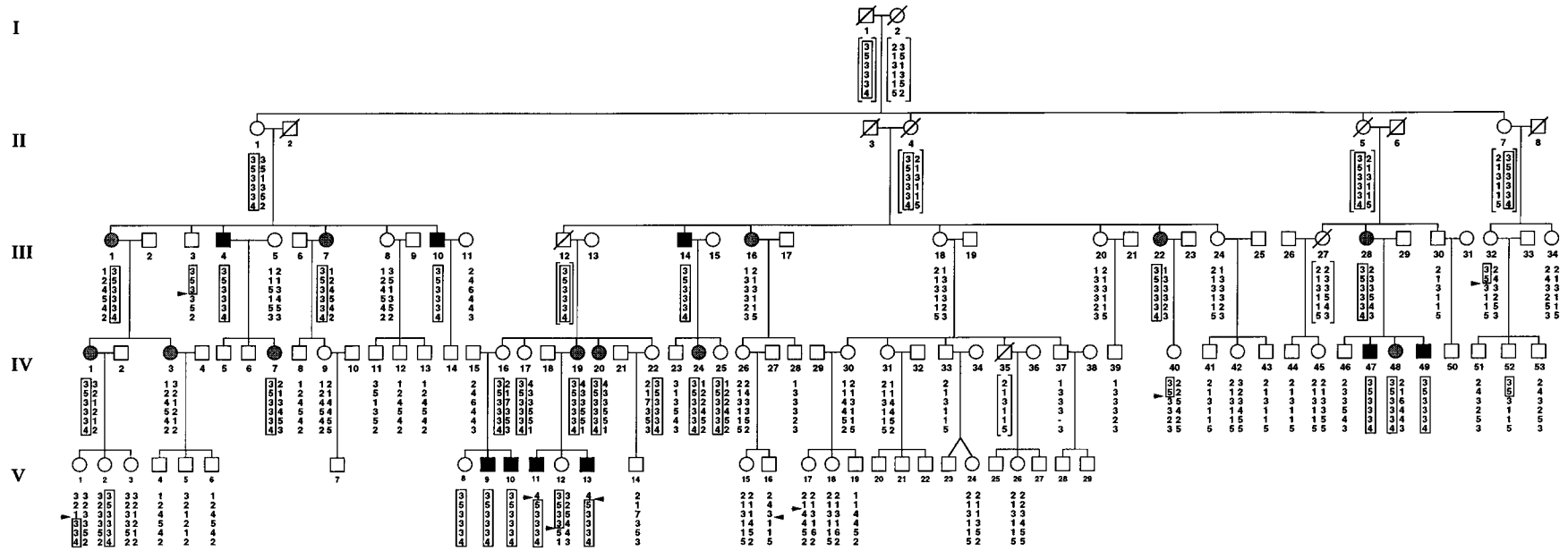
valvular dystrophy, as ascertained by echocardiographic examination. In all affected males, mitral valves were characterized by thicker anterior (AML) and posterior (PML) leaflets ( $4.7 \pm 0.7$  mm vs.  $2.0 \pm 0.4$  mm, for AML, and  $3.8 \pm 0.6$  mm vs.  $1.8 \pm 0.4$  mm, for PML;  $P < .0001$ ), longer AML and PML ( $28.1 \pm 2.4$  mm vs.  $22.1 \pm 4.4$  mm and  $13.6 \pm 1.7$  mm vs.  $10.1 \pm 1.8$  mm, respectively;  $P < .001$ ), and larger mitral annular diameter at end diastole ( $31.3 \pm 3.0$  mm vs.  $23.8 \pm 5.1$  mm;  $P < .001$ ). Since, in this pedigree, males appeared either clearly affected or not affected at all, we were prompted to consider that the penetrance was full. Furthermore, a mild form of hemophilia A was systematically associated with this valvular disease, whereas XMVD-unaffected males were not hemophiliacs. This defect was investigated biologically and did not show any difference with classical hemophilia A, suggesting that hemophilia A and XMVD cosegregate by coincidence in this particular family (see Discussion).

As for females, the valvular defect was less severe; none of them had significant echocardiographic feature of valvular dystrophy (i.e., echocardiographic thickening and lengthening of the mitral valve leaflets and enlargement of the mitral annulus), but 12 of them presented with mild to moderate aortic and/or mitral regurgitation. Finally, a karyotype analysis for patient V-11 did not detect any chromosomal abnormality.

#### *DNA Microsatellite Marker Analysis*

DNA was extracted from whole blood by means of standard protocols. Since the F8 gene lies in Xq28 and XMVD cosegregates with hemophilia A, a series of microsatellite markers spanning the entire Xq28 region was analyzed.

Four of the microsatellites used here—DXS998, DXS8091, DXS8011, and DXS8061—have been characterized at Généthon (<http://www.genethon.fr/>) (Dib et al. 1996); another one, INT-13, is a dinucleotide marker located within F8 gene intron 13 (Lalloz et al. 1994); the last one, DXS1108, lies close to the Xq pseudoautosomal region (Freije et al. 1992). PCR reactions were carried out in 20- $\mu$ l volumes, containing 2  $\mu$ l diluted genomic DNA (~200 ng), 1  $\times$  *Taq* buffer (50 mM KCl, 1.5 mM MgCl<sub>2</sub>, 10 mM Tris-HCl pH 9), 0.2 mM each dNTP, 1  $\mu$ M each of both oligonucleotide primers, and 1 unit *Taq* polymerase (Pharmacia); the mix was then subjected to 30 cycles of PCR amplification, under annealing conditions adapted for each primer, with a Peltier thermal cycler 200 (MJ Research). Two microliters of each PCR product were then diluted with 1  $\mu$ l of loading buffer, denatured for 2 min at 94°C, and kept on ice until separation on a 6% denaturing polyacrylamide gel; the DNA was then transferred onto a nitrocellulose membrane (Hybond, Amersham), hybridized to a la-



**Figure 1** XMVD pedigree. Hatched symbols denote affected patients; symbols for affected males are darker than those for females, to indicate that males are simultaneously affected by severe XMVD and by hemophilia A. Marker order is as follows (*top to bottom*): DXS998, DXS8091, DXS8011, DXS8061, INT-13, and DXS1108. The ancestral disease-bearing haplotype is boxed. Blackened arrows indicate recombinations of parental alleles. Haplotypes in brackets have been reconstructed.

**Table 1****Pairwise LOD Scores for the XMVD Locus, Male-Only Study**

MARKER	LOD SCORE AT $\theta =$						
	0	.01	.05	.1	.2	.3	.4
DXS998	-4.37	-.17	-1.00	-1.42	-1.50	-1.17	-.62
DXS8091	-4.38	2.95	3.36	3.27	2.71	1.94	1.00
DXS8011	-1.27	-.02	.54	.68	.66	.52	.30
DXS8061	3.84	3.78	3.54	3.22	2.53	1.76	.89
INT-13	5.91	5.81	5.41	4.89	3.81	2.64	1.34
DXS1108	5.91	5.81	5.41	4.90	3.82	2.65	1.35

beled 18-mer CA repeat oligonucleotide probe, revealed as recommended by the company (ECL direct nucleic acid labeling and detection system, Amersham), and visualized by autoradiography.

#### Linkage Analysis

The order and intermarker distances given here were as published elsewhere (Dib et al. 1996), and the linkage analyses were carried out on a personal computer using the MLINK features of the LINKAGE program 5.2 (Lathrop and Lalouel 1984). The XMVD disease-allele frequency was assumed to be .00001, on the basis of the rarity of reported cases. Values of .02 and .04 were used to account for possible phenocopies for males and females, respectively, which correspond to IMVP frequency in the general population (Savage et al. 1983). Allele frequencies were arbitrarily assigned a value of  $1/n$ , where  $n$  refers to the number of alleles observed. Since incorrect parameters for linkage analysis may give false results, positive LOD scores were tested for robustness by use of either published frequencies or the frequencies observed in this family. The results were almost identical in every case, suggesting that the number of members in this family was sufficient to obtain very consistent results.

## Results

#### Linkage Analysis

Patient DNAs were typed with six CA repeat polymorphic markers, one of them being intronic to the F8 gene, spanning a total of 19 cM, and haplotypes were reconstructed for important absent or deceased family members (fig. 1). Since the occurrence of this disease has been reported only twice, and for very small pedigrees, the definition of the parameters for LOD score calculations was not obvious. Only male phenotypes were first used to calculate the LOD scores, thus avoiding the use of an arbitrary penetrance value for females.

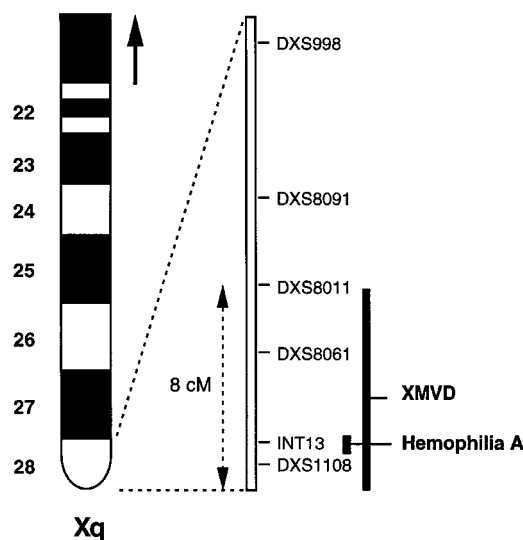
The results of the two-point linkage analysis are given in table 1. An identical maximum LOD score of 5.91 at  $\theta = 0$  was obtained for INT-13 and DXS1108. Haplotype analyses permitted the reconstruction of the ances-

tral disease-bearing haplotype, which was harbored by the ancestor male I-1, who transmitted the mutant allele for XMVD and hemophilia A to all of his daughters. Furthermore, four recombination events have been characterized in male patients III-3, IV-52, V-11, and V-13, allowing precise delineation of the XMVD candidate region to a 8-cM interval between markers DXS8011 and Xqter (fig. 2).

Retrospectively, it has been possible to calculate the penetrance value of valvular regurgitation for females, which may affect XMVD heterozygous patients. Among 17 females harboring the complete minimal disease-linked haplotype, only 10 had a mitral and/or aortic valve abnormality, thus giving a penetrance value of .59. The subsequent two-point linkage analysis gave an identical and increased maximum LOD score of 6.57 at  $\theta = 0$  for INT-13 and DXS1108, which is consistent with the male-only linkage analysis (table 2). Two of the clinically affected women (III-16 and IV-3) did not inherit the disease haplotype and thus appear to be phenocopies.

#### Genomic Analysis around the F8 Gene

Because XMVD and hemophilia A cosegregate in this family, despite the fact that both diseases exist as isolated entities, it was of interest to check whether a single mutation event—namely, a large genomic deletion encompassing either the 5' or 3' sequences—could have simultaneously damaged F8 gene and other genes, thus explaining this complex phenotype. Two sets of oligonucleotides immediately adjacent to the 5' or 3' F8 gene



**Figure 2** Chromosome Xq28 backbone. Polymorphic markers used for linkage analysis are represented. The XMVD gene has been mapped between DXS8011 and Xqter. Factor VIII gene, which is mutated in hemophilia A, has also been represented.

**Table 2****Pairwise LOD Scores for the XMVD Locus, Male and Female Study**

MARKER	LOD SCORE AT $\theta =$						
	0	.01	.05	.1	.2	.3	.4
DXS998	-10.32	-.72	.49	.97	1.19	1.00	.57
DXS8091	-10.66	2.81	3.27	3.25	2.89	2.10	1.14
DXS8011	-4.71	.64	1.18	1.27	1.12	.83	.45
DXS8061	3.91	3.87	3.69	3.43	2.77	1.99	1.05
INT-13	6.57	6.46	6.03	5.48	4.36	3.11	1.65
DXS1108	6.57	6.47	6.07	5.56	4.48	3.22	1.71

sequences were designed and used in PCR experiments, in order to detect possible deletions in XMVD-affected males. No deletion was observed (data not shown).

**Discussion**

The similar symptomatology in this family and in the two other reported pedigrees and the same mode of inheritance permits us to classify them as most likely affected by the same disease, namely XMVD. The clinical association of hemophilia A and XMVD raised the possibility that a single mutation event could have led to the observed complex phenotype. Indeed, prior to the linkage analysis, it could not be excluded that the mutation on a single gene located anywhere on the X chromosome, and simultaneously involved in factor VIII biological activity regulation and cardiac valve integrity, would be the molecular basis of this uncommon clinical association. In order to verify that the coagulation abnormality was indeed linked to the F8 gene, haplotype analyses were conducted throughout the Xq28 telomeric region. As expected, the segregation of hemophilia A was absolutely compatible with the existence of an F8 gene mutation.

Two-point linkage analyses between each marker and the male XMVD phenotype were performed in parallel. This allowed the mapping of the cardiac defect to an Xq28 8-cM region encompassing the F8 gene, with a very significant maximum LOD score value. A subsequent linkage analysis including all male and female patients was performed, and the results supported the Xq28 localization, providing evidence that the heterozygous status for XMVD may be echographically detectable in females. Two phenocopies were identified, which is in agreement with the 4% estimated occurrence of IMVP in the general female population. Cases of moderately affected females had not been reported previously for XMVD, and the occurrence of such cases in this pedigree may be due to skewed X inactivation, as has been shown for dyskeratosis congenita, or to the presence of an allelic variant (Devriendt et al. 1997). From the haplotype analysis, a penetrance value of .59 was estimated for females. The four females (III-32, IV-40, V-1, and V-12) who harbored recombinations within the

candidate region were not echographically affected and thus did not allow refinement of the candidate region.

Direct sequence analysis of the large F8 gene is in progress, in order to identify the causative F8 gene mutation. Nevertheless, many arguments clearly played in favor of the occurrence of two independent mutation events: (i) both hemophilia A and XMVD exist as separate clinical entities; (ii) although hemophilia A is a frequent disease, this particular association had never before been reported; (iii) a contiguous gene syndrome is very unlikely, because large F8 gene deletions are associated with severe forms of hemophilia A and also because no large deletion has been detected in this family by PCR on F8 gene neighboring sequences; and (iv) several cases of severe hemophilia A with large deletions of the F8 gene, either encompassing the whole gene or telomeric or centromeric parts of it and extending to neighboring regions, have been reported, whereas no valvulopathy was associated, which also excludes the possibility that the gene intronic to the F8 gene may be involved in XMVD (Kenwrick et al. 1992; Murru et al. 1994).

Xq28 is known to contain numerous genes involved in X-linked diseases, including two pathologies involving the heart: fatal X-linked infantile cardiomyopathy and Barth syndrome, a disease for which the mutant gene has been recently identified (Gedeon et al. 1995; Bione et al. 1996). Although these diseases are not typically associated with valvular dystrophy, at the present time, we cannot formally exclude that XMVD is allelic to one of these syndromes; XMVD may more likely be the result of a mutation in a gene involved in extracellular matrix integrity, since syndromic mitral valvular dystrophy is frequent in heritable disorders of connective tissue, such as Marfan and Ehlers-Danlos syndromes and osteogenesis imperfecta (Beighton 1969; Pyeritz and Wappel 1983). Interestingly, a gene located within the Xq28 minimal region, BGN, codes for a protein called "biglycan," which is an interesting candidate gene because it is found as a constituent of extracellular matrices in many tissues (Fisher et al. 1989; Traupe et al. 1992). However, complete exon sequence analysis in two families of XMVD did not detect any mutation in this gene (authors' unpublished data). Analysis of other candidate genes is in progress in our laboratory.

This first mapping of the gene for a nonsyndromic valvular dystrophy should help clarify the nosology of this heterogeneous group of diseases. Furthermore, this work paves the way for the identification of the molecular basis of this disease, which may ultimately shed light on the physiopathology of the very frequent IMVP.

**Acknowledgments**

We are very grateful to the Jurg Ott linkage course team, for teaching us the basics of genetic linkage, as well as to Sabine

Fauré, from Généthon. We also thank Agnès Peignard for secretarial assistance. This work was supported by INSERM, by the Association Française contre les Myopathies, and by the Association de Recherche en Physiopathologie et Pharmacologie, CHU Nantes, France. V.S. was the recipient of a special grant from Roche Pharmaceutical.

## References

- Beighton P (1969) Cardiac abnormalities in the Ehlers-Danlos syndrome. *Br Heart J* 31:227-232
- Bione S, D'Adamo P, Maestrini E, Gedeon AK, Bolhuis PA, Toniolo D (1996) A novel X-linked gene, G4.5, is responsible for Barth syndrome. *Nat Genet* 12:385-389
- Devereux RB, Brown WT, Frammer-Fox R, Sachs I (1982) Inheritance of mitral valve prolapse: effect of age and sex on gene expression. *Ann Intern Med* 97:826-832
- Devriendt K, Matthijs G, Legius E, Schollen E, Blockmans D, Van Geet C, Degreef H, et al (1997) Skewed X-chromosome inactivation in female carriers of dyskeratosis congenita. *Am J Hum Genet* 60:581-587
- Dib C, Fauré S, Fizames C, Samson D, Drouot N, Vignal A, Millasseau P, et al (1996) A comprehensive genetic map of the human genome based on 5,264 microsatellites. *Nature* 380:152-154
- Fisher LW, Termine JD, Young MF (1989) Deduced protein sequence of bone small proteoglycan I (biglycan) shows homology with proteoglycan II (decorin) and several nonconnective tissue proteins in a variety of species. *J Biol Chem* 264:4571-4576
- Freije D, Helms C, Watson MS, Donis-Keller H (1992) Identification of a second pseudoautosomal region near the Xq and Yq telomeres. *Science* 258:1784-1787
- Gedeon AK, Wilson MJ, Colley AC, Silence DO, Mulley JC (1995) X-linked fatal infantile cardiomyopathy maps to Xq28 and is possibly allelic to Barth syndrome. *J Med Genet* 32:383-388
- Henney AM, Tsipouras P, Schwartz RC, Child AH, Devereux RB, Leech GJ (1989) Genetic evidence that mutations in the COL1A1, COL1A2, COL3A1, or COL5A2 collagen genes are not responsible for mitral valve prolapse. *Br Heart J* 61:292-299
- Henry LH, DeMaria A, Gramiak R, King DL, Kisslo JA, Popp R, Sahn DJ, et al (1980) Report of the American Society of Echocardiography Committee on Nomenclature and Standards in Two-Dimensional Echocardiography. *Circulation* 62:212-217
- Hunt D, Sloman G (1969) Prolapse of the posterior leaflet of the mitral valve occurring in eleven members of a family. *Am Heart J* 8:149-153
- Kenrick S, Levinson B, Taylor S, Shapiro A, Gitschier J (1992) Isolation and sequence of two genes associated with a CpG island 5' of the factor VIII Gene. *Hum Mol Genet* 1:179-186
- King BD, Clark MA, Baba N, Kilman JW, Wooley CF (1982) "Myxomatous" mitral valves: collagen dissolution as the primary defect. *Circulation* 66:288-296
- Kramer R, Devereux RB, Brown WT, Sachs I (1981) Inheritance of mitral valve prolapse: autosomal dominant with variable expression. *Am J Hum Genet Suppl* 33:82A
- Lalloz MR, Schwaab R, McVey JH, Michaelides K, Tuddenham EG (1994) Haemophilia A diagnosis by simultaneous analysis of two variable dinucleotide tandem repeats within the factor VIII gene. *Br J Haematol* 86:804-809
- Lathrop GM, Lalouel JM (1984) Easy calculations of LOD scores and genetic risks on small computers. *Am J Hum Genet* 36:460-465
- McKusick VA (1997) Mendelian inheritance in man: a catalog of human genes and genetic disorders, 12th ed. Johns Hopkins University Press, Baltimore
- Monteleone PL, Fagan LF (1969) Possible X-linked congenital heart disease. *Circulation* 39:611-614
- Murru S, Casula L, Casarino L, Moi P, Rocchi M, Loi A, Annalena F, et al (1992) A DNA fragment from Xq21 replaces a deleted region containing the entire FVIII gene in a severe hemophilia A patient. *Genomics* 23:352-361
- Newbury-Ecob RA, Zuccollo JM, Rutter N, Young ID (1993) Sex-linked valvular dysplasia. *J Med Genet* 30:873-874
- Pyeritz RE, Wappel MA (1983) Mitral valve dysfunction in the Marfan syndrome: clinical and echocardiographic study of prevalence and natural history. *Am J Med* 74:797-807
- Savage DD, Garrison RJ, Devereux RB, Castelli WP, Anderson SJ, Levy D, McNamara PM, et al (1983) Mitral valve prolapse in the general population. I. Epidemiologic features: the Framingham study. *Am Heart J* 106:571-576
- Tamura K, Fukuda Y, Ishizaki M, Masuda Y, Yamanaka N, Ferrans VJ (1995) Abnormalities in elastic fibers and other connective-tissue components of floppy mitral valve. *Am Heart J* 6:1149-1158
- Traupe H, van den Ouweland AMW, van Oost BA, Vogel W, Vetter U, Warren ST, Rocchi M, et al (1992) Fine mapping of the human biglycan (BGN) gene within the Xq28 region employing a hybrid cell panel. *Genomics* 13:481-483
- Weissman NJ, Pini R, Roman MJ, Kramer-Fox R, Andersen HS, Devereux RB (1994) In vivo mitral valve morphology and motion in mitral valve prolapse. *Am J Cardiol* 73:1080-1088
- Wordsworth P, Ogilvie D, Akhras F, Jackson G, Sykes B (1989) Genetic segregation analysis of familial mitral valve prolapse shows no linkage of fibrillar collagen genes. *Br Heart J* 61:300-306